

Prognostic value of p53 protein expression and clinicopathological factors in infiltrating ductal carcinoma of the breast. A study of 192 patients

J.J. Sirvent^{1,2}, A. Fortuño-Mar², M. Olona^{1,2} and A. Ortí³

¹Joan XXIII Hospital, Tarragona, ²Faculty of Medicine, University Rovira i Virgili, Reus, and

³Verge de la Cinta Hospital, Tortosa, Spain

Summary. The p53 gene is located on the short arm of chromosome 17. It encodes a 53-kd nuclear protein (p53) found in scant amounts in normal tissue. Mutations of the p53 gene have been reported in different human tumours. In breast cancer, it has been noted that the overexpression of p53 protein in the nucleus is an indicator of poor prognosis, although there is a high degree of variability, which may be due to different immunohistochemical techniques, varying assessment of results and the type of monoclonal antibody used.

This study is an immunohistochemical analysis of p53 expression in 192 cases of infiltrating ductal carcinoma of the breast, correlating it with clinicopathological factors and the clinical course of the disease.

Of all the breast-cancer tissue analysed, stains for p53 antibody were found in 87 tumours (45.3%). The results of multivariate analysis show that the independent predictors related to recurrence are tumour size, lymph-node metastasis and p53, while those related to death are necrosis, lymph-node metastasis and p53.

In summary, our series showed prognostic significance between the expression of p53 and shorter survival time and disease-free interval for all patients in general as well as those who presented lymph-node metastases at the time of diagnosis.

Key words: p53, Immunohistochemical, Ductal carcinoma, Prognosis

Introduction

Breast carcinoma is the most frequent malignant tumour in women (Tarragona, Spain: 26.1%). Despite advances in hormone treatment and chemotherapy, the mortality rate has not diminished. It would be interesting

to carry out further studies to find prognostic factors which could help us predict the patient's clinical outcome, such as the relationship between the classical prognostic factors (i.e., tumour size, differentiation degree, histological type, lymph-node metastases) and new ones, because histology alone cannot always predict the clinical course of the disease due to the high degree of subjectivity involved. It has therefore become essential to look at the expression of different factors to determine prognostic groups (Bacus et al., 1989).

The p53 gene is located on the short arm of chromosome 17. It encodes a 53-kd nuclear protein (p53) found in scant amounts in normal tissue. Through the synthesis of this protein, the gene exerts an inhibitory effect on cell proliferation and transformation (Lane and Benchemol, 1990; Ostrowski et al., 1991; Weinberg, 1991), and controls the initiation and/or regulation of DNA replication, as well as the transcription and regulation of the response to DNA alteration (Levine et al., 1991; Marshall, 1991) and programmed cell death (Hollstein et al., 1991; Montenarh, 1992; Dutta et al., 1993). Mutations of the p53 gene have been reported in different human tumours (Nigro et al., 1989). Such mutations favour the expression of more stable, nonfunctioning mutant forms of the protein with a longer half-life, which accumulate in the nucleus and can be detected by immunohistochemistry (Iggo et al., 1990; Jaros et al., 1992). There is a correlation between the detection of mutations by molecular biology methods, like single-strand conformation polymorphism (SSCP), and the detection of the protein by immunohistochemistry (Varley et al., 1991; Thor et al., 1992; Andersen et al., 1993; Marchetti et al., 1993; Bhargava et al., 1994; Fisher et al., 1994; Hurlimann et al., 1994).

This study is an immunohistochemical analysis of p53 expression in 192 cases of infiltrating ductal carcinoma of the breast, correlating it with clinicopathological factors and the clinical course of the disease.

Materials and methods

A total of 192 patients with invasive breast

carcinoma were studied in the Verge de la Cinta Hospital in Tortosa from 1981 to 1992. Fresh tissue from biopsy or tumourectomy was received in the Pathology Department immediately after surgical removal. It was fixed in buffered formalin for up to 18 hours and then embedded in paraffin.

Clinical study

Conventional clinical features were evaluated, including age, menstrual status, treatment carried out, complementary treatment, presence of metastases (local and distant) and patient death (distinguishing between death from breast cancer and other causes). Follow-up information was extracted from patients' charts or, if a patient died, by correspondence with the hospital and attending physician at the time of death.

Histopathological characteristics

Histopathological characteristics were studied in sections stained with haematoxylin-eosin. The histological grade was determined according to criteria established by Bloom and Richardson (1957), modified by Elston (1988), and histological type according to the WHO classification (1981).

Classic pathological features were evaluated, including tumour size, tumour necrosis and node metastases. Tumour size (in mm). Tumour necrosis, depending on whether or not there was necrosis in the infiltrating component of the carcinoma. Presence or absence of lymph-node metastasis and, if present, the number of nodes involved.

Immunohistochemical study

The methodology previously described (Sirvent et al., 1995) was used to determine p53 protein. The protein was assessed according to the intensity of staining (I), with values from 0 to 2, and the number of positive cells (P) was quantified as 1 when the percentage was from 1 to 24%, 2 at 25-49% positive cells, 3 at 50-74% positive cells, and 4 at 75-100% positive cells. A histological score was calculated by the formula, $I \times P$; the range was from 0 to 8 (no values of 5 or 7 were recorded).

Statistical analysis

Descriptive analysis: The mean, the standard deviation (SD) and minimum and maximum values were used for quantitative variables. Categorical variables were described in terms of absolute and relative frequency.

Survival analysis: Survival curves were calculated for recurrence and death using the Kaplan-Meier method.

Predictive-factor analysis: Recurrence and death

were used as independent variables.

Univariate analysis: The Cox proportional-risk analysis was used to calculate the relative risk (RR) of the different predictive variables. A 95% confidence interval (95% CI) was calculated for each RR.

Multivariate analysis: The Cox proportional-risk analysis was used to evaluate the independent predictive variables after they were adjusted. The results are given as RR with a 95% CI.

The accepted level of statistical significance was $p < 0.05$.

Data analysis was carried out using the BMDP package of statistical programs (Dixon, 1991).

Results

Clinical and histological findings

Patient characteristics are shown in Table 1. The mean age at diagnosis in this series was 60 years (SD 12.9) (range, 27-90). Menstrual status was known in 179 of the 192 patients, of whom 152 (84.9%) were postmenopausal (12 months or more since the last menstruation).

Table 1. Clinical, histological and immunohistochemical findings.

<i>Menopausal status</i>		
Premenopausal women		27
Postmenopausal women		152
Unknown		13
<i>Tumour size</i>		
≤ 20 mm		72
21-50		88
>50		15
Unknown		17
<i>Histological grade</i>		
I		90
II		73
III		26
Unknown		3
<i>Tumour necrosis</i>		
Presence		57
Absence		129
Unknown		6
<i>Lymph-node status</i>		
Negative		72
Positive		85
1-3		49
> 3		36
Unknown		35
<i>p53</i>		
Positive (1-8)		87
1		16
2		22
3		9
4		11
6		8
8		21
Negative		105

Histological grade I tumours were more common (47.6%) than grades II and III (38.6% and 13.7%, respectively). The mean tumour size was 3 cm (range, 0.3-11 cm). Tumour necrosis was seen in 57 cases (30.6%). Of the 157 cases in which the axillary nodes could be analysed, 85 (54.1%) presented metastases in a varying number of nodes, ranging from 3 to 37.

p53

Specific staining was confined exclusively to the nuclei, showing different degrees of intensity and different numbers of positive cells (Figs. 1-4); it was observed exceptionally in the cytoplasm of cells undergoing mitosis (Fig. 2). Stains for p53 antibody were found in 87 tumours (45.3%) (Table 1).

Clinical outcome

The median follow-up for mortality was 61.5 months (95% CI: 56.7-70.7) and for relapse was 51.9 (95% CI: 37.1-60.8) during which time there were 55 deaths resulting from breast cancer. Disease-specific survival

analyses were based on deaths resulting from breast cancer, leading us to censor the survival time of 16 patients because of "death due to other causes". The number of relapses was 79 cases.

The disease-free interval was 84% at one year (95% CI: 78.6-90.1) and 59.6% at five years (95% CI: 49.0-70.0). Survival time was 96% at one year (95% CI: 93.0-99.0) and 74.1% at five years (95% CI: 65.0-82.0).

The relapse and overall survival curves for p53 and lymph nodes are shown in Figs. 5A, 5B, 6A and 6B.

Table 2 gives the results of the univariate analysis. In the case of tumour recurrence, statistically significant predictors were age, tumour size, necrosis, lymph-node metastasis and p53. Age, tumour size, degree of differentiation, necrosis, lymph-node metastasis and p53 were significantly related to death.

The results of the multivariate analysis (Table 3) show that the independent predictors related to recurrence are tumour size, lymph-node metastasis and p53, while those related to death were necrosis, lymph-node metastasis and p53. Moreover, in the node-positive group, p53 was an independent indicator for disease-free interval and overall survival as well. It does not act as an

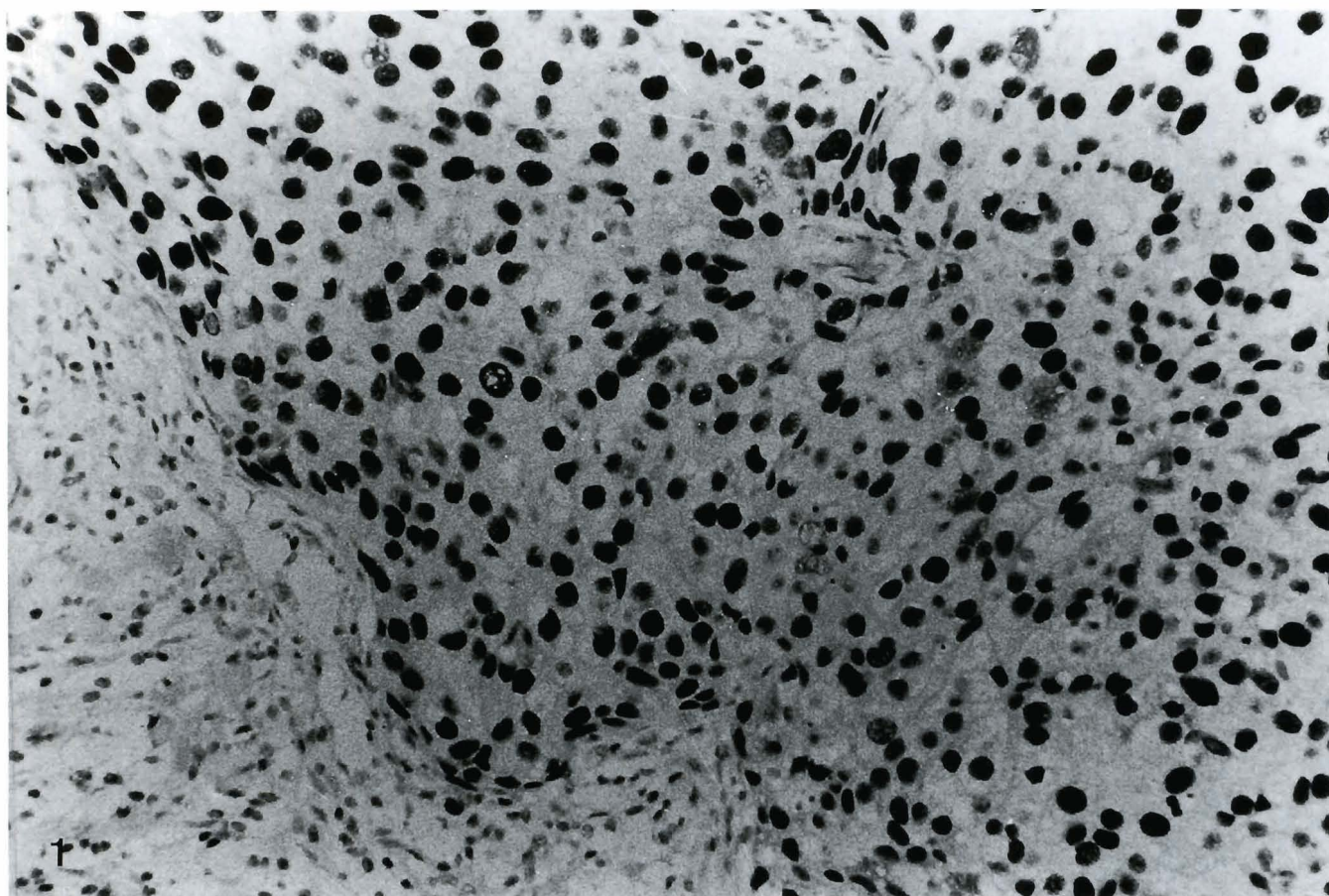


Fig. 1. p53. Strong positive expression in nearly all cells (histoscore 8). ABC, x 250

independent prognostic variable in patients who are node-negative and p53-positive. The significance of p53 becomes evident when we compare negative cases with those expressing some degree of positivity, whatever the histoscore may be.

Discussion

In histochemical studies the p53 protein is found in the cell nucleus where the mutated protein clusters. On rare occasions we observed cytoplasmic positivity in

some cells undergoing mitosis, when the nuclear membrane was ruptured.

In our work we found p53 protein, to a greater or lesser extent, in 45.3% of the cases, a figure that falls within the values published in the literature, which range from 11 to 58% (Friedrichs et al., 1993; Lipponen et al., 1993; Martinazzi et al., 1993; Charpin et al., 1995; Gohring et al., 1995; Rosanelli et al., 1995; Rosen et al., 1995; Sirvent et al., 1995; Horne et al., 1996; Katoh et al., 1996).

This variability in results may be due to different

Table 2. Univariate analysis in operable breast-cancer patients: Cox proportional-risk analysis.

	RECURRENCE RR (95% CI)	SURVIVAL RR (95% CI)
Age	1.40 (1.01-1.92)	1.52 (1.02-2.27)
Tumour size	2.30 (1.36-2.80)	1.84 (1.21-2.79)
Histological grade	1.31 (0.97-1.34)	1.43 (1.02-2.01)
Necrosis	2.43 (1.05-1.67)	1.42 (1.09-1.84)
Lymph-node status	1.99 (1.44-2.79)	2.17 (1.45-3.23)
p53 stain	2.02 (1.29-3.19)	1.84 (1.07-3.16)

Table 3. Multivariate analysis in operable breast-cancer patients: Cox proportional-risk analysis

	RECURRENCE RR (95% CI)	SURVIVAL RR (95% CI)
Age	1.36 (0.95-1.99)	1.49 (0.96-2.29)
Tumour size	1.95 (1.11-2.91)	1.25 (0.76-2.04)
Histological grade	1.03 (0.73-1.45)	1.12 (0.75-1.68)
Necrosis	1.17 (0.88-1.55)	1.52 (1.02-2.26)
Lymph-node status	2.05 (1.46-2.88)	2.54 (1.63-3.99)
p53 stain	1.89 (1.08-3.33)	1.84 (1.06-4.31)

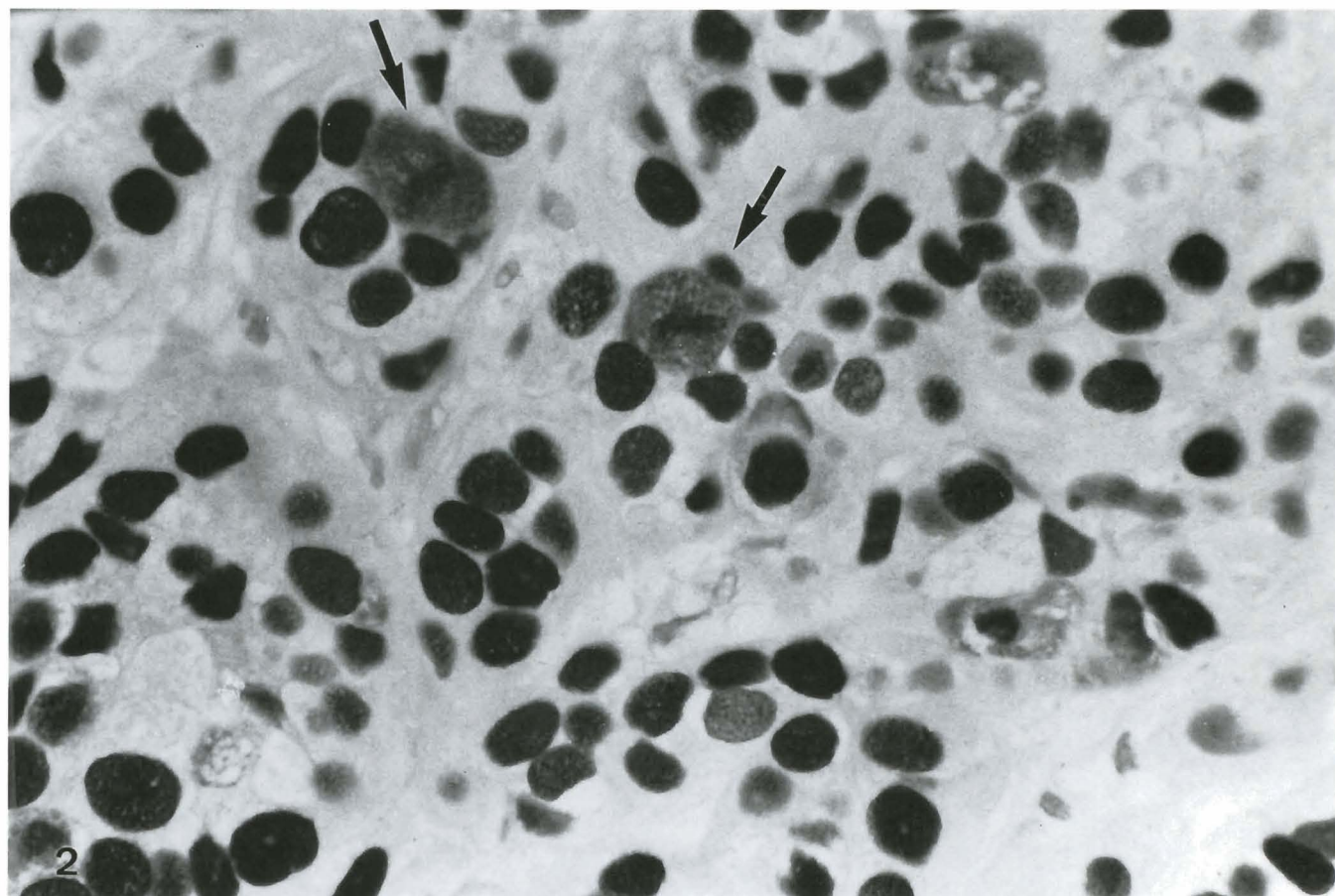


Fig. 2. p53. Cells undergoing mitosis are positive in the cytoplasm also. ABC, x 400

p53 and breast cancer

immunohistochemical techniques (Fisher et al., 1994). For example, a very important step is antigen recovery, which is done at an early stage and may be accomplished with enzymes or heat, using a microwave oven, pressure cooker, baby-bottle steriliser, etc. and immersing the preparations in citrate buffer (pH 6).

Another important aspect is the assessment of the immunohistochemical results. Some studies express the number of positive cells as a percentage, considering a case positive when the number of positive cells is above 10% (Cattoretti et al., 1988; Thor et al., 1992; Andersen et al., 1993). We preferred a semi-quantitative method, which recent studies have shown to give a very good correlation with the true mutation of a gene exon, especially at higher values (histoscores of 6 and 8) (Bartek et al., 1990; Fisher et al., 1994). All cases showing more than two-thirds of the cells positive and with marked staining had a p53 mutation (Schmitt et al., 1998).

To determine the sensitivity and specificity of immunohistochemistry for the detection of p53, the literature contains various studies using techniques for detecting mutations of the different exons which find a good correlation (Varley et al., 1991; Thor et al., 1992;

Andersen et al., 1993; Marchetti et al., 1993; Fisher et al., 1994), although there are as many as 30% false positives and negatives (Sommer et al., 1992; Dunn et al., 1993; Lohmann et al., 1993; Sjogren et al., 1996). This may be due to more positive cases being detected by immunohistochemistry than by genetic study (false positives), or because nonsense mutations occur which therefore do not accumulate protein (false negatives).

Another factor that may influence the results is the type of monoclonal antibody used. In our study we used the DO7 clone because the results were very good in tissue sections fixed in formalin and embedded in paraffin; there was also a very good correlation with the other most commonly used antibody (Pab1801) (Friedrichs et al., 1993; Jacquemier et al., 1994; Horne et al., 1996).

In our study, the presence of p53 protein proved to be of independent prognostic value for both recurrence and overall survival. Friedrichs et al. (1993) and Thor et al. (1992) - the latter with a much longer follow-up - also found that p53 is an independent prognostic factor. Sjogren et al. (1996) observed that patients expressing p53 have a shorter disease-free interval and survival time, although this author's results were not statistically

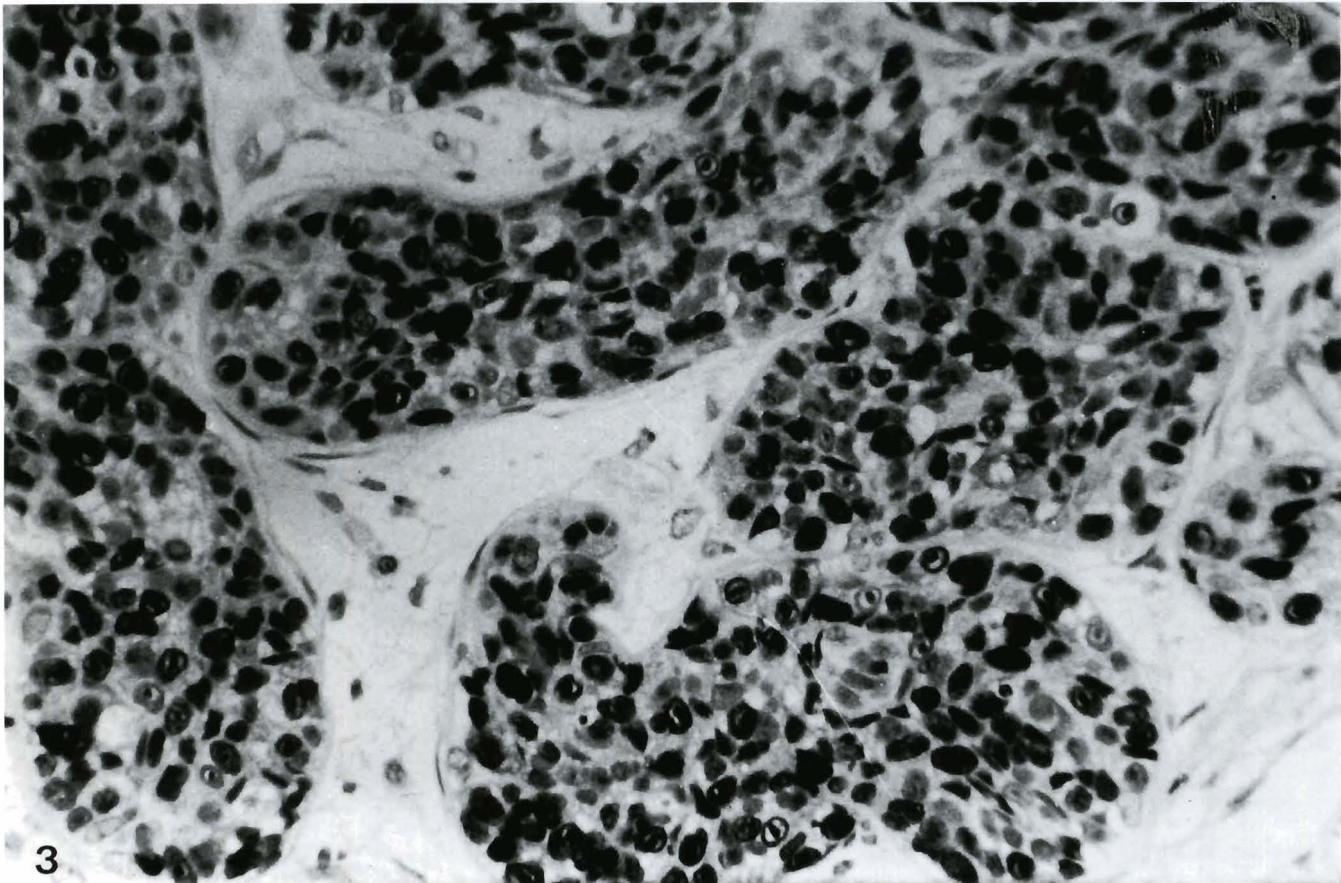


Fig. 3. Cancerisation of a lobule. p53-protein expression in tumour cells. ABC, x 250

significant.

The p53 gene has also been shown to be an independent prognostic factor in node-positive patients, both for relapse and disease-free interval (MacGrogan et al., 1995). It does not act as an independent prognostic

variable in patients who are node-negative and p53-positive, although the prognosis is worse for relapse, especially at high values (histoscore > 6). Neither is it significant for overall survival. These findings contrast with some reported in the literature (Allred et al., 1993;

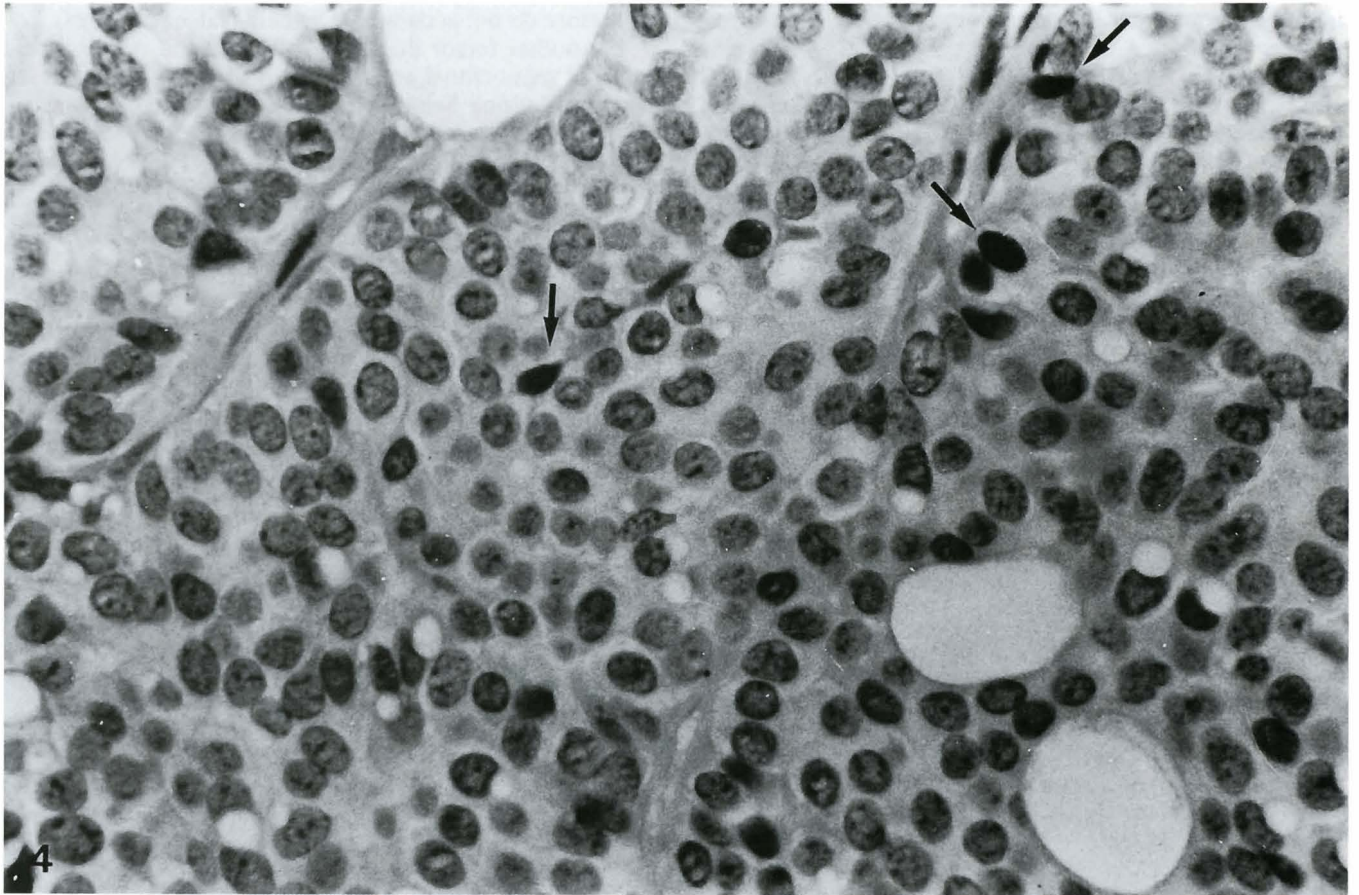


Fig. 4. Only a few cells are positive (histoscore 1). ABC, x 400

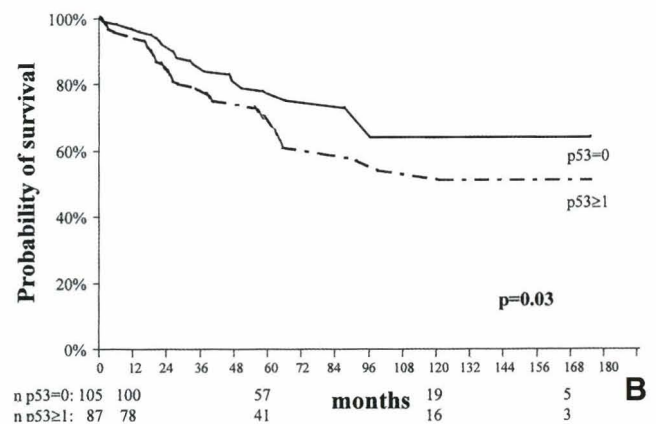
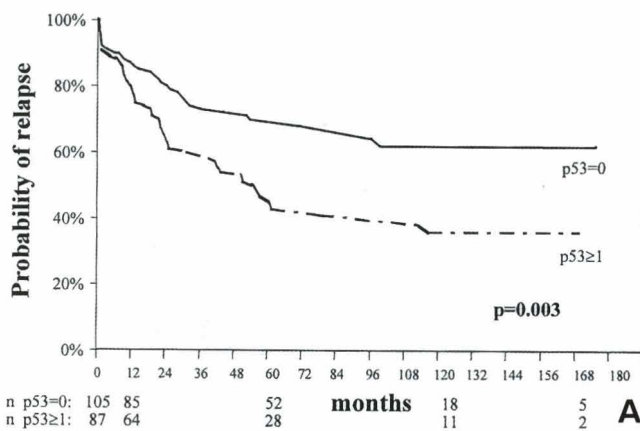


Fig. 5. A,B. Relapse and overall survival curves for p53.

p53 and breast cancer

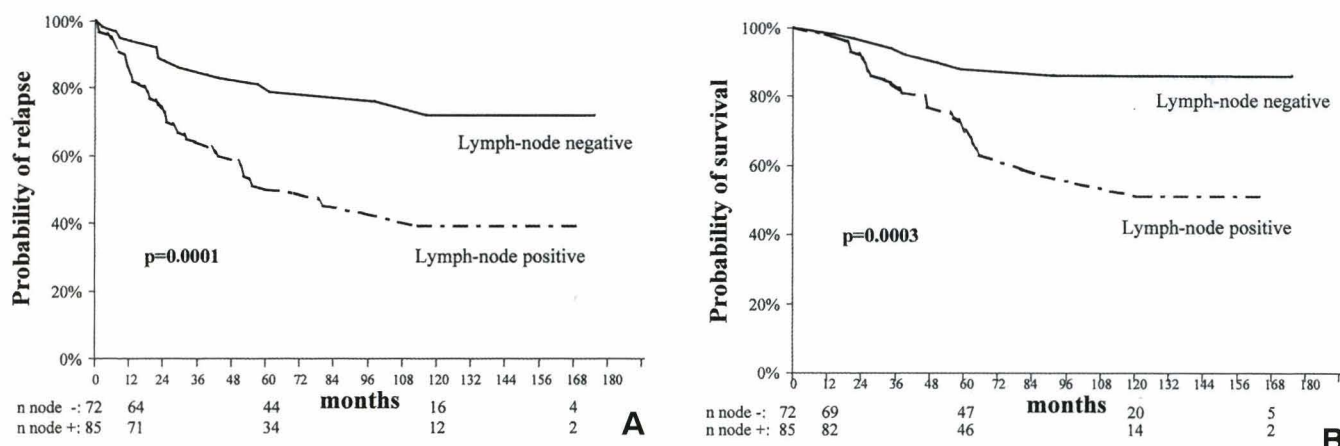


Fig. 6. A,B. Relapse and overall survival curves for lymph nodes.

Silvestrini et al., 1993, 1996).

In summary, our series showed prognostic significance between the expression of p53 and shorter survival time and disease-free interval for all patients in general as well as those who presented lymph-node metastases at the time of diagnosis.

Acknowledgements. This study is part of a doctoral thesis (Ortí A) that was awarded the Dr. Ferran Foundation's prize for the best research project in 1997. We wish to thank Ms. M.T. Salvadó, R. Risa and M. Mar Barberà for their excellent technical assistance and Ms. Martha Hobart for the translation.

References

- Allred D.C., Clark G.M., Elledge R., Fuqua S.A., Brown R.W., Chamness G.C., Osborne C.K. and McGuire W.L. (1993). Association of p53 protein expression with tumor cell proliferation rate and clinical outcome in node-negative breast cancer. *J. Natl. Cancer Inst.* 85, 200-206.
- Andersen T.I., Holm R., Nesland J.M., Heimdal K.R., Ottestad L. and Borresen A.L. (1993). Prognostic significance of TP53 alterations in breast cancer. *Br. J. Cancer* 68, 540-548.
- Bacus S.S., Goldschmidt R., Chin D., Moran G., Weinberg D. and Bacus J.W. (1989). Biological grading of breast cancer using antibodies to proliferating cells and others markers. *Am. J. Pathol.* 135, 783-792.
- Bartek J., Iggo R., Gannon J. and Lane D.P. (1990). Genetic and immunohistochemical analysis of mutant p53 in human breast cancer cell lines. *Oncogene* 5, 893-899.
- Bhargava V., Thor A., Deng G., Ljung B.M., Moore II D.H., Waldmann F., Benz C., Goodson III W., Mayall B., Chew K. and Smith H.S. (1994). The association of p53 immunopositivity with tumor proliferation and other prognostic indicators in breast cancer. *Mod. Pathol.* 17, 361-368.
- Bloom H.J.G. and Richardson W.W. (1957). Histological grading and prognosis in breast cancer. *Br. J. Cancer* 11, 359-377.
- Catoretti G., Rilke F. and Andreola S. (1988). p53 expression in breast cancer. *Int. J. Cancer* 41, 178-183.
- Charpin C., DeVictor B., Andrac L., Amabile J., Bergeret D., LaVaut

- M.N., Allasia C. and Piana L. (1995). p53 quantitative immunohistochemical analysis in breast carcinomas. *Hum. Pathol.* 26, 159-166.
- Dixon W.J. (1991). BMDP statistical software. Vol 1 and 2. University of California Press. Berkeley.
- Dunn J.M., Hastrich D.J., Newcomb P., Webb J.C., Maitland N.J. and Farndon J.R. (1993). Correlation between p53 mutations and antibody staining in breast carcinoma. *Br. J. Surg.* 80, 1410-1412.
- Dutta A., Ruppert J.M., Aster J.C. and Winchester E. (1993). Inhibition of DNA replication factor RPA by p53. *Nature* 365, 79-82.
- Elston C.W. (1988). Grading of invasive carcinoma of the breast. In: *Diagnostic histopathology of the breast*. Page D.L. and Anderson T.J. (eds). Churchill Livingstone. Edinburgh. pp 303-311.
- Fisher C.J., Gillett C.E., Vojtesek B., Barnes D.M. and Millis R.R. (1994). Problems with p53 immunohistochemical staining: the effect of fixation and variation in the methods of evaluation. *Br. J. Cancer* 69, 26-31.
- Friedrichs K., Gluba S., Eidtmann H. and Jonat W. (1993). Overexpression of p53 and prognosis in breast cancer. *Cancer* 72, 3641-3647.
- Gohring U.J., Scharl A., Heckel C., Ahr A. and Crombach G. (1995). p53 protein in 204 patients with primary breast carcinoma: immunohistochemical detection and clinical value as a prognostic factor. *Arch. Gynecol. Obstet.* 256, 139-146.
- Hollstein M., Sidransky D., Vogelstein B. and Harris C.C. (1991). p53 mutations in human cancers. *Science* 253, 49-53.
- Horne G.M., Anderson J.J., Tiniakos D.G., McIntosh G.G., Thomas M.D., Angus B., Henry J.A., Lennard T.W. and Horne C.H. (1996). p53 protein as a prognostic indicator in breast carcinomas: a comparison of four antibodies for immunohistochemistry. *Br. J. Cancer* 73, 29-35.
- Hurlimann J., Chaubert P. and Benhattar J. (1994). p53 gene alterations and p53 protein accumulation in infiltrating ductal breast carcinomas: correlation between immunohistochemical and molecular biology technique. *Mod. Pathol.* 7, 423-428.
- Iggo R., Gatter K., Bartek J., Lane D. and Harris A.L. (1990). Increased expression of mutant forms of p53 oncogene in primary lung cancer. *Lancet* 335, 675-679.
- Jacquemier J., Moles J.P., Penault-Llorca F., Adelaide J., Torrente M., Viens P., Birnbaum D. and Theillet C. (1994). p53 immunohistochemical analysis in breast cancer with four monoclonal antibodies:

p53 and breast cancer

- comparison of staining and PCR-SSCP results. *Br. J. Cancer* 69, 846-852.
- Jaros E., Perry R.H., Adam L., Kelly P.J., Crawford P.J., Kalbag R.M., Mendelow A.D., Sengupta R.P. and Pearson A.D.J. (1992). Prognostic implications of p53 protein, epidermal growth factor receptor, and Ki-67 labelling in brain tumours. *Br. J. Cancer* 66, 373-385.
- Katoh A., Breier S., Stemmler N., Specht S., Blanock K and D'Amico F. (1996). p53 protein expression in human breast carcinoma: lack of prognosis potential for recurrence of the disease. *Anticancer Res.* 16, 1301-1304.
- Lane D.P. and Benchimol S. (1990). p53: oncogene or anti-oncogene? *Gene Dev.* 4, 1-8.
- Levine A.J., Momand J. and Finlay C.A. (1991). The p53 tumour suppressor gene. *Nature* 351, 453-456.
- Lipponen P., Aaltomaa S., Syrjänen S. and Syrjänen K. (1993). p53 protein expression in breast cancer as related to histopathological characteristics and prognosis. *Int. J. Cancer* 55, 51-56.
- Lohmann D., Ruhri C., Schimdt M., Graefl H. and Höfler H. (1993). Accumulation of p53 protein as an indicator for p53 gene mutation in breast cancer. *Diagn. Mol. Pathol.* 2, 36-41.
- MacGrogan G., Bonichon F., de Mascarel I., Trojani M., Durand M., Avril A. and Coindre J.M. (1995). Prognostic value of p53 in breast invasive ductal carcinoma: an immunohistochemical study on 942 cases. *Breast Cancer Res. Treat.* 36, 71-81.
- Marchetti A., Buttitta F., Pellegrini S., Campani D., Diella F., Cecchetti D., Callahan R. and Bistocchi M. (1993). p53 mutations and histological type of invasive breast carcinoma. *Cancer Res.* 53, 4665-4669.
- Marshall C.J. (1991). Tumor suppressor genes. *Cell* 64, 313-326.
- Martinazzi M., Crivelli F., Zampatti C. and Martinazzi S. (1993). Relationship between p53 expression and other prognostic factors in human breast carcinoma. *Am. J. Clin. Pathol.* 100, 213-217.
- Montenarh M. (1992). Biochemical properties of the growth suppressor/oncoprotein p53. *Oncogene* 7, 1673-1780.
- Nigro J.M., Baker S.J., Preisinger A.C., Jessup J.M., Hostetter R., Cleary K., Bigner S.H., Davidson N., Baylin S., Devilee P., Glover T., Collins F.S., Weston A., Modali R., Harris C.C. and Vogelstein B. (1989). Mutations in the p53 gene occur in diverse human tumour types. *Nature* 342, 705-708.
- Ostrowski J.L., Sawan A., Henry L., Wright C., Henry J.A., Hennessy C., Lennard T.J.W., Angus B. and Horne C.H.W. (1991). p53 expression in human breast cancer related to survival and prognostic factors: an immunohistochemical study. *J. Pathol.* 164, 75-81.
- Rosanelli G.P., Steindorfer P., Wirnsberger G.H., Klimpfinger M., Ratschek M., Puerstner P., Auner H. and Berhold A. (1995). Mutant p53 expression and DNA analysis in human breast cancer comparison with conventional clinicopathological parameters. *Anticancer Res.* 15, 581-586.
- Rosen P.P., Lesser M.L., Arroyo C.D., Cranor M., Borgen P. and Norton L. (1995). p53 in node-negative breast carcinoma: an immunohistochemical study of epidemiologic risk factors, histologic features, and prognosis. *J. Clin. Oncol.* 13, 821-830.
- Schmitt F.C., Soares R., Cirnes L. and Seruca R. (1998). p53 in breast carcinomas: Association between presence of mutation and immunohistochemical expression using a semiquantitative approach. *Pathol. Res. Pract.* 194, 815-819.
- Silvestrini R., Benini E., Daidone M.G., Veneroni S., Boracchi P., Cappelletti V., Di Fronzo G. and Veronesi U. (1993). p53 as an independent prognostic marker in lymph node-negative breast cancer patients. *J. Natl. Cancer Inst.* 85, 965-970.
- Silvestrini R., Daidone M.G., Benini E., Faranda A., Tomasic G., Boracchi P., Salvadori B. and Veronesi U. (1996). Validation of p53 accumulation as a predictor of distant metastasis at 10 years of follow-up in 1400 node-negative breast cancers. *Clin. Cancer Res.* 2, 2007-2013.
- Sirvent J.J., Salvadó M.T., Santafé M., Martínez S., Brunet J., Alvaro T. and Palacios J. (1995). p53 in breast cancer. Its relation to histological grade, lymph-node status, hormone receptors, cell-proliferation fraction (Ki-67) and c-erbB-2. Immunohistochemical study of 153 cases. *Histol. Histopathol.* 10, 531-539.
- Sjogren S., Inganas M., Norberg T., Lindgren A., Nordgren H., Holmberg L. and Bergh J. (1996). The p53 gene in breast cancer: prognosis value of complementary DNA sequencing versus immunohistochemistry. *J. Natl. Cancer Inst.* 88, 173-182.
- Sommer S.S., Cunningham J., McGovern R.M., Saitoh S., Schroeder J.J., Wold L.E. and Kovach J.S. (1992). Pattern of p53 gene mutations in breast cancers of women of the midwestern United States. *J. Natl. Cancer Inst.* 84, 246-252.
- Thor A.D., Moore D.H., Edgerton S.M., Kawasaki E.S., Reihnsaus E., Lynch H.T., Marcus J.N., Schwartz L., Chen L.C. and Mayall B.H. (1992). Accumulation of p53 tumor suppressor gene protein: an independent marker of prognosis in breast cancers. *J. Natl. Cancer Inst.* 84, 845-855.
- Varley J.M., Brammar W.J., Lane D.P., Swallow J.E., Dolan C. and Walker R.A. (1991). Loss of chromosome 17p13 sequences and mutations of p53 in human breast carcinomas. *Oncogene* 6, 413-421.
- Weinberg R.A. (1991). Tumor suppressor genes. *Science* 254, 1138-1146.
- World Health Organization (1981). Histological typing of breast tumours. 2nd ed. *International Histological Classification of Tumours*. No. 2. World Health Organization. Geneva.

Accepted July 27, 2000