

Invited Review

The distribution of cholinergic neurons in the human central nervous system

Y. Oda and I. Nakanishi

First Department of Pathology, Faculty of Medicine, Kanazawa University, Japan

Summary. Choline acetyltransferase (ChAT), the enzyme responsible for the biosynthesis of acetylcholine, is presently the most specific marker for identifying cholinergic neurons in the central and peripheral nervous systems. The present article reviews immunohistochemical and in situ hybridization studies on the distribution of neurons expressing ChAT in the human central nervous system. Neurons with both immunoreactivity and in situ hybridization signals of ChAT are observed in the basal forebrain (diagonal band of Broca and nucleus basalis of Meynert), striatum (caudate nucleus, putamen and nucleus accumbens), cerebral cortex, mesopontine tegmental nuclei (pedunclopontine tegmental nucleus, laterodorsal tegmental nucleus and parabrachial nucleus), cranial motor nuclei and spinal motor neurons. The cerebral cortex displays regional and laminar differences in the distribution of neurons with ChAT. The medial septal nucleus and medial habenular nucleus contain immunoreactive neurons for ChAT, which are devoid of ChAT mRNA signals. This is probably because there is a small number of cholinergic neurons with a low level of ChAT gene expression in these nuclei of human. Possible connections and speculated functions of these neurons are briefly summarized.

Key words: Choline acetyltransferase, Central nervous system, Human, Immunohistochemistry, In situ hybridization

Introduction

Neurons that synthesize and release acetylcholine for neurotransmission are referred to as cholinergic neurons. Cholinergic neurons in the mammalian central nervous system are thought to play an important role in fundamental brain functions, such as learning, memory,

arousal, sleep and movement (Butcher and Woolf, 1986; Woolf, 1991). Selective loss of cholinergic neurons in the basal forebrain has been observed in Alzheimer's disease (Perry et al., 1978; Whitehouse et al., 1981). Amyotrophic lateral sclerosis and Huntington's disease are other neurodegenerative disorders in which cholinergic neurons are affected. Choline acetyltransferase (ChAT, acetyl CoA:choline *O*-acetyltransferase, EC 2.3.1.6), the enzyme responsible for the biosynthesis of acetylcholine, is presently the most specific indicator for monitoring the functional state of cholinergic neurons in the central and peripheral nervous systems. This enzyme is also a useful specific marker for identifying cholinergic neurons in the nervous system. During the past 20 years, several polyclonal and monoclonal anti-ChAT antibodies have been developed and applied in anatomical analyses of the central cholinergic organization in mammalian species. More recently, following the successful cDNA cloning for ChAT, an in situ hybridization technique has been induced to detect ChAT mRNA in neurons for identifying authentic cholinergic neurons. The present article reviews immunohistochemical and in situ hybridization studies on the distribution of neurons expressing ChAT in the human central nervous system.

Localization of neuronal cell body with ChAT immunoreactivity and in situ hybridization signals

Based on immunohistochemical studies of monkey and rodent brains, Mesulam (1988) proposed a nomenclature to describe ChAT-immunoreactive neurons which are aggregated in eight major groups: Ch1-Ch8. Ch1 designates the ChAT-containing neurons associated with the medial septal nucleus, Ch2 is associated with the vertical nucleus of the diagonal band of Broca, Ch3 with the horizontal limb nucleus of the diagonal band of Broca, Ch4 with the nucleus basalis of the substantia innominata, Ch5 with the pedunclopontine nucleus of the rostral brain stem, Ch6 with the laterodorsal tegmental nucleus of the rostral brain stem, Ch7 with the medial habenula, and Ch8 is associated with those neurons in the parabrachial nucleus. In addition, the

Offprint requests to: Dr. Yoshio Oda, MD, Associate professor, First Department of Pathology, Faculty of Medicine, Kanazawa University, 13-1 Takara-machi, Kanazawa, Ishikawa 920-8640, Japan, e-mail: yoda@med.kanazawa-u.ac.jp

Human central cholinergic neuron

striate nucleus, cerebral cortex, some cranial nerve nuclei and the spinal cord gray matter also contain ChAT-immunoreactive neurons. This classification is applicable in describing the human central cholinergic system. In human, ChAT-immunoreactive neurons are

detected in the medial septal nucleus (Ch1), nucleus of the diagonal band of Broca (Ch2 and Ch3), the basal nucleus of Meynert (Ch4), the caudate nucleus, the putamen, the nucleus accumbens (the ventral striatum), the pedunclopontine tegmental nucleus (Ch5), the

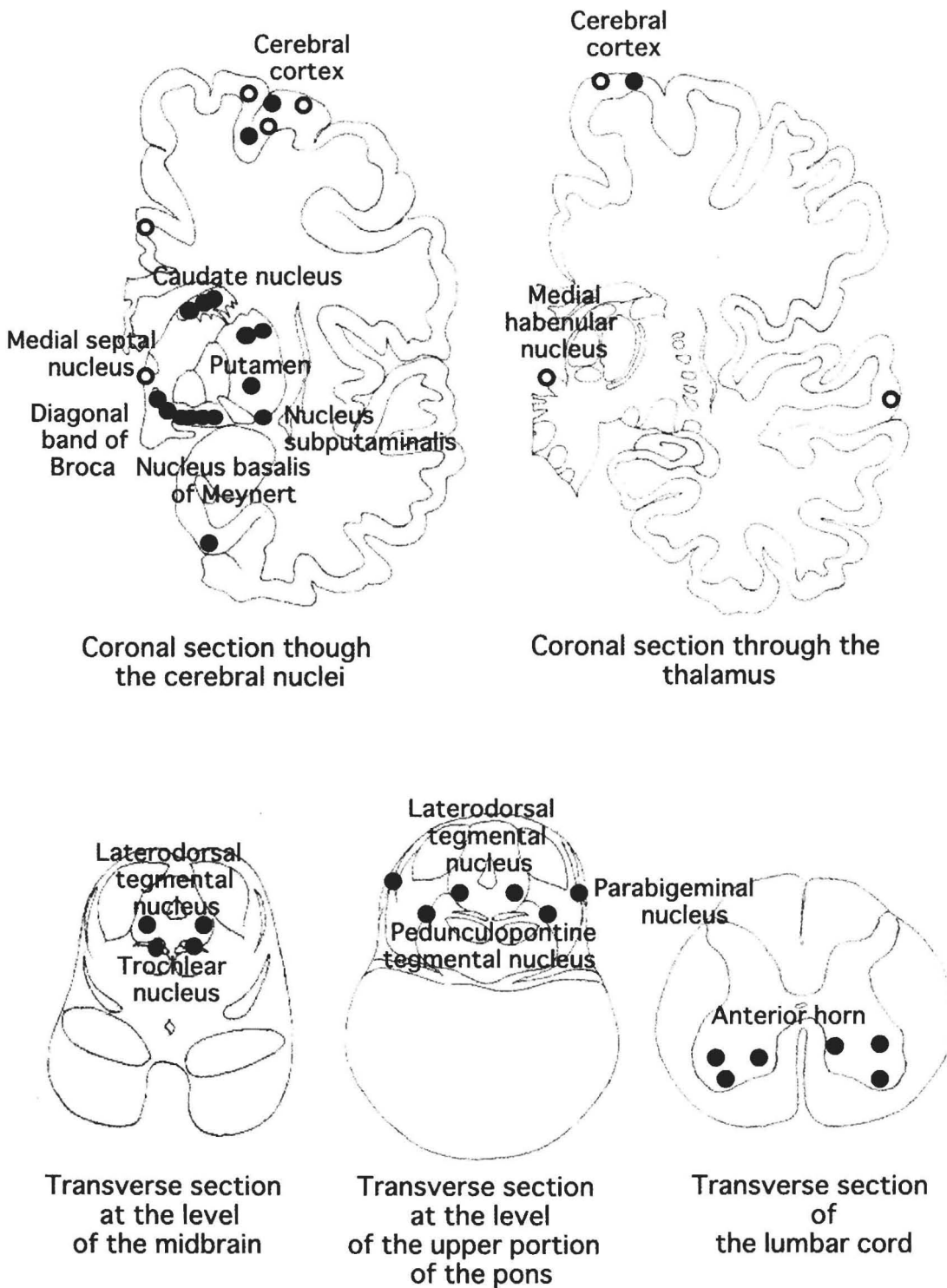


Fig. 1. Schematic representation of the distribution of cholinergic neurons in the human central nervous system. Closed circles indicate neurons with both ChAT immunoreactivity and mRNA; open circles indicate those with ChAT immunoreactivity only.

laterodorsal tegmental nucleus (Ch6), the medial habenular nucleus (Ch7), the parabigeminal nucleus (Ch8), some distinct areas of the cerebral cortex, some cranial nerve nuclei, and the anterior gray horn of the spinal cord. Furthermore, nucleus subputaminalis (Ayala), which has long been disregarded in morphological studies, contains ChAT-immunoreactive neurons (Šimić et al., 1999). Table 1 summarizes the results of immunohistochemical and in situ hybridization studies and Figure 1 shows a schematic representation of the distribution of neurons containing ChAT in the human central nervous system.

I. Magnocellular nuclei of the basal forebrain

Magnocellular nuclei of the basal forebrain are composed of the medial septal nucleus, the nucleus of the diagonal band and the basal nucleus of Meynert. These structures are tightly connected to each other (Ulfing, 1989). In addition, a recent histochemical and immunohistochemical study pointed out that the nucleus subputaminalis is also a component of the magnocellular complex (Šimić et al., 1999).

1. Medial septal nucleus (Ch1)

The medial septal nucleus located in the septum verum forms the antermost portion of the basal magnocellular complex. Large, ovoid neurons with vertical orientation are immunopositive for ChAT. The immunoreactivity of the neurons is relatively weak compared with that of neurons in other magnocellular complex areas such as the nucleus basalis of Meynert. In situ hybridization failed to detect positive signals for ChAT mRNA in the neurons. This is probably because there is a small number of cholinergic neurons with a

low level of ChAT gene expression in this nucleus (Kasashima et al., 1998).

2. Diagonal band of Broca (Ch2 and Ch3)

The diagonal band of Broca is located from the ventromedial portion of the lateral septum (vertical limb of the diagonal band, Ch2) to the ventrorostromedial portion of the subcommissural region (horizontal limb of the diagonal band, Ch3) below Ch4. The boundary between the medial septal nucleus and the vertical limb of the diagonal band (Ch2) is not clearly defined, an area in which neurons are rather sparsely distributed. Sometimes, the two structures are categorized together as Ch1-2. The shape of Ch3 is ill-defined, where neurons are scattered randomly. ChAT-immunoreactive neurons in the diagonal band are large, polygonal (particularly in the vertical) or fusiform (particularly in the horizontal limb). An in situ hybridization study revealed that large neurons in this area contain hybridization signals for ChAT (Kasashima et al., 1998).

3. Nucleus basalis of Meynert (Ch4)

The nucleus basalis of Meynert is a continuous plate of neurons, which occupies the sublenticular region between the sagittal levels of the olfactory tubercle and the lateral geniculate nucleus. Based on a cyto-architectural study of monkey brain (Mesulam et al., 1983), Mesulam and Geula (1988) stated that the human Ch4 complex can also be subdivided into six sectors that occupy its anteromedial (Ch4am), anterolateral (Ch4al), anterointermediate (Ch4ai), intermediodorsal (Ch4id), intermedioventral (Ch4iv) and posterior (Ch4p) regions. Some other researchers used this classification in morphological studies of the human basal forebrain




Fig. 2. Immunohistochemistry (A) and in situ mRNA hybridization (B, dark field) studies of ChAT in the nucleus basalis of Meynert. Most of the large neurons are labeled. x 87.5

Human central cholinergic neuron

Table 1. Regional distribution of neurons with choline acetyltransferase immunoreactivity and mRNA in the human central nervous system

	IMMUNOHISTOCHEMISTRY	IN SITU HYBRIDIZATION
Basal forebrain		
Medial septal nucleus	+	-
Nucleus of diagonal band of Broca	+	+
Nucleus basalis of Meynert	+	+
Nucleus subputaminalis	+	+
Amygdala	-	-
Basal ganglia		
Caudate nucleus	+	+
Putamen	+	+
Globus pallidus	-	-
Thalamus	-	-
Epithalamus		
Medial habenular nucleus	+	-
Lateral habenular nucleus	-	-
Hippocampus	-	-
Entorhinal cortex	+	+
Neocortex		
Brodman's areas		
1, 2, 3 (somatosensory)	-	-
4 (somatomotor)	+	+
6, 8, 9 (premotor)	+	-
17 (first visual)	-	-
18 (secondary visual)	+	-
20, 21	-	-
22 (secondary auditory)	+	-
23, 31 (posterior half of cingulate)	-	-
24 (anterior half of cingulate)	+	+
39, 40	-	-
41, 42 (first auditory)	-	-
46	+	+
Subthalamic nucleus	-	-
Substantia nigra	-	-
Red nucleus	-	-
Mesencephalon		
Pedunculopontine tegmental nucleus	+	+
Laterodorsal tegmental nucleus	+	+
Parabigeminal nucleus	+	+
Pontine nucleus	-	-
Cerebellum	-	-
Cranial nerve nuclei		
Oculomotor nucleus	+	+
Trochlear nucleus	+	+
Spinal cord (anterior horn)	+	+

(Mufson et al., 1989; Lehericy et al., 1993). However, a three-dimensional reconstruction study (Ulfig, 1989; Halliday et al., 1993) revealed that these six subgroups were difficult to clearly distinguish from each other. Halliday et al. (1993) divided the nucleus by the surrounding structures into four subgroups; Ch4a, Ch4ac (corresponding to the nucleus subputaminalis, as described below), Ch4i, and Ch4p regions. Ch4a and Ch4ac are situated between the olfactory tubercle and the posterior edge of the anterior commissure; Ch4i, between the posterior edge of the anterior commissure and the ansa peduncularis; and Ch4p, posterior to the ansa peduncularis. The majority of neurons in Ch4 are

large and polymorphic. Most of the large neurons are ChAT-immunopositive (80-90% according to the calculation by Mesulam et al., 1988) and with RNA signals (Kasashima et al., 1998) (Fig. 2). Their shapes are heterogeneous, ranging from fusiform to multipolar. Almost all neurons with ChAT immunoreactivity also express the nerve growth factor receptor (Mufson et al., 1989).

4. Nucleus subputaminalis

Although the nucleus subputaminalis was first described many years ago by Ayala (1915), the nucleus

Human central cholinergic neuron

is unfamiliar to many scientists, including neuroanatomists. The nucleus subputaminalis is well developed in the human brain and located ventrolaterally to the putamen. This nucleus represents a rostromedial extension of the basal magnocellular complex. Halliday et al. (1993) subgrouped this nucleus as Ch4ac. The current immunohistochemical study (Šimić et al., 1999) demonstrated that 80-90% of the cell bodies contained both ChAT and the vitamin-D-dependent calcium binding protein calbindin-D28k with the remainder of cell bodies showing positivity for nicotinamide adenine dinucleotide phosphate diaphorase.

II. Striatum

The striatum, consisting of the caudate nucleus, the putamen and the nucleus accumbens, is relatively homogenous in terms of cell types. There are three types of neurons: medium-sized spiny neurons (neurons with spiny dendrites); medium-sized aspiny neurons (neurons with aspiny dendrites); and large aspiny neurons. Large multipolar neurons, which correspond to large aspiny neurons, express ChAT (Hirsch et al., 1989; Mesulam et al., 1992; Selden et al., 1994; Holt et al., 1996; Kasashima et al., 1998) (Fig. 3) or nicotinamide adenine dinucleotide phosphate diaphorase (Selden et al., 1994). ChAT-positive large neurons make up 1-2% of the total cell population in the striatum (Holt et al., 1996), and most of them are considered to be interneurons with intrinsic projections. The distribution of cholinergic neurons in the striatum is in a relatively even manner, whereas that of the ChAT-immunopositive neuropils is not uniform (Hirsch et al., 1989; Mesulam et al., 1992; Selden et al., 1994; Holt et al., 1996). Patches of weak ChAT immunoreactivity, called striosomes, are embedded in a strong ChAT-immunoreactive background, called a matrix. The irregular density of cholinergic fibers in the striatum may be related to the

compartmental organization for processing different types of information.

III. Cerebral cortex

The existence of cholinergic neurons in the mammalian cerebral cortex has been a matter of controversy. Early immunohistochemical studies detected no cholinergic neurons in the cerebral cortex (Kimura et al., 1980, 1981; Sofroniew et al., 1982; Armstrong et al., 1983). However, a considerable number of reports have more recently shown ChAT-immunoreactive neurons present in the cerebral cortex of the rat (Houser et al., 1983; Levey et al., 1984; Ichikawa and Hirata, 1986; Eckenstein et al., 1988; Kosaka et al., 1988; Umbriaco et al., 1994), cat (Stichel et al., 1987; Avendaño et al., 1996), fetal monkey (Hendry et al., 1987), and human (Kasashima et al., 1999). In situ hybridization studies demonstrated neurons possessing ChAT mRNA in the rat (Lauterborn et al., 1993) and human (Kasashima et al., 1998, 1999) cerebral cortices. The cholinergic neurons reported in the experimental animals are small fusiform or bipolar neurons, most of which are observed in layers II and III. In human, however, most of the cerebral ChAT-immunoreactive neurons are medium-sized or large pyramidal neurons located predominantly in layers III and V (Fig. 4). The density of such neurons is higher in the motor and secondary sensory areas compared to other cortical areas (Fig. 5). No ChAT-immunoreactive neurons are found in the primary sensory areas. In situ hybridization studies (Kasashima et al., 1998, 1999) also revealed the presence of neurons with ChAT mRNA signals in the human cerebral cortex, though the number of neurons with the hybridization signals is much smaller than that of the immunoreactive neurons in each cortical region and the distribution of neurons demonstrating the ChAT mRNA is more restricted than that of the immuno-




Fig. 3. ChAT immunohistochemistry of the caudate nucleus (**A**) and in situ mRNA hybridization of the putamen (**B**, dark field). Large neurons are positively labeled in both areas. x 250

positive neurons (Kasashima et al., 1999). These results raise the possibility that some ChAT-immunopositive cortical neurons are not authentic cholinergic neurons and contain proteins sharing similar epitopes.

Alternatively, some human cortical cholinergic neurons may contain too low an amount of ChAT mRNA for detection. In addition, ChAT mRNA may be less stable than the protein, thus degrading before postmortem




Fig. 4. Immunohistochemistry (A) and in situ mRNA hybridization (B, dark field) studies of ChAT in the 5th layer of the cerebral motor cortex. A large pyramidal neuron is positively labeled. x 200

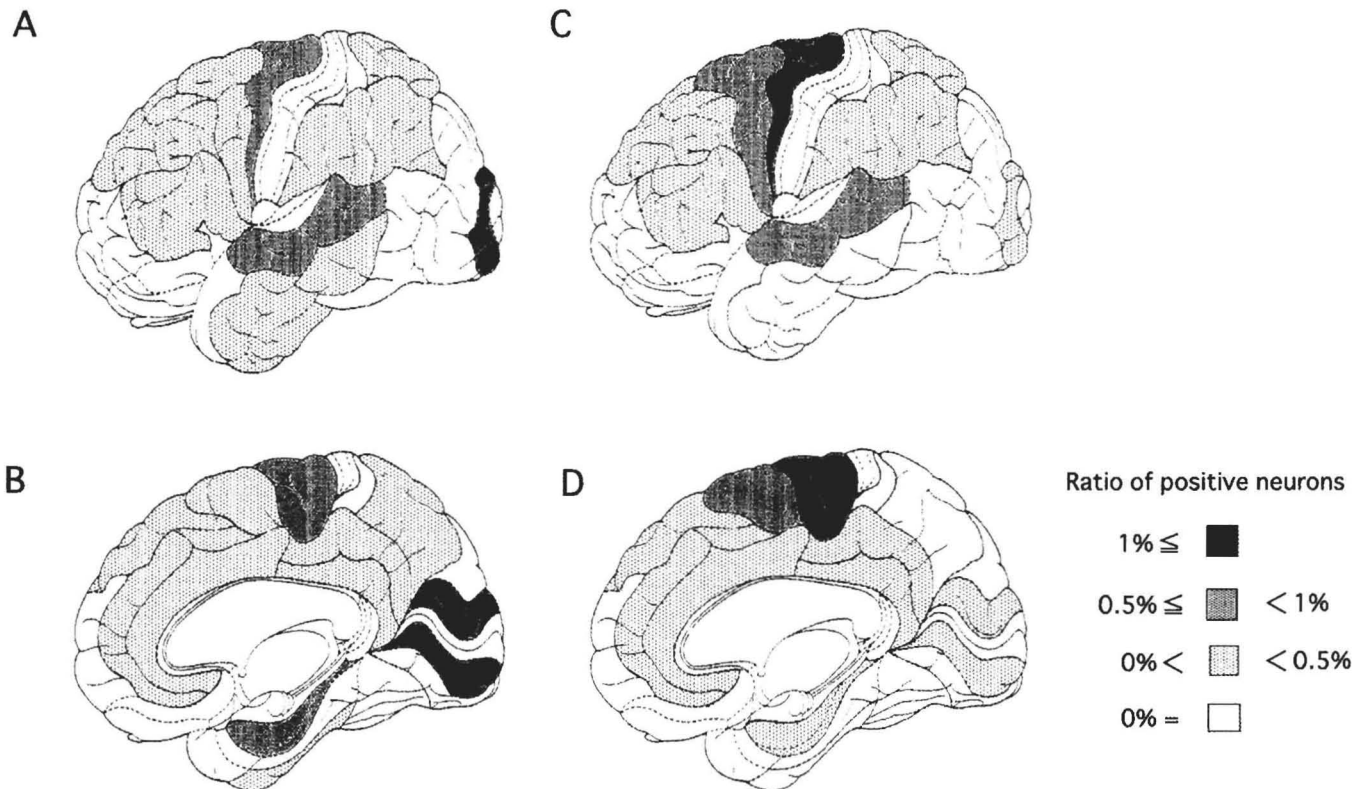


Fig. 5. Schematic representation of the distribution of ChAT-immunoreactive neurons in the 3rd (A and B) and 5th (C and D) layers of the human cerebral cortex.

fixation. The development of monoclonal antibodies for human ChAT applicable to paraffin-embedded tissue sections may help to resolve this issue. Overall, particular areas of the human cerebral cortex contain a certain number of neurons that express ChAT.

IV. Medial habenular nucleus (Ch7)

The medial habenular nucleus, one of the components of the epithalamus, contains small ChAT-immunopositive neurons surrounded by a moderate density of immunoreactive fibers (Heckers et al., 1992). However, an *in situ* hybridization study failed to demonstrate ChAT mRNA in this nucleus (Kasashima et al., 1998).

V. Mesopontine tegmental nuclei

1. Pedunculopontine nucleus (Ch5)

The Ch5 complex that consists of the compact portion (Ch5c) and the diffuse-interstitial portion (Ch5d) (Mesulam et al., 1989; Manaye et al., 1999) is located in the ventromedial portion of the rostral pontine tegmentum (Mizukawa et al., 1986; Mesulam et al., 1989; Manaye et al., 1999). Ch5c is surrounded by the superior cerebellar peduncle, lateral lemniscus and medial lemniscus. More than half of the large neurons are intensely ChAT-immunopositive in Ch5c (Mesulam et al., 1989; Manaye et al., 1999). These neurons are polymorphic in shape (oval or triangular form). ChAT-positive neurons belonging to Ch5d are embedded in the lateral lemniscus, superior cerebellar peduncle, and the

central tegmental tract. They are the same size or slightly smaller than ChAT-immunoreactive neurons of Ch5c. The positive rates show considerable regional variations within the area covered by Ch5d: 25-75% reported by Mesulam et al. (1989) and 16-25% reported by Manaye et al. (1999). This discrepancy probably reflects differences in setting the anatomical boundaries of the Ch5 complex. An *in situ* hybridization study (Kasashima et al., 1998) identified a large number of neurons with ChAT mRNA signals in this area (Fig. 6).

2. Laterodorsal tegmental nucleus (Ch6)

The laterodorsal tegmental nucleus is situated in the central gray matter of the rostral portion of the pontine tegment, between the fourth ventricle and the medial longitudinal fasciculus. Laterally, neurons in this nucleus intermingle with pigmented neurons in the locus ceruleus. Since Ch5d and Ch6 are continuous, these two structures are arbitrarily separated by the dorsal border of the medial longitudinal fasciculus. 80-90% of neurons in this nucleus are ChAT-immunopositive (Mesulam et al., 1989). A majority of neurons in the nucleus contain ChAT mRNA signals, and are sparsely distributed like the neurons of Ch5d.

3. Parabigeminal nucleus (Ch8)

The parabigeminal nucleus is a small oval nucleus situated ventrolaterally to the inferior colliculus and laterally to the lateral lemniscus. Neurons in this nucleus are small. 80-90% of the neurons show moderate ChAT-immunoreactivity (Mesulam et al., 1989), whereas a small number of the neurons are demonstrated to have in

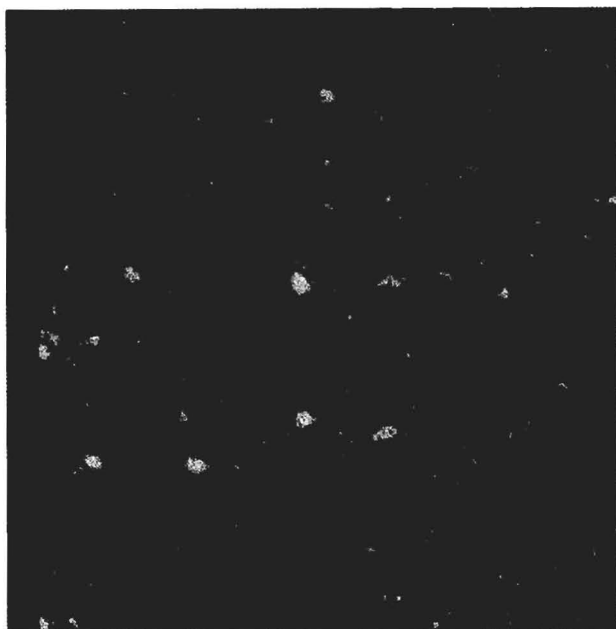


Fig. 6. *In situ* mRNA hybridization for ChAT in the laterodorsal tegmental nucleus (dark field), x 80

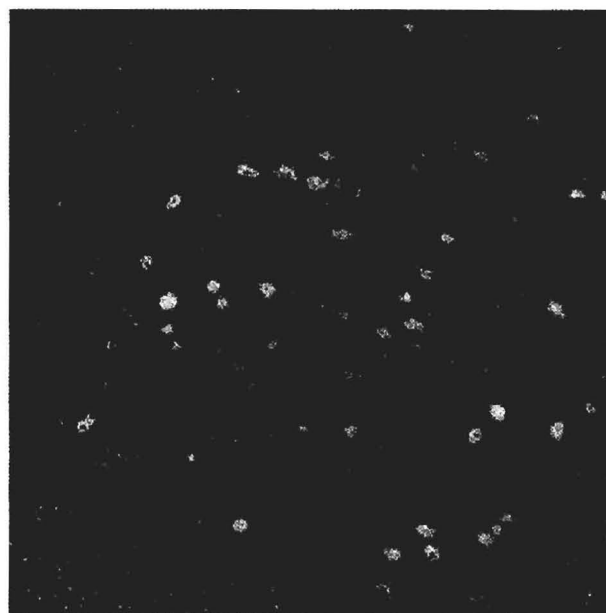


Fig. 7. *In situ* mRNA hybridization for ChAT in the trochlear nucleus (dark field), x 65

Table 2. Possible projections and speculated functions of cholinergic neurons in the human central nervous system

LOCUS OF CHOLINERGIC NEURONS	POSSIBLE MAJOR PROJECTIONS	SPECULATED MAJOR FUNCTIONS
Nucleus basalis of Meynert	Cerebral cortex and amygdala	Learning, memory and arousal
Neostriatum	Unknown (mostly intrinsic)	Motor regulation and recognition
Cerebral cortex	Unknown (intracortical and subcortical)	Movement and modulation of perception
Pedunculopontine tegmental nucleus and laterodorsal tegmental nucleus	Thalamus, neostriatum, basal forebrain, and the other mesopontine areas	Cardiovascular and respiratory regulations, arousal, and memory
Parabigeminal nucleus	Superior colliculus and thalamus	Processing of visual information
Cranial motor nuclei and anterior gray horn of spinal cord	Muscle	Movement

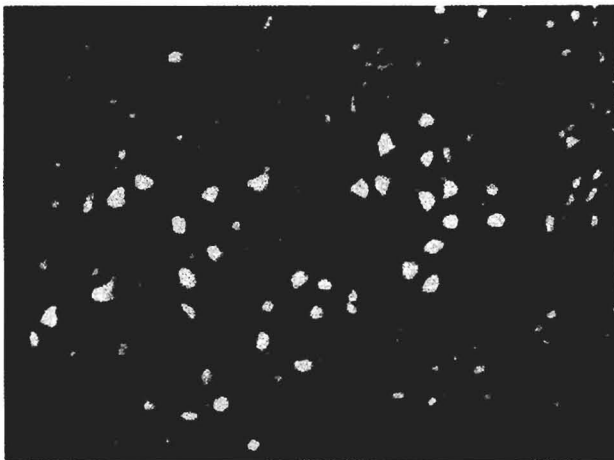


Fig. 8. In situ mRNA hybridization for ChAT in the anterior gray horn of the spinal cord (dark field). Large polygonal and small spindle-shaped neurons contain positive signals. x 40

situ hybridization signals for ChAT mRNA (Kasashima et al., 1998).

VI. Cranial nerve nuclei

All motor nuclei of the cranial nerves including oculomotor, trochlear, trigeminal, abducent, facial, prepositus, vagus, accessory and hypoglossal are ChAT-immunopositive (Mizukawa et al., 1986). Some of them (oculomotor and trochlear nuclei) have been proven to transcribe the ChAT gene (Kasashima et al., 1998) (Fig. 7). In addition, some structures of the vestibular and auditory systems including the nucleus vestibularis lateralis and the nuclei olivaris superioris medialis and lateralis are reported to contain some ChAT-positive cells (Mizukawa et al., 1986)

VII. Spinal cord

Large polygonal (probable α -motor) and small spindle-shaped (probable γ -motor) neurons in the anterior gray horn of the spinal cord express ChAT (Oda et al., 1995; Muroishi et al., unpublished data) (Fig 8). In addition, some neurons in layer III of the posterior gray horn are probably cholinergic (Virgo et al., 1992).

Possible connections and speculated functions of cholinergic neurons in the human central nervous system

Focally distributed cholinergic neurons project fibers to many areas of the central nervous system and exhibit a complicated cholinergic network. Because tracing or destructive experiments cannot be performed in the human brain, the network and functions of human central cholinergic neurons are not completely understood. Based on the results of experimental animal studies and the neuropathology of human disease, possible connections and speculated roles of the central cholinergic neurons have been hypothesized (Woolf, 1991; Mesulam, 1995, 1996) (Table 2). For example, cholinergic neurons in the magnocellular nuclei of the basal forebrain project fibers mainly to the cerebral cortex. The basal forebrain is thought to be the nuclear area for controlling the activity of learning and memory. Cholinergic neurons in the neostriatum are local circuit neurons and play a role in motor regulation. The pontomesencephalic cholinergic neurons (Ch5 and Ch6) project fibers to many areas, particularly to subcortical structures such as the thalamus, the neostriatum, the basal forebrain and the other mesopontine areas, and play an important role in cardiovascular, respiratory and arousal functions. Motor neurons in the cranial nerve nuclei and the spinal cord control voluntary and involuntary movements. The functions of cholinergic neurons in the cerebral cortex remain unclear. However, the restrictive distribution of cholinergic neurons may reflect their functions (Kasashima et al., 1999). For example, a sizable population of Betz cells in the somatomotor area was demonstrated to be cholinergic. Thus, these cells may be responsible for controlling highly skilled voluntary movements. In contrast, cholinergic neurons located in the 3rd layer of the secondary sensory areas may take part in the intracortical sensory network and have some function in the modulation of sensory inputs.

Acknowledgements. The authors' works cited in this review were supported, in part, by grants from the Ministry of Education, Science and Culture of Japan.

References

- Armstrong D.M., Saper C.B., Levey A.I., Wainer B.H. and Terry R.D. (1983). Distribution of cholinergic neurons in rat brain: demonstrated by the immunocytochemical localization of choline acetyltransferase. *J. Comp. Neurol.* 216, 53-68.
- Avendaño C., Umbriaco D., Dykes R.W. and Descarries L. (1996). Acetylcholine innervation of sensory and motor neocortical areas in adult cat: a choline acetyltransferase immunohistochemical study. *J. Chem. Neuroanat.* 11, 113-130.
- Ayala G. (1915). A hitherto undifferentiated nucleus in the forebrain (nucleus subputaminalis). *Brain* 37, 433-438.
- Butcher L.L. and Woolf N.J. (1986). Central cholinergic systems: synopsis of anatomy and overview of physiology and pathology. In: *The biological substrates of Alzheimer's disease*. Scheibel A.B. and Wechsler A.F. (eds). Academic Press. New York. pp 73-86.
- Eckenstein F.P., Baughman R.W. and Quinn J. (1988). An anatomical study of cholinergic innervation in rat cerebral cortex. *Neuroscience* 25, 457-474.
- Halliday G.M., Cullen K., Cairns M.J. (1993). Quantitation and three-dimensional reconstruction of Ch4 nucleus in the human basal forebrain. *Synapse* 15, 1-16.
- Heckers S., Geula C. and Mesulam M.-M. (1992). Cholinergic innervation of the human thalamus: dual origin and differential nuclear distribution. *J. Comp. Neurol.* 325, 68-82.
- Hendry S.H.C., Jones E.G., Killackey H.P. and Chalupa L.M. (1987). Choline acetyltransferase-immunoreactive neurons in fetal monkey cerebral cortex. *Dev. Brain Res.* 37, 313-317.
- Hirsch E.C., Graybiel A.M., Hersh L.B., Duyckaerts C. and Agid Y. (1989). Striosomes and extrastrisomal matrix contain different amounts of immunoreactive choline acetyltransferase in the human striatum. *Neurosci. Lett.* 96, 145-150.
- Holt D.J., Hersh L.B. and Saper C.B. (1996). Cholinergic innervation in the human striatum: a three-compartment model. *Neuroscience* 74, 67-87.
- Houser C.R., Crawford G.D., Barber R.P., Salvaterra P.M. and Vaughn J.E. (1983). Organization and morphological characteristics of cholinergic neurons: an immunocytochemical study with a monoclonal antibody to choline acetyltransferase. *Brain Res.* 266, 97-119.
- Ichikawa T. and Hirata Y. (1986). Organization of choline acetyltransferase-containing structures in the forebrain of the rat. *J. Neurosci.* 6, 281-292.
- Kasashima S., Muroishi Y., Futakuchi H., Nakanishi I. and Oda Y. (1998). In situ hybridization study of the distribution of choline acetyltransferase in the human brain. *Brain Res.* 806, 8-15.
- Kasashima S., Kawashima A., Muroishi Y., Futakuchi H., Nakanishi I. and Oda Y. (1999). Neurons with choline acetyltransferase immunoreactivity and mRNA are present in the human cerebral cortex. *Histochem. Cell Biol.* 111, 197-207.
- Kimura H., McGeer P.L., Peng F. and McGeer E.G. (1980). Choline acetyltransferase-containing neurons in rodent brain demonstrated by immunohistochemistry. *Science* 208, 1057-1059.
- Kimura H., McGeer P.L., Peng J.H. and McGeer E.G. (1981). The central cholinergic system studied by choline acetyltransferase immunohistochemistry in the cat. *J. Comp. Neurol.* 200, 151-201.
- Kosaka T., Tauchi M. and Dahl J.L. (1988). Cholinergic neurons containing GABA-like and/or glutamic acid decarboxylase-like immunoreactivities in various brain regions of the rat. *Exp. Brain Res.* 70, 605-617.
- Lauterborn J.C., Isacson P.J., Montalvo R. and Gail C.M. (1993). In situ hybridization localization of choline acetyltransferase mRNA in adult rat brain and spinal cord. *Mol. Brain Res.* 17, 59-69.
- Lehéricy S., Hirsch E.C., Cervera-Piérot P., Hersh L.B., Bakchine S., Piette F., Duyckaerts C., Hauw J.-J., Javoy-Agid F. and Agid Y. (1993). Heterogeneity and selectivity of the degeneration of cholinergic neurons in the basal forebrain of patients with Alzheimer's disease. *J. Comp. Neurol.* 330, 15-31.
- Levey A.I., Wainer B.H., Rye D.B., Mufson E.J. and Mesulam M.-M. (1984). Choline acetyltransferase-immunoreactive neurons intrinsic to rodent cortex and distinction from acetylcholinesterase-positive neurons. *Neuroscience* 13, 341-353.
- Manaye K.F., Zweig R., Wu D., Hersh L.B., De Lacalle, Saper C.B. and German D.C. (1999). Quantification of cholinergic and select non-cholinergic mesopontine neuronal populations in the human brain. *Neuroscience* 89, 759-770.
- Mesulam M.-M. (1988). Central cholinergic pathways: Neuroanatomy and some behavioral implications. In: *Neurotransmitters and cortical function*. Avoli M., Reader T.A., Dykes R.W. and Gloor P. (eds). Plenum Publishing. New York. pp 237-260.
- Mesulam M.-M. (1995). Cholinergic pathways and the ascending reticular activating system of the human brain. *Ann. NY Acad. Sci.* 757, 169-179.
- Mesulam M.-M. (1996). The system-level organization of cholinergic innervation in the human cerebral cortex and its alteration in Alzheimer's disease. *Prog. Brain Res.* 109, 285-297.
- Mesulam M.M. and Geula C. (1988). Nucleus basalis (Ch4) and cortical cholinergic innervation in the human brain: observation on the distribution of acetylcholinesterase and choline acetyltransferase. *J. Comp. Neurol.* 275, 216-240.
- Mesulam M.-M., Mufson E.J., Levey A.I. and Wainer B.H. (1983). Cholinergic innervation of cortex by the basal forebrain; cytochemistry and cortical connections of the septal area, diagonal band nuclei, nucleus basalis (substantia innominata), and hypothalamus in the rhesus monkey. *J. Comp. Neurol.* 214, 170-197.
- Mesulam M.-M., Geula C., Bothwell M.A. and Hersh L.B. (1989). Human reticular formation: cholinergic neurons of the pedunculopontine and laterodorsal tegmental nuclei and some cytochemical comparisons to forebrain cholinergic neurons. *J. Comp. Neurol.* 281, 611-633.
- Mesulam M.-M., Mash D., Hersh L., Bothwell M. and Geula C. (1992). Cholinergic innervation of the human striatum, globus pallidus, subthalamic nucleus, substantia nigra, and red nucleus. *J. Comp. Neurol.* 323, 252-268.
- Mizukawa K., McGeer P.L., Tago H., Peng J.H., McGeer E.G. and Kimura H. (1986). The cholinergic system of the human hindbrain studies by choline acetyltransferase immunohistochemistry and acetylcholinesterase histochemistry. *Brain Res.* 379, 39-55.
- Mufson E.J., Bothwell M., Hersh L.B., Kordower J.H. (1989). Nerve growth factor receptor immunoreactive profiles in the normal, aged human basal forebrain: colocalization with cholinergic neurons. *J. Comp. Neurol.* 285, 196-217.
- Oda Y., Imai S., Nakanishi I., Ichikawa T. and Deguchi T. (1995). Immunohistochemical study on choline acetyltransferase in the spinal cord of patients with amyotrophic lateral sclerosis. *Pathol. Int.* 45, 933-939.
- Perry E.K., Tomlison B.E., Blessed G., Bergmann K., Gibson P.H. and

Human central cholinergic neuron

- Perry R.H. (1978). Correlation of cholinergic abnormalities with senile plaques and mental test scores in senile dementia. *Br. Med. J.* 25, 1457-1459.
- Selden N., Geula C., Hersh L. and Mesulsm M.-M. (1994). Human striatum: chemoarchitecture of the caudate nucleus, putamen and ventral striatum in health and Alzheimer's disease. *Neuroscience* 60, 621-636.
- Šimić G, Mrzljak L., Fucic A., Winblad B., Lovric H. and Kostovic I. (1999). Nucleus subputaminalis (Ayala): the still disregarded magnocellular component of the basal forebrain may be human specific and connected with the cortical speech area. *Neuroscience* 89, 73-89.
- Sofroniew M.V., Eckenstein F., Thoenen H. and Cuello A.C. (1982). Topography of choline acetyltransferase-containing neurons in the forebrain of the rat. *Neurosci. Lett.* 33, 7-12.
- Stichel C.C., Dolabela de Lima A. and Singer W. (1987). A search for choline acetyltransferase-like immunoreactivity in neurons of cat striate cortex. *Brain Res.* 405, 395-399
- Ulfing N. (1989). Configuration of the magnocellular nuclei in the basal forebrain of the human adult. *Acta Anat.* 134, 100-105.
- Umbriaco D., Watkins K.C., Descarries L., Cozzari C. and Hartman B.K. (1994). Ultrastructural and morphometric features of the acetylcholine innervation in adult rat parietal cortex: an electron microscopic study in serial sections. *J. Comp. Neurol.* 348, 351-373.
- Virgo L., de Belleruche J., Rossi M. and Steiner T.J. (1992). Characterisation of the distribution of choline acetyltransferase messenger RNA in human spinal cord and its depletion in motor neuron disease. *J. Neurol. Sci.* 112, 126-132.
- Whitehouse P.J., Price D.L., Clark A.W., Coyle J.T. and DeLong M.R. (1981). Alzheimer's disease: Evidence for selective loss of cholinergic neurons in the nucleus basalis. *Ann. Neurol.* 10, 122-126.
- Wolf N.J. (1991). Cholinergic systems in mammalian brain and spinal cord. *Prog. Neurobiol.* 37, 475-524.

Accepted January 28, 2000