

## Desmosomes in verrucous carcinoma of the head and neck

Katarina Odar<sup>1</sup>, Nina Zidar<sup>1</sup>, Serena Bonin<sup>2</sup>, Nina Gale<sup>1</sup>, Antonio Cardesa<sup>3</sup> and Giorgio Stanta<sup>2</sup>

<sup>1</sup>Institute of Pathology, Faculty of Medicine, University of Ljubljana, Ljubljana, Slovenia, <sup>2</sup>ACADEM Department, University of Trieste, Trieste, Italy and <sup>3</sup>Department of Pathology, Hospital Clinic, IDIBAPS, University of Barcelona, Barcelona, Spain

**Summary.** Verrucous carcinoma (VC) is a variant of squamous cell carcinoma (SCC), characterised by its inability to metastasize. In contrast, hybrid carcinomas, composed of VC and foci of conventional SCC, harbour a metastatic potential. Correct pathohistological diagnosis is therefore crucial for the choice of treatment. There is mounting evidence that desmosomes are involved in several aspects of carcinogenesis. Previous studies have shown an altered expression of desmosomal components in conventional SCC, which was associated with tumour behaviour, but no data have been found on desmosomes in VC.

We therefore analysed the expression of desmosomal components in biopsy samples of 21 cases of VC and 5 cases of hybrid carcinoma of the head and neck in comparison to 23 cases of conventional SCC and 47 samples of normal squamous epithelium of similar localisation, using immunohistochemistry and real-time reverse-transcription polymerase chain reaction.

We found that the expression patterns of desmosomal components in VC were fairly similar to those in normal epithelium but differed significantly from those in conventional SCC. Immunohistochemical reactions against desmosomal components disclosed the foci of SCC in hybrid carcinomas.

In conclusion, we believe that expression patterns of desmosomal components in VC are consistent with its less aggressive behaviour. Differential expression of desmosomal components between VC and SCC makes some desmosomal components potentially useful in the diagnostics of VC, especially for the detection of hybrid carcinoma.

**Key words:** Verrucous carcinoma, Squamous cell carcinoma, Hybrid carcinoma, Desmosomes

### Introduction

Verrucous carcinoma (VC) is a rare variant of squamous cell carcinoma (SCC) of uncertain pathogenesis (Ackerman, 1948). It is most commonly found on the mucous membranes of the head and neck but it can also arise at other locations, e.g., the skin, anogenital region, urinary bladder and oesophagus. Microscopically, VC consists of filiform projections lined by thick, well differentiated keratinized squamous epithelium, composed of one to a few layers of basal cells and multiplied, voluminous spinous cells lacking cytologic criteria of malignancy. It invades the subjacent stroma with a well defined, pushing margin (Gale and Zidar, 2006). Hybrid carcinomas have also been described composed of VC and foci of conventional SCC (Medina et al., 1984; Orvidas et al., 1998).

VC is characterised by slow growth and, although it is locally invasive, it rarely, if ever, metastasizes. Due to the less aggressive behaviour and a significantly better prognosis than conventional SCC, VC can be treated more conservatively (Strojan et al., 2006; Walvekar et al., 2009). Hybrid carcinomas, in contrast, must be treated as comparably staged SCC, since the foci of conventional SCC in VC indicate a potential for metastasis (Orvidas et al., 1998; Strojan et al., 2006). It is therefore clinically important for a proper pathohistological diagnosis to be made. However, this is often difficult, particularly in small biopsy specimens (Orvidas et al., 1998; Depprich et al., 2006). A molecular marker would be useful to distinguish between VC and conventional SCC.

Desmosomes are subcellular structures that importantly determine the characteristics of squamous epithelium. As intercellular junctions, they function in cell to cell adhesion and the maintenance of tissue integrity. In addition, their components participate in processes such as cell proliferation, differentiation and tissue morphogenesis, probably via cell signalling. The

molecular composition of desmosomes depends on the type and differentiation status of the tissue. In general, desmosomes are composed of at least three separate protein families. Desmosomal cadherins, desmogleins (Dsg1-4) and desmocollins (Dsc1-3) interact extracellularly with the desmosomal cadherins of neighbouring cells. They are intracellularly linked to intermediate filaments of the cytoskeleton via armadillo-family members, plakophilins (Pkp1-3) and plakoglobin (Pg), and a member of the plakin family, desmoplakin (Dp) (Getsios et al., 2004; Garrod and Chidgey, 2008).

There is mounting evidence that desmosomes and their constituents are involved in several aspects of carcinogenesis (Chidgey and Dawson, 2007) and the use of desmosomal proteins as markers for identification and classification of tumours has been proposed (Moll et al., 1986). Previous studies have shown an altered expression of desmosomal components in conventional SCC, which was associated with tumour differentiation and behaviour (Shinohara et al., 1998) but no data have been found on the expression patterns of desmosomal components in VC.

The purpose of our study was to analyse the expression of desmosomal components on the protein and mRNA level in VC, SCC and normal squamous epithelium of the head and neck, using immunohistochemistry and real-time reverse-transcription polymerase chain reaction (real-time RT-PCR).

## Materials and methods

### Patients and tissue samples

Our study included formalin fixed, paraffin embedded tumour samples of 21 patients with VC (14 males, 7 females, aged 31 to 83 years, mean 62.9±15.1), 5 patients with hybrid carcinoma (3 males, 2 females, aged 49 to 79 years, mean 63.6±14.1) and 23 patients with well and moderately differentiated conventional SCC of the head and neck (18 males, 5 females, aged 45 to 79 years, mean 60.3±10.8). The tumours were located in the oral cavity and oropharynx (12 VC, 4 hybrid carcinomas and 9 SCC), in the hypopharynx and larynx (5 VC, 1 hybrid carcinoma and 12 SCC), on the skin (3

VC and 2 SCC) and in the nasal cavity (1 VC).

Thirty-five samples of morphologically normal mucosa and skin adjacent to tumours, where available, were used as internal control for immunohistochemistry. As a control group for real-time RT-PCR, 12 samples of normal epithelium from the oral cavity, pharynx, larynx, and the skin, obtained from patients with non-tumourous conditions were used (8 males, 4 females, aged 20 to 40 years).

Tissue samples were collected during surgery as part of the routine diagnostic procedure. After fixation in 10% buffered formalin for 24 h, samples were embedded in paraffin. Haematoxylin and eosin stains were made from paraffin blocks for routine pathological diagnostics. For the purposes of our study, representative paraffin blocks were collected from the archives of the Institute of Pathology, Faculty of Medicine, University of Ljubljana.

### Immunohistochemistry

Immunohistochemistry was performed on 20 cases of VC, 5 cases of hybrid carcinoma and 20 cases of SCC. Additional sections were cut at 4-5 µm from paraffin blocks and deparaffinization was carried out according to standard procedures. Antigen retrieval methods were optimised for each primary antibody. Briefly, we used microwave oven heating for 10 min at 750 W in sodium citrate buffer (Dako TRS, pH 6.0, Dako, Glostrup, Denmark) or for 25 min at 800 W in ethylenediaminetetraacetic acid (EDTA) buffer (1 mM, pH 9). In some cases, additional enzymatic pretreatment with proteinase 2 (0.1 unit/ml of enzyme activity, Ventana, Tucson, Arizona, USA) was performed.

Immunohistochemical staining was carried out in an automatic immunostainer (Benchmark, Ventana), using commercially available primary antibodies against desmosomal proteins, purchased from Atlas Antibodies (Stockholm, Sweden), Invitrogen (Camarillo, California, USA), Novocastra Laboratories (Newcastle, UK) or Progen Biotechnik (Heidelberg, Germany). An overview of the source and clone, dilution of the primary antibodies and antigen retrieval methods used in this study is given in Table 1. Dsg4 was not analysed

**Table 1.** Overview of source and clone, dilution of the primary antibodies, and antigen retrieval methods used for immunohistochemistry.

Antigen	Source	Clone	Dilution	Antigen retrieval
Desmoglein 1	Progen Biotechnik	Dsg1-P124	ready to use	EDTA
Desmoglein 2	Progen Biotechnik	10G11	1:10	citrate buffer + proteinase 2
Desmoglein 3	Invitrogen	5G11	1:70	sodium citrate buffer
Desmocollin 1	Progen Biotechnik	DSC1-U100	1:10	citrate buffer + proteinase 2
Desmocollin 2	Progen Biotechnik	polyclonal	1:150	citrate buffer + proteinase 2
Desmocollin 3	Progen Biotechnik	Dsc3-U114	1:10	EDTA
Plakophilin 1	Progen Biotechnik	5C2	ready to use	citrate buffer + proteinase 2
Plakophilin 2	Atlas Antibodies	polyclonal	1:70	EDTA
Plakophilin 3	Invitrogen	23E3/4	1:70	EDTA
Desmoplakin 1/2	Progen Biotechnik	DP-2.15+DP-2.17+DP-2.20	ready to use	citrate buffer + proteinase 2
Plakoglobin	Novocastra	11B6	1:20	EDTA

## Desmosomes in verrucous carcinoma

because we were unable to find a sensitive and specific commercially available antibody.

After incubation with primary antibodies, sections were treated with biotinylated secondary antibodies (Ventana) and incubated with peroxidase-conjugated streptavidin. Immunoreactivity was visualised with 3,3'-diaminobenzidine. Sections were counterstained with haematoxylin.

The expression of desmosomal proteins was assessed semiquantitatively using an image analysis system (Cell and Tissue Analysis, Leica, Wetzlar, Germany). The following scoring system was adopted. The staining intensity in tumours was scored in comparison to the layer of normal squamous epithelium with the strongest staining intensity (0=negative, 1=barely visible, 2=weaker, 3=comparable, 4=stronger than normal epithelium). To take into account the extent of positive reaction and variation in the staining intensity within samples, weighted means were calculated when necessary, in order to obtain the final expression scores from 0 to 4, which were used in statistical analyses.

### Reverse transcription and polymerase chain reaction

Real-time RT-PCR analysis was performed on tissue samples of 11 cases of VC, 10 cases of conventional SCC and 12 samples of normal squamous epithelium. Since Pkp2 protein was not detected in the investigated samples by immunohistochemistry, and Dsc1 protein was only found in the skin, Pkp2 and Dsc1 were excluded from real-time RT-PCR analysis.

Total RNA was extracted from formalin fixed paraffin embedded tissue samples after microdissection, as described elsewhere (Stanta et al., 1998). For each sample, 3.2 µg of total RNA were DNase digested as previously described (Nardon et al., 2009). DNase treated RNA was reversely transcribed into cDNA using Moloney murine leukemia virus (M-MLV) reverse transcriptase (Invitrogen, Life Technologies, Carlsbad, CA, USA) and 3.35 nmoles of random hexamers per reaction, as reported elsewhere (Nardon et al., 2009).

The expression levels of the target genes were

measured by means of real-time quantitative PCR using SYBR Green detection chemistry. In order to select a proper reference gene for normalisation, expression levels of 4 candidate housekeeping genes ( $\beta$ -actin, glyceraldehyde-3-phosphate dehydrogenase (GAPDH),  $\beta$ 2-microglobulin and hypoxanthine phosphoribosyl transferase) were analysed in 12 samples of tumours and normal epithelia, selected from our study. On the basis of analysis with the geNorm algorithm (<http://medgen.ugent.be/~jvdesomp/genorm>), GAPDH was selected as the most suitable reference gene for our system. All PCR reactions were performed at least in duplicate. Reactions were prepared using RealMasterMix SYBR ROX 2.5x (5Prime, Hamburg, Germany) according to the manufacturer's instructions. The final volume of the reaction was 22 µl for each replica. Primers (used in 300 nM final concentrations) and starting amounts of cDNA for each reaction are reported in Table 2. Primers were manufactured by Eurofins MWG Operon (Ebersberg, Germany). Amplification was performed on a Mastercycler ep realplex (Eppendorf, Hamburg, Germany). Cycling conditions were as follows: initial template denaturation at 95°C for 90 s and 40 cycles of denaturation for 30 s at 95°C, annealing at the appropriate annealing temperature (Table 2) for 30 s, extension at 72°C for 30 s and fluorescence detection for 20 s. For some primer pairs, the fluorescence detection temperature was set closer to that of the amplicon's melting temperature (Table 2), in order to avoid the detection of non-specific products. The uniqueness of amplification products was confirmed by melting curve analysis and by 8% polyacrylamide gel electrophoresis.

Relative quantification was performed according to the efficiency-calibrated model (Pfaffl, 2001). We used the average threshold cycle (Ct) value of the replicas as the input Ct value for each sample. When the difference in Ct between the replicas was higher than 0.5 cycles, the amplification was repeated. We used the median Ct value of all normal tissue samples as the calibrator. Relative expression ratios of target genes (R) were calculated with the following equation:

**Table 2.** Target-specific primers and conditions used for real-time polymerase chain reaction.

Target gene	Primer sequence 5'-3'	Product size (bp)	Ta (°C)	Tf (°C)	E	cDNA (ng)
Desmoglein 1	f GGCATTGGACTCCTCATCAT - r AGGAGCACCTCCACAATCAC	84	56	72	1.92	15
Desmoglein 2	f ATTTTGGCCTTTCTGCTCCT - r TATGGGGTAAAGCCTTTGG	87	58	80	1.94	25
Desmoglein 3	f TGGGGAAGTCCGTA CTTTGA - r CTCCATCTTTGTCTGCACCA	89	55	72	2.00	15
Plakophilin 1	f CCTTCCTCCTCCAGCTTCT - r GGGCACAGACCAGGAAGTTA	76	57.5	78	1.91	25
Plakophilin 3	f CGAACCCCTGCAGAGACTCA - r GGGTCTGAAGCCATGAGGTA	80	57.5	82	1.98	15
Desmoplakin	f GAATGTTTGGGGTGGATGAG - r ATGTGCTGCTCCACTGAGG	86	56	83	1.98	25
Desmocollin 2	f CGTCCTGTAGATCGTGAGCA - r GGCAGTGGAAAGTTCTGGAGT	89	57	76	1.94	50
Desmocollin 3	f AATGGGCAATCCTTGCAATA - r GTTGACACAAAACCTCCACA	85	58	76	1.81	25
Plakoglobin	f CTCACCAAAGTCTCAACGA - r CCTTCTTCGACAGCTGGTTC	79	56	81	1.92	25
GAPDH	f CCCTCAACGACCACTTTGTCA - r GGTCACCACCCTGTTGCT	75	61.2	80	2.00	45

f; forward primer. r; reverse primer. Ta; annealing temperature. Tf; temperature for fluorescence detection. E; amplification efficiency expressed as time of product increase per cycle. cDNA; starting amount of cDNA per replica. GAPDH; glyceraldehyde-3-phosphate dehydrogenase

$R = [E_{\text{target}}]^{\Delta C_{\text{t target}}} / [E_{\text{reference}}]^{\Delta C_{\text{t reference}}}$ ,  
 where E = amplification efficiency expressed as the time of product increase per cycle for the target or reference gene;  $\Delta C_{\text{t}} = C_{\text{t}}$  of a calibrator -  $C_{\text{t}}$  of a sample for the target or reference gene.

### Statistical analysis

Statistical analysis was performed with SPSS 17.0 for Windows (SPSS Inc., Chicago, Illinois, USA) and Stata SE v. 9.0 (Stata Corporation, Texas, USA) software. The Kruskal-Wallis test with the multi-comparison test and the Mann-Whitney test were used to analyse the differences between groups.

## Results

### Immunohistochemistry

All the investigated proteins except Pkp2 and Dsc1 were detected in all cases of normal squamous epithelium and VC, and were variably present in SCC. Pkp2 was present in the intercalated disks of the heart (unpublished observation), which served as a positive control. Dsc1 was only present in the normal epidermis and SCC of the skin.

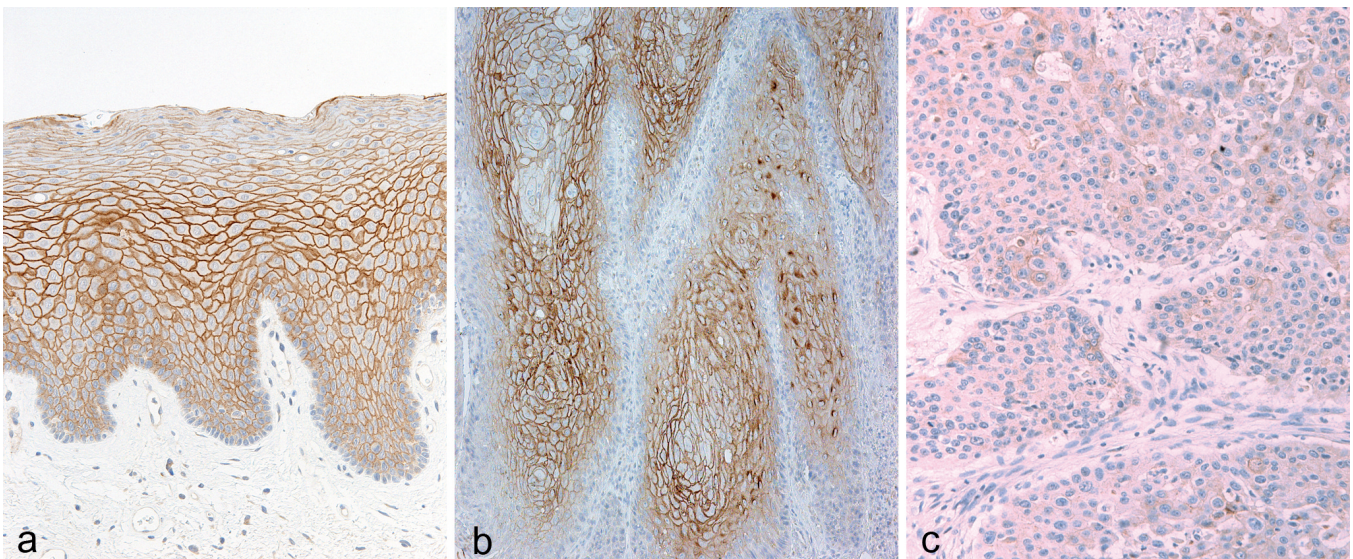
In VC, the expression patterns of desmosomal proteins were generally similar to those in normal squamous epithelium. There were 3 basic expression patterns: predominantly basal/parabasal expression (Dsg2), predominantly suprabasal expression (Dsg1, Pkp1) (Fig. 1a,b), and both basal and suprabasal expression, with or without a changing staining intensity

towards the surface (Dsg3, Dsc2, Dsc3, Pkp3, Pg, Dp) (Fig. 2a,b). There was an increased staining intensity against Pg in 5 cases of VC. No differences were observed between VC of the mucosa and VC of the skin.

In conventional SCC, the expression of desmosomal proteins was markedly altered in comparison to normal epithelium and VC. There was a reduction in staining against Dsg1 (Fig. 1c), Dsc2, Pkp1, Pg and Dp, and an increase in staining against Dsg2. Staining against Pkp3 was mostly reduced but increased staining was found in 3 cases. Staining against Dsg3 was reduced in SCC of the mucosa (Fig. 2c) but increased in SCC of the skin. Dsc1 was only observed in SCC of the skin, with reduced staining in comparison to the normal skin.

**Table 3.** Immunohistochemical expression of desmosomal proteins in verrucous carcinoma and conventional squamous cell carcinoma of the head and neck as determined with semiquantitative immunohistochemistry.

	Verrucous carcinoma (mean expression score ± standard deviation)	Squamous cell carcinoma (mean expression score ± standard deviation)	Mann- Whitney test
Desmoglein 1	2.59±0.24	1.17±0.96	p<0.001
Desmoglein 2	0.26±0.07	2.06±0.99	p<0.001
Desmoglein 3	2.51±0.31	1.88±0.69	p=0.002
Desmocollin 2	2.49±0.29	1.19±0.70	p<0.001
Desmocollin 3	2.05±0.45	1.92±0.52	p=0.538
Plakophilin 1	2.64±0.27	1.31±0.90	p<0.001
Plakophilin 3	1.76±0.70	1.74±0.85	p=0.707
Plakoglobin	3.07±0.40	2.37±0.28	p<0.001
Desmoplakin	2.95±0.06	2.33±0.40	p<0.001



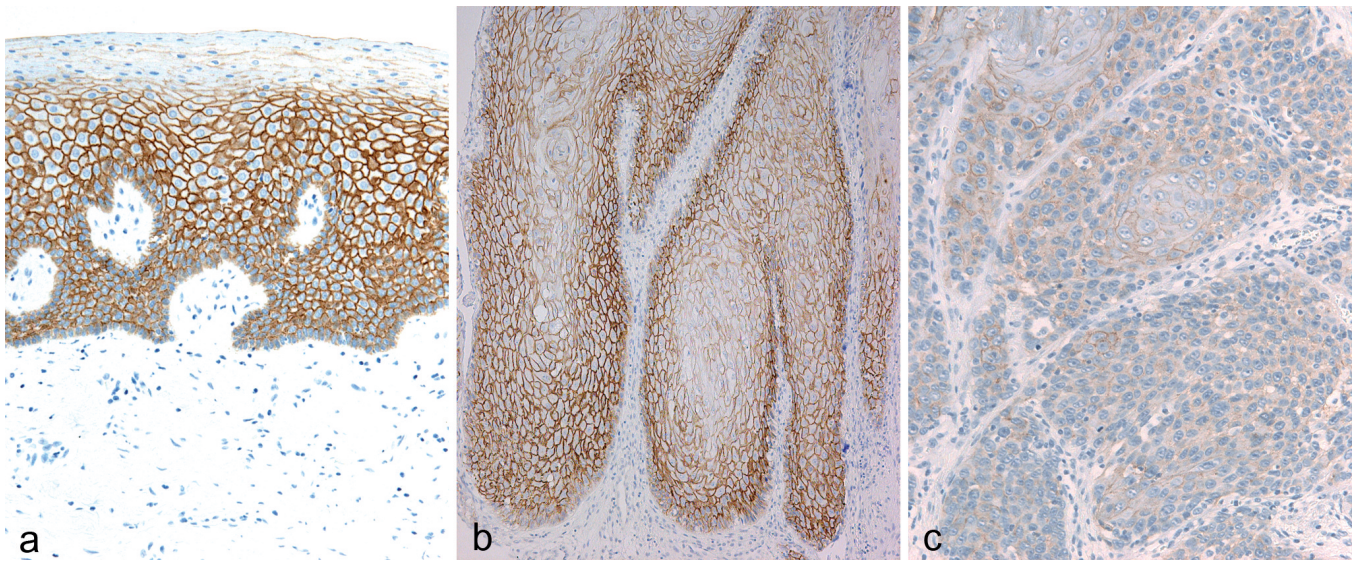
**Fig. 1.** Immunohistochemistry for desmoglein 1: similar distribution in normal squamous epithelium (a) and in verrucous carcinoma (b), with a predominant membranous pattern, and focal perinuclear staining in verrucous carcinoma (b). A reduced intensity of staining in conventional squamous cell carcinoma (c). Orig. magnification x 10

### Desmosomes in verrucous carcinoma

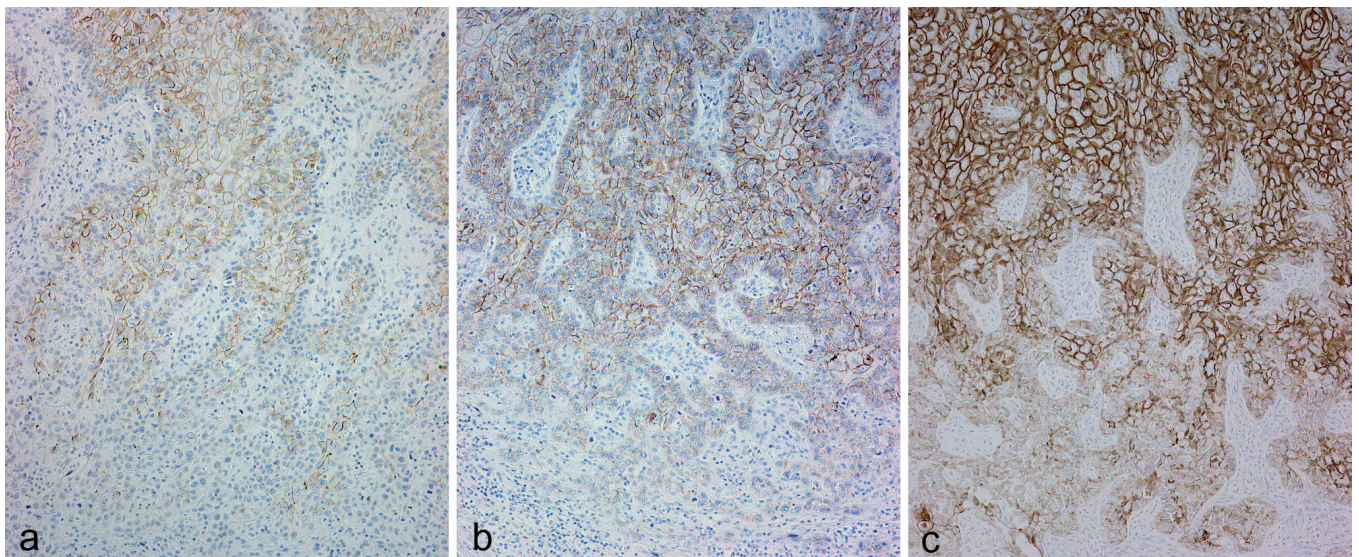
Statistical analysis (Table 3) showed a significantly lower expression of Dsg1, Dsg3, Dsc2, Pkp1, Pg and Dp, and a significantly higher expression of Dsg2 in SCC compared to VC (Mann-Whitney test,  $p < 0.05$ ). There were no significant differences between VC and SCC in the expression of Dsc3 and Pkp3. Because of their limited expression, Pkp2 and Dsc1 were excluded from the statistical analysis.

Positive immunohistochemical reactions mostly

exhibited a membranous pattern but occasionally there was also some additional diffuse cytoplasmic and/or perinuclear/nuclear staining. In addition to nuclear reaction against Pg in parakeratotic cells, perinuclear/nuclear reactions in other cell layers were occasionally observed for Dsg1, Dsg3, Dsc2, Dsc3, Pkp3 and Pg. They were mostly focal and inconspicuous in normal epithelium and SCC but perinuclear/nuclear reactions were more frequently observed in VC for Pg (12 cases)



**Fig. 2.** Immunohistochemistry for desmoglein 3: similar distribution in normal squamous epithelium (a) and in verrucous carcinoma (b), with a membranous pattern. A reduced intensity of staining in conventional squamous cell carcinoma (c). Orig. magnification x 10



**Fig. 3.** Immunohistochemistry for plakophilin 1 (a), desmoglein 3 (b) and desmoplakin (c) in hybrid carcinoma: the intensity of staining is decreasing at the bottom, where verrucous carcinoma is changing to conventional squamous cell carcinoma. Orig. magnification x 10

and Dsc2 (11 cases). Moreover, the perinuclear reaction against Dsc2 was almost diffuse in 5 cases of VC.

In hybrid carcinomas, reactions against desmosomal proteins disclosed the foci of conventional SCC. Staining against Dsg1, Dsg3, Dsc2, Dsc3, Pkp1, Pkp3, Pg and Dp was reduced (Fig. 3a-c) and staining against Dsg2 was increased in foci of SCC, in comparison to VC.

#### Real-time RT-PCR

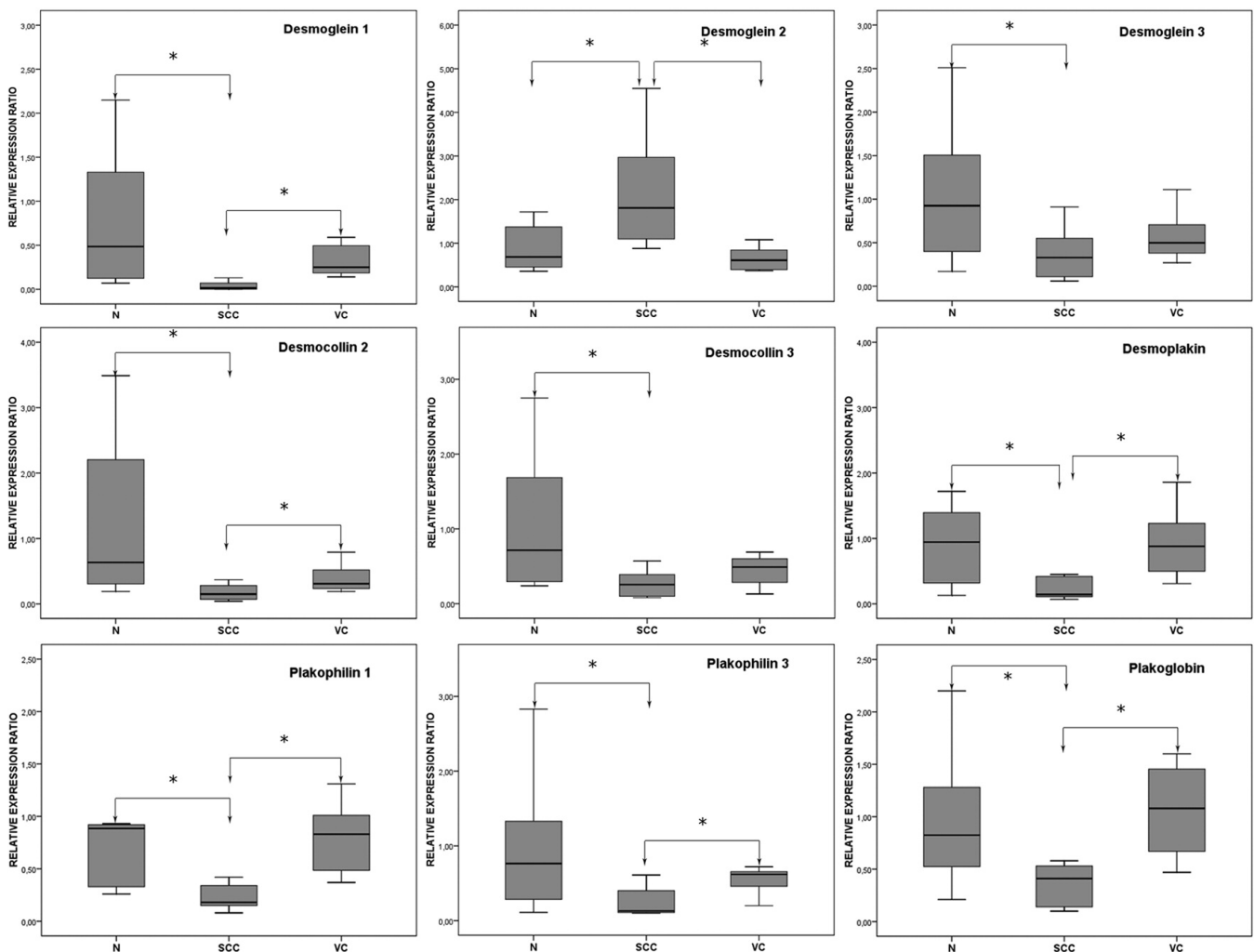
The results of the real-time RT-PCR are presented in Fig. 4. On average, levels of Dsg2 mRNA were lower in normal epithelium and VC than in SCC, and levels of other investigated transcripts were higher in normal epithelium and VC than in SCC.

The Kruskal-Wallis test showed significant differences ( $p < 0.05$ ) between the groups in the relative

expression ratios of all the investigated transcripts. With the multicomparison test (adjusted value for significance;  $p = 0.0083$ ) we found no significant differences between normal epithelium and VC. Normal epithelium and SCC differed significantly in the expression ratios of all the investigated transcripts. VC and SCC differed significantly in the expression ratios of Dsg1, Dsg2, Pg, Dp, Pkp1 and Pkp3. Differences between VC and SCC in the expression ratio of Dsc2 were only significant ( $p = 0.013$ ) with the Mann-Whitney test, and no significant differences were found for Dsg3 and Dsc3.

#### Discussion

We analysed the expression of desmosomal components in VC of the head and neck in comparison to conventional SCC and normal squamous epithelium



**Fig. 4.** Expression of desmosomal components in normal squamous epithelium, verrucous carcinoma and squamous cell carcinoma on the mRNA level. N: normal squamous epithelium. VC: verrucous carcinoma. SCC: squamous cell carcinoma. \*: statistically significant differences.

## *Desmosomes in verrucous carcinoma*

and found that the expression patterns of desmosomal components in VC were fairly similar to those in normal epithelium but differed significantly from those in conventional SCC.

In normal squamous epithelium and VC, we found a similar complex isoform-specific distribution of desmosomal proteins as previously reported in normal epithelium (Kurzen et al., 2003; Getsios et al., 2004; Donetti et al., 2005; Mahoney et al., 2006). However, to the best of our knowledge, expression patterns of desmosomal components in VC have not been described. In VC, we observed predominantly basal/parabasal expression of Dsg2, predominantly suprabasal expression of Dsg1 and Pkp1, whereas Dsc2, Dsg3, Dsc3, Pkp3, Pg and Dp were expressed in both basal and suprabasal cell layers, with or without a changing staining intensity towards the surface. VC did not express Pkp2 and Dsc1 proteins.

On the other hand, the expression of desmosomal components was altered in conventional SCC, and our results are similar to previous reports (Shinohara et al., 1998; Kurzen et al., 2003; Schwarz et al., 2006; Wang et al., 2007; Wong et al., 2008; Brennan and Mahoney, 2009; Papagerakis et al., 2009). In comparison to VC and/or normal epithelium, there was a significantly lower expression of Dsg1, Dsg3, Dsc2, Dsc3, Pkp1, Pkp3, Pg and Dp in SCC, either on protein or mRNA levels or both, whereas the levels of Dsg2 protein and mRNA were significantly higher in SCC.

It has been proposed that alterations of desmosomal components contribute to the progression of tumours, including SCC, by influencing their invasive, metastatic and proliferative potential, due to reduced cell adhesion and/or changes in cell signalisation (Shinohara et al., 1998; Kurzen et al., 2003; Chidgey and Dawson, 2007; Wang et al., 2007; Wong et al., 2008; Brennan and Mahoney, 2009; Papagerakis et al., 2009). The fairly "normal" expression patterns of desmosomal components in VC, which differed significantly from conventional SCC, are thus consistent with the less aggressive behaviour of VC and its inability to metastasize. This is further supported by previous studies describing molecular features of VC such as the expression of matrix metalloproteinases, basement membrane proteins (Impola et al., 2004; Arduino et al., 2010), proteins associated with cellular turnover (Drachenberg et al., 1997; Anderson et al., 1999) and adhesion molecule CD44v9 (Ogawa et al., 2004) in VC.

Some of the previously reported molecular features of VC have been proposed as potential molecular markers for the diagnostics of this tumour (Drachenberg et al., 1997; Anderson et al., 1999; Poh et al., 2001) but their usefulness appears to be limited (Drachenberg et al., 1997). The search for additional markers to facilitate diagnostics of VC and hybrid carcinoma is therefore still one of the primary goals in this field of research. Our finding of differential expression of desmosomal components between VC and conventional SCC might be diagnostically useful. Most importantly, immunohistochemical reactions against desmosomal

proteins quite clearly labelled the foci of conventional SCC in hybrid carcinomas. Of the investigated desmosomal proteins, Pkp1, Dsg2, Dsg3, and Dp are in our opinion the most reliable immunohisto-chemical markers for detecting hybrid carcinoma.

The similar distribution of desmosomal components between normal squamous epithelium and VC indicates that desmosomes probably do not play a crucial role in the pathogenesis of VC. Although we observed slight differences between normal epithelium and some cases of VC, additional studies are needed to elucidate the significance of these differences. The most prominent differences were upregulation and perinuclear localisation of Pg, and perinuclear localisation of Dsc2. Data on the role of Pg in tumorigenesis are contradictory. While some authors suggest that Pg has a tumour suppressive role (Papagerakis et al., 2004; Dusek et al., 2007), others argue for an oncogenic role. The latter has been demonstrated on human squamous carcinoma cell lines, in which Pg ensured cell to cell adhesion at lower levels, while it also caused unregulated cell proliferation and inhibited apoptosis at high levels (Hakimelahi et al., 2000). Hypothetically, the observed overexpression and perinuclear localisation of Pg might, on the one hand, be associated with unregulated growth of VC, while on the other hand sufficient amounts of Pg enable cell to cell adhesion and prevent infiltrative growth and metastases. The explanation of perinuclear localization of Dsc2 in VC is less clear. Similarly as described for Pg and Pkp (Getsios et al., 2004), it might be associated with functions other than cell adhesion. It might also reflect other biological events, such as the formation or internalisation of desmosomes (Burdett and Sullivan, 2002; Windoffer et al., 2002).

### *Conclusion*

The expression patterns of desmosomal components in VC were similar to those in normal squamous epithelium but differed significantly from those in conventional SCC. These findings are consistent with the less aggressive behaviour of VC. Differential expression of desmosomal components between VC and SCC makes some of the desmosomal components potentially useful in the diagnostics of VC, especially for the detection of hybrid carcinoma.

---

*Acknowledgements.* We thank Daniel Velkavrh and Emanuela Boštjančič for their excellent technical assistance.

---

### **References**

- Ackerman L.V. (1948). Verrucous carcinoma of the oral cavity. *Surgery* 23, 670-678.
- Anderson M., Muro-Cacho C., Cordero J., Livingston S. and Muñoz-Antonia T. (1999). Transforming growth factor  $\beta$  receptors in verrucous and squamous cell carcinoma. *Arch. Otolaryngol. Head Neck Surg.* 125, 849-854.

*Desmosomes in verrucous carcinoma*

- Arduino P.G., Carrozzo M., Pagano M., Broccoletti R., Scully C. and Gandolfo S. (2010). Immunohistochemical expression of basement membrane proteins of verrucous carcinoma of the oral mucosa. *Clin. Oral Invest.* 14, 297-302.
- Brennan D. and Mahoney M.G. (2009). Increased expression of Dsg2 in malignant skin carcinomas: A tissue-microarray based study. *Cell. Adh. Migr.* 3, 148-154.
- Burdett I.D. and Sullivan K.H. (2002). Desmosome assembly in MDCK cells: transport of precursors to the cell surface occurs by two phases of vesicular traffic and involves major changes in centrosome and Golgi location during a Ca<sup>2+</sup> shift. *Exp. Cell. Res.* 276, 296-309.
- Chidgey M. and Dawson C. (2007). Desmosomes: a role in cancer? *Br. J. Cancer* 96, 1783-1787.
- Depprich R.A., Handschel J.G., Fritzmeier C.U., Engers R. and Kuebler N. (2006). Hybrid verrucous carcinoma of the oral cavity: A challenge for the clinician and the pathologist. *Oral Oncol. EXTRA.* 42, 85-90.
- Donetti E., Bedoni M., Boschini E., Dellavia C., Barajon I. and Gagliano N. (2005). Desmocollin 1 and desmoglein 1 expression in human epidermis and keratinizing oral mucosa: a comparative immunohistochemical and molecular study. *Arch. Dermatol. Res.* 297, 31-38.
- Drachenberg C.B., Blanchaert R., Ioffe O.B., Ord R.A. and Papadimitrou J.C. (1997). Comparative study of invasive squamous cell carcinoma and verrucous carcinoma of the oral cavity: expression of bcl-2, p53, and Her-2/neu, and indexes of cell turnover. *Cancer. Detect. Prev.* 21, 483-489.
- Dusek R.L., Gotsel L.M., Chen F., Strohecker A.M., Getsios S., Harmon R., Müller E.J., Caldeleri R., Cryns V.L. and Green K.J. (2007). Plakoglobin deficiency protects keratinocytes from apoptosis. *J. Invest. Dermatol.* 127, 792-801.
- Gale N. and Zidar N. (2006). Benign and potentially malignant lesions of the squamous epithelium and squamous cell carcinoma. In: *Pathology of the head and neck*. Cardesa A. and Slootweg P.J. (eds). Springer-Verlag. Berlin. pp 1-29.
- Garrod D. and Chidgey M. (2008). Desmosome structure, composition and function. *Biochim. Biophys. Acta* 1778, 572-587.
- Getsios S., Huen A.C. and Green K.J. (2004). Working out the strength and flexibility of desmosomes. *Nat. Rev. Mol. Cell. Biol.* 5, 271-281.
- Hakimelahi S., Parker H.R., Gilchrist A.J., Barry M., Li Z., Bleackley R.C. and Pasdar M. (2000). Plakoglobin regulates the expression of the anti-apoptotic protein BCL-2. *J. Biol. Chem.* 275, 10905-10911.
- Impola U., Uitto V.J., Hietanen J., Hakkinen L., Zhang L., Larjava H., Isaka K. and Saarialho-Kere U. (2004). Differential expression of matrilysin-I (MMP-7), 92 kD gelatinase (MMP-9), and matalloelastase (MMP-12) in oral verrucous and squamous cell cancer. *J. Pathol.* 202, 14-22.
- Kurzen H., Munzing I. and Hartschuh W. (2003). Expression of desmosomal proteins in squamous cell carcinomas of the skin. *J. Cutan. Pathol.* 30, 621-630.
- Mahoney M.G., Hu Y., Brennan D., Bazzi H., Christiano A.M. and Wahl J.K. III. (2006). Delineation of diversified desmoglein distribution in stratified squamous epithelia: implications in diseases. *Exp. Dermatol.* 15, 101-109.
- Medina J.E., Dichtel W. and Luna M.A. (1984). Verrucous-squamous carcinomas of the oral cavity. A clinicopathologic study of 104 cases. *Arch. Otolaryngol.* 110, 437-440.
- Moll R., Cowin P., Kapprell H.P. and Franke W.W. (1986). Desmosomal proteins: new markers for identification and classification of tumors. *Lab. Invest.* 54, 4-25.
- Nardon E., Donada M., Bonin S., Dotti I. and Stanta G. (2009). Higher random oligo concentration improves reverse transcription yield of cDNA from biptic tissues and quantitative RT-PCR reliability. *Exp. Mol. Pathol.* 87, 146-151.
- Ogawa A., Fukuta Y., Nakajima T., Kanno S.M., Obara A., Nakamura K., Mizuki H., Takeda Y. and Satoh M. (2004). Treatment results of oral verrucous carcinoma and its biological behaviour. *Oral Oncol.* 40, 793-797.
- Orvidas L.J., Olsen K.D., Lewis J.E. and Suman V.J. (1998). Verrucous carcinoma of the larynx: a review of 53 patients. *Head Neck* 20, 197-203.
- Papagerakis S., Shabana A.H., Depondt J., Pibouin L., Bliin-Wakkach C. and Berdal A. (2004). Altered plakoglobin expression at mRNA and protein levels correlates with clinical outcome in patients with oropharynx squamous carcinomas. *Hum. Pathol.* 35, 75-85.
- Papagerakis S., Shabana A.H., Pollock B.H., Papagerakis P., Depondt J. and Berdal A. (2009). Altered desmoplakin expression at transcriptional and protein levels provides prognostic information in human oropharyngeal cancer. *Hum. Pathol.* 40, 1320-1329.
- Pfaffl M.W. (2001). A new mathematical model for relative quantification in real-time RT-PCR. *Nucleic Acids Res.* 29, e45.
- Poh C.F., Zhang L., Lam W.L., Zhang X., An D., Chau C., Priddy R., Epstein J. and Rosin M.P. (2001). A high frequency of allelic loss in oral verrucous lesions may explain malignant risk. *Lab. Invest.* 81, 629-634.
- Schwarz J., Ayim A., Schmidt A., Jager S., Koch S., Baumann R., Dünne A.A. and Moll R. (2006). Differential expression of desmosomal plakophilins in various types of carcinomas: correlation with cell type and differentiation. *Hum. Pathol.* 37, 613-622.
- Shinohara M., Hiraki A., Ikebe T., Nakamura S., Kurahara S., Shirasuna K. and Garrod D.R. (1998). Immunohistochemical study of desmosomes in oral squamous cell carcinoma: correlation with cytokeratin and E-cadherin staining, and with tumour behaviour. *J. Pathol.* 184, 369-381.
- Stanta G., Bonin S. and Perin R. (1998). RNA extraction from formalin-fixed and paraffin-embedded tissues. *Methods. Mol. Biol.* 86, 23-26.
- Strojan P., Šmid L., Čizmarevič B., Žagar T. and Auersperg M. (2006). Verrucous carcinoma of the larynx: determining the best treatment option. *Eur. J. Surg. Oncol.* 32, 984-988.
- Walvekar R.R., Chaukar D.A., Deshpande M.S., Pai P.S., Chaturvedi P., Kakade A., Kane S.V. and D'Cruz A.K. (2009). Verrucous carcinoma of the oral cavity: A clinical and pathological study of 101 cases. *Oral Oncol.* 45, 47-51.
- Wang L., Liu T., Wang Y., Cao L., Nishioka M., Aguirre R.L., Ishikawa A., Geng L. and Okada N. (2007). Altered expression of desmocollin 3, desmoglein 3, and beta-catenin in oral squamous cell carcinoma: correlation with lymph node metastasis and cell proliferation. *Virchows Arch.* 451, 959-966.
- Windoffer R., Borchert-Stuhltrager M. and Leube R.E. (2002). Desmosomes: interconnected calcium-dependent structures of remarkable stability with significant integral membrane protein turnover. *J. Cell. Sci.* 115, 1717-1732.
- Wong M.P., Cheang M., Yorlida E., Coldman A., Gilks C.B., Huntsman D. and Berean K. (2008). Loss of desmoglein 1 expression associated with worse prognosis in head and neck squamous cell carcinoma patients. *Pathology* 40, 611-616.