

Prospective evaluation of the learning curve of confocal laser endomicroscopy in patients with IBD

Helmut Neumann¹, Michael Vieth², Raja Atreya¹, Markus F. Neurath¹ and Jonas Mudter¹

¹Department of Medicine I, University of Erlangen-Nuremberg, Germany and ²Institute of Pathology, Klinikum Bayreuth, Germany

Summary. Background and aims: Confocal laser endomicroscopy (CLE) represents a novel endoscopic imaging technique which enables the *in vivo* microscopic imaging within the mucosal layer of the gut at subcellular resolution. Currently, there are no data available on the learning curve of CLE, which was therefore the aim of our study. Methods: Twenty-six consecutive patients with inflammatory bowel disease (IBD) underwent total colonoscopy and were examined by fluorescein-aided CLE. Image data were collected and reviewed by two endoscopists in a blinded fashion. CLE images were compared to endoscopical and histological findings. Prospectively, the following performance parameters were documented: total duration of the procedure, confocal imaging time, time to receive a confocal image in focus, number of confocal images, number of confocal images in focus, CLE diagnosis and final histopathological diagnosis. Results: A significance decrease of CLE duration was detected between the first 8 and the subsequent cases ($p=0.002$). Confocal imaging time and the time to receive an image in focus declined significantly over time ($p=0.0001$), while number of images in focus significantly increased ($p=0.0007$). Agreement between CLE and histopathology improved over time with kappa values of 0.81 after twenty-six cases. Conclusions: There was a significant improvement in CLE performance over time, including decreased confocal imaging time, successful CLE diagnosis and decline in procedural time. These parameters improved significantly after the initial three cases. Therefore, CLE represents an easy to learn and apply novel diagnostic method for *in vivo* analysis and diagnosis in IBD.

Key words: Confocal laser endomicroscopy, CLE, Inflammatory bowel disease, Learning curve, Diagnosis, pCLE, iCLE, In vivo, Imaging, Ulcerative colitis, Crohn disease.

Introduction

Inflammatory bowel disease (IBD) with its two main subforms, ulcerative colitis (UC) and Crohn's disease (CD), is characterized by a chronic course in which acute episodes and episodes of remission may alternate (Neurath and Finotto, 2009). Traditionally, endoscopic diagnosis of IBD is based on the investigation of mucosal surface and surrounding blood vessels in low magnification white light. To overcome these limitations structure enhancement procedures, like chromoendoscopy and magnification endoscopy were developed, providing a more detailed view of the mucosa (Neumann et al., 2011). More recently, imaging systems based on optical (narrow band imaging, NBI) or digital filter technologies (Fujinon intelligent chromoendoscopy, FICE) were introduced, allowing more and new mucosal details to be seen (Neumann et al., 2009, 2011). Nevertheless, despite ongoing development of new endoscopic techniques, the examination of microscopic mucosal abnormalities for final diagnosis remained a field of histopathology. Very recently, confocal laser endomicroscopy (CLE) was introduced, enabling *in vivo* microscopic imaging within the mucosal layer of the gut at a subcellular resolution (ASGE Technology Committee et al., 2009; Meining, 2009). CLE allowed 1000 fold magnification of living tissue during ongoing endoscopy. Previous studies have shown the utility of CLE for the classification of inflammation activity and for the differentiation of dysplasia-associated lesional mass and adenoma-like mass in UC (Hurlstone et al., 2007; Li et al., 2010). Furthermore, Kiesslich et al. reported that CLE can

predict whether UC lesions, which were identified by chromoendoscopy, should undergo biopsy examination, thereby increasing the diagnostic yield and reducing the need for biopsy examinations (Kiesslich et al., 2007; Kiesslich and Neurath, 2008).

While it is known that CLE is time consuming, the learning curve for this procedure has not yet been described. Therefore, the purpose of this study was to determine the learning curve of CLE in patients with IBD.

Material and methods

Study design

Consecutive patients with known or suspected IBD (ulcerative colitis or Crohn's disease) underwent total ileocolonoscopy. All patients signed informed consent to participate in this study. The study was approved by the local ethical committee and government authorities. Subjects were enrolled if they met the following inclusion criteria: more than 18 years of age, ability to provide written informed consent, known or clinically suspected IBD. Patients with one or more of the following criteria were excluded from the study: inability to provide written informed consent, severe uncontrolled coagulopathy, impaired renal or liver function, pregnancy or breast feeding, active gastrointestinal bleeding, known allergy to fluorescein and residing in institutions (e.g. prison). All patients underwent a clinical interview, physical examination and routine laboratory investigation. Patients' demographics are shown in table 1.

Endoscopy and CLE

Patients underwent sedation with midazolam and pethidine or monitored anaesthesia care with propofol. After reaching the terminal ileum, CLE was performed from circumscribed lesions and endoscopically normal mucosa. All procedures were performed using the confocal endomicroscopy probe ColoFlex^{UHD} (Cellvizio, Mauna Kea Technologies, Paris, France). 5 ml 10% Fluorescein was administered intravenously to enable CLE. Confocal images were digitally saved and afterwards biopsies were taken. Image data were collected and reviewed by two endoscopists in a blinded fashion to endoscopical and histological appearance. Normal mucosa and pathological lesions were evaluated according to modified Miami classification for pCLE (Wallace and Fockens, 2009). All procedures were performed by one experienced endoscopist under supervision of a gastropathologist. The endoscopist attended a workshop on CLE prior to the study. Prospectively, the following performance parameters were documented: total duration of the procedure, confocal imaging time, time to receive a confocal image in focus, confocal image numbers, number of confocal images in focus, CLE diagnosis and final histo-

pathological diagnosis.

Diagnosis agreement between endomicroscopy and histopathology was based on endomicroscopy findings which include lymphatic dilation, hyperaemia and visualization of different cellular structures like crypts, intestinal vili, goblet cells, inflammatory and lymphoid cells.

Statistical analysis

Data were entered into Excel worksheets (MicrosoftTM Corporation, Redmond, Wash., USA). The mean and standard deviation (\pm SD) procedural time for CLE was evaluated for the first 3 cases, the next 3 cases, the next 4 cases and subsequent cases. Mann-Whitney U test with a two-sided level of significance was used to compare the mean procedural time and the extent of examination before and after the initial 10 cases. A P-value of <0.05 was considered as statistically significant. Agreement between confocal diagnosis and histopathology was calculated using Kappa values. Spearman correlation test was used to examine the time dependent learning curve.

Results

A total of twenty-six procedures were examined from October 2009 until December 2009. 64.54 percent of patients were female. Mean age was 45.5 years (range

Table 1. Demographic data and group assignment.

Group	n	Males/ Females	Mean age (range)
UC	14	10/ 4	47.0 years (20-54 years)
CD	12	0/12	26.5 years (24-68 years)

UC: ulcerative colitis; CD: Crohn's disease; n: cases.

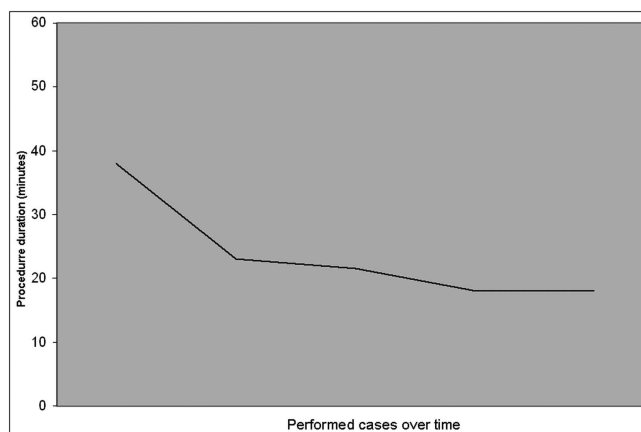


Fig. 1. Relation between mean procedure duration and performed cases. There was a significant difference between the first 8 and the subsequent cases ($p=0.002$).

Learning curve of endomicroscopy in IBD

20-68 years). The adjacent table summarizes demographic data of included patients. The mean comparative time of normal ileo-colonoscopy was 7 minutes for cecal intubation and 17 minutes for withdrawal time. The mean (\pm SD) duration for CLE was 19.0 ± 6.71 minutes. The mean (\pm SD) duration for the first 3 cases was 38.0 ± 10.97 minutes, 23.0 ± 3.21 minutes for the next 3 cases, 21.5 ± 8.74 minutes for the next 4 cases and 18.0 ± 3.69 minutes for the remaining 16 cases (Fig. 1). A significant decrease of CLE duration was detected between the first 8 and the subsequent cases ($p=0.002$).

The mean (\pm SD) duration to receive an image in focus was 6.0 ± 27.01 seconds. The mean (\pm SD) duration for the first 3 cases was 81.0 ± 0.58 seconds, 18.0 ± 35.51

seconds for the next 3 cases, 12.5 ± 9.26 seconds for the next 4 cases and 5.5 ± 2.04 seconds for the remaining 12 cases (Fig. 2). A highly significant difference was found between the first 4 and the subsequent cases ($p=0.0001$).

The mean (\pm SD) number of confocal images in focus was $67.78\%\pm0.19$. The mean (\pm SD) number of confocal images in focus for the first 3 cases was $7.15\%\pm0.21$, $63.00\%\pm0.11$ for the next 3 cases, 69.70 ± 0.03 for the next 4 cases and $69.16\%\pm0.09$ for the remaining 12 cases (Fig. 3). Overall, a significant difference was determined between the first 3 and the subsequent cases ($p=0.0007$).

The Spearman correlation showed a significant negative correlation between the procedure duration and

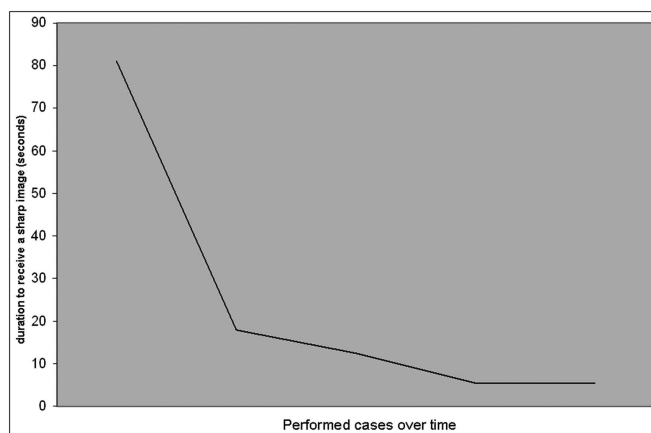


Fig. 2. Relation between mean duration to receive a confocal image in focus compared with number of performed cases. A significant difference was observed between the first 4 and the subsequent cases ($p=0.0001$).

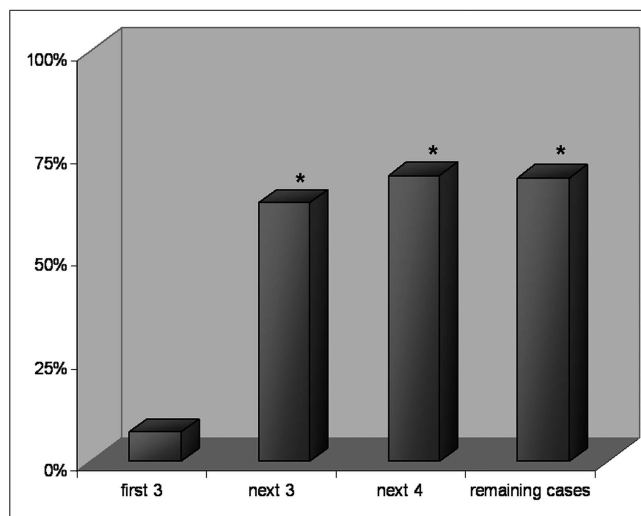


Fig. 3. Mean number of confocal images in focus of the first 3 and subsequent cases. Significant differences were marked with an asterisk.

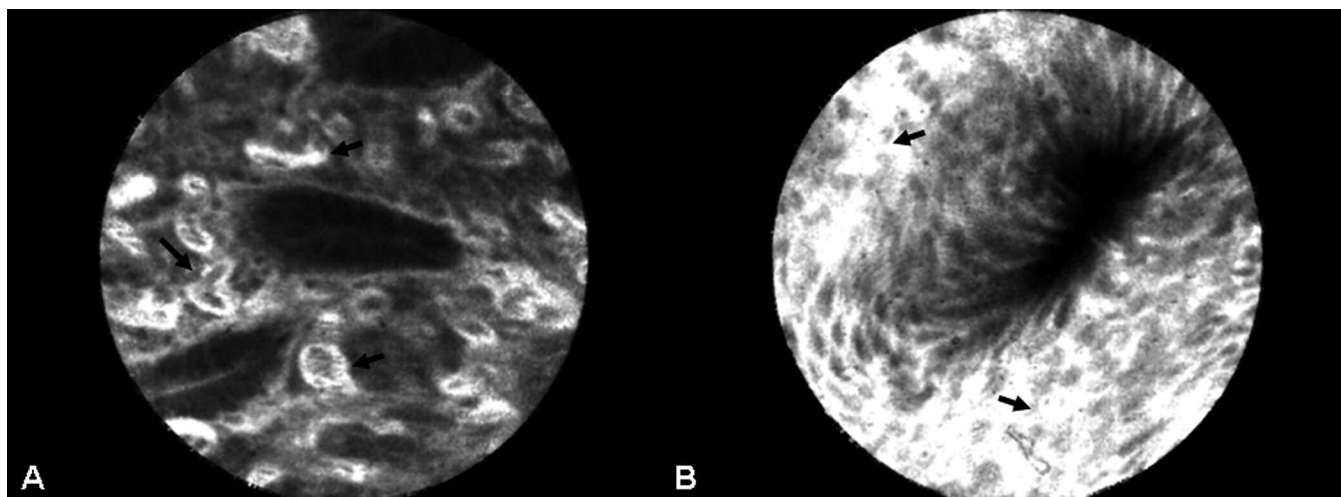


Fig. 4. Changes of vessel architecture in patient with ulcerative colitis. Note the increased number of blood vessels that are all dilated (A) and Fluorescein leaks (B) demonstrated by extravasation of Fluorescein (arrows) around fragile vessels.

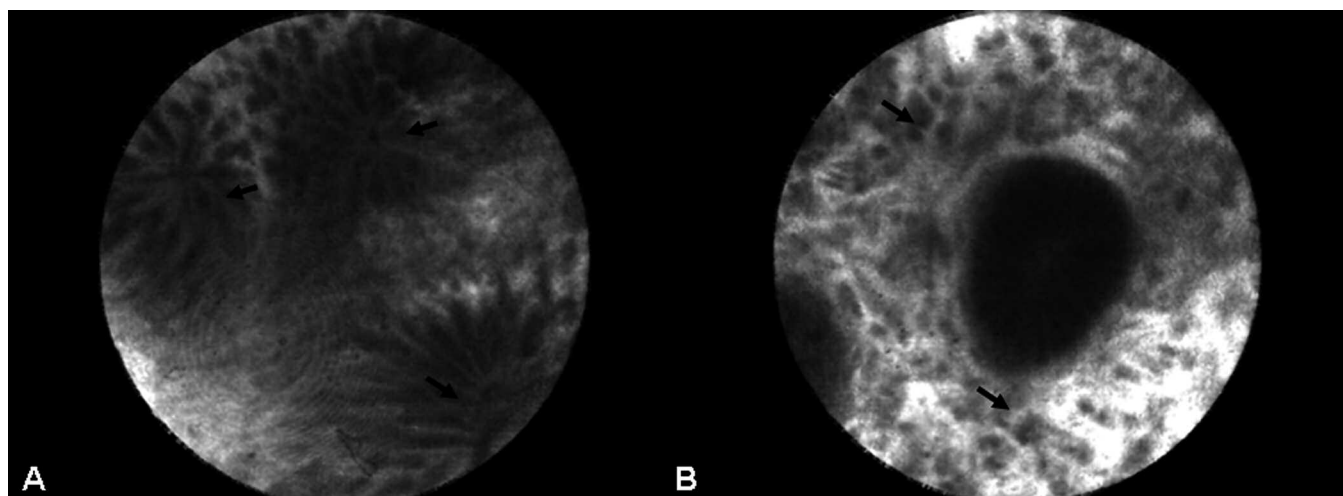


Fig. 5. In patient with ulcerative colitis and mild inflammatory activity confocal laser endomicroscopy showed distortion of crypt architecture (**A**, arrows) and increased cellular inflammatory infiltrate (**B**, arrows) around dilated blood vessels with some Fluorescein leakage.

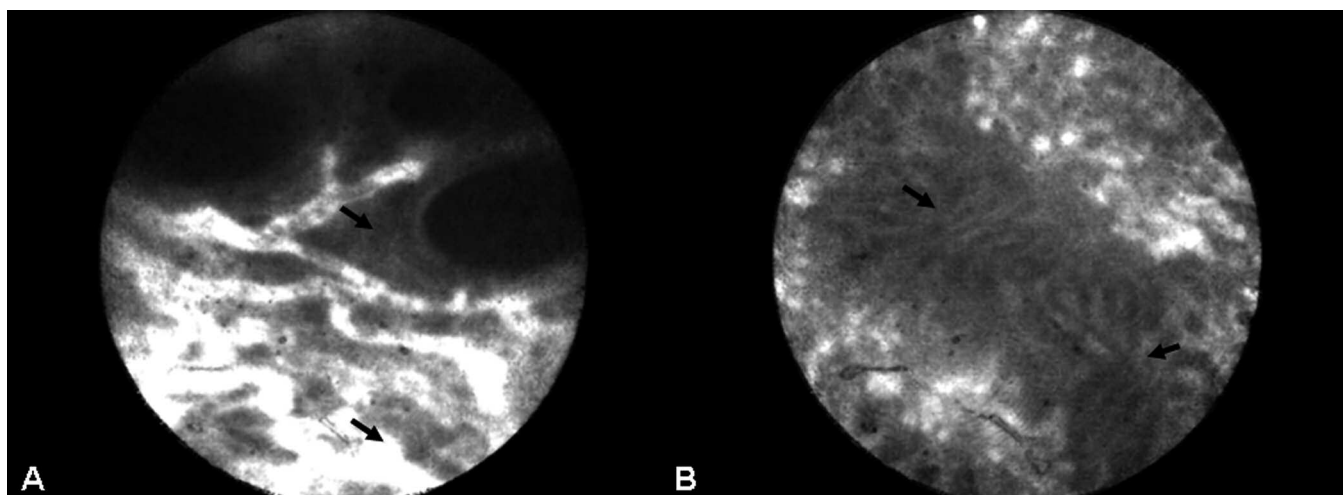


Fig. 6. In Crohn's disease confocal laser endomicroscopy revealed an increase of inflammatory cells and Fluorescein leakage around microvessels in the lamina propria (**A**, arrows). Colonic crypts were variously shaped and irregular in arrangement (**B**, arrows).

the first procedure performed in our department ($r_s = -0.29$).

Weighted kappa statistics showed high agreement between confocal and histopathological diagnosis with a value of 0.8116.

Endomicroscopy findings included lymphatic dilation, hyperaemia and visualization of different cellular structures like crypts, intestinal vili, goblet cells, inflammatory and lymphoid cells (Figs. 4-6). None of the patients investigated had any kind of intraepithelial neoplasia, neither on optical biopsies nor on standard histopathology.

No patient discomfort and no adverse events regarding the procedure or the use of intravenous

fluoresceine were documented in our study population.

Discussion

There was a significant improvement in CLE performance over time, including decreased confocal imaging time, successful CLE diagnosis and decline in procedural time. These parameters improved significantly after the initial three cases. After the first ten cases the mean procedural time remained at eighteen minutes suggesting that appropriate training can rapidly be achieved.

CLE represents a new endoscopic imaging technique which enables to obtain high resolution images of gut

mucosal layer at a subcellular resolution (ASGE Technology Committee et al., 2009). The technique is based on tissue illumination with a low-power laser. Therefore, fluorescent contrast agents have to be applied, either systemically (e.g. fluorescein) or topically (e.g. cresyl violet or acriflavine hydrochloride). The reflected laser light is refocused by the detection system allowing an optical biopsy of the superficial mucosal layer of the gut. Currently, two different imaging systems for endomicroscopy are available and approved by the FDA. In one system, the confocal endoscope is integrated within the distal tip of the endoscope (Pentax, Tokyo, Japan) whereas the other system is probe based (pCLE) and inserted through the accessory channel of a standard endoscope (Cellvizio, Mauna Kea Technologies, Paris, France). Both techniques have several advantages and disadvantages compared to the other. The advantages of the Pentax-system include a higher lateral resolution ($0.7\ \mu\text{m}$ compared to $1.0\ \mu\text{m}$ for pCLE) and the possibility to focus through the mucosa from $0\text{--}250\ \mu\text{m}$. The advantages of the Mauna Kea Technologies-system include the possibility of an ad hoc usage and a greater versatility of the pCLE probes, which can be used with nearly any endoscope (Neumann et al., 2010a). In this study we focused on the learning curve of pCLE. Previously, different studies have shown the potential applications of CLE in the diagnosis of different gastrointestinal disorders (ASGE Technology Committee et al., 2009; Neumann et al., 2010a). Therefore, CLE was able to predict the presence of neoplastic changes in polyps with high accuracy (97.4% sensitivity, 99.4% specificity, 99.2% accuracy) (Kiesslich et al., 2004). In a prospective, randomized, double-blind, controlled, crossover trial, CLE with targeted biopsy significantly improved the diagnostic yield for endoscopically inapparent Barrett's neoplasia compared to a standard endoscopy with random-biopsies and reduced the number of biopsies needed per patient (Dunbar et al., 2009). Furthermore, it was shown that CLE allows the *in-vivo* detection of *Helicobacter pylori*-infection and celiac disease (Kiesslich et al., 2005; Trovato et al., 2007).

However, CLE is believed to be time consuming and an examiner-dependent procedure. Therefore, the aim of this study was to prospectively provide the learning curve of CLE in patients with IBD. Our analysis showed a significant learning curve in performing CLE. In our experience, the average procedure duration was eighteen minutes after the initial ten cases showing a significant decrease between the first eight and the subsequent cases. Furthermore, the duration to receive a confocal image in focus and the number of confocal images in focus improved over time demonstrating a significant learning curve. While a clear advantage of CLE is its capability to perform an optical biopsy, thereby sparing tissue biopsies and consecutive time and costs of histopathological analysis, an adequate "histological" analysis by the endoscopist is absolutely necessary. Therefore, we analyzed Kappa statistics of histological

analysis between the endoscopist and gastropathologist. Our analysis showed high agreement between confocal and histopathological diagnosis which is in line with previously published data (Hoffman et al., 2006; Kiesslich et al., 2008). Of note, *in vivo* diagnosis of Crohn's disease may be limited as some pathogenic lesions characteristic for Crohn's disease cannot be visualized based on the limited tissue penetrance of the blue laser light. In our study we used the ultra high definition probe for confocal imaging which has an imaging plane depth of about $60\ \mu\text{m}$. Therefore, diagnosis of CD was based on vessel and architectural features including number of goblet cells, vascularity, crypts and presence of microerosions. Currently, there is an ongoing prospective trial to evaluate the sensitivity and specificity of these parameters for the *in vivo* diagnosis of Crohn's disease (Neumann et al., 2010b).

A limitation of our study was the relatively small sample size. Nevertheless, we were able to demonstrate a significant learning curve in performing CLE. Additionally, after the first ten cases the studied performance parameters showed no further significant changes, suggesting that appropriate training of CLE can be achieved after the first ten cases.

During the study, no severe or mild adverse events regarding the use of intravenous fluorescein were detected. Very recently, Wallace et al. performed a cross sectional survey of sixteen International Academic Medical Centers with active research protocols in CLE that involved intravenous fluorescein. While no serious adverse events were reported, mild adverse events occurred in 1.4% of individuals, including nausea/vomiting, transient hypotension without shock, injection site erythema, diffuse rash, and mild epigastric pain (Wallace et al., 2010). The authors concluded that the use of intravenous fluorescein for gastrointestinal CLE appears to be safe and is associated only with few acute complications.

In conclusion, CLE is certainly more time consuming than standard endoscopy with random biopsies but results are readily available and comparable to histopathological work-up. We were able to demonstrate a significant learning curve of CLE and high agreement between both confocal and histopathological diagnosis. Therefore, CLE represents a safe and easy to learn novel method for the *in vivo* diagnosis of IBD.

Acknowledgments. None of the authors has any conflicts of interest pertaining to this article/work to declare.

References

- ASGE Technology Committee, Kantsevoy S.V., Adler D.G., Conway J.D., Diehl D.L., Farraye F.A., Kaul V., Kethu S.R., Kwon R.S., Mamula P., Rodriguez S.A. and Tierney W.M. (2009). Confocal laser endomicroscopy. *Gastrointest. Endosc.* 70, 197-200.
- Dunbar K.B., Okolo P. 3rd, Montgomery E and Canto M.I. (2009).

- Confocal laser endomicroscopy in Barrett's esophagus and endoscopically inapparent Barrett's neoplasia: a prospective, randomized, double-blind, controlled, crossover trial. *Gastrointest. Endosc.* 70, 645-654.
- Hoffman A., Goetz M., Vieth M., Galle P.R., Neurath M.F. and Kiesslich R. (2006). Confocal laser endomicroscopy: technical status and current indications. *Endoscopy* 38, 1275-1283.
- Hurlstone D.P., Thomson M., Brown S., Tiffin N., Cross S.S. and Hunter M.D. (2007). Confocal endomicroscopy in ulcerative colitis: differentiating dysplasia-associated lesion mass and adenoma-like mass. *Clin. Gastroenterol. Hepatol.* 5, 1235-1241.
- Kiesslich R., Burg J., Vieth M., Gnaendiger J., Enders M., Delaney P., Polglase A., McLaren W., Janell D., Thomas S., Nafe B., Galle P.R. and Neurath M.F. (2004). Confocal laser endoscopy for diagnosing intraepithelial neoplasias and colorectal cancer in vivo. *Gastroenterology* 127, 706-713.
- Kiesslich R., Goetz M., Burg J., Stolte M., Siegel E., Maeurer M.J., Thomas S., Strand D., Galle P.R. and Neurath M.F. (2005). Diagnosing *Helicobacter pylori* in vivo by confocal laser endoscopy. *Gastroenterology* 128, 2119-2123.
- Kiesslich R., Goetz M., Lammersdorf K., Schneider C., Burg J., Stolte M., Vieth M., Nafe B., Galle P.R. and Neurath M.F. (2007). Chromoscopy-guided endomicroscopy increases the diagnostic yield of intraepithelial neoplasia in ulcerative colitis. *Gastroenterology* 132, 874-882.
- Kiesslich R., Goetz M. and Neurath M.F. (2008). Confocal laser endomicroscopy for gastrointestinal diseases. *Gastrointest. Endosc. Clin. N Am.* 18, 451-466.
- Kiesslich R. and Neurath M.F. (2008). What new endoscopic imaging modalities will become important in the diagnosis of IBD. *Inflamm. Bowel Dis.* 14, 172-176.
- Li C.Q., Xie X.J., Yu T., Gu X.M., Zuo X.L., Zhou C.J., Huang W.Q., Chen H. and Li Y.Q. (2010). Classification of inflammation activity in ulcerative colitis by confocal laser endomicroscopy. *Am. J. Gastroenterol.* 105, 1391-1396.
- Meining A. (2009). Confocal endomicroscopy. *Gastrointest. Endosc. Clin. N Am.* 19, 629-635.
- Neumann H., Fry L.C., Bellutti M., Malfertheiner P. and Mönkemüller K. (2009). Double-balloon enteroscopy-assisted virtual chromoendoscopy for small-bowel disorders: a case series. *Endoscopy* 41, 468-471.
- Neumann H., Kiesslich R., Wallace M.B., Neurath M.F. (2010). Confocal laser endomicroscopy: Technical advances and clinical applications. *Gastroenterology* 139, 388-392.
- Neumann H., Vieth M., Raitel M., Neurath M.F. and Mudter J. (2010). Confocal laser endomicroscopy in patients with Crohn's disease. *Gastrointest. Endosc.* 71, 342.
- Neumann H., Neurath M.F. and Mudter J. (2011). New endoscopic approaches in IBD. *World J. Gastroenterol.* 17, 63-68.
- Neurath M.F. and Finotto S. (2009). Translating inflammatory bowel disease research into clinical medicine. *Immunity* 31, 357-361.
- Trovato C., Sonzogni A., Ravizza D., Fiori G., Rossi M., Tamayo D., Miller M.J., Bardella M.T. and Crosta C. (2007). Celiac disease: in vivo diagnosis by confocal endomicroscopy. *Gastrointest. Endosc.* 65, 1096-1099.
- Wallace M.B. and Fockens P. (2009). Probe-based confocal laser endomicroscopy. *Gastroenterology* 136, 1509-1513.
- Wallace M.B., Meining A., Canto M.I., Fockens P., Miehke S., Roesch T., Lightdale C.J., Pohl H., Carr-Locke D., Lühr M., Coron E., Filoche B., Giovannini M., Moreau J., Schmidt C. and Kiesslich R. (2010). The safety of intravenous fluorescein for confocal laser endomicroscopy in the gastrointestinal tract. *Aliment. Pharmacol. Ther.* 31, 548-52.

Accepted January 19, 2011