

# Melanocytic matricoma. Report of a further case with clinicopathological and immunohistochemical findings, differential diagnosis and review of the literature

F. Cartaginese and A. Sidoni

Institute of Pathological Anatomy, Medical School, University of Perugia, Perugia, Italy

**Summary.** Melanocytic matricoma is a rare recently described lesion. It usually presents as a pigmented, dark-papular, crusted lesion on sun-damaged skin of adult patients. Histopathologically, these lesions are characterized by well-circumscribed nodules composed of matrical and supramatrical cells with clustered shadow cells, and admixed pigmented dendritic melanocytes. It differs from matricomas and pilomatricomas by its lack of calcification, cyst formation, granulomas, and connections to the epidermis and other adnexal structures. The clinical differential diagnosis includes hemangioma, pigmented basal cell carcinoma, and melanoma. Melanocytic matricoma presumably is the representation of an epithelial-melanocytic interaction in the anagen phase of the hair cycle. An extensive search of the medical literature revealed 11 reports of benign melanocytic matricomas and 5 malignant counterparts. We report an additional case of melanocytic matricoma with discussion of clinicopathologic features and differential diagnosis.

**Key words:** Melanocytic matricoma, Hair follicle, Pilomatricoma, Matricoma, Adnexal tumor

## Introduction

In 1999, Carlson and colleagues (Carlson et al., 1999) described two cases of well-circumscribed nodules composed of matrical and supramatrical cells surrounding solitary or clustered “ghost cells” and admixed pigmented dendritic melanocytes. The authors coined the designation “melanocytic matricoma” for

*Offprint requests to:* Professor Angelo Sidoni, S.C. di Anatomia Patologica, Azienda Ospedaliera di Terni, Via Tristano di Joannuccio 1, 05100 Terni, Italy. e-mail: [angelo.sidoni@med.unipg.it](mailto:angelo.sidoni@med.unipg.it), [fabiocartaginese@libero.it](mailto:fabiocartaginese@libero.it)

these neoplasms.

This peculiar lesion recollects the normal anatomic process that takes place in the healthy bulb of a hair follicle, recapitulating the intimate relationship existing between matrical epithelium and melanocytes in the embryonal hair follicle or in the anagen stage of the hair cycle (Carlson et al., 1999).

Ever since melanocytic matricoma was first described, there has been some discussion about whether there is sufficient clinical and pathologic evidence to support the real existence of this entity (Carlson et al., 2003; Resnik, 2003a,b; Rizzardi and Melato, 2003a,b).

An extensive search of the medical literature revealed that only a few cases of melanocytic matricoma have been reported since the original description, including benign (Carlson et al., 1999; Rizzardi et al., 2002; Williams et al., 2003; Horenstein and Kahn, 2004; Peralta Soler et al., 2007; Islam et al., 2007; Monteagudo et al., 2008) and malignant forms (Sloan et al., 1992; Hardisson et al., 2001; Monteagudo et al., 2003; Jani et al., 2008), and a case in a dog (Saito et al., 2005).

We present a new case of melanocytic matricoma with emphasis on morphological, immunohistochemical and diagnostic features.

Moreover, we have also examined the expression of E-cadherin and  $\beta$ -catenin, proteins that play an important role in the morphogenesis of hair follicles and are crucial in the development of hair follicle-related tumors (Peralta Soler et al., 2007), in order to support the hypothesis that melanocytic matricoma may represent an earlier stage of anagen phase of the hair cycle differentiation.

## Material and methods

A 81-year-old male with severely sun-damaged skin presented with an asymptomatic brown-black firm

## Melanocytic matricoma

papule, 15 mm in diameter, on his right forearm. The clinical differential diagnosis included pigmented basal cell carcinoma, thrombosed hemangioma and melanoma. The lesion was surgically excised. No local recurrence was noted at the site of the original excision after a follow-up of 53 months.

The tumor was completely excised. The biopsy specimen was fixed in 10% neutral buffered formalin and embedded in paraffin. Four-micrometer thick sections were stained with hematoxylin-eosin and periodic acid-Schiff.

We performed immunohistochemical studies on 4  $\mu$ m paraffin sections. The automatized instrument Bond-Max™ (Vision BioSystems™, Mount Waverley, Australia) and the Bond™ polymer refine detection system (Vision BioSystems™, Mount Waverley, Australia) were used to investigate labeling of antibodies to HMB45 (clone HMB45, ready to use, NeoMarkers), melan A (clone A103, ready to use, Novocastra), pancytokeratin (clone AE1/AE3, ready to use, Novocastra) high-molecular-weight cytokeratin (clone 34,E12, ready to use, Novocastra), S-100 protein (polyclonal, ready to use, Novocastra), E-cadherin (clone 36B5, ready to use, Novocastra) and  $\beta$ -catenin (polyclonal, ready to use, NeoMarkers).

For HMB45, melan A, pancytokeratin, high-molecular-weight cytokeratin and E-cadherin, sections were incubated at 25°C for 15 minutes with the respective antibodies and heat-induced epitope retrieval was performed using 0.01M citrate retrieval solution at pH 6.0. For S-100 protein, sections were incubated at 25°C for 15 minutes with the antibody; heat-induced epitope retrieval was not required. For  $\beta$ -catenin, sections were incubated at 25°C for 20 minutes with the antibody and heat-induced epitope retrieval was performed using 0.01M citrate retrieval solution at pH 6.

## Results

Microscopic examination of the surgical specimen revealed a well circumscribed nodule, with asymmetrically distributed black pigmentation, located in the middle and deep dermis (Fig. 1).

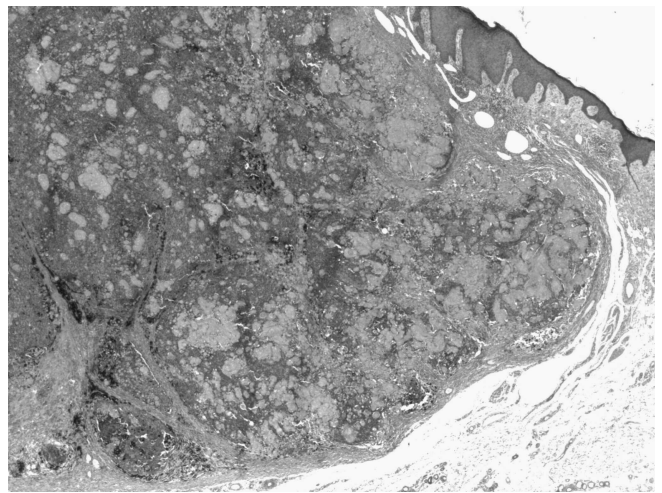
The tumor was composed of two cell populations, including an epithelial component and a melanocytic component. The epithelial component was arranged in solid nests and lobules composed of basaloid cells with scant amount of cytoplasm, indistinct cellular borders and prominent nucleoli (reminiscent of matrical and supramatrical cells), which abruptly turned into nucleus-free "shadow cells" with a characteristic ring of keratinized cytoplasm surrounding a lucent center. Basaloid cells displayed mitotic activity and a mild degree of cytological atypia. Admixed with these cells there was a melanocytic component consisting of dendritic melanocytes with abundant melanin pigmentation and scattered aggregates of melanophages (Fig. 2).

Large aggregates of melanin pigment were noted in

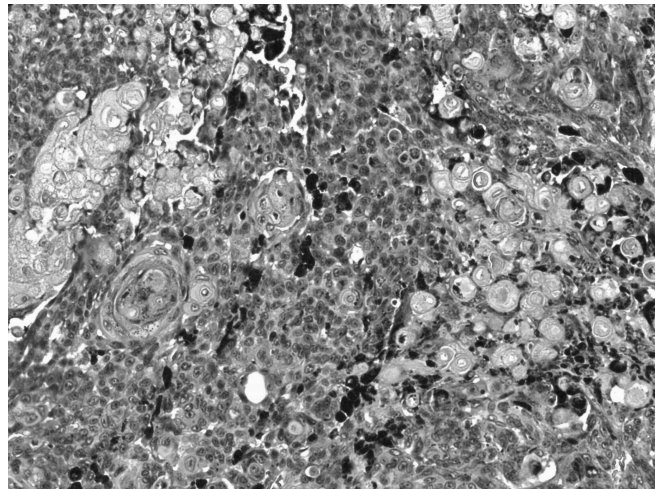
both the melanocytic and the epithelial components. No granulomatous reaction, calcification, cyst formation, or identifiable connection with the overlying epidermis or adnexal epithelium were observed.

The dermis surrounding the lesion revealed changes of significant sun damage. The epidermis overlying the dermal nodule was flattened and hyperkeratotic, with acanthosis at the periphery.

Immunohistochemically, pancytokeratin and high-molecular-weight cytokeratin (34BE12) exhibited positivity for surface epidermis as well as the keratinized "shadow cells", and, less prominently, the basaloid cells.



**Fig. 1.** Well delineated and asymmetrically pigmented tumor in the dermis. H&E, original magnification x 12.5.



**Fig. 2.** Greater magnification shows a biphasic cell population formed by basaloid matrical and supramatrical cells that abruptly turn into nucleus-free "shadow cells" and dendritic melanocytes. H&E, original magnification x 100.

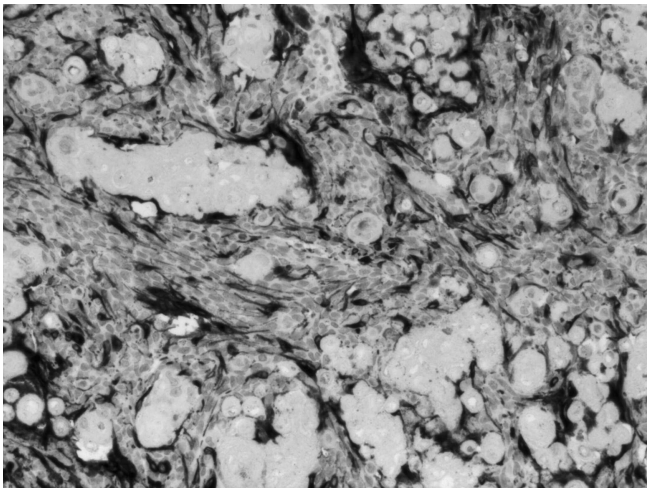
## Melanocytic matricoma

Melan A, S-100 protein and HMB-45 highlighted the morphology of the dendritic melanocytes, which were admixed with the epithelial cells, surrounding them with their process (Fig. 3).

The immunohistochemical studies for  $\beta$ -catenin revealed a cytoplasmatic and nuclear staining in the basaloid cells and a membranous staining in the intermediate differentiating cells. The fully differentiated "shadow cells" were negative. E-cadherin was at the cell membrane of all cells, with higher expression in keratinocytes than in melanocytes, and was absent in the "shadow cells". This expression pattern of E-cadherin and  $\beta$ -catenin is identical to the developing hair follicle in anagen phase (Peralta Soler et al., 2007).

### Discussion

Melanocytic matricoma was first recognized in 1999 by Carlson and colleagues (Carlson et al., 1999), who



**Fig. 3.** Melan A immunohistochemistry highlights dendritic melanocytes admixed with the epithelial cells. Original magnification x 100.

reported two cases of a pigmented matrical neoplasm that recapitulates the bulb of the anagen hair follicle, composed of matrical cells and dendritic melanocytes.

Subsequently, other case reports have confirmed the uniqueness of this entity (Rizzardi et al., 2002; Williams et al., 2003; Horenstein and Kahn, 2004; Saito et al., 2005; Islam et al., 2007; Peralta Soler et al., 2007; Monteagudo et al., 2008). Including the currently reported case, to our knowledge only twelve cases of melanocytic matricoma have been reported to date (Table 1).

The histogenesis and nomenclature of this tumor is still controversial (Resnik, 2003a,b; Rizzardi and Melato, 2003a,b; Carlson et al., 2003), but it is considered a peculiar entity which differs both clinically and histologically from pilomatricomas, matricomas and pigmented matricoma variants (Ackerman et al., 1993).

Melanocytic matricoma presents clinically as a small (less than 1 cm) well-circumscribed purple to black papule on sun-damaged skin in the elderly (sixth to seventh decade). Affected sites include the nose, preauricular area, cheek, chest, shoulder and forearm. The clinical differential diagnosis should include pigmented basal cell carcinoma, malignant melanoma and hemangioma (Brenn and McKee, 2005).

Histologically, the appearance of reported cases is quite similar. It presents as a well-circumscribed dermal tumor showing asymmetrical pigmentation. It is arranged in solid nests and lobules composed of basaloid cells with scant amounts of cytoplasm and prominent nucleoli reminiscent of matrical and supramatrical cells. Cytological atypia, as well as mitotic figures, may be present. Dispersed singly and in small aggregates are "shadow cells" within the tumor, and pigmented dendritic melanocytes are admixed. Surrounding the tumor there is a sclerotic stromal response containing melanophages. The dermis and overlying epidermis reveal changes of significant sun damage including elastosis, epidermal atrophy and actinic keratosis.

The characteristics of melanocytic matricoma, such as small size, well circumscribed borders and lack of

**Table 1.** Reported cases of melanocytic matricoma.

Authors/year	Age	Sex	Size (cm)	Site	Dermatologic history
Carlson (1999)1	66	M	0.8	Left chest region	BCC
Carlson (1999)1	80	M	0.5	Forearm	Sun damage
Rizzardi (2002)7	62	F	0.6	Nose	Sun damage
Williams (2003)8	78	M	0.4	Left preauricular area	BCC and AK
Horenstein (2004)9	69	M	0.5	Right cheek	Sun damage
Peralta Soler (2007)10	66	F		Right shoulder	
Islam (2007)11	70	M	1.5	Right hand	BCC
Islam (2007)11	82	M	0.5	Right preauricular area	AK, BCC and SCC
Islam (2007)11	76	M		Top part of back	
Monteagudo (2008)12	66	M	0.6	Bridge of nose	AK
Saito (2005)14 (dog)	2	M	2	Tail	
Present case (2010)	81	M	1.5	Right forearm	Sun damage

AK: actinic keratosis; BCC: basal cell carcinoma; SCC: squamous cell carcinoma.



recurrence, are highly suggestive of a benign nature. In the present case, the long disease-free period observed seems to confirm the benign behaviour of this tumor.

The histologic differential diagnoses of melanocytic matricoma include the pigmented variants of pilomatricoma, matrical carcinoma, basal cell carcinoma with matrical differentiation and malignant melanoma (Carlson et al., 1999; Williams et al., 2003).

Melanocytic matricoma is distinctly different from pilomatricoma, both clinically and pathologically. Pilomatricoma occurs in young people as a cystic neoplasm, is firm to the touch, and is located in the deep dermis or subcutaneous tissues; it is often accompanied by calcification of "shadow cells" and granulomatous response to keratinized elements (Carlson et al., 1999). In contrast, melanocytic matricoma presents as a papule in elderly individuals, without connections to the epidermis and other adnexal structures, and calcification and granulomatous reactions are uncommon. Pigmented pilomatricoma does not contain prominent melanocytic hyperplasia, contrasting with the marked proliferation of pigmented dendritic melanocytes in melanocytic matricoma (Zaim, 1971; Cazars et al., 1974; Spitz et al., 1981).

Melanocytic matricoma is morphologically different from so-called matricoma or proliferating pilomatricoma, despite some controversies in this issue (Carlson et al., 2003; Resnik, 2003a,b; Rizzardi and Melato, 2003a,b). According to Ackerman (1993), matricoma is described as having a silhouette composed of multiple small aggregations with cystic, solid and cystic, and solid profiles, positioned throughout the dermis and sometimes just inside the subcutaneous fat. In contrast, melanocytic matricoma is characteristically a single, solid dermal nodule and has a characteristic proliferation of dendritic melanocytes.

Matrical carcinoma with prominent melanocytic hyperplasia has been reported and the possibility of these lesions representing malignant melanocytic matricoma has been raised (Sloan et al., 1992; Hardisson et al., 2001; Monteagudo et al., 2003; Jani et al., 2008). This variant of carcinoma is a poorly defined, multinodular tumor that penetrates deeper layers and contains mitotically active cells and areas of necrosis, with a locally aggressive behaviour (Sloan et al., 1992; Hardisson et al., 2001; Monteagudo et al., 2003; Jani et al., 2008).

Basal cell carcinoma with matrical differentiation is characterized by foci of typical basal cell carcinoma composed of basaloid nests showing peripheral palisading and stromal retraction artefacts (Del Sordo et al., 2007).

It is known that the bulb of the hair follicles in the anagen phase contains matrical and supramatrical cells, as well as pigmented melanocytes that give hair its colour (Carlson et al., 1999). Because melanocytes are more prominent in the early anagen phase, melanocytic matricoma is suggestive of early-stage follicular differentiation during anagen; this contrasts with

pilomatricoma, which is characterized by late-stage differentiation (Carlson et al., 1999; Williams et al., 2003; Horenstein and Kahn, 2004; Peralta Soler et al., 2007; Islam et al., 2007).

Recently, Peralta Soler et al. (2007) have investigated the expression of cadherins and catenins, proteins that play an important role in the morphogenesis of hair follicles and the formation of hair follicle-related tumors, in a case of melanocytic matricoma. Their results have demonstrated that the differential distribution of these proteins in melanocytic matricoma is identical to the developing hair follicle in anagen phase.

In the present case, we have also investigated the distribution of E-cadherin and  $\beta$ -catenin and our results support the previously hypothesized resemblance of this rare tumor to the hair bulb in anagen.

In conclusion, melanocytic matricoma is a distinctive clinical and pathological entity that represents a benign pigmented papule in sun-damaged areas of older individuals, formed by well-circumscribed nodules with groups of "shadow cells" (matrical/supramatrical cells) and prominent pigmented dendritic melanocytes. Dermatologists and dermatopathologists should be aware of this entity and a correct interpretation is extremely important due to its clinical and histopathologic overlap with other malignant lesions.

## References

- Ackerman A.B., DeViragh P.A. and Chongchitnant N. (1993). Pilomatricoma and matricoma. In: Neoplasm with follicular differentiation. Spahr J.F. Jr (ed). Lea & Febiger. Philadelphia. pp 477-506.
- Brenn T. and McKee P.H. (2005). Melanocytic matricoma. In: Pathology of the skin with clinical correlation. 3rd ed. McKee P.H., Calonje E. and Granter S.R. (eds). Elsevier Mosby. pp 1541-1542.
- Carlson J.A., Healy K., Slominski A. and Mihm M.C. Jr (1999). Melanocytic matricoma: a report of two cases of a new entity. *Am. J. Dermatopathol.* 21, 344-349.
- Carlson J.A., Slominski A. and Mihm M.C. Jr (2003). What are the clinicopathologic features of matricoma? *Am. J. Dermatopathol.* 25, 446-447.
- Cazars J.S., Okun M.R. and Pearson H. (1974). Pigmented calcifying epithelioma. Review and presentation of a case with unusual features. *Arch. Dermatol.* 110, 773-774.
- Del Sordo R., Cavaliere A. and Sidoni A. (2007). Basal cell carcinoma with matrical differentiation: expression of  $\beta$ -catenin and osteopontin. *Am. J. Dermatopathol.* 29, 470-474.
- Hardisson D., Linares M., Cuevas-Santos J. and Contreras F. (2001). Pilomatricoma: a clinicopathologic study of six new cases and review of the literature. *Am. J. Dermatopathol.* 23, 394-401.
- Horenstein M.G. and Kahn A.G. (2004). Pathologic quiz case: a 69-year-old man with a brown-black facial papule. Melanocytic matricoma. *Arch. Pathol. Lab. Med.* 128, 163-164.
- Islam M.N., Bhattacharyya I., Proper S.A., Glanz S.M., Vega J.M. and Hassanein A.M. (2007). Melanocytic matricoma: a distinctive clinicopathologic entity. *Dermatol. Surg.* 33, 857-863.
- Jani P., Chetty R., Ghazarian D.M. (2008). An unusual composite

*Melanocytic matricoma*

- pilomatrix carcinoma with intralesional melanocytes: differential diagnosis, immunohistochemical evaluation, and review of the literature. *Am. J. Dermatopathol.* 30, 174-177.
- Monteagudo B., Requena L., Used-Aznar M.M. and Cabanillas M. (2008). Melanocytic matricoma. *Actas. Dermosifiliogr.* 99, 576-578.
- Monteagudo C., Fernández-Figueras M.T., San Juan J., Lopez D. and Carda C. (2003). Matrical carcinoma with prominent melanocytic hyperplasia (malignant melanocytic matricoma?). A report of two cases. *Am. J. Dermatopathol.* 25, 485-489.
- Peralta Soler A., Burchette J.L., Bellet J.S. and Olson J.A. Jr (2007). Cell adhesion protein expression in melanocytic matricoma. *J. Cutan. Pathol.* 34, 456-460.
- Resnik K.S. (2003a). Is melanocytic matricoma a bona fide entity or is it just one type of matricoma? *Am. J. Dermatopathol.* 25, 166.
- Resnik K.S. (2003b). Isn't melanocytic matricoma simply one expected histopathologic expression of matricoma? *Am. J. Dermatopathol.* 25, 446.
- Rizzardi C., Brollo A., Colonna A., Lo Brutto R. and Melato M. (2002). A tumor with composite pilo-folliculosebaceous differentiation harboring a recently described new entity-melanocytic matricoma. *Am. J. Dermatopathol.* 24, 493-497.
- Rizzardi C. and Melato M. (2003a). Is melanocytic matricoma a bona fide entity or is it just one type of matricoma?: splitting hairs... in hair matrix tumors! Author's reply. *Am. J. Dermatopathol.* 25, 166-167.
- Rizzardi C. and Melato M. (2003b). Simply, the point is that pathologists should bear in mind melanocytic matricoma. *Am. J. Dermatopathol.* 25, 447.
- Saito S., Suzuki K., Shibuya H., Yamaguchi T. and Sato T. (2005). Melanocytic matricoma in a dog. *Vet. Pathol.* 42, 499-502.
- Sloan J.B., Sueki H. and Jaworsky C. (1992). Pigmented malignant pilomatrixoma: report of a case and review of the literature. *J. Cutan. Pathol.* 19, 240-246.
- Spitz D., Fisher D., Friedman R.J. and Kopf A.W. (1981). Pigmented pilomatricoma. A clinical simulator of malignant melanoma. *J. Dermatol. Surg. Oncol.* 7, 903-906.
- Williams C.M., Bozner P., Oliveri C.V. and Horenstein M.G. (2003). Melanocytic matricoma: case confirmation of a recently described entity. *J. Cutan. Pathol.* 30, 275-278.
- Zaim M.T. (1971). Pilomatricoma with melanocytic hyperplasia: an uncommon occurrence and a diagnostic pitfall. *Arch. Dermatol.* 104, 865-866.

Accepted December 23, 2009