

The relationship between pregnancy-associated plasma protein-A (PAPP-A) and human intervertebral disc degeneration

Helen E. Gruber¹, Laura Buchanan¹, Jane A. Ingram¹,
Natalia Zinchenko¹, H. James Norton² and Edward N. Hanley Jr¹

¹Department of Orthopaedic Surgery and ²Department of Biostatistics, Carolinas Medical Center, Charlotte, N.C., USA

Summary. Pregnancy-associated plasma protein-A (PAPP-A), a metalloproteinase expressed by a number of cell types, has the important role of cleaving insulin-like growth factor (IGF)-binding protein-2, -4 and -5 in the extracellular matrix and thus freeing up IGF and making it available to cells. The objective of the present study was to utilize immunocytochemical analysis to determine the proportion of PAPP-A-positive cells in a large group of disc specimens which covered the spectrum of changes from relatively healthy Thompson grade II discs to extremely degenerate grade V discs. Work was approved by our institutional human subjects review board. Seventy-two intervertebral disc specimens were assessed for immunocytochemical localization of PAPP-A and the proportion of positive cells determined in the outer annulus, inner annulus and nucleus pulposus. The percentage of PAPP-A positive cells in both the outer and inner annulus correlated significantly with increasing stages of disc degeneration in a fashion which was not dependent upon subject age. There was no significant difference in the percentage of PAPP-A positive cells in the inner annulus of herniated vs non-herniated sites, or in the outer annulus of herniated vs non-herniated sites. Data reported here point to the importance of additional work to elucidate the role of PAPP-A in intervertebral disc aging and degeneration.

Key words: PAPP-A, Disc degeneration, Immunocytochemistry

Introduction

Pregnancy-associated Plasma Protein-A (PAPP-A) is a newly recognized metalloproteinase (MMP) expressed by several cell types, including fibroblasts, osteoblasts and smooth muscle cells (Lawrence et al., 1999; Mazerbourg et al., 2001; Ortiz et al., 2003; Sivanandam et al., 2004; Conover et al., 2004, 2006; Kumar et al., 2005; Qin et al., 2006; Jia and Heersche 2007). Recent work has also shown that PAPP-A is present in the human intervertebral disc (Gruber et al., 2008b). PAPP-A has an extremely important role because it cleaves IGF binding proteins (IGFBP) -2, -4 and -5 in the extracellular matrix (ECM), thereby modulating local IGF bioavailability to nearby cells (Kumar et al., 2005; Boldt and Conover 2007).

Insulin-like growth factor-I (IGF-I) has long been recognized as an important regulator of chondrocyte phenotype and differentiation. Some cells, such as human osteoarthritic chondrocytes, show a low or hyporesponsive response to IGF-I (Tardig et al., 1996). Compared to cartilage, much less is understood about IGF-I in the human intervertebral disc. Okuda et al., have suggested that the age-related decrease in IGF-I dependent proteoglycan synthesis in disc cells from the rat may be caused by increased IGF-binding proteins (IGF-BPs) during early aging (Okuda et al., 2002). This points to the importance of obtaining a greater understanding of how IGF-I is regulated in the disc.

Conover et al., have studied many aspects of PAPP-A in their recent publications, including its regulation in cultured human osteoblasts (Conover et al., 2004) and smooth muscle cells (Bayes-Genis et al., 2001; Conover et al., 2006), and have reviewed that it is expressed by a variety of cell types (Boldt and Conover 2007). PAPP-A is now viewed as an important determinant of growth and development via its ability to proteolyze IGFBPs

and thus regulate IGF bioavailability in the microenvironment around cells. Thus is it timely to further study the specific role of PAPP-A in the pathophysiology of disc degeneration.

There is some evidence that there may be increased IGFBP in the aged disc. In vitro work by Okuda et al., looked at cultured disc cells from aging rats (Okuda et al., 2002). They found an age-related decrease in proteoglycan synthesis and an increase in IGFBPs. Osada et al., have cultured bovine disc cells, and found that fetal cells were much more active than adult cells (Osada et al., 1996). Walsh et al., examined mouse disc cells and also found a muted response to IGF-I in vitro (Walsh et al., 2004). It is important to note, however, that these were data derived from in vitro work which may have influenced cell responses.

The objective of the present study was to utilize immunocytochemical analysis to determine the proportion of PAPP-A-positive cells in a larger group of disc specimens (compared to our previous analyses (Gruber et al., 2008b) which covered the spectrum of changes from relatively healthy Thompson grade II discs (Thompson et al., 1990) to extremely degenerate grade V discs. In addition, we investigated potential differences between cervical compared to lumbar disc sites, and potential relationships with disc herniation.

Material and methods

Clinical study population

Experimental study of human disc specimens was approved prospectively by the authors' Human Subjects Institutional Review Board at Carolinas Medical Center. The need for informed consent was waived since disc tissue was removed as part of routine surgical practice. Scoring of disc degeneration utilized the Thompson scoring system; this system scores disc degeneration over the spectrum from healthy discs to discs with advanced degeneration (grade V, the most advanced stage of degeneration) (Thompson et al., 1990). Patient specimens were derived from surgical disc procedures performed on individuals with herniated discs and degenerative disc disease. Surgical specimens were transported to the laboratory in sterile tissue culture medium. The study population contained the following Thompson grade distribution: Lumbar specimens: 6 grade II specimens; 21 grade III specimens, 21 grade IV specimens, and 1 grade V specimen; cervical specimens: 2 grade III specimens, 20 grade IV specimens, and 1 grade V specimen.

Immunolocalization of PAPP-A in human disc tissue and cell counts

Specimens were fixed in 10% neutral buffered formalin for no longer than 24 hours, and stored in 70% ethanol until embedding in paraffin without decalcification. Paraffin sections were cut at 4 μ m, collected on PLUS slides (Allegiance, McGaw Park, IL)

and dried at 60°C. Sections were deparaffinized in xylene (Allegiance) and rehydrated through graded alcohols (AAPER, Shelbyville, KY) to distilled water. The remainder of the procedure was performed using the Dako Autostainer Plus (Dako, Carpinteria, CA) automated stainer. Endogenous peroxidase was blocked using 3% H₂O₂ (Humco, Texarcana, TX). Slides were incubated for one hour with anti-human PAPP-A (polyclonal rabbit anti-human; Dako) at a 1:50 dilution. Universal Negative control rabbit (Dako) was used as a negative control. Secondary antibody was Dako LSAB2 biotinylated Link for HRP/AP for 10 minutes followed by peroxidase-conjugated streptavidin (Dako) for 10 minutes and DAB (Dako) for 5 minutes. Slides were removed from the stainer, rinsed in water, counterstained with 0.002% light green, dehydrated, cleared and mounted with resinous mounting media (Cytoseal XYL, Richard-Allan Scientific, Kalamazoo, MI).

The proportion of cells positive for PAPP-A immunolocalization was determined by counting the number of positive and negative cells in outer annulus, inner annulus and nucleus pulposus regions of the disc. No measurements were performed in sites of morphologic evidence of disc herniation. Two authors (HEG and LB) performed cell counts, and data were checked for intraobserver consistency. The scorer was blinded to grade and age at the time of histologic scoring. For cell counts, the average total number of cells scored were as follows: outer annulus, 299 \pm 190 (53) (mean \pm S.D. (n)); inner annulus, 477 \pm 279 (67), and nucleus pulposus, 300 \pm 68 (4).

Statistical analyses

Statistical analysis of data utilized standard methods using SAS software (version 11; SAS Institute, Cary, NC), including Fisher's exact test, ANOVA and Tukey's test where appropriate, correlation analyses and t-tests. Data were tested for normality using the Shapiro-Wilk test. When testing for linear relationships between Thompson disc grades and the percentage of cells positive for PAPP-A immunolocalization, Spearman's correlation coefficient, a non-parametric test, was used because Thompson grades were measured on an ordinal scale. Since only four nucleus specimens were available for analyses, these nucleus data were not included in our correlation analyses.

Results

Table 1 summarizes the subject demographic data according to Thompson grade and region of the disc evaluated (outer annulus, inner annulus and nucleus). (Note that some tissue samples contained both regions of outer annulus and inner annulus, and inner annulus and nucleus pulposus.) The study population contained 21 males and 50 females, and disc specimens were obtained from 49 lumbar and 22 cervical disc sites.

Figures 1-3 show representative immunocytochemical localizations in the outer annulus (Fig. 1A),

PAPP-A in the human disc

inner annulus (Fig. 2), and nucleus pulposus (Fig. 3). A negative control is shown for the outer annulus in Figure 1B. When disc cells were present in clusters (Fig. 2B), both positive and negative localization patterns were present. Degenerating discs also can contain annulus cells encapsulated by concentric layers of matrix material. Such cells often displayed PAPP-A localization as shown in Figure 2C).

The percentages of PAPP-A positive cells in the outer annulus and in the inner annulus grouped according to disc degenerative stage are shown in Figure 4A and B. Although both relationships are highly significant ($p=0.0063$ and <0.0001), there was a stronger correlation present with the inner annulus data. In the outer annulus, the percentage of cells positive for PAPP-A localization was 24% larger in more degenerated grade V discs than in grade II discs (Fig. 5A). In the inner annulus, however, there was a 50% increase in cells positive for PAPP-A localization when comparing grade II discs to grade V discs (Fig. 5B). (Since only four specimens were analyzed from the nucleus

pulposus, these data were not included in the analyses relating data to disc grade).

To further investigate the relationship between disc degeneration and the proportion of PAPP-A positive cells in the inner annulus, we utilized ANOVA analysis with Tukey's test. Since there were few specimens in the Thompson grade V group, these were pooled with the grade IV specimen data for this analysis. Analysis showed that there were significant differences between grade II discs and grade III and pooled grade IV-V discs, and between grade III and pooled grade IV-V discs, $p=0.05$. As shown in Fig. 4, 5, the proportion of positive cells increased with increasing disc degeneration.

In the present study we also investigated here potential differences due to derivation of data from cervical vs. lumbar disc sites. (The four specimens from the nucleus pulposus were all derived from lumbar disc sites.) As shown in Table 2, there were no significant

Table 1. Patient demographic data and thompson grades*.

Thompson Grade	Outer Annulus**	Inner Annulus**	Nucleus**	Age (years) *
II	3	5	1	36.1±11.2 (6)
III	19	19	3	43.4±11.6 (22)
IV	29	41	0	53.8±10.2 (41)
V	2	2	0	49.0±11.3 (2)
Pooled Grades IV and V	31	43	0	53.6±10.2 (43)

* Data expressed as means ± S.D. (n). Age data represent mean age for all subjects of respective disc grade. ** Data are number of specimens for each disc site in the respective disc grade

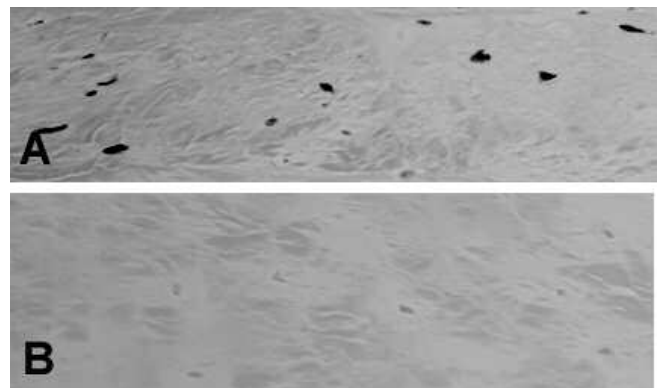


Fig. 1. A. Immunolocalization of PAPP-A in cells in the outer annulus. B. Negative control from an adjacent section. x 320

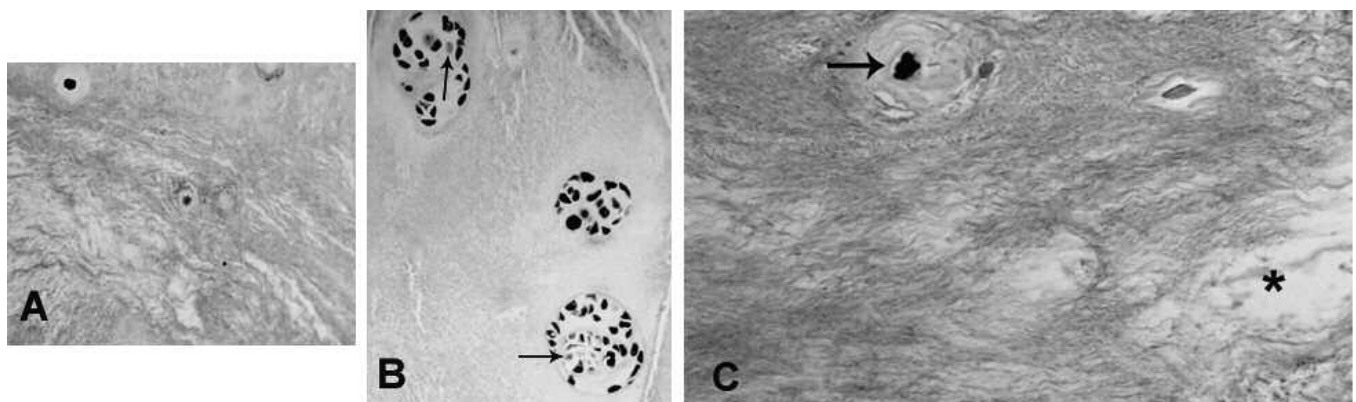


Fig. 2. Immunolocalization of PAPP-A in cells in the inner annulus (A). When cells were present in clusters (B) in the inner annulus, both positive and negative cells were present. Cells with negative localization are marked by arrows. C illustrates an inner annulus cell which is surrounded by a concentric encapsulating matrix (arrow) and is positive for PAPP-A localization. Note the prominent degeneration and loss of matrix in this specimen (*). A, x 275; B, x 250; C, x 320

PAPP-A in the human disc

Table 2. Comparison of data by disc site (lumbar vs cervical)*.

	Lumbar	Cervical
Age (years)	47.0±13.7 (49)	53.0±6/8 (23)
Outer annulus: % Positive for PAPP-A localization	75.0±14.9 (39)	82.4±14.8 (14)
Inner Annulus: % Positive for PAPP-A localization	63.7±20.2 (45)	76.2±10.3 (22) **
Nucleus pulposus	16.5±9.5 (4)	--

*Data expressed as means ± S.D. (n). ** The mean percentage localization in the cervical inner annulus specimens was significantly greater than that in the corresponding lumbar sites, p=0.0013.

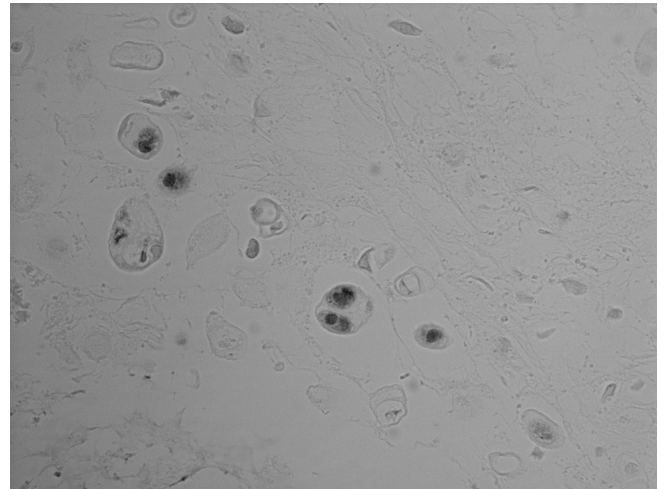


Fig. 3. This image of the nucleus pulposus shows a region of relatively few cells, some of which were positive for PAPP-A immunolocalization. x 720

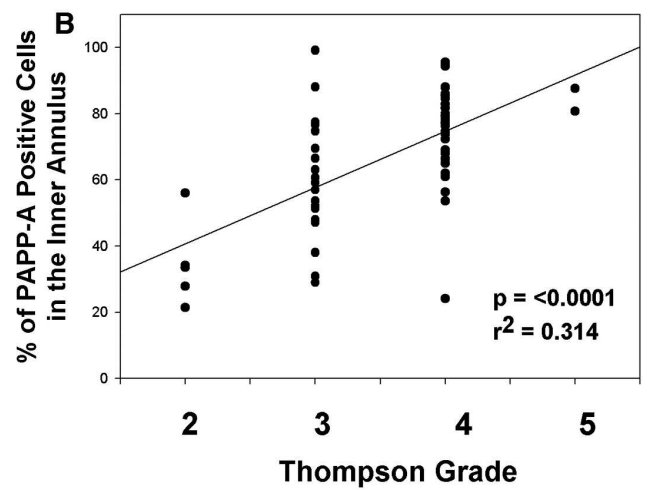
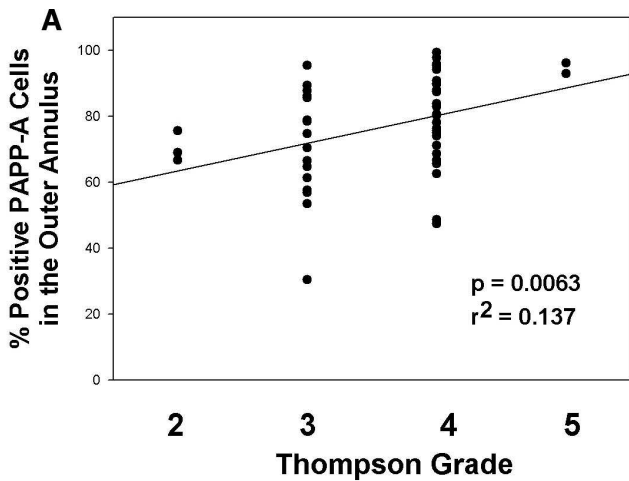


Fig. 4. Presentation of the proportion of cells positive for PAPP-A immunolocalization in the outer annulus (A) and in the inner annulus (B).

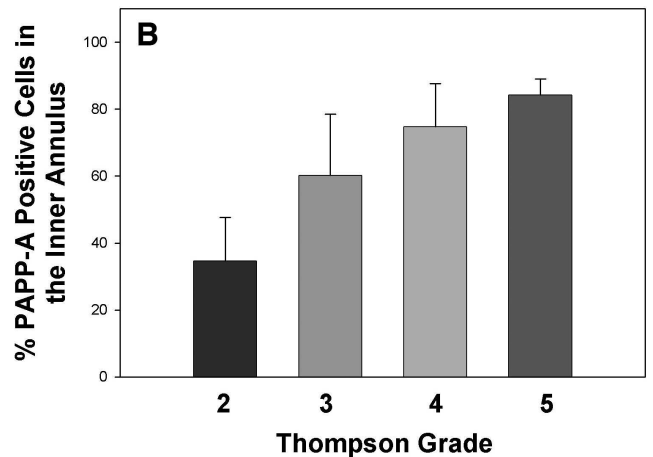
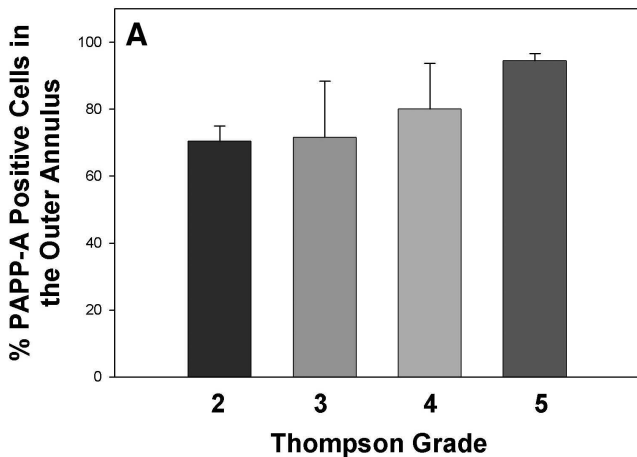


Fig. 5. Mean data for the proportion of cells positive for PAPP-A localization in the outer annulus (A) and inner annulus (B). Data are presented as means ± S.D.

PAPP-A in the human disc

Table 3. Comparison of data derived from herniated vs non-herniated sites *.

	Herniated Sites	Non-Herniated Sites
Outer annulus: % Positive for PAPP-A localization	80.3±11.36 (28)	73.37±17.98 (25)
Inner Annulus: % Positive for PAPP-A localization	68.95±17.31 (39)	66.31±20.19 (28)

**Data expressed as means ± S.D. (n)

differences in mean ages, or the mean percentage of cells positive for PAPP-A localization in the outer annulus. There was, however, a significantly greater percentage of immunolocalization of PAPP-A in the cervical inner annulus compared to percentage in the lumbar inner annulus ($p=0.0013$, Table 2).

Annulus data were also analyzed using analysis of covariance to test whether there was a contribution from subject age. When controlling for age with this technique, data still showed a significant relationship to the higher stages of disc degeneration in the inner annulus ($p<0.0001$). This finding, however, did not hold for data from the outer annulus, possibly due to our smaller sample size in that group.

Finally, data were analyzed to determine if data from herniated discs differed from data derived from non-herniated discs. No significant difference was present between herniated vs non-herniated discs for the percentage of positive cells in the outer annulus, or for the percentage of positive cells in the inner annulus (Table 3).

Discussion

The proteolytic activity of PAPP-A targets selected IGFBP 2, 4 and 5. We have previously shown that these binding proteins are expressed by the cells of the human intervertebral disc (Gruber et al., 2008b). Findings from the work of Kumar et al. examining conditioned medium of myoblasts showed that PAPP-A did not cleave IGFBP-3 (Kumar et al., 2005). These investigators proposed that PAPP-A plays a critical role by enhancing the bioavailability of IGFs by its degradation of the IGFbps and the subsequent release of IGFs into the surrounding tissues (Kumar et al., 2005), and it is likely that it plays a similar role in the intervertebral disc extracellular matrix.

IGF-1 is an important cytokine in the disc from a number of perspectives. As noted above, Okuda et al., studied cultured disc cells from aging rats (Okuda et al., 2002) and identified an age-related decrease in proteoglycan synthesis and an increase in IGFbps. Work from our laboratory has found that IGF-1 has an anti-apoptotic effect and an anti-senescent effect on cultured human annulus cells (Gruber et al., 2000, 2008a). Thus a

better understanding of PAPP-A, which has the ability to free up IGF in the disc matrix, is biologically important.

Whether in lumbar discs or cervical disc, the findings reported here show that a greater proportion of disc cells contain PAPP-A in the more advanced stages of disc degeneration (Figs. 4, 5), a relationship which was shown to be independent of subject age by our analysis of covariance assessment.

Studies on matrix synthesis and degradation in the disc have shown that pro-inflammatory cytokines, such as TNF- α , are important cytokines involved in the pathogenesis of disc degeneration (Freemont et al., 2002; Weiler et al., 2005). TNF- α is elevated in the degenerating disc, induces changes in the biochemical features of discs, notably a loss in proteoglycans, stimulates production of nerve growth factor (Abe et al., 2007), and has been found to regulate MMP-3 in nucleus pulposus cells (Seguin et al., 2005). These data are important since there is an accumulating body of evidence showing that PAPP-A is the target of inflammatory cytokines (Resch et al., 2004).

In addition to studies on TNF α , work by Hoyland et al., emphasizes the importance of the role of IL-1 in the degenerating intervertebral disc. LeMaitre et al., have reported increased levels of IL-1 in degenerate human discs (LeMaitre et al., 2005). IL-1 was also found to significantly downregulate types I and II collagen and aggrecan (LeMaitre et al., 2005). There are also data showing that IL-1 beta will stimulate, and the IL-1 receptor agonist inhibit, matrix degeneration in intact human discs (Hoyland et al., 2008). Current three-dimensional in vitro work in our laboratory, however, has shown that both IL-1 and TNF α will stimulate in vitro production of PAPP-A by human annulus cells (Gruber et al., 2010); we look forward to additional studies of both in vivo and in vitro effects of inflammatory cytokines on the intervertebral disc.

We should mention that a shortcoming of the present study is the absence of concomitant measurement of IGF-1 and the relevant IGF-binding proteins. This would have been very helpful since data from the aging rat nucleus pulposus by Okuka et al. (2002) have been interpreted to show a loss of proteoglycans caused by downregulation of IGF-1 receptor in addition to an increase in IGF-binding proteins. Clearly future human annulus and nucleus pulposus studies which include such analyses will be important contributions to the literature.

In summary, the work presented here is important because it provides new insight into disc cell expression of PAPP-A during disc degeneration. As the disc degenerates, a significantly greater proportion of cells express PAPP-A. We look forward to additional studies from in vivo and in vitro investigations to further analyze PAPP-A's role in disc aging and degeneration.

Acknowledgements. We wish to thank the Carolinas Back Pain Research Endowment and the Cannon Research Grant program for support.

References

- Abe Y., Akeda K., An H.S., Aoki Y., Pichika R., Muehleman C., Kimura T. and Masuda K. (2007). Proinflammatory cytokines stimulate the expression of nerve growth factor by human intervertebral disc cells. *Spine* 32, 635-642.
- Bayes-Genis A., Schwartz R.S., Lewis D.A., Overgaard M.T., Christiansen M., Oxvig C., Ashai K., Homes D.R. Jr and Conover C.A. (2001). Insulin-like growth factor binding protein-4 protease produced by smooth muscle cells increases in the coronary artery after angioplasty. *Arterioscler. Thromb. Vasc. Biol.* 21, 335-341.
- Boldt H.B. and Conover C.A. (2007). Pregnancy-associated plasma protein -A (PAPP-A): A local regulator of IGF bioavailability through cleavage of IGF-BPs. *Growth Hormone IGF Res.* 17, 10-18.
- Conover C.A., Chen B.-K. and Resch Z.T. (2004). Regulation of pregnancy-associated plasma protein-A expression in cultured human osteoblasts. *Bone* 34, 297-302.
- Conover C.A., Bale L.K., Harrington S.C., Resch Z.T., Overgaard, M.T. and Oxvig C. (2006). Cytokine stimulation of pregnancy-associated plasma protein A expression in human coronary artery smooth muscle cells: inhibition by resveratrol. *Am. J. Physiol. Cell Physiol.* 290, C183-C188.
- Freemont A.J., Watkins A., LeMaitre C., Jeziorska M. and Hoyland J.A. (2002). Current understanding of cellular and molecular events in intervertebral disc degeneration: implications for therapy. *J. Pathol.* 196, 374-379.
- Gruber H.E., Norton H.J. and Hanley E.N.Jr (2000). Anti-apoptotic effects of IGF-1 and PDGF on human intervertebral disc cells in vitro. *Spine* 25, 2153-2157.
- Gruber H.E., Hoelscher G., Ingram J., Bethea S. and Hanley E.N. Jr (2008a). IGF-1 rescues human intervertebral annulus cells from in vitro stress-induced premature senescence. *Growth Factors* 26, 220-225.
- Gruber H.E., Hoelscher G.L., Ingram J.A. and Hanley E.N. (2008b). Immunolocalization and biochemical evidence of pregnancy-associated plasma protein-A (PAPP-A) in the intervertebral disc. *Spine* 33, E447-E454.
- Gruber H.E., Hoelscher G.L., Deepe R. and Hanley E.N. Jr (2010). IL-1 and TNF- α stimulate pregnancy-associated plasma protein A production in human annulus cells in three-dimensional culture. *Orthopaedic Research Society, 2010 abstracts.*
- Hoyland J.A., Le Maitre C. and Freemont A.J. (2008). Investigation of the role of IL-1 and TNF in matrix degradation in the intervertebral disc. *Rheumatology* 47, 809-814.
- Jia D. and Heersche J.N.M. (2007). Pregnancy-associated plasma protein-A proteolytic activity in rat vertebral cell cultures: Stimulation by dexamethasone - A potential mechanism for glucocorticoid regulation of osteoprogenitor proliferation and differentiation. *J. Cell. Physiol.* 204, 848-858.
- Kumar A., Mohan S., Newton J., Rehage M., Tran K., Baylink D.J. and Qin X. (2005). Pregnancy-associated plasma protein-A regulates myoblast proliferation and differentiation through an insulin-like growth factor-dependent mechanism. *J. Biol. Chem.* 280, 37782-37789.
- Lawrence J.B., Oxvig C., Overgaard M.T., Sottrup-Jensen L., Gleich G.J., Hayes L.G., Yates J.R. 3rd and Conover C.A. (1999). The insulin-like growth factor (IGF)-dependent IGF binding protein-4 protease secreted by human fibroblasts is pregnancy-associated plasma protein-A. *Proc. Natl. Acad. Sci. USA* 96, 3149-3153.
- LeMaitre C.L., Freemont A.J. and Hoyland J.A. (2005). The role of interleukin-1 in the pathogenesis of human intervertebral disc degeneration. *Arthritis Res. Therapy* 7, R732-R745.
- Mazerbourg S., Overgaard M.T., Oxvig C., Christiansen M., Conover C.A., Laurendeau I., Vidaud M., Tosser-Klopp G., Zapf J. and Monget P. (2001). Pregnancy-associated plasma protein-A (PAPP-A) in ovine, bovine, porcine, and equine ovarian follicles: Involvement in IGF binding protein-4 proteolytic degradation and mRNA expression during follicular development. *Endocrinology* 142, 5243-5253.
- Okuda S., Myoui A., Ariga K., Nakase T., Yonenobu K. and Yoshikawa H. (2002). Mechanisms of age-related decline in insulin-like growth factor-I dependent proteoglycan synthesis in rat intervertebral disc cells. *Spine* 26, 2421-2426.
- Ortiz C.O., Chen B.-K., Bale L.K., Overgaard M.T., Oxvig C. and Conover C.A. (2003). Transforming growth factor-, regulation of the insulin-like growth factor binding protein-4 protease system in cultured human osteoblasts. *J. Bone Miner. Res.* 18, 1066-1072.
- Osada R., Ohshima H., Ishihara H., Yudoh K., Sakai K., Matsui H. and Tsuji H. (1996). Autocrine/paracrine mechanism of insulin-like growth factor-1 secretion, and the effect of insulin-like growth factor-1 on proteoglycan synthesis in bovine intervertebral discs. *J. Orthop. Res.* 14, 690-699.
- Qin X., Wergedal J.E., Rehage M., Tran K., Newton J., Lam P., Baylink D.J. and Mohan S. (2006). Pregnancy-associated plasma protein-A increases osteoblast in vitro and bone formation *in vivo*. *Endocrinology* 147, 5653-5661.
- Resch Z.T., Chen B.-K., Bale L.K., Oxvig C., Overgaard M.T. and Conover C.A. (2004). Pregnancy-associated plasma protein A gene expression as a target of inflammatory cytokines. *Endocrinology* 145, 1124-1129.
- Seguin C.A., Pilliar R.M., Roughley P.J. and Kandel R.A. (2005). Tumor necrosis factor-alpha modulates matrix production and catabolism in nucleus pulposus tissue. *Spine* 30, 1940-1948.
- Sivanandam A.S., Mohan S., Kita H., Kapur S., Chen S.-T., Linkhart T.A., Bagi G., Baylink D.J. and Qin X. (2004). Studies on regulation of IGF (insulin-like growth factor)-binding protein (IGFBP) 4 proteolysis by pregnancy-associated plasma protein-A (PAPP-A) in cells treated with phorbol ester. *Biochem. J.* 379, 57-64.
- Tardif F., Reboul P., Pelletier J.P., Geng C. and Cloutier J.M.M.-P.J. (1996). Normal expression of type 1 insulin-like growth factor receptor by human osteoarthritic chondrocytes with increased expression and synthesis of insulin-like growth factor binding proteins. *Arthritis Rheum.* 39, 968-978.
- Thompson J.P., Pearce R.H., Schechter M.T., Adams M.E., Tsang I.K.Y. and Bishop P.B. (1990). Preliminary evaluation of a scheme for grading the gross morphology of the human intervertebral disc. *Spine* 15, 411-415.
- Walsh A.J.L., Bradford D.S. and Lotz J.C. (2004). In vivo growth factor treatment of degenerated intervertebral discs. *Spine* 29, 156-163.
- Weiler C., Nerlich A.G., Bachmeier B.E. and Boos N. (2005). Expression and distribution of tumor necrosis factor alpha in human lumbar intervertebral discs: A study in surgical specimen and autopsy controls. *Spine* 30, 44-53.