

Temporomandibular joint disc: a proposed histopathological degeneration grading score system

Rosalia Leonardi¹, Mugurel Constantin Rusu² and Carla Loreto³

¹Department of Dentistry, Faculty of Dentistry, University of Catania, Policlinico Universitario, Italy, ²Faculty of Dental Medicine, University of Medicine and Pharmacy Carol Davila Bucharest, Romania and ³Department of Anatomy, Diagnostic Pathology, Forensic Medicine, Hygiene and Public Health, University of Catania, Italy

Summary. Aims: The purpose of this study was to draw up a TMJ disc histopathological score that is a semi-quantitative transcription of the entire spectrum of TMJ disc degenerative diseases related to changes in disc tissue, and then validate the proposed grading, in order to contribute to a standardized histopathological diagnosis. Methods: Sections from sixty two temporomandibular joint disc specimens affected by tissue degenerative changes and stained with Hematoxylin & Eosin (H&E) were collected from among those found in the archives of the Department of Dentistry at Catania University. Specimens, included anterior, intermediate and posterior disc bands. Based on a literature search regarding the most frequent histopathological changes detected in TMJ disc tissue a grading score was designed. This score takes into account pathological disc tissue transformation i.e. collagen bundles, non-specific degenerative changes and the presence of blood vessels. This grading system results in a score ranging from 0 up to 8 for heavily degenerated disc tissue. Two observers performed the assessment of the TMJ disc H&E stained sections. Each specimen was scored twice by each observer after a minimum interval of 1 week. Results: The average TMJ disc degeneration score of the TMJ disc sample was 3.89 ± 1.37 . There was an almost perfect agreement, between the two observers, and degeneration scores from the two observers were highly correlated. Conclusions: The introduction of this validated degeneration score system may be of major importance for future research and collaboration between different centers in order to improve knowledge in TMJ disc histopathology.

Key words: TMJ disc, Degeneration, Histopathology, Grading, Score

Introduction

The human temporomandibular joint (TMJ) articular disc consists of a compact fibrous tissue, in which rare fibroblast-like cells can be found among the compact and regularly arranged collagen fibres (Caltabiano et al., 1991; Marchetti et al., 1999; Leonardi et al., 2001, 2002b). This disc separates the articulating surface of the glenoid fossa and eminence from that of the mandibular condyle, dividing the joint cavity into two compartments (Kapila et al., 1995). The functional importance of the disc is highlighted in various TMJ arthropathies especially, when aberrations to its position, morphology, and composition are accompanied by symptoms, which range from joint crepitus and clicking to a limited range of mandibular movements and pain (Haskin et al., 1995; Sato et al., 1997). Several studies have also demonstrated that, subsequent to TMJ arthropathies, the discal tissue presents degenerative changes, which are the result of maladaptation to increased joint loading (Kirk, 1990; Haskin et al., 1995). These degenerative changes are influenced by the type and degree of disc displacement, in that the more it is displaced the more the severe histopathological changes can be observed (Carlsson et al., 1967; Bean et al., 1977; Leonardi et al., 2007).

Several investigations have been published describing the histopathological findings of the degenerated TMJ disc and their relationship with cytokine, growth factors and biomolecular mediators (Paegle et al., 2003; Hamada et al., 2008; Leonardi et al., 2000, 2008; Matsumoto et al., 2008), however, so far, no molecular basis has been identified as a cause for this

degenerative disorder (Luder, 2002) Therefore, the pathology and/or mechanism regarding the development and progression of disc degenerative change, is still not fully understood (Kang et al., 2006). Besides the difficulties encountered by previous investigation in the study of TMJ disease already described (Haskin et al., 1995), there is also the lack of a histopathological score system. Consequently, data analysis has been limited to descriptive or subjective estimates (Paegle et al., 2002). The lack of this score system has represented one of the major obstacles when trying to understand tissue changes at a molecular level and inter-relate the findings from different research teams. To the knowledge of the authors, no study has been devoted to developing a histopathological score to evaluate TMJ disc degeneration and until now no relative literature has been found.

The purpose of this study was to draw up a TMJ disc histopathological score that is a semi-quantitative transcription of the entire spectrum of TMJ disc degenerative diseases related to changes in disc tissue, and then validate the proposed grading, in order to contribute to a standardized histopathological diagnosis.

Materials and methods

Specimens

Sections from sixty-two temporomandibular joint disc specimens from among those stained with Hematoxylin & Eosin (H&E) and affected by tissue degenerative changes were collected from previously studied materials used in our earlier investigations (Leonardi et al., 2000a,b, 2001, 2002a,b, 2003, 2007, 2008). Eight virtually unaffected human TMJ discs (control sample) were studied along with the pathological material. Approval by the Ethics committee and informed consent were obtained for each patient before tissue collection.

The discs affected by degenerative changes (32 from the right TMJ and 30 from the left) were taken from 51 female and 11 male patients, the mean age value of all patients was 37.2 ± 9.4 years. All the selected discs, extirpated during surgery as previously described (Widmark et al., 1997) were not mutilated when removed or incompletely excised or removed in fragments. Every disc was macroscopically deformed. None of them had a normal biconcave shape.

The autopsy specimens (control sample) which were embedded in paraffin, were taken from two male and six female subjects (mean age 49.7 ± 4.4 years). They were selected from among those available at the Anatomy Institute Archives Catania University, Italy, because 1) the clinical history of each subject was negative for generalized joint disease or TMJ arthropathy 2) no macroscopic signs of degenerative or inflammatory joint disease on dissection could be detected, 3) during microscopic examination of sections stained with H&E no pathological changes could be appreciated. Both

patients and autopsy specimen included the anterior and intermediate bands, as well as the posterior disc band.

Histopathological characteristics of the TMJ disc degeneration score

In order to establish principles and proposed standards for the scoring system three items were considered: 1) it has to be simple and reproducible (simplicity); 2) The system should be equally useful for the assessment of both clinical and experimental TMJ disc histopathology models (utility); 3) The histopathology grading system should be capable of being harmonized, eventually, with histological assessment systems from other joints (comparability) (Pritzker et al., 2006). To create the score, a literature search on human TMJ discs with normal appearance and degenerative changes, was carried out and pertinent articles were retrieved. The more frequent histopathological findings were collected, as well those for normal disc appearance. Other grading score systems for degenerative joint changes other than TMJ were also collected and their findings thoroughly examined so as to decide whether or not to include them in the TMJ degeneration score (Pritzker, 1977; Pritzker et al., 2006; Roberts et al., 1989). According to these aforementioned premises, a grading score was designed.

This score takes into account three different pathological disc tissue transformation parameters (collagen bundles, non-specific degenerative changes and the presence of blood vessels).

As regards collagen bundles, in normal human TMJ the disc is composed of superimposed layers of compact bundles of collagen (mainly type I) fibres disposed sagittally and obliquely and alternated with each other (Minarelli and Liberti, 1997). Moreover the organization and function of the collagen fiber system in the human temporomandibular joint disc and its attachments are different according to the disc regions, as demonstrated under the polarizing microscope (Scapino et al., 2006).

In the degenerated disc sample, collagen bundle fragmentation is seen first, while, in the even more degenerated discs tears appear. These latter ones are characterized by defects following the orientation of the collagen fibers bundles. In heavily degenerated discs, splitting can be appreciated. This is defined as a disc fissure of the disc, lined with a layer of cells (Fig. 1). The lining of cells on the inner surface of the split differentiates it from an artifact produced during specimen sectioning (Kurita et al., 1989).

As far as the presence of blood vessels in youngsters and adults is concerned, all the central, posterior and anterior portions of the disc, excluding the posterior (bilaminar zone) and anterior disc attachments are avascular (Yoshida et al., 1998; Paegle et al., 2002). In contrast, a high density of blood vessels is described in disc specimens taken at any stage of internal derangement of the joint (Yoshida et al., 1999; Paegle et al., 2002; Leonardi et al., 2003). Newly formed

A TMJ disc degeneration grading score

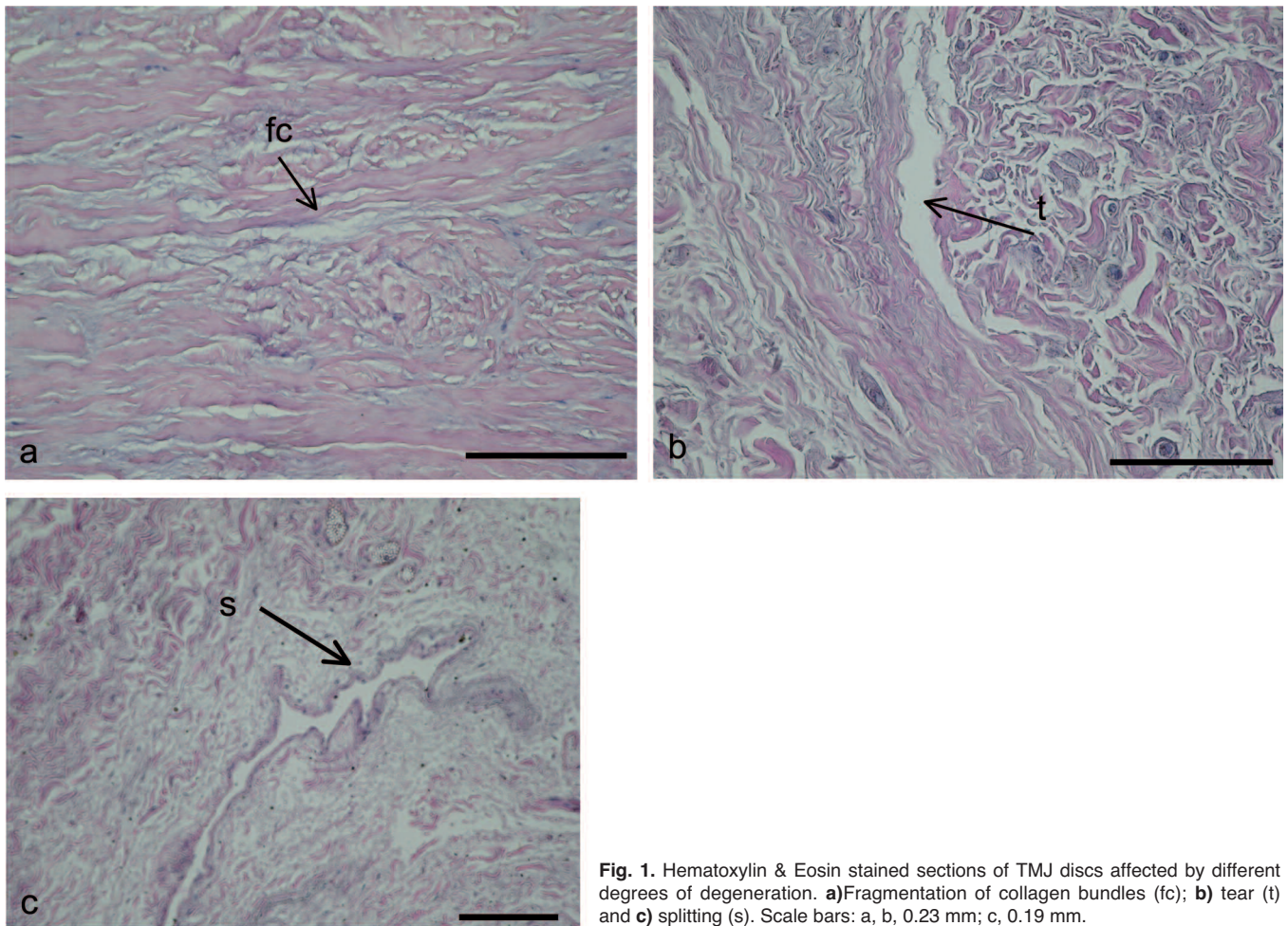


Fig. 1. Hematoxylin & Eosin stained sections of TMJ discs affected by different degrees of degeneration. **a)** Fragmentation of collagen bundles (fc); **b)** tear (t) and **c)** splitting (s). Scale bars: a, b, 0.23 mm; c, 0.19 mm.

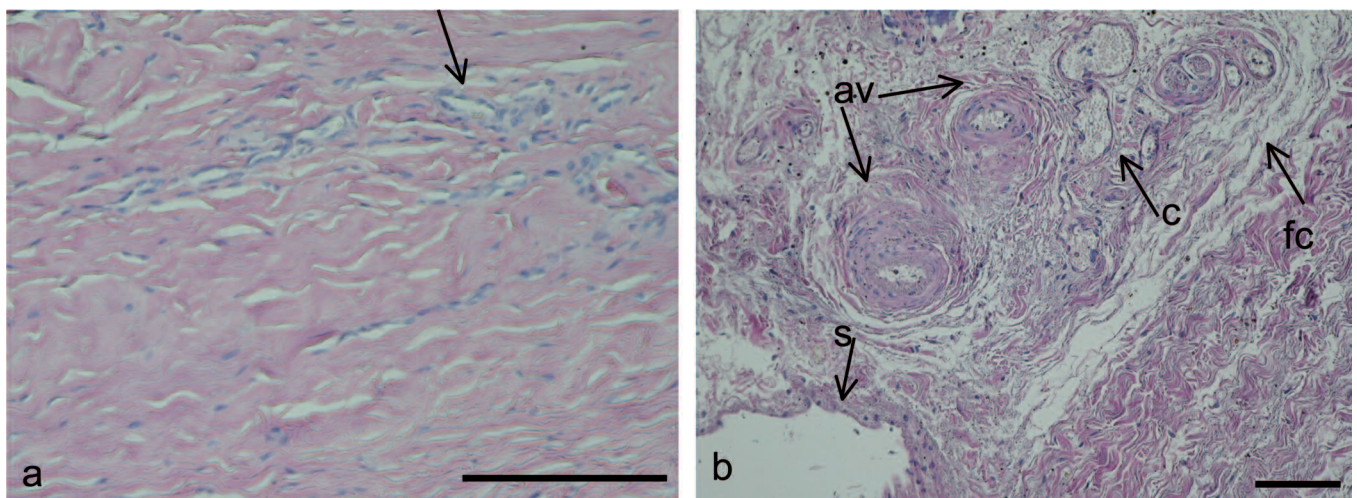


Fig. 2. Hematoxylin & Eosin stained sections of TMJ discs affected by different degrees of degeneration. **a)** an ingrowth of capillaries can be appreciated in a mild degenerated disc tissue; **b)** capillaries, arterioles and venules are detected in severe damaged disc. Scale bar: a, 0.27 mm; b, 0.11 mm

A TMJ disc degeneration grading score

capillaries are observed at first, and arteries and venules become evident as disc degeneration progresses (fig.2).

Non specific degenerative changes (fatty degeneration, calcified areas, hyalinization and chondroid metaplasia) were also included in the degeneration score, as they are very frequently reported in the literature (Kurita et al., 1989; McKay et al., 1992; Luder, 2002; Leonardi et al., 2007).

This grading system results in a score ranging from 0 up to 8 for badly degenerated disc tissue. The parameter values are summarized and interpreted according to Table 1. A score from 0 to 3 was allocated in two of the three categories (Table 1) while the third category contains the 0 to 2 score. These were added together to give a final score out of 8. The three groups were: no/minimal degeneration (degeneration score of 0 or 1), moderate degeneration (score 2-3), and severe degeneration (score 4-8).

Sample scoring

All samples were presented blinded with respect to tissue origin and examined in random order under direct light microscopy by each of the observers. First, each H&E stained section was examined at a 40x magnification to obtain information about the entire section and to determine the extent of lesions present. Secondly, the entire section was examined at a 100x magnification to give more detail of the disc's

appearance. Two observers A and B, with at least 10 years experience in TMJ disc tissue histopathological evaluation, performed the assessment of the TMJ disc H&E stained sections. Each specimen was scored twice by each observer after a minimum interval of 1 week. The mean average of the two scores from each observer was used in whatever analysis was performed.

Statistical analysis

The score values of this score are on an ordinal scale of measurement. Median values and standard deviations were chosen for descriptive statistics. Cohen's kappa was calculated to determine an agreement between the two expert diagnosis. Pearson's correlation coefficient was used to investigate the correlation between the grading results of the two observers. All data were analyzed with the SPSS program (SPSS® release 16.0, Chicago, IL, USA).

Results

The average TMJ disc degeneration score (sum of the scores obtained by the two observers) of the TMJ disc sample was 3.89 ± 1.37 . The mean scores for each observer were very close respectively, 3.90 ± 0.18 and 3.88 ± 0.16 . The Cohen's kappa (percentage of agreement) value obtained was 0.95, which is commonly interpreted as an almost perfect agreement. Also, the Pearson correlation coefficient ($r=0.971$) showed that scores obtained by independent observers were statistically significant.

Discussion

Several articles have described the histopathological anatomy of human TMJ discs (Axelsson et al., 1987; Haskin et al., 1995; Holmlund, 2007; Leonardi et al., 2007, 2008; Matsumoto et al., 2008), but a histopathological degeneration grading score system has not yet been published, even though it is needed. A universally accepted system for the histopathologic grading of degenerative TMJ disc pathological findings is an important prerequisite for the generation of histological, histochemical, and immunohistochemical data in TMJ disc research, data that can be compared by different laboratories. So far, it has been claimed that maintaining a consistent observer performance in the evaluation of TMJ disc histopathology is difficult (Kurita et al., 1989) due to the lack of a validated score system (Hall et al., 1984). As matter of fact, some grading systems have been proposed to quantify the degree of degeneration of intervertebral disc (IVD) (Pritzker, 1977; Roberts et al., 1989), but these cannot be used for the TMJ disc as its anatomy clearly differs from IVD.

Therefore, the present study aimed at introducing, for the first time, a scoring system for TMJ disc

Table 1. Scheme for the histopathological assessment of the features of degenerative TMJ disc changes.

	Collagen bundles
0 points	Preservation of multidirectional collagen bundles
1 point	Altered collagen bundles architecture and/or fragmentation of collagen bundles
2 points	Tears
3 points	Splitting
	Non-specific degenerative changes
0 points	No degeneration
1 point	Fatty degeneration or calcified areas or hyalinization (fibrosis) or chondroid metaplasia
2 points	Two kind of the following: fatty degeneration or calcified areas or hyalinization (fibrosis) or chondroid metaplasia
3 points	3 or more kinds of degenerations
	Degree of vascularization
0 points	Absence
1 point	Capillaries
2 points	Arterioles and venules
Sum 0 or 1	No TMJ disc degeneration
Sum 2-3	Moderate grade of degeneration
Sum 4-8	Severe grade of degeneration

A TMJ disc degeneration grading score

degenerative pathology, in order to correlate disc histopathology clinical, medical and research findings, and so gain a better understanding of this pathology. The TMJ disc degeneration score proposed here focuses on the above histopathological changes because these can be easily identified in routine H&E-stained slides. This proposed system uses an 8 point score system based on a combination of tissue architectural changes.

Cell types and their distribution were not accounted for in our scoring system, as TMJ disc cells are poorly characterized and frequently referred to by various names, (Kapila et al., 1995). Moreover, it seems that there is a heterogeneously distributed subpopulation (Leonardi et al., 2002b; Detamore et al., 2006), whose percentage has not yet been well established in normal or degenerated tissue. In fact, due to the lack of investigation concerning disc cells subpopulation, no universally accepted and objective findings on a morphological basis have been reported in literature. The only morphometric study on degenerated TMJ discs describes an increase of chondrocyte-like cells on ID discs compared to the control, but this was not statistically significant. Another issue with disc cell subpopulation is that their exact quantification requires time and a grid mounted onto the eye piece of an optical microscope (Kurita et al., 1989; Paegle et al., 2002) which is rather time-consuming (Gynther et al., 1998). As far as inflammatory cells are concerned, no significant inflammation has ever been reported in human TMJ disc specimens (Hall et al., 1984; Kurita et al., 1989) contrary to the synovial living (Gynther et al., 1998), thus no score was provided in our grading system, as cellular signs inflammation are not a characteristic of TMJ disc degeneration.

On the other hand, three items were taken into account during the design of our disc degeneration score system, i.e. collagen bundle integrity or damage, degree of neo-vascularization and non specific degenerative changes: i.e. fatty degeneration, calcified areas, hyalinization (fibrosis), and chondroid metaplasia, on the basis that they have been the most frequent findings reported by studies on TMJ disc histopathology and can be easily detected on H & E stained section (Kurita et al., 1989; Leonardi et al., 2001, 2003). Immunohistochemistry which may improve the accuracy of the histologic diagnosis, was not taken into consideration in our score as it cannot be used regularly due to its relatively high cost.

The score presented here shows a very good inter-observer reliability, as the percentage of agreement between the two observers was almost perfect and data were highly consistent. The introduction of the present validated degeneration score system may be of major importance for future research collaboration between different centers so that consensus exists regarding definition and classifications. Moreover, findings from several investigations can be easily compared using this score, with the hope of improving our knowledge of TMJ disc degeneration etiology.

References

- Axelsson S., Fitins D., Hellsing G. and Holmlund A. (1987). Arthrotic changes and deviation in form of the temporomandibular joint--an autopsy study. *Swed. Dent. J.* 11, 195-200.
- Bean L.R., Omnell K.A. and Oberg T. (1977). Comparison between radiologic observations and macroscopic tissue changes in temporomandibular joints. *Dentomaxillofac. Radiol.* 6, 90-106.
- Caltabiano C., Martinez G. and Leonardi R. (1991). Structure and ultrastructure of the human tmj meniscus. *Mondo Ortod.* 16, 145-148.
- Carlsson G.E., Oberg T., Bergman F. and Fajers C.M. (1967). Morphological changes in the mandibular joint disk in temporomandibular joint pain dysfunction syndrome. *Acta Odontol. Scand.* 25, 163-181.
- Detamore M.S., Hegde J.N., Wagle R.R., Almarza A.J., Montufar-Solis D., Duke P.J. and Athanasios K.A. (2006). Cell type and distribution in the porcine temporomandibular joint disc. *J. Oral Maxillofac. Surg.* 64, 243-248.
- Gynther G.W., Dijkgraaf L.C., Reinholt F.P., Holmlund A.B., Liem R.S. and de Bont L.G. (1998). Synovial inflammation in arthroscopically obtained biopsy specimens from the temporomandibular joint: A review of the literature and a proposed histologic grading system. *J. Oral Maxillofac. Surg.* 56, 1281-1286; discussion 1287.
- Hall M.B., Brown R.W. and Baughman R.A. (1984). Histologic appearance of the bilaminar zone in internal derangement of the temporomandibular joint. *Oral Surg. Oral Med. Oral Pathol.* 58, 375-381.
- Hamada Y., Kondoh T., Holmlund A.B., Sakota K., Nomura Y. and Seto K. (2008). Cytokine and clinical predictors for treatment outcome of visually guided temporomandibular joint irrigation in patients with chronic closed lock. *J. Oral Maxillofac. Surg.* 66, 29-34.
- Haskin C.L., Milam S.B. and Cameron I.L. (1995). Pathogenesis of degenerative joint disease in the human temporomandibular joint. *Crit. Rev. Oral Biol. Med.* 6, 248-277.
- Helmy E.S., Timmis D.P., Sharawy M.H., Abdelatif O. and Bays R.A. (1990). Fatty change in the human temporomandibular joint disc. Light and electron microscopy study. *Int. J. Oral Maxillofac. Surg.* 19, 38-43.
- Holmlund A. (2007). Disc derangements of the temporomandibular joint. A tissue-based characterization and implications for surgical treatment. *Int. J. Oral Maxillofac. Surg.* 36, 571-576.
- Kang H., Bao G.J. and Qi S.N. (2006). Biomechanical responses of human temporomandibular joint disc under tension and compression. *Int. J. Oral Maxillofac. Surg.* 35, 817-821.
- Kapila S., Lee C. and Richards D.W. (1995). Characterization and identification of proteinases and proteinase inhibitors synthesized by temporomandibular joint disc cells. *J. Dent. Res.* 74, 1328-1336.
- Kirk W.S. Jr (1990). Morphologic differences between superior and inferior disc surfaces in chronic internal derangement of the temporomandibular joint. *J. Oral Maxillofac. Surg.* 48, 455-460.
- Kurita K., Westesson P.L., Sternby N.H., Eriksson L., Carlsson L.E., Lundh H. and Toremalin N.G. (1989). Histologic features of the temporomandibular joint disk and posterior disk attachment: Comparison of symptom-free persons with normally positioned disks and patients with internal derangement. *Oral Surg. Oral Med. Oral Pathol.* 67, 635-643.
- Leonardi R., Villari L., Piacentini C., Bernasconi G., Baciliero U. and Travali S. (2000a). Cd44 standard form (cd44h) expression and

A TMJ disc degeneration grading score

- distribution in dysfunctional human temporomandibular joint discs. *Int. J. Oral Maxillofac. Surg.* 29, 296-300.
- Leonardi R., Villari L., Bernasconi G., Piacentini C., Baciliero U. and Travali S. (2000b). Cellular S-100 protein immunostaining in human dysfunctional temporomandibular joint discs. *Arch. Oral. Biol.* 45, 411-418.
- Leonardi R., Villari L., Bernasconi G. and Caltabiano M. (2001). Histochemical study of the elastic fibers in pathologic human temporomandibular joint discs. *J. Oral Maxillofac. Surg.* 59, 1186-1192.
- Leonardi R., Caltabiano M., Cascone P. and Loreto C. (2002a). Expression of heat shock protein 27 (hsp27) in human temporomandibular joint discs of patients with internal derangement. *J. Craniofac Surg.* 13, 713-717; discussion 718-720.
- Leonardi R., Villari L., Piacentini C., Bernasconi G., Travali S. and Caltabiano C. (2002b). Immunolocalization of vimentin and alpha-smooth muscle actin in dysfunctional human temporomandibular joint disc samples. *J. Oral Rehabil.* 29, 282-286.
- Leonardi R., Lo Muzio L., Bernasconi G., Caltabiano C., Piacentini C. and Caltabiano M. (2003). Expression of vascular endothelial growth factor in human dysfunctional temporomandibular joint discs. *Arch. Oral Biol.* 48, 185-192.
- Leonardi R., Loreto C., Barbato E., Polimeni A., Caltabiano R. and Lo Muzio L. (2007). A histochemical survey of the human temporomandibular joint disc of patients with internal derangement without reduction. *J. Craniofac. Surg.* 18, 1429-1433.
- Leonardi R., Loreto C., Barbato E., Caltabiano R., Lombardo C., Musumeci G. and Lo Muzio L. (2008). Mmp-13 (collagenase 3) localization in human temporomandibular joint discs with internal derangement. *Acta Histochem.* 110, 314-318.
- Luder H.U. (2002). Factors affecting degeneration in human temporomandibular joints as assessed histologically. *Eur. J. Oral Sci.* 110, 106-113.
- Marchetti C., Cornaglia I., Casasco A., Bernasconi G., Baciliero U. and Stetler-Stevenson W.G. (1999). Immunolocalization of gelatinase-a (matrix metalloproteinase-2) in damaged human temporomandibular joint discs. *Arch. Oral Biol.* 44, 297-304.
- Matsumoto T., Tojyo I., Kiga N., Hiraishi Y. and Fujita S. (2008). Expression of adamts-5 in deformed human temporomandibular joint discs. *Histol. Histopathol.* 23, 1485-1493.
- McKay G.S., Yemm R. and Cadden S.W. (1992). The structure and function of the temporomandibular joint. *Br. Dent. J.* 173, 127-132.
- Minarelli A.M. and Liberti E.A. (1997). A microscopic survey of the human temporomandibular joint disc. *J. Oral Rehabil.* 24, 835-840.
- Paegle D.I., Holmlund A.B. and Reinholt F.P. (2002). Characterization of tissue components in the temporomandibular joint disc and posterior disc attachment region: Internal derangement and control autopsy specimens compared by morphometry. *J. Oral Maxillofac. Surg.* 60, 1032-1037.
- Paegle D.I., Holmlund A.B. and Hjerpe A. (2003). Matrix glycosaminoglycans in the temporomandibular joint in patients with painful clicking and chronic closed lock. *Int. J. Oral Maxillofac. Surg.* 32, 397-400.
- Pritzker K.P. (1977). Aging and degeneration in the lumbar intervertebral disc. *Orthop. Clin. North. Am.* 8, 66-77.
- Pritzker K.P., Gay S., Jimenez S.A., Ostergaard K., Pelletier J.P., Revell P.A., Salter D. and van den Berg W.B. (2006). Osteoarthritis cartilage histopathology: Grading and staging. *Osteoarthritis Cartilage* 14, 13-29.
- Roberts S., Menage J. and Urban J.P. (1989). Biochemical and structural properties of the cartilage end-plate and its relation to the intervertebral disc. *Spine (Phila Pa 1976)* 14, 166-174.
- Sato S., Goto S., Kawamura H. and Motegi K. (1997). The natural course of nonreducing disc displacement of the tmj: Relationship of clinical findings at initial visit to outcome after 12 months without treatment. *J. Orofac. Pain* 11, 315-320.
- Scapino R.P., Obrez A. and Greising D. (2006). Organization and function of the collagen fiber system in the human temporomandibular joint disk and its attachments. *Cells Tissues Organs* 182, 201-225.
- Widmark G., Dahlstrom L., Kahnberg K.E. and Lindvall A.M. (1997). Discectomy in temporomandibular joints with internal derangement: A follow-up study. *Oral Surg. Oral Med. Oral Pathol. Oral Radiol. Endod.* 83, 314-320.
- Yoshida A., Higuchi Y., Kondo M., Tabata O. and Ohishi M. (1998). Range of motion of the temporomandibular joint in rheumatoid arthritis: Relationship to the severity of disease. *Cranio* 16, 162-167.
- Yoshida H., Fujita S., Nishida M. and Iizuka T. (1999). Angiogenesis in the human temporomandibular joint studied by immunohistochemistry for cd34 antigen. *J. Oral Pathol. Med.* 28, 289-292.