

# Morphometric study of healthy jejunal and ileal mucosa in adult and aged subjects

Jasna B. Trbojević-Stanković<sup>1</sup>, Novica M. Milićević<sup>2</sup>, Dragoslav P. Milošević<sup>3</sup>,  
Nebojša Despotović<sup>3</sup>, Mladen Davidović<sup>3</sup>, Predrag Erceg<sup>3</sup>, Božidar Bojić<sup>4</sup>, Danijela Bojić<sup>4</sup>,  
Petar Svorcan<sup>4</sup>, Marijana Protić<sup>4</sup>, Branka Dapčević<sup>4</sup>, Miloš D. Miljković<sup>2</sup> and Živana Milićević<sup>2</sup>

<sup>1</sup>Clinical-Hospital Center "Dr Dragiša Mišović", Belgrade, Serbia, <sup>2</sup>Institute of Histology and Embryology, Faculty of Medicine, University of Belgrade, Belgrade, Serbia, <sup>3</sup>Department of Geriatrics, Zvezdara University Clinical Center, Belgrade, Serbia and <sup>4</sup>Center for Gastroenterology and Hepatology, Zvezdara University Clinical Center, Belgrade, Serbia

**Summary.** Small intestine mucosa is often affected with malabsorptive, autoimmune and inflammatory pathological processes. However, morphometric data on the healthy human small intestine mucosa, especially ileum, are scarce. We aimed to obtain histoquantitative data on the healthy jejunal and ileal mucosa and assess the effects of gender and ageing on these parameters. Computer-aided morphometric analysis was performed on 24 jejunal and 25 ileal biopsy samples collected upon routine endoscopy screening of healthy persons with a family history of intestinal malignancy. Subjects were distributed in four groups according to age and sex: adult (<60 years) and elderly (>60 years) males, and adult (<60 years) and elderly (>60 years) females. Results were statistically analyzed with Mann-Whitney U test. Jejunal mucosal thickness was significantly reduced in elderly subjects ( $p<0.05$ ), especially in elderly females compared to adult ones ( $p<0.05$ ). Jejunal villi were significantly wider in adult than in the elderly subjects ( $p<0.05$ ), whereas ileal villi were significantly wider in elderly compared to adult subjects ( $p<0.01$ ) and in male compared to female subjects ( $p<0.05$ ). No statistically significant differences were found in other histoquantitative parameters (mucosa epithelium height, crypt numerical density, villous height, crypts and villous perimeter, diameter and epithelium height) of jejunal and ileal mucosa. This study provides complete morphometric data on the healthy human jejunum and the first relevant data on the healthy ileal mucosa, thus representing a valuable morphometric reference for future histoquantitative studies of human small bowel mucosa in both healthy and disease affected individuals.

**Key words:** Morphometry, Jejunal mucosa, Ileal mucosa, Age, Gender, Human

## Introduction

The small intestinal mucosa is frequently affected with malabsorptive, autoimmune and inflammatory pathological processes. Morphology and morphometry of pathologically altered tissue has been dealt with in a number of studies (Rosenkrans et al., 1980; Shidrawi et al., 1994; Pires et al., 2003; Corazza and Villanacci, 2005). In contrast to that, there is a notable lack of information on the quantitative characteristics of healthy human small bowel mucosa. Especially rare are studies on the structural and histoquantitative characteristics of ileum. On the other hand, the few morphometric studies of jejunal mucosa either used a rather small sample of healthy intestinal tissue (Riecken et al., 1976; Warren et al., 1978; Bode et al., 1982), or the normality of this tissue was subjectively assessed (Corazza et al., 1985).

Previous studies have shown a number of age-related structural changes in many tissues and organs, including the small bowel mucosa (Webster and Leeming, 1975; Warren et al., 1978; Ciccocioppo et al., 2002; Pieperhoff et al., 2008). Still, a direct effect of ageing in reducing mucosal surface area and in other structural alterations of the small intestine remains to be disputed (Corazza et al., 1986). These alterations may possibly be further influenced by sex-related factors, but we found no data on this subject in scientific literature.

Therefore, we aimed to analyze the specimens of healthy small intestinal mucosa using computer-aided morphometric analysis in order to provide reference data for future histoquantitative studies of pathologically altered ileum and jejunum. Furthermore, we assessed the

effects of gender and ageing on the histoquantitative parameters of healthy jejunal and ileal mucosa.

## **Materials and methods**

### *Tissue samples*

Tissue specimens (24 jejunal and 25 ileal) were collected upon routine endoscopy screening of 49 healthy persons with a family history of intestinal malignancy. Biopsies were performed at the Center for Gastroenterology and Hepatology, Zvezdara Clinical Center, Belgrade, Serbia. All subjects gave informed consent prior to their inclusion in the study. Sampling was performed in accordance with ethical standards laid down in the Declaration of Helsinki and approved by the Ethics Committee of the Zvezdara Clinical Center (03/11/2003).

Samples of jejunum were obtained from 8 adult males (mean age 42.37 years), 5 adult females (mean age 46 years), 4 elderly males (mean age 77.17 years) and 7 elderly females (mean age 72 years). Samples of ileum were taken from 5 adult males (mean age 45.6 years), 8 adult females (mean age 48.37 years), 9 elderly males (mean age 73.2 years) and 3 elderly females (mean age 70.67 years). Subjects younger than 60 were grouped as "adult", and those over 60 as "elderly". All subjects were well-nourished and none had malabsorption.

### *Tissue preparation and morphometric analysis*

The biopsies were fixed for 24 hours in neutral buffered formalin and processed to Paraplast. Serial sections of tissue samples (3-5  $\mu\text{m}$  thick) were made. From each biopsy sample the 1st and 6th section were stained with hematoxylin-eosin and used for morphometric analysis. The sections were inspected under an Opton Photomicroscope III (Carl Zeiss AG, Oberkochen, Germany). Morphometric analysis was performed on microphotographs acquired with an Olympus C3030-Z digital camera (Olympus Deutschland GmbH, Hamburg, Germany) coupled with a microscope and a computer.

Tissue elements of ileal and jejunal mucosa were manually traced on the microphotographs projected on a computer screen and directly measured using the computer-aided image analysis software Analysis 3.1 (Soft Imaging System GmbH, Münster, Germany). The number of measurements for each parameter of each section (given in brackets below) was determined according to the basic principles of morphometry (Weibel, 1979) and earlier morphometric studies of the human intestine (Pires et al., 2003; Kelly et al., 2004; Milošević et al., 2007). The following small intestinal mucosa parameters were studied at 100x magnification on strictly longitudinally sectioned crypts and villi: mucosal height (3), villous height (10), villous maximum width (10), depth of the crypts (6) and crypt

density (the number of crypts per 0.1  $\text{mm}^2$  of tissue) (10). Villous/crypt ratio was calculated subsequently from villous height and crypt depth results. Surface epithelium height (6) and diameter (6), perimeter (6) and epithelium height of the crypts (6), as well as diameter (6), perimeter (6) and epithelium height of the villi (6), were measured at 250x magnification. These crypt and villi parameters were determined from tissue samples with strictly cross-sectioned crypts and villi. Morphometric analysis was performed by a single investigator, blind to the age and gender of the subject.

### *Statistical analysis*

Means and standard deviations were calculated for each parameter. Results were statistically analyzed with Mann-Whitney U test with SPSS for Windows 12.0 (SPSS Inc., Chicago, IL, USA).

## **Results**

All tissue elements of the jejunal (Figures 1, 2) and ileal (Figures 3, 4) mucosa were easily distinguished, enabling precise measurement of all selected parameters in all groups of patients.

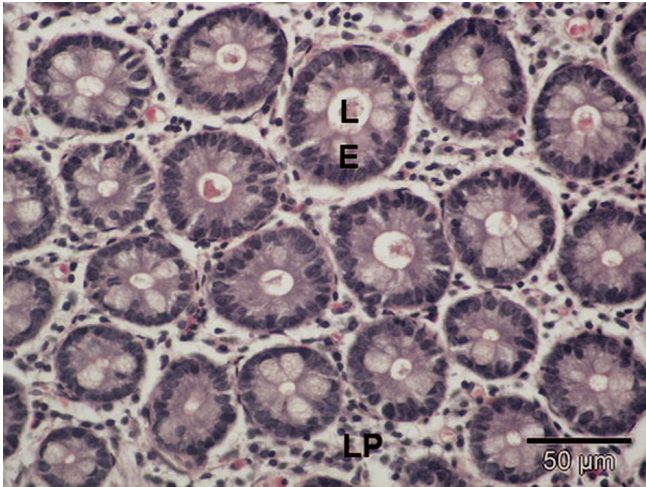
### *Morphometric characteristics of the jejunum*

Jejunal mucosal thickness was significantly reduced in elderly subjects ( $p < 0.05$ ), especially in elderly females compared to adult ones ( $p < 0.05$ ), as shown in Table 1. Adult subjects had larger crypt diameter and perimeter than the elderly (Table 2). The crypt epithelium showed a tendency to be higher in adult subjects ( $p = 0.05$ ) (Table 2). The crypts were deeper in adult subjects than in the elderly (Table 1). Male subjects of all ages had higher crypt density than female subjects (Table 1). Villous height was similar in elderly subjects (Table 1). The same was true for villous perimeter and diameter (Table 2). Adult subjects had significantly wider villi than the elderly ( $p < 0.05$ ) (Table 1). Villous epithelium (Table 2), as well as mucosal surface epithelium (Table 1), were of similar height in all groups.

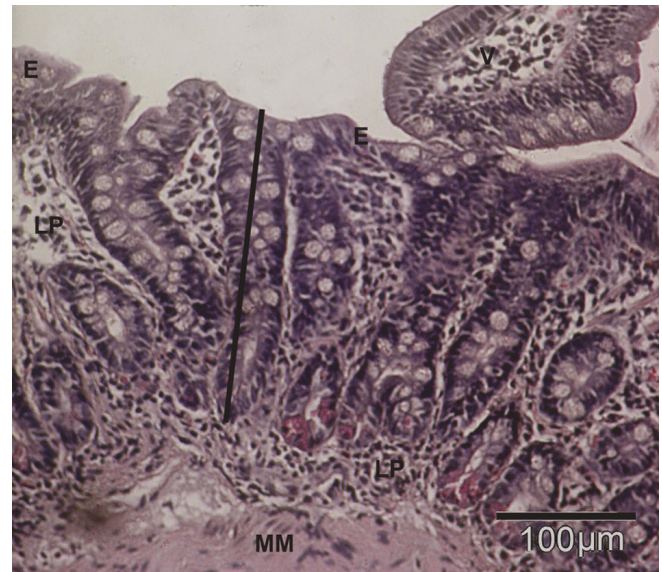
### *Morphometric characteristics of the ileum*

In elderly females higher crypt density was accompanied by smaller crypt size, as represented by crypt diameter, perimeter and epithelium height (Tables 3, 4). The crypts were deeper in female than in male subjects of all ages (Table 3). Villous perimeter, diameter and epithelial height were higher in male than in female subjects (Table 4). Villi were significantly wider in elderly compared to adult subjects ( $p < 0.01$ ) and in female compared to male subjects ( $p < 0.05$ ) (Table 3). No statistically significant differences were found in other investigated morphometric parameters of the ileum.

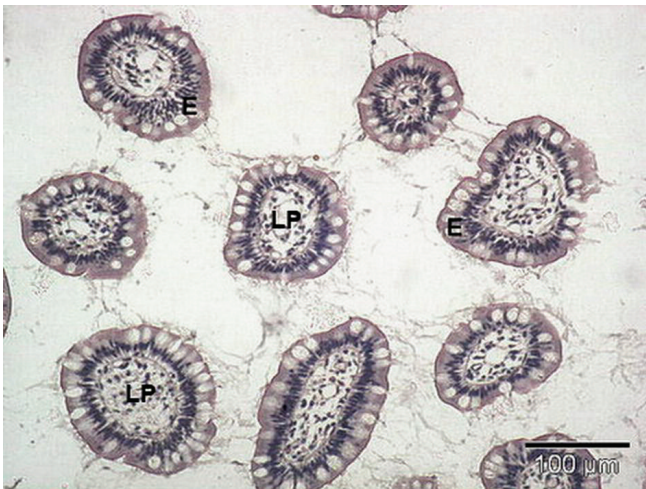
## Morphometry of healthy jejunum and ileum



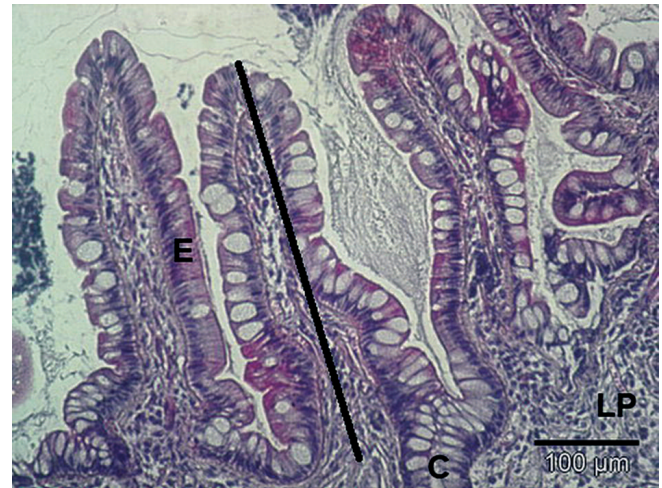**Fig. 1.** Transverse section of the crypts in the jejunal mucosa of a healthy adult male. L: lumen of the crypt; E: epithelium of the crypt; LP: lamina propria. Hematoxylin-eosin.



**Fig. 2.** Longitudinal section of the crypts in the jejunal mucosa of a healthy adult female. MM: muscularis mucosae; LP: lamina propria; V: villus; E: surface epithelium; Line: crypt depth. Hematoxylin-eosin.



**Fig. 3.** Transverse section of the ileal villi of a healthy adult female. E: villous epithelium; LP: lamina propria. Hematoxylin-eosin.



**Fig. 4.** Longitudinal section of the ileal villi of a healthy adult male. E: villous epithelium, LP: lamina propria; C: crypt; Line: vilous height. Hematoxylin-eosin.

**Table 1.** Histoquantitative parameters of the jejunal mucosa in adult and aged healthy subjects.

	Adult males	Elderly males	Adult females	Elderly females
Mucosal height (μm)	283.10±5.18**	221.53±0.00**	417.60±64.86*,**	258.57±44.67*,**
Number of crypts (per 0.1 mm <sup>2</sup> )	12.57±6.43	12.95±0.00	8.22±3.87	6.96±1.16
Crypt depth (μm)	141.28±6.979	80.19±0.00	176.13±9.40	154.03±0.00
Villous height (μm)	356.85±19.45	310.95±45.51	415.45±149.83	366.97±92.08
Villous maximum width (μm)	150.43±3.17**	119.45±21.94**	167.68±24.95**	127.62±26.66**
Villous/crypt ratio	2.31±0.06	-	2.60±1.22	3.16±0.00
Surface epithelium height (μm)	32.05±3.57	27.67±9.89	28.55±10.77	28.14±2.68

\*: adult vs. elderly females p<0.05; \*\*: adult vs. elderly subjects p<0.05

## Morphometry of healthy jejunum and ileum

**Table 2.** Histoquantitative parameters of the jejunal crypts and villi in adult and aged healthy subjects.

	Adult males	Elderly males	Adult females	Elderly females
Crypt perimeter ( $\mu\text{m}$ )	160.10 $\pm$ 25.45	152.39 $\pm$ 25.90	159.13 $\pm$ 22.55	145.09 $\pm$ 7.70
Crypt diameter ( $\mu\text{m}$ )	49.43 $\pm$ 8.36	47.56 $\pm$ 9.10	48.20 $\pm$ 6.92	44.09 $\pm$ 3.00
Crypt epithelial height ( $\mu\text{m}$ )	18.00 $\pm$ 2.08*	16.78 $\pm$ 2.27*	18.94 $\pm$ 3.04*	16.37 $\pm$ 0.63*
Villous perimeter ( $\mu\text{m}$ )	532.08 $\pm$ 113.85	485.95 $\pm$ 74.60	517.37 $\pm$ 160.72	490.48 $\pm$ 60.52
Villous diameter ( $\mu\text{m}$ )	157.33 $\pm$ 39.87	142.84 $\pm$ 1.16	165.49 $\pm$ 36.52	131.89 $\pm$ 30.87
Villous epithelial height ( $\mu\text{m}$ )	28.60 $\pm$ 4.90	30.28 $\pm$ 2.42	31.07 $\pm$ 0.61	29.69 $\pm$ 2.16

\* adult vs. elderly subjects  $p=0.05$

**Table 3.** Histoquantitative parameters of the ileal mucosa in adult and aged healthy subjects.

	Adult males	Elderly males	Adult females	Elderly females
Mucosal height ( $\mu\text{m}$ )	279.34 $\pm$ 132.48	266.81 $\pm$ 0.00	-	230.13 $\pm$ 73.90
Number of crypts (per 0.1 $\text{mm}^2$ )	4.36 $\pm$ 2.71	5.10 $\pm$ 3.94	5.50 $\pm$ 4.61	6.79 $\pm$ 5.15
Crypt depth ( $\mu\text{m}$ )	132.33 $\pm$ 7.84	164.48 $\pm$ 26.57	219.17 $\pm$ 67.29	204.44 $\pm$ 0.00
Villous height ( $\mu\text{m}$ )	273.08 $\pm$ 128.55	332.06 $\pm$ 57.6	325.82 $\pm$ 33.52	240.26 $\pm$ 0.00
Villous maximum width ( $\mu\text{m}$ )	106.75 $\pm$ 0.00*,**	142.18 $\pm$ 24.14*,**	112.15 $\pm$ 13.90*,**	194.96 $\pm$ 0.00*,**
Villous/crypt ratio	1.43 $\pm$ 0.00	1.90 $\pm$ 0.14	1.66 $\pm$ 0.54	1.17 $\pm$ 0.00
Surface epithelium height ( $\mu\text{m}$ )	35.2 $\pm$ 2.97	28.15 $\pm$ 6.05	33.78 $\pm$ 5.94	32.78 $\pm$ 2.33

\*: adult vs. elderly subjects  $p<0.05$ ; \*\*: males vs. females  $p<0.05$

**Table 4.** Histoquantitative parameters of the ileal crypts and villi in adult and aged healthy subjects.

	Adult males	Elderly males	Adult females	Elderly females
Crypt perimeter ( $\mu\text{m}$ )	177.34 $\pm$ 39.85	189.53 $\pm$ 31.70	187.20 $\pm$ 58.64	166.36 $\pm$ 24.06
Crypt diameter ( $\mu\text{m}$ )	49.91 $\pm$ 8.18	51.87 $\pm$ 7.93	51.23 $\pm$ 17.66	48.28 $\pm$ 5.38
Crypt epithelial height ( $\mu\text{m}$ )	20.68 $\pm$ 1.53	20.10 $\pm$ 3.27	19.16 $\pm$ 3.71	18.56 $\pm$ 1.41
Villous perimeter ( $\mu\text{m}$ )	549.32 $\pm$ 133.73	485.90 $\pm$ 93.43	476.38 $\pm$ 67.56	475.75 $\pm$ 22.56
Villous diameter ( $\mu\text{m}$ )	160.04 $\pm$ 23.61	147.09 $\pm$ 10.59	132.49 $\pm$ 19.85	138.12 $\pm$ 9.36
Villous epithelial height ( $\mu\text{m}$ )	31.21 $\pm$ 2.95	31.45 $\pm$ 5.81	29.26 $\pm$ 3.61	26.54 $\pm$ 4.01

## Discussion

This study provides morphometric data on all elements of the normal human jejunal and ileal mucosa. In the literature, the morphometric parameters of the normal human small bowel are very few, probably due to low availability of this tissue. To this end, we used the intestinal tissues obtained from carefully selected patients who were subjected to routine endoscopy screening because of the family history of intestinal malignancy and in whom pathological alterations were not discovered.

Small intestine mucosa is often affected with malabsorptive, autoimmune and inflammatory pathological processes. Some of these disorders, namely coeliac disease, require histological evaluation for final diagnosis and monitoring in response to therapy

(Corazza and Villanacci, 2005). However, descriptive observations based on visual assessment of the mucosal biopsy are not sufficient and measurements are necessary (Slavin et al., 1980). Morphometric data on the healthy human small intestine mucosa are very infrequent, thus also raising the question of reference values with which the measures of pathologically altered tissue could be compared. Defining these reference values would facilitate the diagnosis of initial, subtle changes in tissue geometry, at an early stage of the disease. Furthermore, as it is well known that age and sex may affect the structural features and morphometric parameters of tissues and organs (Warren et al., 1978), we defined the appropriate groups of subjects that enabled us to investigate the influence of these factors.

Elderly subjects in our study, regardless of sex, had similar villous height, villous maximum width and

mucosal epithelial height to those in the study by Webster and Leeming (1975). However, our elderly subjects had thicker jejunal mucosa (251.16  $\mu\text{m}$ ) than those in the study by Webster and Leeming (143  $\mu\text{m}$ ) (1975). Earlier, we discovered only minor morphometric changes of the rectal mucosa in elderly healthy subjects (Milošević et al, 2007), which is in accordance with the prevailing view regarding the colon (Banning, 2008). This is in very good agreement with the data obtained in this study regarding the small intestine, as well as with the results of Corazza et al. (1986) who did not show any reduction of jejunal surface area as a consequence of age. In line with this, no evidence was found for a significant effect of age on duodenal morphometry (Giacosa, 1989; Lipski et al., 1992).

Considering the paucity of morphometric data on the normal human small intestine, it is not surprising that the information on the influence of gender is lacking in the literature. Our study represents a rare contribution which shows that morphometric parameters of small intestine are not related with the gender. However, a significant decrease in jejunal mucosal height was observed in elderly females. Whether this finding could be related to the intestinal pathology, which is more frequent in elderly female subjects (Alonso and Santos 2009; Holt, 2001), remains to be further investigated.

Our results of jejunal morphometry corresponded well with some rare data from other authors (Webster and Leeming, 1975; Slavin et al., 1980; Penna et al., 1981; Bennett et al., 1985). Healthy adults in our study, regardless of sex, had mean villous height within the range of those reported by Penna et al. (1981). The mean crypt depth in adult subjects in our study corresponded well with the results from Bennett et al. (1985) and Penna et al. (1981). Furthermore, villous/crypt ratio in adults included in our study is in accordance with those recorded by Penna et al. (1981). It should be emphasized, however, that measurements in the studies by Bennett et al. (1985) and Penna et al. (1981) were performed by calibrating the readings against a standard graticule, while we used a much more sophisticated computer-assisted technique. Slavin et al. (1980) used a similar computer-assisted measuring technique to ours. In their study, the image was traced manually with a light pen on the monitor screen and then measured automatically. However, they defined neither the age nor the sex of the investigated subjects in their study and have chosen to measure mucosal thickness as the distance between the upper border of the muscularis mucosae and the tip of the villi, whereas we opted to define mucosal thickness as the distance between muscularis mucosae and the villus/crypt junction, as described by Pires et al. (2003). These may be the reasons for the notable difference between mean mucosal thickness in our study group (307.48  $\mu\text{m}$  for all subjects, regardless of age and sex) and that reported by Slavin et al. (426.4  $\mu\text{m}$ ) (1980).

To the best of our knowledge, there is only one report on the morphometric characteristics of ileal

mucosa in the available scientific literature. However, this research (Solhaug, 1976) included a rather small number of subjects – 5 experimental and 10 controls. Furthermore, 14 of the 15 subjects were females, and none was older than 52. The results presented in our study, therefore, may be considered as the first relevant data on this subject.

In conclusion, this study provides complete morphometric data on the healthy human jejunum and the first relevant data on the healthy ileal mucosa, thus representing a valuable morphometric reference for future histoquantitative studies of human small bowel mucosa in both healthy and disease affected individuals.

---

*Acknowledgements.* Thanks are due to Jovanka Ognjanović for technical assistance. Opton Photomicroscope III, Olympus C3030-Z digital camera and Analysis 3.1 software were kindly donated to Novica M. Milićević by Alexander von Humboldt-Foundation, Bonn, Germany. This study was supported by the Ministry of Science and Technological Development of the Republic of Serbia (grant no. 145016).

---

## References

- Alonso C. and Santos J. (2009). A closer look at mucosal inflammation in irritable bowel syndrome: sex- and gender-related disparities-- quantity, quality, or both? *Am. J. Gastroenterol.* 104, 401-403.
- Banning M. (2008). Ageing and the gut. *Nurs. Older People* 20, 17-21.
- Bennett M.K., Sachdev G.K., Jewell D.P. and Anand B.S. (1985). Jejunal mucosal morphology in healthy north Indian subjects. *J. Clin. Pathol.* 38, 368-371.
- Bode J.C., Kruppel H., Schwerk W., Lorenz-Meyer H. and Durr H.K. (1982). Quantitative histomorphometric study of the jejunal mucosa in chronic alcoholics. *Digestion* 23, 265-270.
- Ciccocioppo R., Di Sabatino A., Luinetti O., Rossi M., Cifone M.G. and Corazza G.R. (2002). Small bowel enterocyte apoptosis and proliferation are increased in the elderly. *Gerontology* 48, 204-208.
- Corazza G.R. and Villanacci V. (2005). Coeliac disease. *J. Clin. Pathol.* 58, 573-574.
- Corazza G.R., Frazzoni M., Dixon M.F. and Gasbarrini G. (1985). Quantitative assessment of the mucosal architecture of jejunal biopsy specimens: a comparison between linear measurement, stereology and computer aided microscopy. *J. Clin. Pathol.* 38, 765-770.
- Corazza G.R., Frazzoni M., Gatto M.R. and Gasbarrini G. (1986). Ageing and small-bowel mucosa: a morphometric study. *Gerontology* 32, 60-65.
- Giacosa A. (1989). Morphometry of normal duodenal mucosa. *Scand. J. Gastroenterol.* 24 (S167), 10-12.
- Holt P.R. (2001). Diarrhea and malabsorption in the elderly. *Gastroenterol. Clin. North. Am.* 30, 427-444.
- Kelly P., Menzies I., Crane R., Zulu I., Nickols C., Feakins R., Mwansa J., Mudenda V., Katubulushi M., Greenwald S. and Farthing M. (2004). Responses of small intestinal architecture and function over time to environmental factors in a tropical population. *Am. J. Trop. Med. Hyg.* 70, 412-419.
- Lipski P.S., Bennett M.K., Kelly P.J. and James O.F. (1992). Ageing and duodenal morphometry. *J. Clin. Pathol.* 45, 450-452.
- Milošević P.D., Trbojević J., Milićević N.M., Bojić D., Davidović M.,

*Morphometry of healthy jejunum and ileum*

- Svorcan P., Dapčević B., Bojić B., Mihajlović G. and Milićević Ž. (2007). A quantitative morphometric study of rectal mucosa in adult and aged healthy subjects. *Histol. Histopathol.* 22, 433-436.
- Penna F.J., Hill I.D., Kingston D., Robertson K., Slavin G. and Shiner M. (1981). Jejunal mucosal morphometry in children with and without gut symptoms and in normal adults. *J. Clin. Pathol.* 34, 386-392.
- Pieperhoff P., Hömke L., Schneider F., Habel U., Shah N.J., Zilles K. and Amunts K. (2008). Deformation field morphometry reveals age-related structural differences between the brains of adults up to 51 years. *J. Neurosci.* 28, 828-842.
- Pires A.L.G., da Silveira T.R. and da Silva V.D. (2003). Digital morphometric and stereologic analysis of small intestinal mucosa in well-nourished and malnourished children with persistent diarrhea. *J. Pediatr. (Rio J.)* 79, 329-336.
- Riecken E.O., Sahlfeld M. and Lorenz-Meyer H. (1976). Quantification of the three-dimensional structure of jejunal mucosa in healthy subjects and patients with coeliac disease. *Dtsch. Med. Wochenschr.* 101, 51-53.
- Rosenkrans P.C., Meijer C.J., Cornelisse C.J., van der Wal A.M. and Lindeman J. (1980). Use of morphometry and immunohistochemistry of small intestinal biopsy specimens in the diagnosis of food allergy. *J. Clin. Pathol.* 33, 125-130.
- Shidrawi E.G., Przemioslo R., Davies D.R., Tighe M.R. and Ciclitira P.J. (1994). Pitfalls in diagnosing coeliac disease. *J. Clin. Pathol.* 47, 693-694.
- Slavin G., Sowter C., Robertson K., McDermott S. and Paton K. (1980). Measurement in jejunal biopsies by computer-aided microscopy. *J. Clin. Pathol.* 33, 254-261.
- Solhaug J.H. (1976). Morphometric studies of the small intestine following jejuno-ileal shunt operation. *Scand. J. Gastroent.* 11, 155-160.
- Warren P.M., Pepperman M.A. and Montgomery R.D. (1978). Age changes in small-intestinal mucosa. *Lancet* 312, 849-850.
- Webster S.G.P. and Leeming J.T. (1975). The appearance of the small bowel mucosa in old age. *Age Ageing* 4, 168-174.
- Weibel E.R. (1979) *Practical methods for biological morphometry*. Vol. 1. Academic Press. New York.

Accepted August 4, 2009