

# Nicotinamide N-Methyltransferase upregulation correlates with tumour differentiation in oral squamous cell carcinoma

Monica Emanuelli<sup>1</sup>, Andrea Santarelli<sup>2</sup>, Davide Sartini<sup>1</sup>, Domenico Ciavarella<sup>3</sup>,  
Valentina Rossi<sup>1</sup>, Valentina Pozzi<sup>1</sup>, Corrado Rubini<sup>4</sup> and Lorenzo Lo Muzio<sup>3</sup>

<sup>1</sup>Department of Biochemistry, Biology and Genetics, Polytechnic University of Marche, Ancona, Italy, <sup>2</sup>Institute of Dentistry and Stomatological Sciences, Polytechnic University of Marche, Ancona, Italy, <sup>3</sup>Department of Surgical Sciences, University of Foggia, Foggia, Italy and <sup>4</sup>Department of Neurosciences, Section of Pathological Anatomy and Histopathology, Polytechnic University of Marche, Ancona, Italy

**Summary.** We investigated expression levels of Nicotinamide N-Methyltransferase (NNMT), an enzyme involved in the biotransformation of many drugs and xenobiotic compounds, in oral squamous cell carcinoma (OSCC). Measurements were performed by immunohistochemistry and the relationship between tumour characteristics and NNMT levels in OSCC was studied to evaluate the effectiveness of NNMT as a prognostic marker in squamous cell carcinoma of the oral cavity. In conclusion, the present study suggests that NNMT may have potential as a biomarker and as a therapeutic target for OSCC.

**Key words:** Nicotinamide N-Methyltransferase, Oral squamous cell carcinoma, Prognostic marker

## Introduction

Oral squamous cell carcinoma (OSCC) is the most frequent malignant tumour of the oral cavity, with about 30,000 new cases and 8,000 related deaths per year in the United States. Despite refinement of surgical techniques and adjuvant therapies, the mortality rate of OSCC has shown little improvement over the last three decades, the overall five-year survival of these patients remaining less than 50%, and the diagnostic delay seems to be responsible for the poor prognosis of patients with OSCC (Brickman and Wong, 2006).

Because traditional clinical methods lack sensitivity

to detect OSCC at an early time point, the identification of reliable and clinically applicable markers through gene expression profiling is essential to predict the aggressiveness of tumours and disease outcome. In fact, recent studies have shown that each case possesses its own biological characteristics, clinical behaviour, and, by extension, unique sensitivity to therapy (Carinci et al., 2005).

Currently, deregulation of the cell cycle, apoptosis and cell-cell/cell-matrix adhesions are considered the main events in OSCC tumorigenesis, and several genes related to these pathways are being evaluated for their potential as prognostic factors (Lo Muzio et al., 2005, 2006; Tomioka et al., 2006; Ueda et al., 2006).

We wished to focus on the expression of genes critical in the drug metabolism process, in particular Nicotinamide N-Methyltransferase (NNMT), which encodes an enzyme belonging to Phase II Metabolizing Enzymes and is involved in the biotransformation and detoxification of many xenobiotics (Rini et al., 1990; Aksoy et al., 1994, 1995).

In fact, the metabolism of drugs, toxic chemicals, hormones and micronutrients is often implicated in many diseases and pathophysiological processes, such as cancer and resistance to chemotherapy (Szakacs et al., 2004).

To explore the role played by NNMT in OSCC, in the present study we analysed enzyme expression in oral squamous cell carcinoma specimens obtained at surgery by immunohistochemistry. The relationship between clinicopathological findings and NNMT tumour expression was analysed to evaluate the effectiveness of NNMT as a prognostic marker in oral squamous cell carcinoma.

## Materials and methods

### Case selection

A total of 92 patients, who were referred for OSCC at our institution between April 1990 and May 2005, were analysed in this study. The study population consisted of 53 men and 39 women with a mean age of 68 years (range, 48-92 years); 41 cases were stage I, 13 stage II, 14 stage III, and 24 stage IV. The histopathological grading was assessed on paraffin H&E-stained sections. Tumour extent was classified according to the TNM system by the UICC 2000 classification (Union Internationale Contre le Cancer) [UICC 2000] and tumors were classified as grade 1, 2, or 3, according to the WHO classification of histological differentiation. Twenty-nine of the 92 patients had metastasis to regional lymph nodes. All patients were analysed for survival rates. Survival was calculated from the date of surgery to the date of the latest clinical follow-up or death by disease. Patients who died of postoperative complications were excluded from the study. None of the patients had been treated previously. They received surgical treatment with curative intention. No patient had multicentric lesions.

Fifty-one paraffin-embedded specimens of healthy oral mucosa were obtained from patients who had undergone routine oral surgical procedures, with the informed consent of the donors, and were evaluated as a control group.

All the samples were collected as per the institutional committee guidelines. Table 1 lists the clinico-pathological findings of the patients.

### Immunohistochemical analyses

Four- $\mu$ m serial sections from formalin-fixed, paraffin-embedded blocks of representative tumor areas were cut for each case. Only sections containing sufficient epithelium to assess the antibody reactivity with 1000 cells were considered for this study.

Immunohistochemistry was then performed on the remaining sections mounted on poly-L-lysine-coated glass slides. Deparaffined and rehydrated sections were incubated for 30 minutes in 3%  $H_2O_2$ /methanol to quench endogenous peroxidase activity, and then rinsed for 20 minutes with phosphate-buffered saline (Bio-Optica M107, Milan, Italy). Non-specific protein binding was attenuated by incubation for 30 minutes with 5% horse serum in PBS. Specimens were incubated overnight with polyclonal rabbit antibody anti-human NNMT (Richard Weinshilboum, Mayo Clinic, Rochester, MN) at a dilution of 1:500. The specificity of this antibody has been described in the literature (Xu et al., 2003).

The antibody was applied directly to the section and the slides were incubated overnight (4°C) in a "humidified chamber". The sections were washed three times with PBS at room temperature. Immune

complexes were subsequently treated with the secondary biotinylated antibody and then detected by streptavidin peroxidase, both incubated for 30 minutes at room temperature (Vectastain ABC kit, Vector Laboratories, Burlingame, CA, USA). After rinsing with three changes of PBS the immunoreactivity was visualized by development for 2 minutes with 0.1%, 3,3'-diaminobenzidine and 0.02% hydrogen peroxide (DAB substrate kit, Vector Laboratories Burlingame, CA, USA). Sections were counterstained with Mayer's haematoxylin, mounted with permanent mounting medium and examined by light microscopy.

Positive controls consisted of tissue specimen sections of human liver with known antigenic reactivity. A negative control was performed in all cases by substituting the primary antibody for normal rabbit serum. Negative controls in all instances resulted in a negative immunoreactivity for NNMT.

### Immunohistochemical categories

To evaluate NNMT expression, the mean percentage of positive tumour cells was determined from the percentage of positive cells derived from the analysis of 100 cells in 10 random areas at x400 magnification. The positivity for NNMT was evaluated by an expert pathologist in the field (CR) who was blind to the clinicopathological data, and was scored by the

**Table 1.** Clinico-pathological findings in OSCC.

Variables	No.	P< 0.05	Statistical analysis
Healthy mucosa	51	YES (0.0014)	Mann Whitney test
OSCC (Cases)	92		
Cases	92		
Age			
≤ 65 years		NO	Mann Whitney test
>65 years			
Gender			
Male	53	NO	Mann Whitney test
Female	39		
Grading			
G1	24	YES (0.0498)	One-way analysis of variance
G2	35		
G3	32		
Lymph node metastasis			
Negative	61	NO	Mann Whitney test
Positive	29		
Staging			
I	42	NO	Kruskal-Wallis test
II	13		
III	13		
IV	23		

## NNMT expression in oral cancer

percentage of stained cells. A semiquantitative assessment of NNMT expression was performed assigning cases to one of the five following categories: (a) score 0, when the stained cells comprised between 0% and 10% of the total; (b) score 1, when the stained cells comprised between 10% and 30% of the total cell population; (c) score 2, when the stained cells comprised between 30% and 50% of the total; (d) score 3, when the stained cells comprised between 50% and 80% of the total; (e) score 4, when the stained cells accounted for more than 80%.

### Statistical analysis

Data were analysed using GraphPad Prism software version 5.00 for Windows (GraphPad Software, San Diego, California, USA, [www.graphpad.com](http://www.graphpad.com)). Significant differences ( $P < 0.05$ ) between groups were determined using one-way analysis of variance and the Mann-Whitney test. Survival curves were analysed

according to the method of Kaplan-Meier and for differences between curves the p-value was calculated by the log-rank test. A p-value of less than 0.05 was accepted as statistically significant.

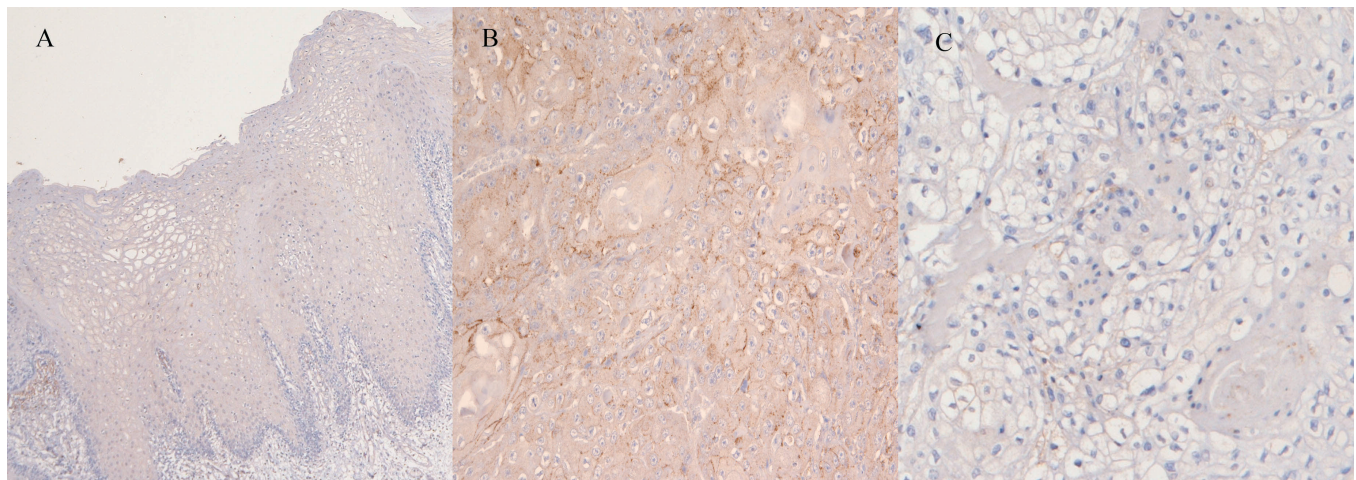
### Results

#### NNMT expression in normal oral mucosa

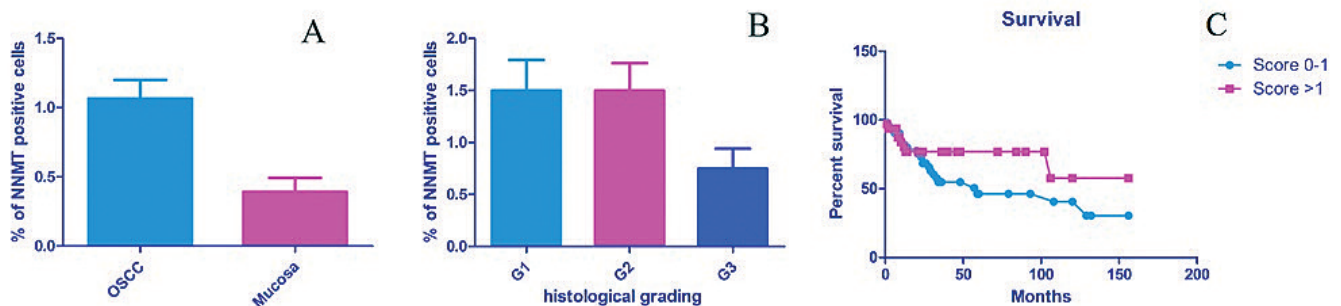
Forty cases out of 51 (78%) were not immunolabeled by anti-NNMT antibody. Normal mucosa of positive cases displayed absent or very weak cytoplasmic NNMT immunoreactivity, with occasionally moderate nuclear staining. In positive cases, normal epithelium included around 10% of stained cells.

#### NNMT expression in OSCC

We examined NNMT expression in OSCC tissues by immunohistochemistry. OSCC exhibited significantly



**Fig. 1.** Immunohistochemistry. **A.** Normal oral mucosa displayed absent cytoplasmic NNMT immunoreactivity in all epithelial layers. **B.** Moderately differentiated squamous cell carcinoma. Prevalently cytoplasmic positivity of the tumor cells. **C.** Poorly differentiated squamous cell carcinoma. Negativity or very weak cytoplasmic NNMT immunoreactivity of the tumor cells. a, x 100; b, c, x 200.



**Fig. 2.** Statistical analysis. **A.** Graph of increased NNMT expression in OSCC compared to normal mucosa. **B.** Graph of higher NNMT expression in well- and moderately-differentiated tumors with respect to undifferentiated ones. **C.** Kaplan-Meier survival curves of patients with OSCC (square, patients bearing tumours with high NNMT expression levels; circle, patients bearing tumours with low NNMT expression levels).

increased expression of NNMT compared to normal mucosa (Figs. 1, 2A).

We analysed the relationship between clinicopathological parameters and the level of NNMT tumour expression as determined by immunohistochemistry analyses. The clinicopathological parameters investigated in this study were age, gender, histological grading, nodal metastasis and pathological stage. There was no statistically significant correlation between NNMT expression and staging, sex, age, and lymph node metastasis. A statistically significant inverse correlation was found between NNMT expression and the histological grading of the tumour, in fact, the percentage of cells expressing NNMT was higher in well- and moderately differentiated tumours with respect to undifferentiated ones (Fig. 2B).

We also addressed the question of whether the extent of NNMT expression is associated with patient prognosis. To determine associations, patients were stratified into two groups, according to the level of NNMT tumour expression. The survival rate was calculated using the Kaplan-Meier method and compared between the two groups. When analysed for prognostic significance, patients with absent or low NNMT immunoreactive tumours manifested poorer overall survival rates in comparison with patients with moderate or high NNMT immunoreactive tumours, but the difference was not statistically significant (Fig. 2C). However, these results seem to indicate a favourable prognosis in patients with tumours expressing high NNMT levels, whereas the absence of marked NNMT expression seems to constitute a hallmark of aggressive biological behaviour.

## Discussion

The frequency of oral squamous cell carcinoma is rapidly increasing and it is the most frequent malignant tumour of the oral cavity. The incidence of metastasis depends on the degree of cellular differentiation, degree of invasion and site of the primary tumour. However, the survival of patients with oral squamous cell carcinoma remains unaffected despite recent therapeutic advances. The clinical behaviour of this tumour is difficult to predict based on classical histopathological parameters alone. Biological markers that can identify the lesions with an aggressive phenotype and worse prognosis need to be identified.

In the present study we investigated the expression of the enzyme Nicotinamide N-Methyltransferase in cancer tissues obtained from 91 patients with OSCC.

Compared with normal mucosa, we found a significantly increased NNMT expression in the examined OSCCs and, interestingly, this over-expression was more evident in well- and moderately-differentiated cases than in undifferentiated ones. This finding was in agreement with our previous study on OSCC, where NNMT mRNA levels were higher in cancerous tissue than in corresponding normal mucosa (Sartini et al.,

2007) supporting a role for NNMT in oral carcinogenesis.

NNMT catalyzes the transmethylation from S-adenosylmethionine to nicotinamide and to some other azaheterocycles, playing a pivotal role in the biotransformation and detoxification of many xenobiotics (Rini et al., 1990; Aksoy et al., 1994). In fact, N-methylation is one method by which drugs and other xenobiotic compounds are metabolized by the liver and the enzyme NNMT is responsible for this activity. Predominantly expressed in the liver, NNMT activity has a bimodal frequency distribution, an observation that raises the possibility that this enzyme activity may be regulated by a genetic polymorphism; moreover variation in NNMT activity might result in differences among individuals in the metabolism and therapeutic effect of drugs (Aksoy et al., 1994) and in the formation of potentially toxic pyridine metabolites. In fact, its catalytic activity could also lead to the production of toxic compounds, as shown in Parkinson's disease, where enhanced NNMT activity seems to produce toxic N-methylpyridinium compounds, which have been advanced as possible neurotoxins, underlying nigrostriatal degeneration (Williams and Ramsden, 2005a).

As above reported, NNMT is highly expressed in the liver, while low expression has been detected in the kidney, lung, skeletal muscle, placenta, heart, and brain. Several tumours have been associated with abnormal NNMT expression; these include glioblastoma, stomach adenocarcinoma (Markert et al., 2001; Jang et al., 2004; Lim et al., 2006), papillary thyroid cancers (Xu et al., 2003, 2005; Xu and Hershman, 2006), and colon (Roessler et al., 2005), clear cell ovarian and renal carcinoma (Yao et al., 2005; Sartini et al., 2006; Bignotti et al., 2007), where its upregulation appears to be inversely related to tumour size, thus suggesting that the enzyme may be significant in an initial step of malignant conversion. Recently, 2-DE experiments revealed that NNMT exists in multiple spots in gastric cancer tissues, while in normal tissue a single spot is predominant. This seems to suggest a post-translational modification of the enzyme in gastric cancer. Moreover, pancreatic juice from patients with pancreatic cancer has been shown to contain increased levels of NNMT mRNA, with respect to pancreatic juice of patients with chronic pancreatitis (Rogers et al., 2006).

In the present study an inverse correlation was seen between NNMT expression and OSCC histological grading, thus suggesting that the enzyme may be significant in an initial step of malignant conversion. Contrary to our previous findings, no statistical correlation was found between enzyme expression and pathological stage or lymph node metastasis. Although the reason for the different results is not known, there are some possible explanations. One possibility is related to the different methods adopted to evaluate enzyme expression levels. Indeed, in the present study, through immunohistochemistry, NNMT was evaluated in

tumours as a cytosolic protein and its expression was quantified as the mean percentage of positive tumour cells without considering adjacent normal mucosa; in our earlier work, NNMT was instead investigated at the mRNA level by semiquantitative and real-time PCR, and differential gene expression measurements (tumour vs. adjacent normal tissue) were performed and related to clinicopathological parameters.

Another possible reason is that NNMT mRNA levels could be subjected to a post-transcriptional regulation, which is a very powerful mechanism that allows cells to control and quickly change the amount of a specific protein. Indeed, mRNA expression provides information only on which transcription products may be translated in subsequent steps, while the actual amount of protein is a result of numerous post-transcriptional and post-translational regulatory mechanisms, which determine the real function of the protein.

Although the function of NNMT in cancer cell metabolism is still unclear, the results obtained in both studies seem to suggest that the enzyme may be involved in the early phases of oral carcinogenesis and may participate in tumour growth (Xu et al., 2003, 2005). As already mentioned, the enzyme catalyzes the formation of N<sup>1</sup>-methylnicotinamide, thus being involved in the major route of nicotinamide catabolism (Seifert et al., 1984). Indeed, N<sup>1</sup>-methylnicotinamide is mostly excreted into urine and partly further converted via catalysis by aldehyde oxidase to N<sup>1</sup>-methyl-2-pyridone-5-carboxiamide and N<sup>1</sup>-methyl-4-pyridone-5-carboxiamide, which are also excreted into urine. Therefore, NNMT could participate in the regulation of nicotinamide intracellular levels, modulating its excretion after N-methylation.

In this regard, NNMT upregulation could affect all fundamental events in which nicotinamide appears to be implicated. Nicotinamide is involved in the production of the important coenzymes NAD(H) and NADP(H), which are essential for cellular functions. NAD is well known as an electron carrier during mitochondrial oxidative phosphorylation; in recent years it has emerged as a key player in a wide range of biological processes that do not involve the redox properties of the nicotinamide ring, like cellular resistance to stress or injury, and longevity (Williams and Ramsden, 2005b). In fact, several enzymes use NAD, as a substrate, including ADP-ribosyltransferases, CD38 and sirtuins, and can be inhibited by nicotinamide (Zhang, 2003). Because of this inhibition, the salvage and/or elimination of nicotinamide are crucial steps in NAD metabolism and the enzyme NNMT could play a fundamental role in the regulation of these cellular events.

Even though the effects of NNMT upregulation deserve further investigation, it is tempting to speculate that the tumour cells, through this aberrant enzyme expression, attempt to control cellular events related to nicotinamide concentration or regulate transmethylation reactions using S-adenosylmethionine. Moreover, owing to the broad substrate specificity exhibited by NNMT, its

methyltransferase activity could alter the efficacy and/or adverse effect profile of standard doses of chemotherapeutic drugs.

In agreement with our previous results, an improved overall survival rate was shown for patients bearing tumours with higher NNMT expression levels than patients with tumours with lower NNMT expression, although without reaching statistical significance. While the involvement of NNMT in oral cancer progression must be investigated, the observations reported above seem to suggest that the enzyme plays a role in the early phases of tumour expansion, enhancing cell growth and proliferation. In this regard, knowing the status of NNMT expression would be helpful in predicting the prognosis for each patient.

The present study suggests that NNMT overexpression is a peculiar feature of OSCC and that the enzyme may have potential as prognostic marker; indeed high NNMT expression levels are expected to result in better survival rate for OSCC patients. Further studies will explore the applicability of screening NNMT expression as a prognostic determinant, and will fully assess its promising role as a new therapeutic drug target for OSCC.

---

*Acknowledgements.* We gratefully acknowledge Dr Richard Weinsilbourn, Mayo Clinic, Rochester, MN, for providing NNMT antibody.

---

## References

- Aksoy S., Brandriff B.F., Ward A., Little P.F. and Weinsilbourn R.M. (1995). Human nicotinamide N-methyltransferase gene: molecular cloning, structural characterization and chromosomal localization. *Genomics* 29, 555-561.
- Aksoy S., Szumlanski C.L. and Weinsilbourn R.M. (1994). Human liver nicotinamide N-methyltransferase. cDNA cloning, expression, and biochemical characterization. *J. Biol. Chem.* 269, 14835-14840.
- Bignotti E., Tassi R.A., Calza S., Ravaggi A., Bandiera E., Rossi E., Donzelli C., Pasinetti B., Pecorelli S. and Santin A.D. (2007). Gene expression profile of ovarian serous papillary carcinomas: identification of metastasis-associated genes. *Am. J. Obstet. Gynecol.* 196, 245 e1-11.
- Brinkman B.M. and Wong D.T. (2006). Disease mechanism and biomarkers of oral squamous cell carcinoma. *Curr. Opin. Oncol.* 18, 228-233.
- Carinci F., Lo Muzio L., Piattelli A., Rubini C., Chiesa F., Ionna F., Palmieri A., Maiorano E., Pastore A., Laino G., Dolci M. and Pezzetti F. (2005). Potential markers of tongue tumor progression selected by cDNA microarray. *Int. J. Immunopathol. Pharmacol.* 18, 513-524.
- Jang J.S., Cho H.Y., Lee Y.J., Ha W.S. and Kim H.W. (2004). The differential proteome profile of stomach cancer: identification of the biomarker candidates. *Oncol. Res.* 14, 491-499.
- Lim B.H., Cho B.I., Kim Y.N., Kim J.W., Park S.T. and Lee C.W. (2006). Overexpression of nicotinamide N-methyltransferase in gastric cancer tissues and its potential post-translational modification. *Exp. Mol. Med.* 38, 455-465.
- Lo Muzio L., Farina A., Rubini C., Pezzetti F., Stabellini G., Laino G.,

- Santarelli A., Pannone G., Bufo P., de Lillo A. and Carinci F. (2005). Survivin as prognostic factor in squamous cell carcinoma of the oral cavity. *Cancer Lett.* 225, 27-33.
- Lo Muzio L., Santarelli A., Emanuelli M., Pierella F., Sartini D., Staibano S., Rubini C. and De Rosa G. (2006). Genetic analysis of oral squamous cell carcinoma by cDNA microarrays focused apoptotic pathway. *Int. J. Immunopathol. Pharmacol.* 19, 675-682.
- Markert J.M., Fuller C.M., Gillespie G.Y., Bubien J.K., McLean L.A., Hong R.L., Lee K., Gullans S.R., Mapstone T.B. and Benos D.J. (2001). Differential gene expression profiling in human brain tumors. *Physiol. Genomics* 5, 21-33.
- Rini J., Szumlanski C., Guerciolini R. and Weinshilboum R.M. (1990). Human liver nicotinamide N-methyltransferase: ion-pairing radiochemical assay, biochemical properties and individual variation. *Clin. Chim. Acta* 186, 359-374.
- Roessler M., Rollinger W., Palme S., Hagmann M.L., Berndt P., Engel A.M., Schneidinger B., Pfeffer M., Andres H., Karl J., Bodenmuller H., Ruschoff J., Henkel T., Rohr G., Rossol S., Rosch W., Langen H., Zolg W. and Tacke M. (2005). Identification of nicotinamide N-methyltransferase as a novel serum tumor marker for colorectal cancer. *Clin. Cancer Res.* 11, 6550-6557.
- Rogers C.D., Fukushima N., Sato N., Shi C., Prasad N., Hustinx S.R., Matsubayashi H., Canto M., Eshleman J.R., Hruban R.H. and Goggins M. (2006). Differentiating pancreatic lesions by microarray and QPCR analysis of pancreatic juice RNAs. *Cancer Biol. Ther.* 5, 1383-1389.
- Sartini D., Muzzonigro G., Milanese G., Pierella F., Rossi V. and Emanuelli M. (2006). Identification of nicotinamide N-methyltransferase as a novel tumor marker for renal clear cell carcinoma. *J. Urol.* 176, 2248-2254.
- Sartini D., Santarelli A., Rossi V., Goteri G., Rubini C., Ciavarella D., Lo Muzio L. and Emanuelli M. (2007). Nicotinamide N-methyltransferase upregulation inversely correlates with lymph node metastasis in oral squamous cell carcinoma. *Mol. Med.* 13, 415-421.
- Seifert R., Hoshino J. and Kroger H. (1984). Nicotinamide methylation. Tissue distribution, developmental and neoplastic changes. *Biochim. Biophys. Acta* 801, 259-264.
- Szakacs G., Annereau J.P., Lababidi S., Shankavaram U., Arciello A., Bussey K.J., Reinhold W., Guo Y., Kruh G.D., Reimers M., Weinstein J.N. and Gottesman M.M. (2004). Predicting drug sensitivity and resistance: profiling ABC transporter genes in cancer cells. *Cancer Cell* 6, 129-137.
- Tomioka H., Morita K., Hasegawa S. and Omura K. (2006). Gene expression analysis by cDNA microarray in oral squamous cell carcinoma. *J. Oral. Pathol. Med.* 35, 206-211.
- Ueda G., Sunakawa H., Nakamori K., Shinya T., Tshako W., Tamura Y., Kosugi T., Sato N., Ogi K. and Hiratsuka H. (2006). Aberrant expression of beta- and gamma-catenin is an independent prognostic marker in oral squamous cell carcinoma. *Int. J. Oral. Maxillofac. Surg.* 35, 356-361.
- Williams A.C. and Ramsden D.B. (2005a). Autotoxicity, methylation and a road to the prevention of Parkinson's disease. *J. Clin. Neurosci.* 12, 6-11.
- Williams A.C. and Ramsden D.B. (2005b). Nicotinamide homeostasis: a xenobiotic pathway that is key to development and degenerative diseases. *Med. Hypotheses.* 65, 353-362.
- Xu J. and Hershman J.M. (2006). Histone deacetylase inhibitor depsipeptide represses nicotinamide N-methyltransferase and hepatocyte nuclear factor-1beta gene expression in human papillary thyroid cancer cells. *Thyroid* 16, 151-160.
- Xu J., Moatamed F., Caldwell J.S., Walker J.R., Kraiem Z., Taki K., Brent G.A. and Hershman J.M. (2003). Enhanced expression of nicotinamide N-methyltransferase in human papillary thyroid carcinoma cells. *J. Clin. Endocrinol. Metab.* 88, 4990-4996.
- Xu J., Capezzone M., Xu X. and Hershman J.M. (2005). Activation of nicotinamide N-methyltransferase gene promoter by hepatocyte nuclear factor-1beta in human papillary thyroid cancer cells. *Mol. Endocrinol.* 19, 527-539.
- Yao M., Tabuchi H., Nagashima Y., Baba M., Nakaigawa N., Ishiguro H., Hamada K., Inayama Y., Kishida T., Hattori K., Yamada-Okabe H. and Kubota Y. (2005). Gene expression analysis of renal carcinoma: adipose differentiation-related protein as a potential diagnostic and prognostic biomarker for clear-cell renal carcinoma. *J. Pathol.* 205, 377-387.
- Zhang J. (2003). Are poly(ADP-ribosylation) by PARP-1 and deacetylation by Sir2 linked? *Bioessays* 25, 808-814.

Accepted July 8, 2009