

Immunohistochemical expression of glycodelin in breast cancer correlates with estrogen-receptor α and progesterone-receptor A positivity

Christoph Scholz^{1*}, Bettina Toth^{2*}, Elisabeth Barthell¹, Ioannis Mylonas¹, Tobias Weissenbacher¹, Klaus Friese^{1,2} and Udo Jeschke¹

¹LMU Munich, Department of Obstetrics and Gynaecology, Munich and

²LMU Munich, Department of Obstetrics and Gynaecology-Grosshadern, Munich, Germany

*Both authors contributed equally

Summary. Glycodelin (Gd), previously known as placental protein 14 (PP 14), acts as an immunosuppressive glycoprotein by suppressing the cytolytic capacity of human natural killer (NK) cells and T-cells *in vitro*. Glycodelin is expressed in normal glandular epithelium of the endometrium as well as in normal and malignant glandular cells in and outside of the reproductive tract. Recently, Gd expression was demonstrated in normal and cancerous human breast tissue.

Paraffin-embedded breast cancer tissue blocks (n=121) were examined for Gd expression. No part of the specimens contained carcinoma *in situ*.

Gd expression was present in lobular and ductal breast carcinoma. We observed expression of Gd in breast cancer independent of grading. With regard to nodal status, no significant differences in the expression of Gd between cancer tissue from patients with or without axillary lymph node metastases were present. However, Gd expression was found to be significantly higher in breast cancer tissue when the staining reaction for steroid receptors was also positive.

These results implicate that Gd might be an additional marker for the differentiation of breast cancer tissue. To which extent Gd could serve as an additional indicator for breast cancer survival is part of our ongoing research.

Key words: Glycodelin, Breast cancer, Differentiation, Immunohistochemistry

Introduction

Breast cancer is the most common malignant tumour in women worldwide. Due to constantly enhanced therapeutic regimens its survival rates have improved substantially over the last 20 years. Hormone sensitivity is the most important predictive marker, indicating better prognosis due to available endocrine treatment options. In addition, hormone receptor positivity in breast cancer cells indicates better differentiation and less aggressive malignant behaviour. Treatment of early stage breast cancer depends on endocrine responsiveness, which is defined as staining steroid-receptor positive in more than 10% of breast cancer cells (Goldhirsch et al., 2007).

However, the biological significance of low-level expression of steroid receptors in breast cancer cells remains an area of scientific concern (Payne et al., 2008). Additional markers that are associated with better differentiation and intracellular signalling are needed in order to tailor endocrine therapy to those cancer patients that are likely to respond. The immunoreactivity of glycodelin (Gd) was evaluated in invasive breast cancer specimens (n=121) to investigate the capability of Gd as a marker of differentiation.

Glycodelin, a member of the family of lipocalins, is a secreted glycoprotein found in variable concentrations and tissue specific glycosylation in the human genital tract and is known to be expressed in breast cancer (Kamarainen et al., 1999). It exists in various isoforms with different glycosylation patterns that influence their staining behaviour (Morris et al., 1996; Tse et al., 2002; Chiu et al., 2007). The structure of a specific breast cancer glycodorm remains to be investigated. Nevertheless, invasive breast carcinoma without axillary or distant metastases were found to have a higher expression of Gd, hinting towards a better differentiation

and prognosis (Jeschke et al., 2005). Kämäräinen et al. (Kamarainen et al., 1997) were able to show that glycodeclin expressing cells also upregulated markers of organized epithelia, such as cytokeratins 8 and 18, as well as E-cadherin, and physiologic changes in intracellular distribution of β -catenin. This expression-pattern was accompanied by the acquisition of a phenotype of organized glandular epithelium.

Gd is further known to have direct immunomodulatory effects by suppressing the reactivity of stimulated T- lymphocytes and by inhibiting NK- and B-cell function *in vitro* (Seppala et al., 2002). Therefore, Gd might contribute towards tumour progression in an early phase of carcinogenesis in which organized local immune evasion is provided by the expression of Gd, while intracellular signalling is still intact.

Material and methods

Specimens

Formalin-fixed paraffin-embedded tissue from breast cancer patients undergoing surgery at the First Department of Obstetrics and Gynaecology of the Ludwig- Maximilians-University of Munich were investigated. All specimens had a histological classification as lobular or ductal breast cancer by a gynaecological pathologist. Patients with metastatic disease were excluded, as well as all patients with any proportion of ductal carcinoma *in situ* (DCIS) within tumorous tissue, as Gd expression has been seen in virtually all cases of DCIS (Jeschke et al., 2005).

Tissue blocks of 121 breast cancers fulfilled the above mentioned criteria. The mean age of the patients was 62.2 (SD 9.8) years (45-84 years) with 85% being postmenopausal. Out of the 83 ductal carcinoma 9 were graded as "G1", 40 as "G2" and 34 specimens as "G3". With regard to lobular carcinoma (n=38) 15 were graded as "G1", 16 as "G2", 3 as "G3". Grading was performed according to criteria published by Elston and Ellis (Elston and Ellis, 2002). If one or more of the criteria was not assessable due to technical variations the specimen was classified as Gx, as was the case in 4 lobular carcinoma specimens. Nodal involvement, as well as hormone receptor status was equally distributed among the study population. As part of the clinical work-up ER- α and PR-A isoforms are evaluated. In our study population all "receptor-positive" breast cancer specimens were positive for ER- α and PR-A. (ER- α and PR-A positive: 48 ductal, 20 lobular; ER- α and PR-A negative: 35 ductal, 18 lobular).

Immunohistochemistry

Immunohistochemical detection of Gd expression on paraffin sections (4 μ m) of breast cancer tissue was performed according to procedures described previously (Jeschke et al., 2005). In a first step sections were incubated in 3% methanol/ H₂O₂ (30 min) to inhibit endogenous peroxidase activity, washed in phosphate-

buffered saline (PBS, pH 7.4) for 5 min and treated with 1.5% goat serum for 20 min at 22°C to reduce non-specific background staining. To loosen aldehyde bonds sections were boiled in an acidic buffer (pH6.0) containing 2% Na-citrate and citric acid for 5 min and subsequently cautiously cooled to room temperature in tap water. The primary monoclonal antibody, known to recognize the CH epitope on Gd was purchased at Glycotope GmbH (Berlin, Germany) (code: A87-B/D2; isotype: IgG1_k) has been characterized previously (Jeschke et al., 2006). Specific binding of the antibody to Gd was analyzed by Western blot analysis. To specify immunoreactivity against the A isoform of glycodeclin we included a seminal vesicle (known to express glycodeclin S, which is the other most common Gd isoform) as a negative control (Fig. 1C). Incubation with the primary antibody was performed overnight at 4°C. Sections were then incubated with biotinylated secondary anti-mouse antibody (1:200) for 1 hr and then with avidin-biotin peroxidase complex (1:25) (ABC) prepared according to manufacturer's instructions for 45 min (Vectastain-Elite-ABC Kit, Vector Laboratories, Burlingame CA, USA). Labelling was revealed by incubation with 1 mg/ml diaminobenzidine/H₂O₂ (Dako, Hamburg, Germany) for 5 min and the reaction stopped by washing in tapwater for 10 min. Sections were counter-stained in hemalaun for 1 min, then cover-slipped. The primary antibody was replaced with pre-immune rabbit serum in controls. Positive (decidual tissue) and negative (human trophoblast tissue) controls were always included.

Two independent observers, including a gynaecological pathologist, assessed the specimens using the semi-quantitative immunoreactive score (IRS) after Remmele and Stegner - routinely used for assessing receptor positivity in breast cancer - evaluated the intensity and distribution patterns of the staining reaction. The IRS was calculated by multiplication of optical staining intensity (graded as 0=no, 1=weak, 2=moderate and 3=strong staining) and the percentage of positive stained cells (0=no staining, 1 \leq 10% of the cells, 2=11-50% of the cells, 3=51-80% of the cells and 4 \geq 81% of the cells). Evaluation of each specimen was performed without having any knowledge of the pathological diagnosis. For all sections, we assessed the mean optical density and the quantity of pixels which had a positive reaction for glycodeclin using the KSRun software (imaging system KS400, release 3.0; Zeiss, Vision GmbH, Germany)

Statistics

The SPSS/PC software package, version 16.0 (SPSS GmbH, Munich, Germany), was used for collection, processing and statistical analysis of all data. Statistical analysis was performed using the non-parametrical Mann-Whitney U test and in case of 3 or more groups its extension, the Kruskal-Wallis one-way analysis of variance by ranks. All p-values resulted from two-sided statistical tests and p \leq 0.05 was considered to be significant.

Expression of glycodeclin in receptor-positive breast cancer

Results

Characteristics of study population

121 breast cancer specimens were included in the study. 83 of them were classified as ductal carcinoma, 38 as lobular. Within those subgroups grading was distributed as follows: 89% (n=74) of ductal carcinoma were classified being G2 or G3, whereas for lobular carcinoma 81% (n=38) were graded as G1 or G2 (Table 1).

Glycodeclin expression

Gd was expressed both in lobular and in ductal breast carcinoma. Although there was a tendency towards increased staining in ductal carcinoma, no significant differences were found (median IRS for

ductal carcinoma: 1.81 versus median IRS = 1.55 lobular carcinoma) (Fig. 1A). Gd expression in lobular and ductal carcinoma cells was independent of their grading (Fig. 1B). Fig. 2C shows staining examples of a Gd negative (IRS:0) lobular G1 breast cancer specimen and a Gd positive (IRS:4) ductal G2 specimen. Although not statistically significant, there has been a tendency

Table 1.

	ductal	lobular
G1	9	15
G2	40	16
G3	34	3
Gx	0	4
Σ	83	38

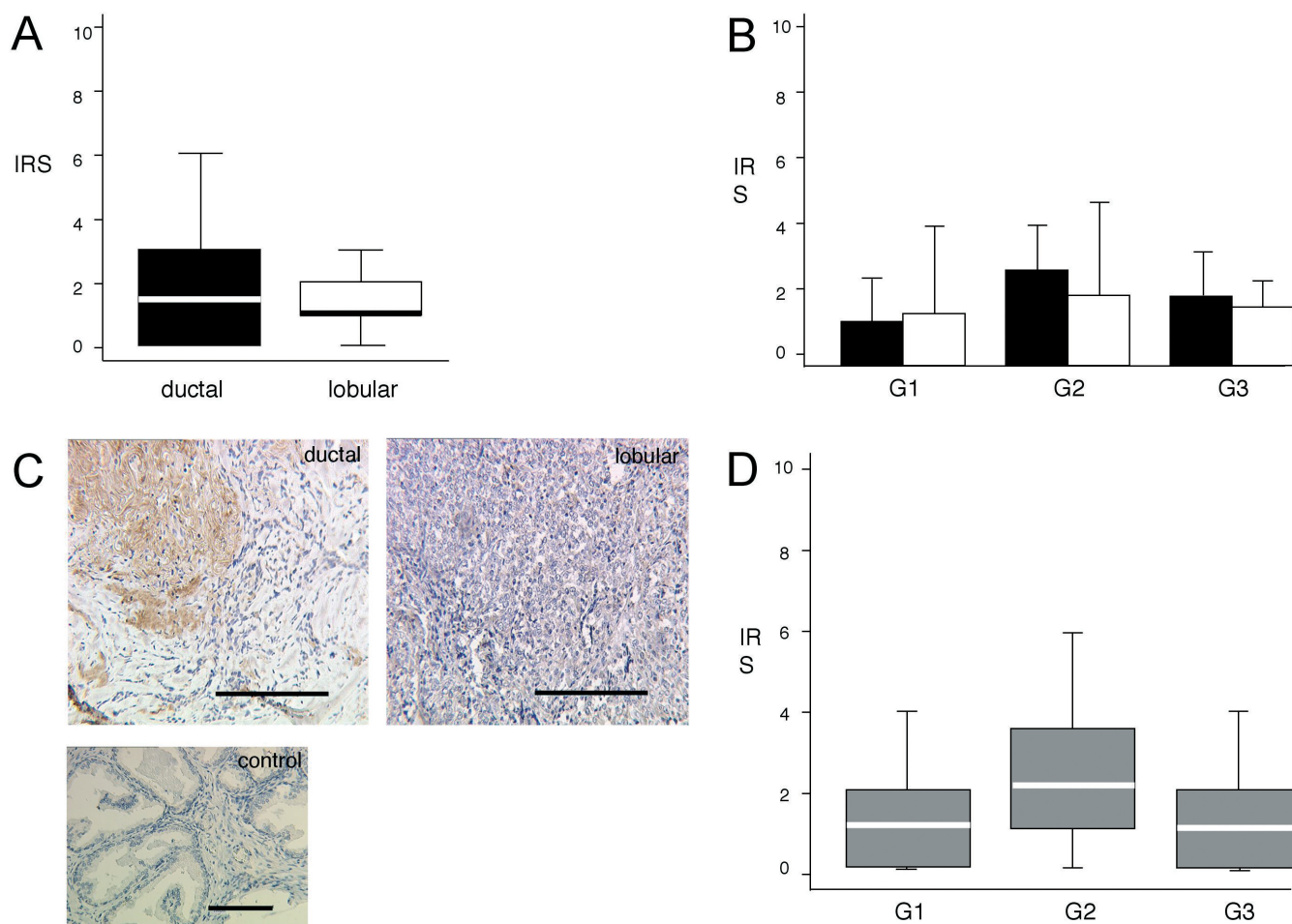


Fig. 1. Glycodeclin is equally expressed in ductal and lobular breast cancer and its expression is independent from grading. Immunohistochemical evaluation according to the Immune Reactivity Score (IRS) revealed no significant difference between ductal and lobular breast cancer specimens (**A**). Two staining examples and a negative control (seminal vesicle) are shown in (**C**). For box plots boxes indicate 25th and 75th Quartile with horizontal bars indicating median staining intensity. Error bars denote standard error of mean (SEM) (**A**, **B**, **D**). No statistically significant difference between different grading characteristics could be determined for ductal and lobular breast cancer (**B**). Summative results revealed a tendency towards higher expression in G2 tumours yet no statistically significant difference (**C**). Bars: 200 μ m.

Expression of glycodeilin in receptor-positive breast cancer

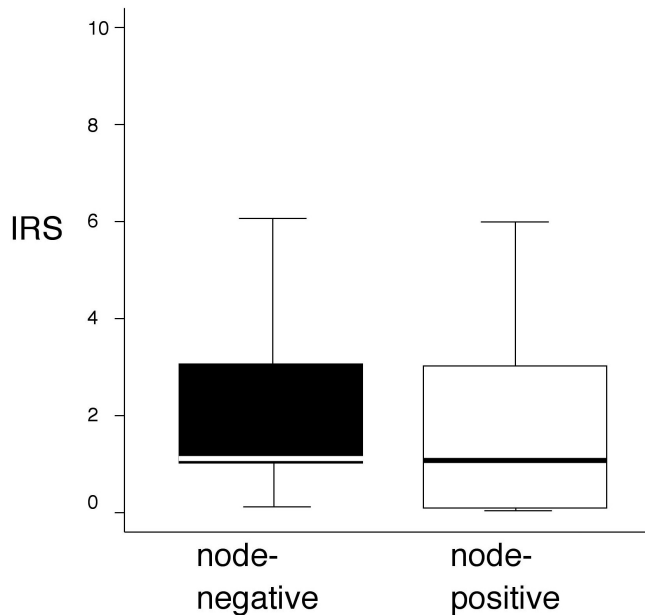


Fig. 2. Glycodeilin expression of breast cancer dependent on nodal status. Patients with positive axillary lymph nodes showed no significantly higher Gd expression.

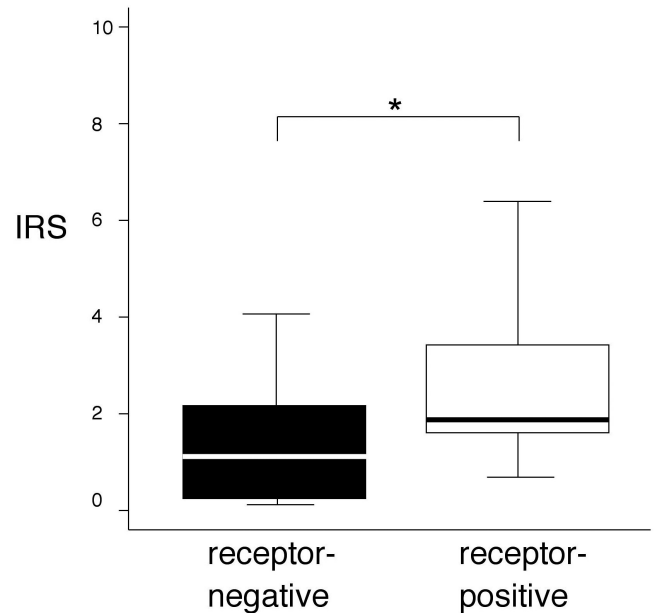


Fig. 3. Glycodeilin expression in breast cancer was significantly higher in tissue specimens that are receptor positive as compared to receptor negative specimens ($p < 0.05$). Receptor negative specimens ($n=53$) were compared to receptor positive specimens ($n=68$) and statistical significance of histochemical reactivity against Gd was determined by the Mann-Whitney-U test.

towards higher expression of Gd in G2 tumours in a pooled analysis of lobular and ductal carcinoma (Fig. 1D)

There was no significant difference between tumours of patients with positive axillary lymph nodes and those without. Median IRS for tumours without nodal involvement was 1.59 ($n=61$) for those with affected lymph nodes 1.87 ($n=60$) (Fig. 2).

Gd expression was found to be significantly higher in those specimens that also stained positive for steroid receptors. Median IRS of all hormone receptor negative tissue sections was 1.4 ($n=53$) compared to hormone receptor positive specimens that had a median IRS of 1.99 ($n=68$) ($p=0.033$).

Discussion

Gd expression was analysed in breast cancer tissue without any parts of the specimens containing carcinoma *in situ*. The monoclonal antibody used in these experiments detects specific carbohydrate structures of Gd (Jeschke et al., 2006). Glycosylation seems to play a pivotal functional role in Gd (Seppala et al., 2007). We found a significant increase in glycosylated Gd protein expression in hormone receptor positive (ER- α and PR-A) specimens. However, Gd expression was independent of nodal involvement, grading and cancer type. To our knowledge this study is the largest done so far on Gd expression in breast cancer. Kämäräinen et al. (1999) were able to describe Gd expression in 21/35 ductal carcinomas, 9/9 tubular carcinomas, 9/9 mucinous

carcinomas, 3/3 mixed ductal/tubular carcinomas and 7/11 lobular carcinomas. However, no differentiation was made according to ductal carcinoma in situ (DCIS). Later on, it became clear that DCIS uniformly stained positive for Gd (Jeschke et al., 2005). Therefore, we excluded all specimens that contained any fraction of DCIS in addition to invasive cancer. In accordance to the study population used by Kämäräinen et al. we did not find any correlation of Gd expression and nodal involvement (Kamarainen et al., 1999). The pivotal clinical marker of differentiation is "Grading". Grading of our specimens was performed by a gynaecological pathologist according to the most commonly used international criteria by Elston and Ellis (Elston and Ellis, 2002). To our knowledge the influence of grading on Gd expression has never been tested before.

Surprisingly, no significant differences between grading types was seen. A tendency towards higher levels of Gd expression in G2 tumours only in a pooled analysis might be explained by the immunomodulatory properties of Gd. Antigenic properties of tumours are altered during carcinogenesis. Secretion of a glycoprotein that inhibits NK- and T-cell responses locally would be more important for earlier tumour stage survival. We speculate that in later stages of differentiation this mechanism becomes less important. Nevertheless, the tendency of G2 tumours to express Gd did not reach statistical significance in our study

Expression of glycodelin in receptor-positive breast cancer

population.

Gd expression was found to be significantly higher in those specimens that were positive for steroid receptors. Expression of Gd is known to be dependent on steroid hormone levels. It is normally expressed in steroid responsive tissues of the reproductive tract and its secretion is strictly dependent on progesterone levels (Seppala et al., 2002). In endometrium, as well as cancerous tissue, Gd expression changes with steroid receptor notably PR expression (Mandelin et al., 2003; Stavreus-Evers et al., 2006). In our study population all 68 „receptor-positive“ invasive breast cancer specimens stained positive for ER- α and PR-A in the routine clinical work-up. IN routine clinical work-up other isoforms are usually not assessed as ER- α and PR-A positivity will decide whether to start antihormonal therapy. Possible associations between Gd and other steroid receptor isoforms, as well as putative Gd isoform differences between tissue specimens could not be investigated in this study. Gd is known to be an efficient inhibitor of E-selectin mediated cell adhesion *in vitro*, fostering tumour spread (Jeschke et al., 2003). Its high expression in well-differentiated breast cancer tissue might contribute towards the clinical phenomenon of early micro-metastatic spread even in small G1 tumours. On the other hand, Gd expression is known to be associated with higher differentiation. During neoplastic progression Gd mRNA and protein levels fall, while transfection of glycodelin cDNA in breast cancer cell cultures suppressed proliferation and induced a differentiated epithelial glandular phenotype (Jeschke et al., 2003, Kamarainen et al., 1997). Taken together, our study promotes Gd as an additional marker for differentiation, though additional, larger studies, as well as carefully designed *in vitro* experiments, will be needed to show progesterone dependent differentiation and glycosylation effects on breast cancer.

Acknowledgements. The work presented here is part of the MD thesis of EB. The Friedrich Baur Stiftung and a fellowship “Molekulare Medizin” by the University of Munich support CS. We are extremely grateful for marvellous technical assistance by C.Kuhn, S. Schulze and S. Kunze. We cordially thank PD Dr. Doris Mayr from the Institute of Pathology for generous assistance.

References

- Chiu P.C.N., Chung M.-K., Koistinen R., Koistinen H., Seppala M., Ho P.-C., Ng E.H.Y., Lee K.-F. and Yeung W.S.B. (2007). Cumulus oophorus-associated glycodelin-C displaces sperm-bound glycodelin-A and -F and stimulates spermatozoa-zona pellucida binding. *J. Biol. Chem.* 282, 5378-5388.
- Elston C.W. and Ellis I.O. (2002). Pathological prognostic factors in breast cancer. I. The value of histological grade in breast cancer: experience from a large study with long-term follow-up, *Histopathology* 41, 154-161.
- Goldhirsch A., Wood W. C., Gelber R.D., Coates A. S., Thurlimann B. and Senn H.J. (2007). Progress and promise: highlights of the international expert consensus on the primary therapy of early breast cancer 2007. *Ann. Oncol.* 18, 1133-1144.
- Jeschke U., Wang X., Briese V., Friese K. and Stahn R. (2003). Glycodelin and amniotic fluid transferrin as inhibitors of E-selectin-mediated cell adhesion, *Histochem. Cell Biol.* 119, 345-354.
- Jeschke U., Mylonas I., Kunert-Keil C., Dazert E., Shabani N., Werling M., Kuhn C., Janni W., Gerber B. and Friese K. (2005). Expression of glycodelin protein and mRNA in human ductal breast cancer carcinoma in situ, invasive ductal carcinomas, their lymph node and distant metastases, and ductal carcinomas with recurrence. *Oncol. Rep.* 13, 413-419.
- Jeschke U., Kuhn C., Mylonas I., Schulze S., Friese K., Mayr D., Speer R., Briese V., Richter D.U., Haase M. and Karsten U. (2006). Development and characterization of monoclonal antibodies for the immunohistochemical detection of glycodelin A in decidual, endometrial and gynaecological tumour tissues. *Histopathology* 48, 394-406.
- Kamarainen M., Seppala M., Virtanen I. and Andersson L.C. (1997). Expression of glycodelin in MCF-7 breast cancer cells induces differentiation into organized acinar epithelium, *Lab. Invest.* 77, 565-573.
- Kamarainen M., Halttunen M., Koistinen R., von Boguslawsky K., von Smitten K., Andersson L.C. and Seppala M. (1999). Expression of glycodelin in human breast and breast cancer. *Int. J. Cancer* 83, 738-742.
- Mandelin E., Lassus H., Seppala M., Leminen A., Gustafsson J.A., Cheng G., Butzow R. and Koistinen R. (2003). Glycodelin in ovarian serous carcinoma: association with differentiation and survival. *Cancer Res.* 63, 6258-6264.
- Morris H.R., Dell A., Easton R.L., Panico M., Koistinen H., Koistinen R., Oehninger S., Patankar M.S., Seppala M. and Clark G.F. (1996). Gender-specific glycosylation of human glycodelin affects its contraceptive activity. *J. Biol. Chem.* 271, 32159-32167.
- Payne S.J., Bowen R.L., Jones J.L. and Wells C.A. (2008). Predictive markers in breast cancer--the present, *Histopathology* 52, 82-90.
- Seppala M., Koistinen H., Koistinen R., Chiu P.C. and Yeung W.S. (2007). Glycosylation related actions of glycodelin: gamete, cumulus cell, immune cell and clinical associations, *Hum. Reprod. Update* 13, 275-287.
- Seppala M., Taylor R.N., Koistinen H., Koistinen R. and Milgrom E. (2002). Glycodelin: a major lipocalin protein of the reproductive axis with diverse actions in cell recognition and differentiation. *Endocr. Rev.* 23, 401-430.
- Stavreus-Evers A., Mandelin E., Koistinen R., Aghajanova L., Hovatta O. and Seppala M. (2006). Glycodelin is present in pinopodes of receptive-phase human endometrium and is associated with down-regulation of progesterone receptor B. *Fertil. Steril.* 85, 1803-1811.
- Tse J.Y., Chiu P.C., Lee K.F., Seppala M., Koistinen H., Koistinen R., Yao Y.Q. and Yeung W.S. (2002). The synthesis and fate of glycodelin in human ovary during folliculogenesis. *Mol. Hum. Reprod.* 8, 142-148.

Accepted November 7, 2008