

Immunohistochemical and *in situ* hybridization observations favor a local catecholamine production in the human Achilles tendon

Dennis Bjur¹, Patrik Danielson¹, Håkan Alfredson² and Sture Forsgren¹

¹Department of Integrative Medical Biology, Section for Anatomy, Umeå University, Umeå, Sweden and

²Department of Surgical and Perioperative Science, Sports Medicine, Umeå University, Umeå, Sweden

Summary. Results of recent studies using immunohistochemistry show evidence of an occurrence of catecholamine production in the cells (tenocytes) of patellar tendons exhibiting tendinopathy (tendinosis). In the present study, antibodies against the catecholamine-synthesizing enzyme tyrosine hydroxylase (TH) and α_1 -adrenoreceptors were applied to sections of specimens of normal and tendinosis Achilles tendons. *In situ* hybridization using a probe detecting human TH mRNA was also utilized. It was found that sympathetic innervation was very scarce. On the other hand, there were distinct α_1 -adrenoreceptor immunoreactions in blood vessel walls. Interestingly, tenocytes, particularly from tendinosis samples in which the tenocytes showed an abnormal shape (not the typical slender appearance), displayed TH immunoreactions and reactions for TH mRNA. Of further interest was the finding of α_1 -adrenoreceptor immunoreactions in tenocytes. The observations show not only evidence of local catecholamine production at the protein level, which was the case in recent studies for the patellar tendon, but also at the mRNA level. The observations suggest that the tenocytes, especially those with disfigured appearances in tendinosis, can produce catecholamines and also that they can respond to sympathetic transmitters. This is of interest as adrenergic stimulation in other parts of the body is known to induce degenerative/apoptotic and proliferative events, features which are seen in Achilles tendinosis. These observations are completely new findings concerning the human Achilles tendon. It is likely that locally produced catecholamines and the occurrence of autocrine/paracrine effects of these substances are of great relevance during the process of tendinosis.

Key words: Achilles tendon, Tenocytes, Tendinopathy, sympathetic innervation, Tyrosine hydroxylase

Introduction

Impaired function, tenderness and chronic pain are frequently occurring phenomena for human tendons. When these symptoms occur together, and when ultrasound or MRI examination show thickening and abnormalities in the involved tendon area, the condition is referred to as tendinosis (Alfredson, 2005). In these cases, hypercellularity, hypervascularity and degenerative and apoptotic events occur (Khan et al., 1999; Yuan et al., 2003; Cook et al., 2004). It is possible that signal substances such as nerve transmitters are involved in the processes of tendinosis. Thus, catecholamines are reported to have trophic and degenerative effects in other tissues (e.g. Zhang and Faber, 2001). One tendon in which tendinosis frequently occurs is the Achilles tendon.

The patterns of innervation of the Achilles tendon have been largely unknown for humans. For the rabbit Achilles tendon, it has been shown that the nerves from the paratenon form plexuses and penetrate into the tendon. Many nerve fibers, however, end on the surface of, and not within, the tendon (Ippolito and Postacchini, 1986). In the cat Achilles tendon, sensory innervation is present in relation to the blood vessels in the paratenon as well as in the endotenon (Andres et al., 1985). In the rat Achilles tendon, there is a peptidergic as well as a sympathetic innervation, the innervations being clearly more pronounced in the paratenon than in the tendon tissue proper (Ackermann et al., 1999, 2001).

In a recent study, we found that the nerve fascicles of the loose paratendinous connective tissue of the dorsal side of the normal Achilles tendons exhibit immunoreactions for the general nerve marker protein gene-product 9.5 (PGP 9.5) and to some degree also immunoreactions for the sensory nerve markers substance P (SP) and calcitonin gene-related peptide (CGRP) (Bjur et al., 2005). The levels of such innervations were seen to be lower within the tendon tissue proper, in which they were found in the zones of loose connective tissue that occur within the tendon. In

specimens of tendinosis tissue, immunoreactions for PGP 9.5 and SP/CGRP could be detected as well (Bjur et al., 2005).

So far nothing is known concerning the distribution of the sympathetic nervous system in the human Achilles tendon, nor is it known if and how adrenergic receptors are present in this tendon. This lack of knowledge is a drawback as efferent sympathetic activity can intensify pain in other parts of the body (McMahon, 1991), as adrenergic effects can be related to effects on cell proliferation and/or lead to apoptosis (Anesini and Borda, 2002; Burniston et al., 2005) and as the sympathetic nervous system on the whole has well-known effects concerning blood vessel regulation. Furthermore, in recent immunohistochemical studies on the human patellar tendon, we have made highly interesting findings favoring the occurrence of a local, non-neuronal, production of catecholamines in the tendon cells (tenocytes) themselves in this particular tendon (Danielson et al., 2007a). For all these reasons, the normal and tendinosis Achilles tendon of man were examined by the use of immunohistochemical methods. One aim was to reveal the general patterns of sympathetic innervation and the possible occurrence of adrenergic receptors in the human Achilles tendon. Another aim was to reveal if a local catecholamine production in tenocytes can be evidenced both at protein and mRNA levels. Immunohistochemistry, as well as in situ hybridization using a probe for tyrosine hydroxylase (TH) mRNA, were utilized.

Materials and methods

Individuals

Tissue samples from 29 individuals were examined. These corresponded to 12 males and 17 females.

The samples included biopsies from the Achilles tendon of a group of patients suffering from chronic painful mid-portion Achilles tendinosis (n=21) (8 males, mean age 43 years; 13 females, mean age 47 years). All patients had experienced a long duration of pain-symptoms (mean 19 months) and exhibited activity-related pain in a tender, thickened portion of the Achilles tendon, located 2-6 cm cranial to the tendon insertion into the calcaneus. Tendinosis was verified by clinical examination and ultrasonography or MRI. Ultrasonography showed the occurrence of tendon changes consisting of a localized widening, irregular collagen fiber structure and hypoechoic areas. MRI showed a localized widening and increased signal intensity.

All patients were otherwise healthy, on no medication, and non-smokers.

Other samples were from individuals (n=8) with pain-free and clinically normal Achilles tendons (4 males, mean age 37 years; 4 females, mean age 40 years). They were of approximately the same ages as the tendinosis patients but were not per definition age-matched. The individuals in this group are further on

referred to as the normal group. In all these tendons, ultrasonography showed normal tendon width and no structural changes or hypoechoic areas. The biopsies were taken from the mid-portion, corresponding to the level for the tendinosis area (cf. above). The specimens were taken from the superficial part of the dorsal side of the tendon.

All individuals in the normal group were healthy, on no medication, and non-smokers.

The study protocol has been approved by the Committee of Ethics at the Faculty of Medicine and Odontology, Umeå University, and later on by the Regional Ethical Review Board in Umeå, and the experiments were conducted according to the principles expressed in the Declaration of Helsinki.

Control samples from other tissues were also examined. These corresponded to samples of rat superior cervical ganglion (SCG), rat fetal heart and human colon.

Sampling

A surgical procedure with strict sterile conditions was performed. A local anaesthetic (4-5 mL Pilocarpinhydrochloride, 10 mg/mL, Astra Zeneca, Södertälje, Sweden) was administered into the skin. In the normal group, a longitudinal incision was performed through the skin and paratenon. Via this procedure, the tissue samples (2 mm in width and 1-5 mm in length) of the dorsal part of the tendon could be taken, with emphasis on minimizing the trauma. In the tendinosis group, the tissue samples were taken during surgical treatment. Through a straight longitudinal incision lateral to the Achilles tendon mid-portion, the thickened tendon was visualized. Macroscopically abnormal tendon tissue was removed. The paratenonous connective tissue was often found to be coalesced with the tendon tissue proper. The tissue samples represent tendinosis tissue from various depths of the tendon.

Immunohistochemistry

Immunohistochemistry was performed for all tendinosis specimens and for all control specimens. The principles for transportation from the operation room to the laboratory, fixation, sectioning and immunohistochemical stainings were the same for the different specimens. Sections from a large number of specimens were processed simultaneously for a certain antibody.

Sectioning and fixation

After the surgical procedure, the specimens for immunohistochemistry were immediately fixed by immersion, overnight at 4°C, in a solution of 4% formaldehyde in 0.1 M phosphate buffer, pH 7.0. They were then thoroughly washed in Tyrode's solution, containing 10% sucrose, at 4°C overnight, mounted on thin cardboard in OCT embedding medium (Miles Laboratories, Naperville, IL) and frozen at -80°C until

Sympathetic system of the Achilles tendon

sectioning. Series of 7 μm thick sections were cut using a cryostat. The sections were mounted on slides pre-coated with chrome-alun gelatine and were then dried. Sections from all the various samples were processed, either via immunofluorescence or by peroxidase-antiperoxidase (PAP)-staining, for demonstration of TH, neuropeptide Y (NPY) or α_1 -adrenoreceptor. After test stainings, the PAP procedure as well as immunofluorescence staining turned out to be useful for delineating TH- and NPY-immunoreactions. Concerning visualization of immunoreactions for the α_1 -adrenoreceptor, fluorescence staining was found to be the optimal staining procedure. The control tissues were chemically fixed and processed for immunofluorescence in the same way as tendon specimens. Sections of all samples were also processed for hematoxylin-eosin in order to reveal the tissue morphology.

Immunofluorescence processing

Sections to be processed for TH, NPY or α_1 -adrenoreceptor were initially treated with acid potassium permanganate for 2 min to enhance the visualization of specific immunofluorescence reaction sites (Hansson and Forsgren, 1995). Subsequently, rinsing in phosphate-buffered saline (PBS), incubation for 20 min in a 1% solution of detergent Triton X-100 (Kebo Lab, Stockholm) in 0.01 M PBS, pH 7.2, containing 0.1% sodium azide as preservative, and rinsing for 3x5 min in PBS were performed. Sections were incubated in 5% normal swine serum in PBS supplemented with 0.1% bovine serum albumin (BSA) for 15 min. They were then incubated with the primary antibody, diluted in PBS with BSA, in a humid environment. Incubation proceeded overnight at 4°C or for 60 min at 37°C. After this incubation with specific antiserum, three 5 min washes in PBS and another incubation in normal swine serum followed, after which the sections were incubated with secondary antibody corresponding to tetramethylrhodamine isothiocyanate (TRITC)-conjugated swine antirabbit IgG (code: R 0156, Dakopatts, Denmark), diluted 1:40, for 30 min at 37°C. Mounting was made in Vectashield. Examination was carried out in a Zeiss Axioskop 2 plus microscope, equipped with epifluorescence optics and an Olympus DP70 digital camera.

PAP-staining

PAP staining was additionally performed concerning demonstration of TH- and NPY- immunoreactions. The sections were treated with acid potassium permanganate for 2 min, after which they were incubated in a 1% Triton X-100 solution for 20 min. They were then washed in PBS 3x5 min and endogenous peroxidase activity was blocked by a 30 min incubation in 1% H_2O_2 . Subsequently the sections were incubated with normal swine serum for 15 min and thereafter with primary antibody for 60 min at 37°C. After washing in PBS and yet another incubation in normal swine serum,

the secondary antibody was applied (swine anti-rabbit, 1:100, code Z196; Dakopatts, Glostrup, Denmark). The sections then underwent rinsing in PBS 3x5 min, were thereafter incubated for 30 min at room temperature (RT) with peroxidase labeled IgG immunoglobulin (1:100; PAP-rabbit, Z0113, Dakopatts), again washed in PBS 3x5 min and developed in diaminobenzidine (DAB) solution for 5 min. Before dehydration, the sections were dipped for 20 s in Mayers hematoxylin (htx) for delineating general tissue morphology. They were then dehydrated and finally mounted in DPX microscopy mounting medium.

As an alternative, in order to accomplish further antigen retrieval, microwave treatment was utilized as a first step. For this purpose, the slides were initially placed in plastic Koplín jars filled with 0.01 M citrate buffer, pH 6.0. The jars were placed in the microwave oven (55°C) and were boiled at 650 W for 3x5 min. After each cycle, the slides were transferred to new jars with fresh citrate buffer cooled to RT. After cooling for 20 min, the sections were rinsed in PBS buffer. Thereafter followed the procedures described above.

A Zeiss Axioskop 2 microscope equipped with an Olympus DP70 digital camera was used for examination of the sections.

Antibodies and control stainings

The antibodies used were raised against TH, NPY and α_1 -adrenoreceptor. All three are rabbit antibodies.

The TH antibody (P40101) is from Pel-Freez (Rogers, Arkansas, USA), was raised against a SDS-denatured, purified recombinant rat and bovine TH and was used at a dilution of 1:25-1:50 (final dilution: 1:25). It is reported by the supplier to cross-react with all mammalian forms of TH tested up to now. To test the specificity of this antiserum, comparative stainings of rat adrenal medulla and rat SCG, for which the staining is well established, were performed.

The NPY antibody (PC223L) was obtained from Oncogene (Boston, MA, USA) and was used at a dilution of 1:500-1:1000 (final dilution: 1:500). The antibody is reported by the supplier to be reactive in various species, including man. For control purposes, NPY antiserum had been preabsorbed overnight at 4°C with 20 μg of synthetic NPY (Sigma Chemicals, St Louis, MO, USA) in 1 ml of antiserum. Furthermore, as there were very faint NPY reactions observed (cf. below) sections of a reference tissue (human colonic tissue) were stained as well (see Results).

The α_1 -adrenoreceptor antibody (PC161) was also obtained from Oncogene and was used at a dilution of 1:25-1:100 (final dilution: 1:50). The antigen for this receptor antibody is a synthetic peptide (KFSREKKA AKT) corresponding to amino acids 339-349 of the human α_1 -adrenoreceptor, a sequence that is reported by the supplier to be 100% conserved within the 3rd intracellular loop of the α_1 -adrenoreceptor subtypes that so far have been examined. For control purposes, the reactions obtained after stainings of

sections of fetal rat heart tissue were evaluated (cf. Results).

Apart from the different types of control stainings described above, replacements of the primary antibodies with PBS supplemented with BSA or normal serum were performed as additional controls for all antibodies.

In situ hybridization (ISH)

A digoxigenin (DIG)-hyperlabeled oligonucleotide probe (ssDNA) for detection of human TH mRNA (for details, see Table 1) was used on sections from chemically unfixed biopsies from two of the tendinosis tendons and one of the normal tendons. These biopsies were transported to the laboratory and directly embedded and frozen in the same way as were the chemically fixed specimens. ISH was performed according to an established ISH protocol (Panoskaltis-Mortari and Bucy, 1995), using an alkaline phosphatase (AP)-labeled anti-DIG antibody for detection, with a few modifications.

Series of 10 µm thick cryosections were cut using a cryostat (with a knife washed in 70% EtOH in DEPEC-H₂O) and mounted onto Super Frost Plus slides (nr. 041300, Menzel-Gläser). The sections were air-dried at room temperature (RT) for 30 min and thereafter fixed in 4% paraformaldehyde (PFA) in 0.1 M phosphate buffer (PB) (the PFA solution was first passed through a 0.45 µm sterile filter) for 60 min at RT. The slides were then washed with 2x saline sodium citrate (SSC) for 2x10 min. Concerning SSC the following procedures were performed: 20x SSC was prepared from 3 M NaCl and 0.3 M sodium citrate, pH 7.0 [+20°C], and autoclaved. 2x SSC was prepared by doing 10x dilution of 20x SSC in DEPEC-H₂O.

The sections were thereafter incubated in 0.2 M HCl for 8 min at RT to inhibit endogenous alkaline phosphatase activity. After this, the sections were acetylated by incubation of slides for 15 min at RT in a mixture of 195 mL DEPEC-H₂O, 2.7 mL tiethanolamine, 0.355 mL HCl, and 0.5 mL acetic anhydride (the acetic anhydride was added after the slides had been placed in the slide holder). Slides were then again rinsed in 2x SSC. After that, 100 ng of the ssDNA probe was put in 15 µL of hybridization solution in a 1.5 mL eppendorf tube and denaturated for 5 min at 80°C and then put on ice. The hybridization solution was as follows: 500 µL formamide, 200 µL 20x SSC, 50 µL of 20x Denhardt's solution, 50 µL herring sperm DNA (10 mg/mL) heat-denaturated, 25 µL bakers yeast RNA (10 mg/mL), 175

µL dextran sulfate (50%); total volume: 1.0 mL.

The probe-containing hybridization solution was then applied to each section, the sections thereafter being covered with cover slips and sealed with nail polish. Incubation followed at 56°C overnight. The slides were thereafter washed for 2x10 min at RT in 2x SSC and for 5 min at RT in STE-buffer (500 mM NaCl, 20 mM Tris-HCl [pH 7.5], 1 mM EDTA). Incubation in 100 µL RNase A (40 µg/ml in STE) thereafter followed for 30 min at 37°C. After this, the slides were washed for 20 min at 56°C in 2x SSC, 50% formamide (25 mL 100% and 25 mL 2x SSC buffer), then for 2x5 min placed at RT in 1x SSC, and for 2x5 min at RT in 0.5x SSC. Then the slides were washed for 5 min in buffer 1 (100 mM Tris-HCl [pH 7.5] + 150 mM NaCl). Thereafter followed incubation of the sections in buffer 1 containing 4% normal horse serum (NHS) for 60 min at RT in a humid chamber. Then the sections were incubated in 100 µL of the AP-labeled anti-DIG antibody (diluted 1:500 in buffer 1 with 4% NHS) for 60 min at RT in a humid chamber. The slides were thereafter washed for 2x10 min in buffer 1, and for 2x5 min in buffer 2 (100 mM Tris-HCl [pH 9.5] + 100 mM NaCl + 50 mM MgCl₂). After this, the enzyme (AP) substrate solution (20 µL NBT/BCIP in 1 mL buffer 2 with 10 µL levamisole) was sterile filtered (22 µm) and added to the sections, and the slides were then incubated up-and-down in the dark at 4°C overnight. The color reaction was then stopped by placing the slides in buffer 3 (10 mM Tris-HCl [pH 8.0] + 1 mM EDTA). Thereafter followed counter-staining of the slides in methylgreen (0.5% – 0.5g/100mL) by the following procedure: The slides were dipped for 30 s in 75%-ethanol, for 30 s in 95%-ethanol, for 4-5 s in 0.5% methylgreen, and finally washed in pure (99.5%) ethanol x 3. The slides were mounted in Pertex microscopy mounting medium.

The corresponding sense DIG-hyperlabeled ssDNA probe was used as negative control. As a positive control probe, a β-actin probe (GD5000-OP) was used (GeneDetect, New Zealand).

Results

Morphological aspects

The normal group

The border zone between the loose paratendinous connective tissue and the dorsal tendon tissue proper was readily defined. The loose paratendinous connective

Table 1. ssDNA probe.

| Probe | Code | Dilution | Fixation | Source |
|--|-----------|--|--|-------------------------|
| Antisense probe ¹ , recognizing human TH mRNA | GD1811-OP | 100 ng in 15 µL hybridization solution | Postfixation according to ISH protocol | GeneDetect, New Zealand |

¹GreenStar* DIG-hyperlabeled oligonucleotide probe. Sequence: AACCGCGGGGACATGATGGCCT.

Sympathetic system of the Achilles tendon

tissue was found to consist of loosely arranged collagen fibrils showing wavy courses and spaces of loose connective tissue in which blood vessels occurred (Fig. 1a,b). Nerve fascicles also occurred here (cf. below). In

the tendon tissue proper, the collagen fibrils were aligned in parallel bundles (Fig. 1a), and the tenocytes showed elongated/slender, spindle-shaped appearances and were evenly spread throughout the preparation.

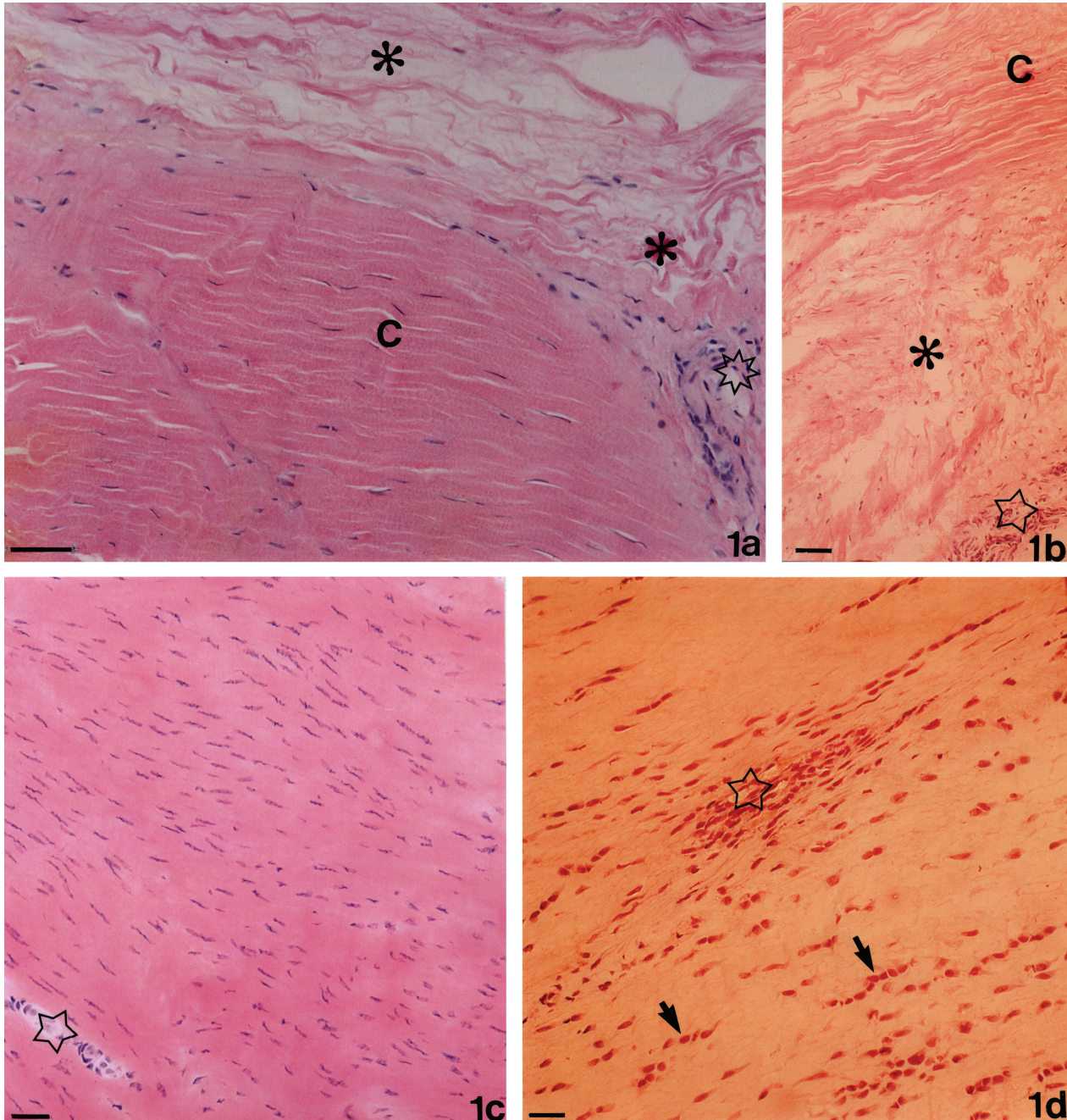


Fig. 1 Sections of specimens of normal (a-b) and tendinosis (c-d) Achilles tendons. a, b. The border zone between loose paratendinous connective tissue (asterisks) and tendon tissue proper, containing collagen fibrils of parallel alignment (C), is seen in (a). The presence of blood vessels in the loose paratendinous connective tissue is seen (open stars, a, b). The collagen fibrils show wavy courses in the loose paratendinous connective tissue. c-d. There is a large number of slender tenocytes in parallel alignment in (c), whereas the tenocytes in (d) partly show a more rounded form, to some extent coursing in rows (arrows). A blood vessel with a number of surrounding cells is seen in (d) (open star). Htx-eosin. a, c, d, x 320 (bar 25 μ m); b, x 200 (bars 25 μ m).

Areas with loose connective tissue and blood vessels were found interspersed between the collagen bundles. In association with the smallest blood vessels, perivascular cells occurred.

The tendinosis group

There was not a clearly distinguishable border between paratendinous connective tissue and tendon tissue proper in the tendinosis specimens. Overall, the morphology of the specimens of the tendinosis patients showed great variations. Variations were also seen within the specimens. In 14 of the tendinosis specimens, the overall morphology was changed in the way that there was a large number of tenocytes (Fig. 1c) and a large number of blood vessels. In half of these 14 tendinosis specimens, the collagen was irregularly arranged and the tenocytes were rounded/widened in their appearances, sometimes forming bead-like structures (Fig. 1d) or showing a very wavy appearance. Furthermore, the cells of the vessel walls could in these cases be seen to be more rounded than normally seen. In 2 of the tendinosis samples, the majority of the tenocytes showed rounded/widened appearances. The overall morphology was, on the other hand, more or less normal, the tendons exhibiting collinearly arranged collagen fibrils, in 3 tendinosis samples. The tenocytes in these latter specimens were slender and there was a moderate degree of vascularisation (not shown). The tenocytes in 2 tendinosis samples showed intermediate characteristics between those seen in samples showing hypercellularity/hypervascularity and frequent rounded tenocytes, and those in samples in principle showing a normal appearance.

Immunohistochemistry

TH- and NPY-innervation patterns

In the nerve fascicles of the loose paratendinous connective tissue of the normal tendons, TH- and NPY-like immunoreactions (LI) (Fig. 2a) were occasionally detected.

There was overall a scanty TH- and NPY-innervation perivascularly in both control and tendinosis tendons. This was a fact for both the loose paratendinous connective tissue and the tendon tissue proper. When perivascular innervation was observable, the nerve fibers usually lay more or less in association with the media-adventitia junction (Fig. 3a). In total, in the walls of the overwhelming majority of blood vessels, no TH- or NPY-LI were detectable (cf. Figs. 2b,c, 3b).

Control stainings concerning TH and NPY

As specific TH- and NPY- LI were rarely detected both perivascularly and within the nerve fascicles in the Achilles tendon specimens, stainings for TH and NPY of control specimens were regularly processed in parallel


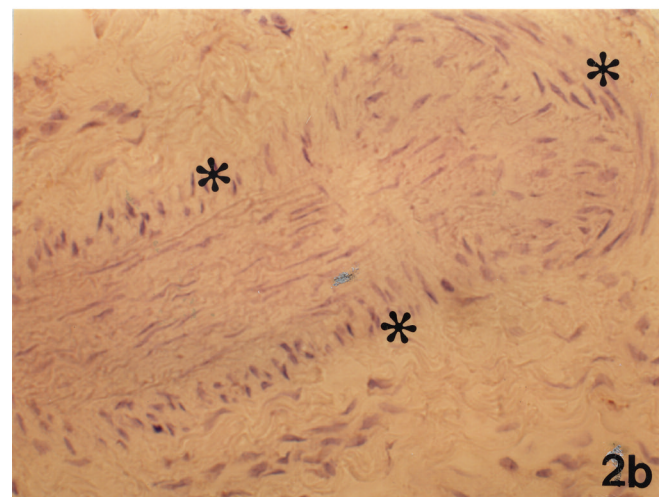



Fig. 2. a-b. Sections of normal Achilles tendons processed for TH. The parts shown are from the loose paratendinous connective tissue; a large nerve fascicle is seen in (a) and longitudinally and transversally cut large arteries in (b). All parts of (a) correspond to nerve fascicle structure except for the area marked with an asterisk. The media-adventitia junction of the artery in (b) is marked with asterisks. The presence of a few immunoreactive nerve fibers in the nerve fascicle is seen (arrows, a), whilst no specific immunoreaction is seen in (b). **c.** A section showing a blood vessel in the loose paratendinous connective tissue of a normal Achilles tendon. The section was processed for NPY. No specific immunoreactions are observable. a, x 320; b, x 200; c, x 500

Sympathetic system of the Achilles tendon

(cf. Material and methods). In these specimens, distinct specific immunoreactions for NPY and TH were detected.

TH immunoreaction in tenocytes

It was revealed that tenocytes actually did show TH-

LI. However, there was a variability between different specimens and between different tenocytes in individual specimens in this respect. Thus, immunolabeled tenocytes could be seen to be intermingled with non-immunolabeled cells (Fig. 4a). Furthermore, it was evident that the most distinct reactions were obtained for tenocytes that did not show the slender appearance that

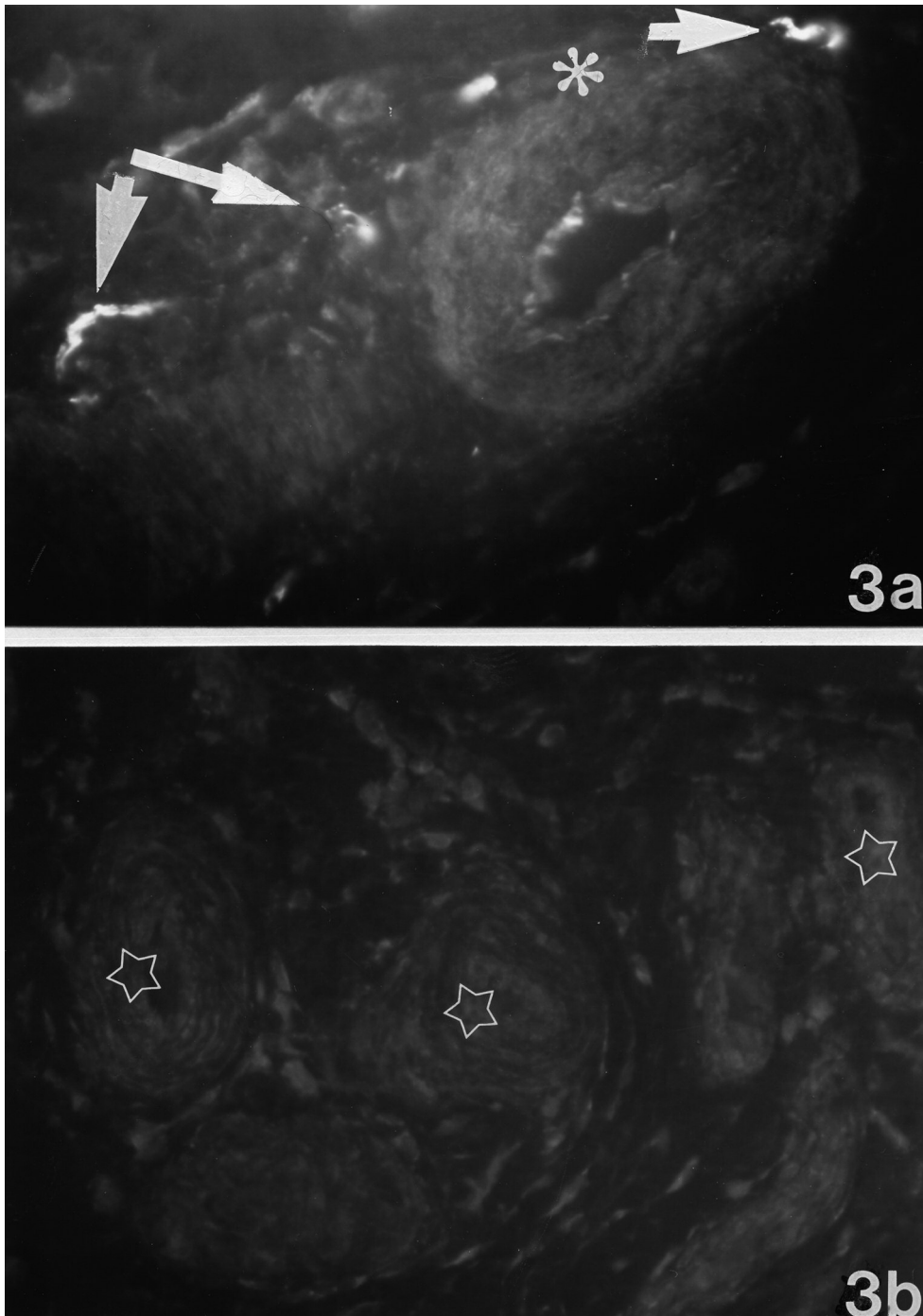


Fig. 3. a, b. Blood vessels of tendinosis Achilles tendon tissue as seen after processing for TH. A transversally cut artery to the right and part of an obliquely cut artery to the left in **(a)** (asterisk at media-adventitia junction). Several blood vessels are seen in **(b)** (stars). Occurrence of immunoreactive nerve fibers is observable in association with the arteries in **(a)** (arrows). They partly occur at the level of the media-adventitia junction. No specific immunoreaction is seen in **(b)**. x 300

Sympathetic system of the Achilles tendon

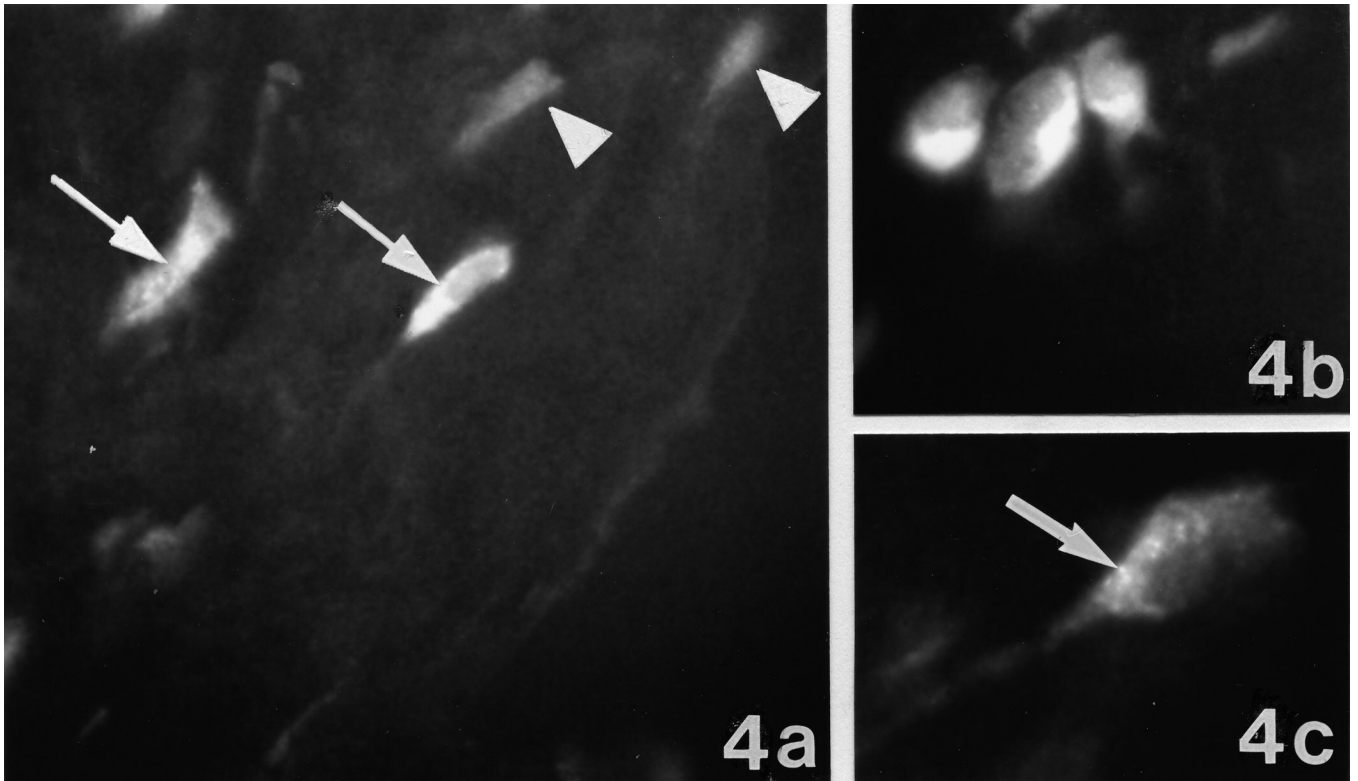


Fig. 4. Section of tendinosis Achilles tendon tissue processed for TH. In (a), some of the tenocytes show immunoreaction (arrows), while others show only background fluorescence (arrowheads). In (b), it is seen that rounded tenocytes forming a group of cells are immunolabeled. In (c), the immunoreactions are seen to occur as intracellular punctate reactions (arrow). a, x 300; b, x 400; c, x 500

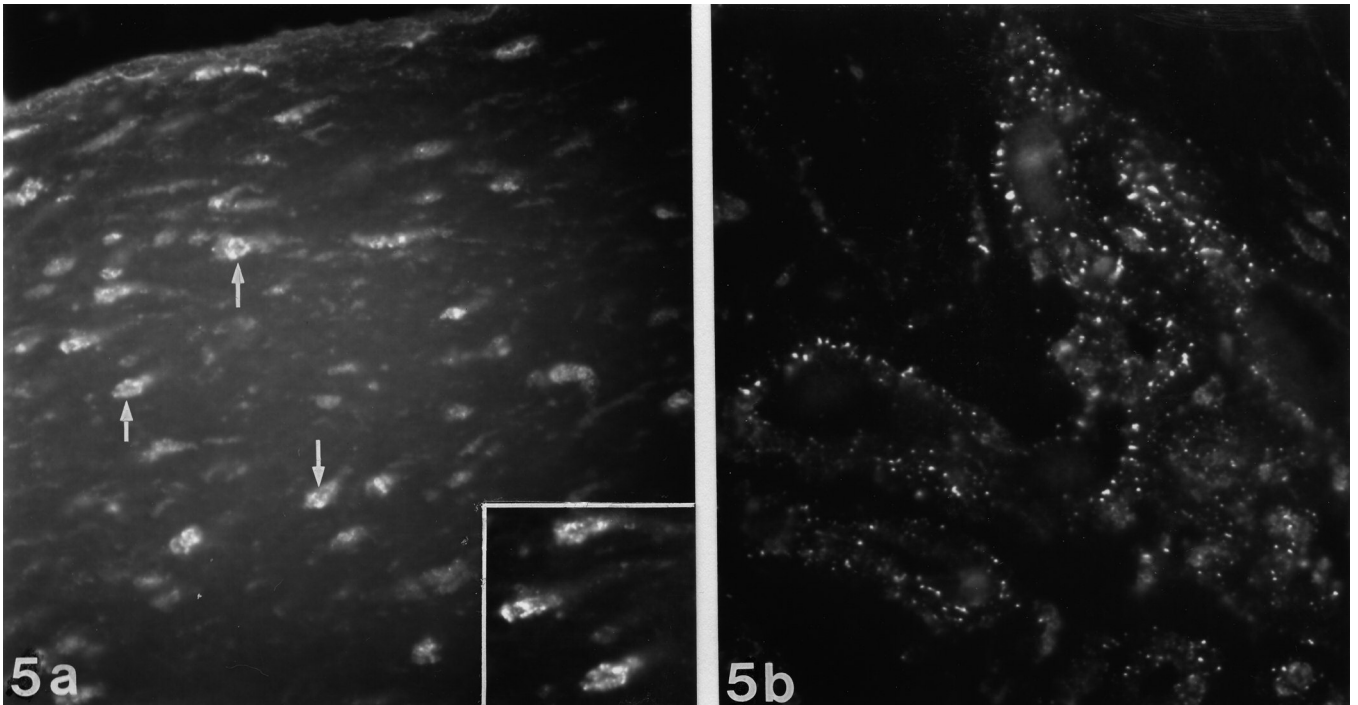


Fig. 5. Sections of tendinosis Achilles tendon tissue processed for α_1 -adrenoreceptor. Tenocytes showing immunoreaction are seen in (a) (arrows). A part of the area in (a), including one of the indicated tenocytes, is shown at higher magnification in the inset; the immunoreactions being seen to occur as intracellular granular reactions. In (b), occurrence of punctate immunoreactions in blood vessel walls is seen. a, x 200, inset a, b, x400

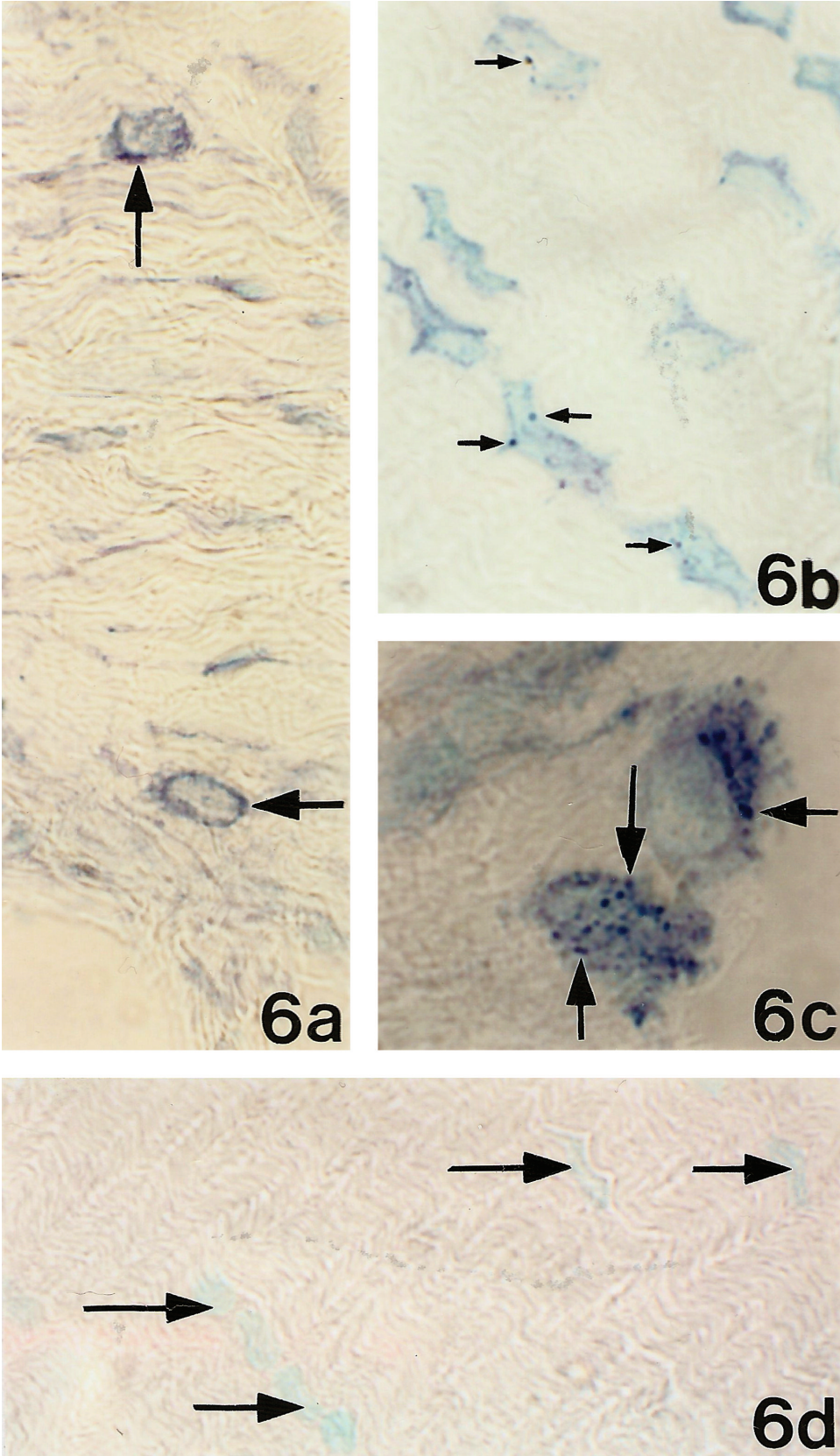


Fig. 6. Sections of Achilles tendon tissue from a tendinosis patient, processed by in situ hybridization using DIG-AP detection. A ssDNA probe recognizing human TH mRNA was utilized. Antisense staining (a-c), sense staining (d). Occurrence of reactions for TH mRNA is shown for abnormal tenocytes, displaying rounded (a) (arrows), wavy and widened (b) and bizarre and rounded (c) appearances. In (b) and (c), it is seen that the reactions show punctate appearances (arrows). There are no reactions in (d). a, b, d, x 400, c, x 500

is typical for normal such cells. TH-immunoreactions were particularly detected in cells showing widened/cylindrical or rounded (Fig. 4b) or very wavy appearances, i.e. tenocyte appearances seen in certain of the tendinosis specimens (cf. above). Thus, the occurrence of TH-LI or not in the tenocytes was in principle related to the morphologic appearance of the tenocytes. At high magnification, the immunoreactions were seen to show a punctate appearance (Fig. 4c). In control stainings when the primary antibody was not applied, only background reactions were noted for the tenocytes. In comparison to the perivascular TH-LI detected and the levels of TH-LI detected in control tissues (cf. Materials and methods), the degree of TH-immunoreaction in the tenocytes was somewhat weaker. However, in tendinosis tendons, TH immunoreactions in tenocytes were, on the whole, more frequently detected than nerve related TH immunoreactions.

Immunoreactions for the α_1 -adrenoreceptor

Immunoreaction for the α_1 -adrenoreceptor could be detected in blood vessel walls (Fig. 5b). There was a variability in this respect between different specimens. This was true for both the normal group and the tendinosis group. α_1 -adrenoreceptor-LI were also detected in nerve fascicles (not shown).

Of particular interest was the finding that α_1 -adrenoreceptor-LI were detectable in tenocytes (Fig. 5a). The immunoreactions were most evidently seen in some of the tendinosis specimens. As described above for TH, the tenocytes showing the most distinct α_1 -adrenoreceptor-LI in principle did not exhibit a typical slender tenocyte appearance. Thus, the variability in receptor immunoreactions was related to the occurrence of a variability in morphologic appearance and not to methodological aspects. The immunolabeled tenocytes were in certain cases seen to be lined up in rows. At high magnification, the immunoreactions showed a granular appearance (Fig. 5a inset).

When normal serum or PBS supplemented with BSA was used instead of primary antibody no reactions of the type here described were seen. Immunoreactions obtained in sections of rat fetal heart were in accordance with patterns of α_1 -adrenoreceptor reactions reported for rat heart cells in previous reports (Luther et al., 2001).

In situ hybridization

After incubation with antisense probe detecting human TH mRNA, reactions were observed for tenocytes. The reactions were variably seen. The most distinct reactions were noted for tendinosis tenocytes showing bizarre appearances, i.e. unusually rounded and widened appearances (Fig. 6a-c). No reactions were seen using the corresponding sense probe (Fig. 6d).

Discussion

In the present study, it is shown that the dorsal

regions of the normal human Achilles tendon, as well as the tendinosis Achilles tendon regions here examined, are only scarcely supplied with sympathetic innervation. On the other hand, there is a distinct occurrence of α_1 -adrenoreceptors, including in tenocytes in tendinosis specimens. Most interestingly, we found evidence suggesting that the tenocytes themselves can produce catecholamines, as seen via immunohistochemical staining for TH and via *in situ* hybridization staining using a probe for detecting TH mRNA. These findings strengthen previous findings of the presence of TH immunoreaction in tenocytes in another human tendon, the patellar tendon (Danielson et al., 2007a), and extend the observations made in that study by showing the presence of TH in tenocytes at the mRNA level.

General morphological aspects

Although the morphology of the tendinosis specimens in principle was different from that of the normal control specimens, there were marked inter-individual variations between the different tendinosis specimens. Thus, in some tendinosis specimens, the morphology to a certain extent resembled that of the normal tendons, whilst the morphology in others was deranged. In certain specimens, the tenocytes showed a rounded and widened appearance. The occurrence of a marked variability in morphology between different tendinosis preparations does to a certain extent resemble the observations for Achilles (Astrom and Rausing, 1995; Jozsa and Kannus, 1997; Movin et al., 1997; Khan et al., 1999; Shalabi, 2004) and patellar (Cook et al., 2004) tendinosis made in previous studies.

Occurrence of limited sympathetic innervation

The nerve fascicles identified contained few if any sympathetic nerve fibers, and sympathetic perivascular innervation was scanty. It should here be clarified that the specimens did not contain the large feeding arteries of the tendon, nor large nerves. In comparison, in the region of the loose paratendinous connective tissue on the ventral part of the human Achilles tendon, there is a more distinct perivascular sympathetic innervation and a presence of large nerve fascicles harboring frequent sympathetic nerve fibers (Andersson et al., 2007). Thus, there appear to be marked differences concerning levels of sympathetic innervation between ventral and dorsal parts of the Achilles tendon paratendinous tissue. In comparison, in studies on the human patellar tendons by Lian and collaborators (Lian et al., 2006), perivascular TH-immunoreactive nerve fibers occurred throughout the tendon proper. These observations show that overall there is a comparatively high level of perivascular sympathetic innervation in the patellar tendon. In the studies by Lian and collaborators (Lian et al., 2006), the level of this innervation was found to be decreased in response to tendiopathy (tendinosis).

In the rat Achilles tendon, there is a very limited NPYergic/sympathetic innervation in the tendon tissue,

Sympathetic system of the Achilles tendon

whilst such an innervation is present to a high degree in the loose connective tissue around the tendon, mainly appearing as networks around blood vessels (Ackermann et al., 2001).

Presence of α_1 -adrenoreceptors

Evidence of a presence of α_1 -adrenoreceptors was distinctly seen. The α_1 -adrenoreceptor immunoreactions conformed to intracellular punctate reactions. In accordance with this observation, immunoreactions to adrenoreceptors have also in previous studies been shown to exhibit cytosolic distributions in other regions of the body (McGrath et al., 1999; Enriquez de Salamanca et al., 2005). A distinct observation was the finding that tenocytes could be seen to exhibit immunoreactions for the α_1 -adrenoreceptor. In accordance with this finding, tenocytes of patellar tendinosis tendons show adrenoreceptor immunoreactions (Danielson et al., 2007a), and avian tendon cells contain adrenoreceptor mRNA (Wall et al., 2004).

Interference with adrenergic effects can have an influence on degenerative/apoptotic events but can also induce cell proliferation. E.g. β -adrenoceptor antibodies may induce apoptosis in rat cardiocytes (Staudt et al., 2003), extensive stimulation of α_1 -adrenoreceptors can lead to proliferation of fibroblasts in the vascular adventitia (Zhang and Faber, 2001) and stimulation of hepatic stellate cells, which are the liver's principal fibrogenic cells, with sympathetic neurotransmitters leads to increased cell proliferation and increased liver fibrosis (Oben and Diehl, 2004). It is therefore of interest to note that tenocytes of tendinosis tendons are known to proliferate and to be subjected to degenerative and apoptotic events (Yuan et al., 2003).

Evidence that tenocytes might produce catecholamines

Of great interest in the present study are the findings of TH-LI and reactions for TH mRNA concerning tenocytes. Thus, although the occurrence of effects of circulating adrenaline/noradrenaline cannot be ruled out, it seems possible that locally produced catecholamines may be the mediators that bind to the frequently occurring adrenoreceptors. Concerning the tenocytes, it is therefore possible that autocrine/paracrine catecholamine effects occur. These aspects are quite new concerning human tendons and need to be further explored. Also, in the studies by Diehl and Oben and collaborators it has been shown that the hepatic stellate cells can not only respond to sympathetic neurotransmitters but also produce them (Oben and Diehl, 2004; Oben et al., 2004). Of interest for the present study is the finding made in cell culture studies that cells with fibroblast-like appearances can be induced to become neuroectodermal cells and possibly neurons (Rieske et al., 2005). Of considerable further interest is our recent finding of the presence of enzymes involved in acetylcholine synthesis and of muscarinic receptors in the tenocytes of the human patellar tendon,

in particular in tendinosis (Danielson et al. 2006).

Concluding remarks

In summary, the present study shows that there is a very limited sympathetic innervation in the Achilles tendon regions here examined. Nevertheless, α_1 -adrenoreceptors are frequently present. Most importantly, it appears as though the tenocytes, especially those exhibiting rounded/cylindrical appearances in tendinosis tissue, have the capacity for catecholamine production. Furthermore, such cells are also equipped with adrenergic receptors. These observations suggest that, although the sympathetic innervation within the Achilles tendon is scarce, marked transmitter effects may be obtained via locally produced catecholamines.

Note added in proof

While the present study was in press, a study showing the existence of TH mRNA in another human tendon exhibiting tendinosis, namely the patellar tendon, has been published on line (Danielson et al., 2007b).

Acknowledgements. The authors thank Ms. Ulla Hedlund for excellent technical services. Financial support was obtained from the Faculty of Medicine at Umeå University, the Swedish National Centre for Research in Sports and the County Council of Västerbotten.

References

- Ackermann P.W., Finn A. and Ahmed M. (1999). Sensory neuropeptidergic pattern in tendon, ligament and joint capsule. A study in the rat. *Neuroreport* 10, 2055-2060.
- Ackermann P.W., Li J., Finn A., Ahmed M. and Kreicbergs A. (2001). Autonomic innervation of tendons, ligaments and joint capsules. A morphologic and quantitative study in the rat. *J. Orthop. Res.* 19, 372-378.
- Alfredson H. (2005). The chronic painful Achilles and patellar tendon: research on basic biology and treatment. *Scand. J. Med. Sci. Sports.* 15, 252-259.
- Andersson G., Danielson P., Alfredson H. and Forsgren S. (2007). Nerve-related characteristics of ventral paratendinous tissue in chronic Achilles tendinosis. *Knee Surg. Sports Traumatol. Arthrosc.* 15, 1272-1279.
- Andres K.H., von Düring M. and Schmidt R.F. (1985). Sensory innervation of the Achilles tendon by group III and IV afferent fibers. *Anat. Embryol. (Berl.)* 172, 145-156.
- Anesini C. and Borda E. (2002). Modulatory effect of the adrenergic system upon fibroblast proliferation: participation of beta 3-adrenoreceptors. *Auton. Autacoid Pharmacol.* 22, 177-186.
- Astrom M. and Rausing A. (1995). Chronic Achilles tendinopathy. A survey of surgical and histopathologic findings. *Clin. Orthop. Relat. Res.* 151-164.
- Bjur D., Alfredson H. and Forsgren S. (2005). The innervation pattern of the human Achilles tendon: studies of the normal and tendinosis tendon with markers for general and sensory innervation. *Cell Tissue Res.* 320, 201-206.

Sympathetic system of the Achilles tendon

- Burniston J.G., Tan L.B. and Goldspink D.F. (2005). beta2-Adrenergic receptor stimulation in vivo induces apoptosis in the rat heart and soleus muscle. *J. Appl. Physiol.* 98, 1379-1386.
- Cook J.L., Feller J.A., Bonar S.F. and Khan K.M. (2004). Abnormal tenocyte morphology is more prevalent than collagen disruption in asymptomatic athletes' patellar tendons. *J. Orthop. Res.* 22, 334-338.
- Danielson P., Alfredson H. and Forsgren S. (2006). Immunohistochemical and histochemical findings favoring the occurrence of autocrine/paracrine as well as nerve-related cholinergic effects in chronic painful patellar tendon tendinosis. *Microsc. Res. Tech.* 69, 808-819.
- Danielson P., Alfredson H. and Forsgren S. (2007a). Importance of sympathetic innervation, adrenergic receptors, and a possible local catecholamine production in the development of patellar tendinopathy (tendinosis) in man. *Microsc. Res. Tech.* 70, 310-324.
- Danielson P., Alfredson H. and Forsgren S. (2007b). In situ hybridization studies confirming recent findings of the existence of a local nonneuronal catecholamine production in human patellar tendinosis. *Microsc. Res. Tech.* 70, 908-911.
- Enriquez de Salamanca A., Siemasko K.F., Diebold Y., Calonge M., Gao J., Juarez-Campo M. and Stern M.E. (2005). Expression of muscarinic and adrenergic receptors in normal human conjunctival epithelium. *Invest. Ophthalmol. Vis. Sci.* 46, 504-513.
- Hansson M. and Forsgren S. (1995). Immunoreactive atrial and brain natriuretic peptides are co-localized in Purkinje fibres but not in the innervation of the bovine heart conduction system. *Histochem. J.* 27, 222-230.
- Ippolito E. and Postacchini F. (1986). Anatomy. In: *The tendons: Biology-pathology-clinical aspects*. Perucia L., Postacchini F. and Ippolito E. (eds). Editrice Kurtis. Milano. pp 9-36.
- Jozsa L. and Kannus P. (1997). *Human tendons: anatomy, physiology, and pathology*. Human Kinetics, Champaign, IL, USA.
- Khan K.M., Cook J.L., Bonar F., Harcourt P. and Astrom M. (1999). Histopathology of common tendinopathies. Update and implications for clinical management. *Sports. Med.* 27, 393-408.
- Lian Ö., Dahl J., Ackermann P.W., Frihagen F., Engebretsen L. and Bahr R. (2006). Pronociceptive and antinociceptive neuromediators in patellar tendinopathy. *Am. J. Sports Med.* 34, 1801-1808
- Luther H.P., Podlowski S., Schulze W., Morwinski R., Buchwalow I., Baumann G. and Wallukat G. (2001). Expression of alpha1-adrenergic receptor subtypes in heart cell culture. *Mol. Cell. Biochem.* 224, 69-79.
- McGrath J.C., Mackenzie J.F. and Daly C.J. (1999). Pharmacological implications of cellular localization of alpha1-adrenoceptors in native smooth muscle cells. *J. Auton. Pharmacol.* 19, 303-310.
- McMahon S.B. (1991). Mechanisms of sympathetic pain. *Br. Med. Bull.* 47, 584-600.
- Movin T., Gad A., Reinholt F.P. and Rolf C. (1997). Tendon pathology in long-standing achillodynia. Biopsy findings in 40 patients. *Acta Orthop. Scand.* 68, 170-175.
- Oben J.A. and Diehl A.M. (2004). Sympathetic nervous system regulation of liver repair. *Anat. Rec. A Discov. Mol. Cell Evol. Biol.* 280, 874-883.
- Oben J.A., Roskams T., Yang S., Lin H., Sinelli N., Torbenson M., Smedh U., Moran T.H., Li Z., Huang J., Thomas S.A. and Diehl A.M. (2004). Hepatic fibrogenesis requires sympathetic neurotransmitters. *Gut* 53, 438-445.
- Panoskaltis-Mortari A. and Bucy R.P. (1995). In situ hybridization with digoxigenin-labeled RNA probes: facts and artifacts. *Biotechniques* 18, 300-307.
- Rieske P., Krynska B. and Azizi S.A. (2005). Human fibroblast-derived cell lines have characteristics of embryonic stem cells and cells of neuro-ectodermal origin. *Differentiation* 73, 474-483.
- Shalabi A. (2004). *Magnetic resonance imaging in chronic Achilles tendinopathy*. Thesis. Karolinska University Press, Stockholm.
- Staudt Y., Mobini R., Fu M., Felix S.B., Kuhn J.P. and Staudt A. (2003). Beta1-adrenoceptor antibodies induce apoptosis in adult isolated cardiomyocytes. *Eur. J. Pharmacol.* 466, 1-6.
- Wall M.E., Faber J.E., Yang X., Tsuzaki M. and Banes A.J. (2004). Norepinephrine-induced calcium signaling and expression of adrenoceptors in avian tendon cells. *Am. J. Physiol. Cell. Physiol.* 287, C912-918.
- Yuan J., Wang M.X. and Murrell G.A. (2003). Cell death and tendinopathy. *Clin. Sports Med.* 22, 693-701.
- Zhang H. and Faber J.E. (2001). Trophic effect of norepinephrine on arterial intima-media and adventitia is augmented by injury and mediated by different alpha1-adrenoceptor subtypes. *Circ. Res.* 89, 815-822.

Accepted August 17, 2007