

Quantitative cell-cycle protein expression in oral cancer assessed by computer-assisted system

C.P. Soares¹, J.A.S. Zuanon², D.B. Teresa¹, P.A Fregonezi¹,
C.B. Neto¹, M.R.B. Oliveira², E.A. Donadi⁴, C.P. Martinelli-Kläy³ and E.G. Soares³

¹Department of Clinical Analysis, School of Pharmacy, University of São Paulo State (UNESP), Araraquara, São Paulo, Brazil,

²Department of Physiology and Pathology, School of Dentistry, University of São Paulo State (UNESP), Araraquara, São Paulo, Brazil,

³Department of Pathology, Faculty of Medicine of Ribeirão Preto, University of São Paulo (USP), Ribeirão Preto, SP, Brazil,

⁴Department of Clinical Medicine, Faculty of Medicine of Ribeirão Preto, University of São Paulo (USP), Ribeirão Preto, SP, Brazil

Summary. The knowledge of cell-cycle control has shown that the capacity of malignant growth is acquired by the stepwise accumulation of defects in specific genes regulating cell growth. Histologic diagnosis might be improved by a quantitative evaluation of more specific diagnosis biomarkers, which could help to precisely identify pre-malignant and malignant oral lesions. The aim of the present study is to evaluate whether computer-based quantitative assessment of p53, PCNA and Ki-67 immunohistochemical expression, could be used clinically to foresee the risk of oral malignant transformation. This retrospective study was carried out in ninety-five oral biopsies, 27 were classified as fibrous inflammatory hyperplasia, 40 as leukoplakia and 28 as oral squamous cell carcinoma. Sixteen out of the 40 leukoplakia were diagnosed as non-dysplastic leukoplakia, the other 24 being dysplastic leukoplakia, of which 50.0% were classified as moderate to severe dysplasia. Comparison of the four groups of oral tissues showed significant rises in p53 and Ki-67 positivity index, which increased steadily in the order benign, pre-malignant, and malignant. In contrast, it was not possible to relate higher PCNA levels with pre-malignant and malignant oral lesions. We therefore conclude that PCNA immunohistochemistry expression is probably an inappropriate marker to identify oral carcinogenesis, whereas joint quantitative evaluation of p53 and Ki-67, appears to be useful as a tumor marker, providing a pre-diagnostic estimate of the potential for cell-cycle deregulation of the oral proliferate status.

Key words: Oral cancer, p53, PCNA, Ki-67, computer-assisted analysis

Introduction

Oral cancer is a frequently-occurring tumor worldwide and oral squamous cell carcinoma (OSCC) in particular is a remarkably common malignancy of the mouth (Saranath et al., 1999; Gasco and Crook, 2003). The incidence of oral cancer varies widely around the world and rates are higher in developed than in developing countries. In Brazil, oral cancer is the fifth most common cancer among males and the seventh among females (Wünsch-Filho, 2002). It's distribution varies from region to region in Brazil, but it is related to lower social strata, higher mortality being observed in deprived areas (Antunes et al., 2001; Wünsch-Filho, 2002).

Progression through the cell-cycle is controlled by a variety of proteins, involved in DNA repair, duplication and separation. The deregulated expression of these cellular proteins, occasioned by several cofactors, has been implicated in malignant cell transformation. The loss of tumor suppressor regulation and a high proliferative activity could contribute to development of oral cancer by a multi-step process. An imbalance between a negative suppressor gene control and positive oncogene expression, as well as a growth-factor pathway of lesions, have been suggested (Scully et al., 2000).

The p53 protein acts as a transcription factor and, by activating transcription of a number of target genes that have DNA binding sites for p53, controls cell-cycle progression and also performs several other cell regulatory functions. It controls cell replication, acting as a G1 checkpoint control but also, if a cell is damaged and repair is impossible, p53 triggers apoptosis -

programmed cell death (Levine, 1997). Alteration of p53 tumor-suppressor genes by mutation or overexpression of dominant inhibitors of its activity constitutes one of commonest genetic aberrations in head and neck human cancers (Nylander et al., 2000). However, studies of p53 protein in oral cancer and other oral lesions, including leukoplakia, are relatively few.

Proliferating cell nuclear antigen (PCNA), a cofactor of DNA polymerase δ , is a 36 kDa nuclear protein with an important role in DNA synthesis, DNA repair, cell-cycle progression and cell proliferation (Liu and Klein-Szanto, 2000). Another cell-cycle protein is Ki-67 antigen, which reflects proliferation activity closely, being short-lived, and peaks in the G2 and M phases (Endl and Gerdes, 2000). Analysis of this proliferation marker has been described as useful in estimating cancerous proliferation (Xie et al., 1999), although their significance in head and neck tumors is still in debate. Some studies have shown a strong correlation between oral lesions grade and increase proliferation indices (Kemp et al., 1998; Krecicki et al., 1999; Fabbrocini et al., 2000) while others were not able to establish this association (Birchall et al., 1997; Sittel et al., 1999).

In order to make clear this controversy, in the present study we investigated the p53, PCNA and Ki-67 immunopositivity quantification, assessed by computer-based image and manual analysis in oral lesions stratified by histologic diagnosis.

Materials and methods

Specimens

Ninety-five oral biopsies were selected from the School of Dentistry, University of São Paulo State (UNESP) and Department of Pathology, School of Medicine of Ribeirão Preto, University of São Paulo (USP) archives, between 1982 and 2005, and their use was approved by the Brazilian institutional ethical committee on human experimentation. Tumor grades were evaluated histologically from tissues stained with hematoxylin and eosin and all the samples were graded according to the criteria recently proposed by Van der Waal and Axéll, 2002. Of the 95 biopsies, 27 were classified as fibrous inflammatory hyperplasia (FIH), 40 as leukoplakia (LKP) and 28 as oral squamous cell carcinoma (OSCC). The LKP group were divided, according to the presence of dysplasia, and 16 were classified as non-dysplastic leukoplakia (LK) and 24 as dysplastic leukoplakia (DLK). Of the 24 DLK, 50.0% (n = 12) were classified as moderate to severe dysplasia. Owing to excessive background or high tissue degradation caused by the antigen retrieval immunohistochemical process, we have analyzed different numbers of biopsies in each group for development of p53, Ki-67 and PCNA staining. Ninety-five biopsies, were used for p53 analysis and were diagnosed as 27 FIH, 16 LK, 24 DLK and 28 OSCC. For the Ki-67 immunohistochemistry technique, 78 biopsies,

were used, of which 17 were FIH, 13 LK, 22 DLK and 26 OSCC. Finally, PCNA staining was performed on 24 FIH, 14 LK, 24 DLK and 17 OSCC, totaling 79 biopsies.

Immunohistochemistry Procedures (p53, PCNA and Ki-67 proteins)

Histological sections of 4 μ m were cut, placed on organosilane-pretreated slides, dewaxed in xylene, rehydrated in graded alcohol and rinsed in water. Endogenous peroxidase activity was blocked by immersion in 3% hydrogen peroxide, for 5 min. in each of five consecutive baths. After washing, the slides were immersed in 10 mM sodium citrate buffer (pH 6.0) and boiled twice for 12 min in a high-intensity microwave oven in order to enhance the immunoreactivity. The sections were allowed to cool at room temperature and subsequently washed in PBS. p53, Ki-67 and PCNA proteins expression were estimated with a streptavidin-biotin system (Duet system, DAKO, Glostrup, Denmark). The slides were incubated with primary monoclonal antibody: p53 (DO-7 diluted 1:500, DAKO), PCNA (PC-10 diluted 1/10.000, DAKO) or Ki-67 antibody (MIB-1 diluted 1:500, Immunotech, Marseille, France), in a humidified chamber at 4°C (overnight), and subsequently with biotinylated anti-rabbit antibody and streptavidin-peroxidase complex (Duet, DAKO) at 37°C for 30 minutes. Between each stage of the above procedures, the sections were carefully rinsed with several changes of PBS. They were then incubated with diaminobenzidine (GIBBICO, Gaithersburg, Maryland, USA), counterstained lightly with Carrazzi's hematoxylin, dehydrated in graded alcohol, cleared in xylene and mounted in Permount mounting medium (MERCK, Darmstadt, Germany). Three controls were included for each reaction: positive, negative and normal. The p53 and PCNA positive controls were sections of OSCC, with high immunohistochemical expression, and the Ki-67 positive control was a section of human tonsil. The negative controls were the same sections that were used as positive controls, omitting the primary antibody from the assay and replacing it with PBS. Sections of normal oral tissue were used as normal controls.

Image acquisition and analysis

Positive nuclei of p53, PCNA and Ki-67 were quantified by the Qwin Image Analysis System (LEICA, Wetzlar, Germany). Images were acquired and then processed and analyzed by the system. A mean of, five microscope fields were selected from the highly positive stained area in order to analyse 1000 nuclei per biopsy and the segmentation was also controlled interactively through the RGB color filter of the system. Moreover, for each section the median number of positive-staining nuclei was counted for both p53 and PCNA staining. For normal p53-positivity evaluation, ten normal oral tissue controls were counted, and a cut-off (1.5%) was

Cell-cycle proteins and oral cancer

established. Expression of p53 was classified by positivity-index (PI), adapted from CRUZ et al., 2002: index I (0 to 1.5%), II (>1.5 to 25%), III (>25 to 50%) and IV (> 50% to 96%). p53 was considered overexpressed for values ranging from >1.3% to 96%. Using ten normal oral tissue controls for PCNA-positive immunostaining, the cut-off was found to be 79% and for this reason the positivity-index (PI) was ranged in only two categories: I (<80%) and II (\geq 80%). PCNA expression was considered to be high when the index was equal to II. To Ki-67, the mean number of positive-staining nuclei was counted in 10 normal oral tissue controls, and a cut-off (15%) was established. Expression of Ki-67 was considered negative from zero positive-staining nuclei up to the cut-off (0 to 15%) and positive for values ranging from >15% to 79%.

p53, PCNA and Ki-67 interobserver quantification

p53, PCNA and Ki-67 immunohistochemistry expression was handle quantified in an optical microscope by three observers, counting the immunolabelling in 1000 nuclei per biopsy and the mean number of positive cells was demonstrated in the percentage.

Statistical analysis

The Kruskal-Wallis and Dunn's Multiple Comparison tests were applied in order to compare quantitatively the immunohistochemical expression of p53, PCNA and Ki-67 among the oral lesions. The Chi-squared (χ^2) test was used for comparisons between the positivity indices to p53, PCNA and Ki-67 staining and histological oral lesion classification. Significance was established if $p < 0.05$.

Results

Among the 95 oral lesions, certain anatomical sites were more common than other ones. In all four groups,

the buccal mucosa was the most frequent location: 10 out of 28 (12.3%) OSCC, 5 out of 16 (6.2%) LK, 10 out of 24 (41.6%) DLK and 13 out of 27(16%) FIH. The second most frequent region was the tongue, followed by the margin of the alveolus with 16 out of 95 (16.8%) and 10 out of 95 (10.5%) biopsies, respectively. Moreover, in biopsies classified as OSCC, the mouth floor, tongue and margin of the alveolus were equally the second most frequent location in 3 out of 28 (10.7%) biopsies.

The quantitative p53, PCNA and Ki-67 immunohistochemical expression results, for each histological grade are displayed in Table 1, Table 2 and Figure 1. The staining images are pictured in Figure 2 and 3. p53 expression increased progressively from group to group in the order FIH, LK, DLK and OSCC (Tables 1, 2, Fig. 1A) and the quantitative expression in both, image analysis (IM) an interobserver quantification (IQ) procedure, seems related with malignant transformation ($p < 0.05$) and could be used as a biomarker of tumor aggressiveness. Positivity of p53 was distributed in the basal layer in FIH, basal and a few cells labeled in the suprabasal layer in LK, basal with many cells labeled in suprabasal layers in DLK and in all layers with a diffuse pattern in the OSCC group. (Fig. 2-A-D). Moreover, p53 staining was absent in 6 (22.2%) FIH, 1 (6.2%) LK and 6 (21.4%) OSCC.

The Kruskal-Wallis test verified no significant difference in PCNA expression, obtained by IM and IQ procedures, among the groups of oral lesions. The labeled nuclei were distributed from the basal up to the epithelial surface, in all oral lesions groups (Tables 1, 2, Figs. 1B, 3A-D).

From these results, Ki-67 was more efficient than PCNA in determining steadily rising proliferation among benign, pre-malignant and malignant oral lesions (Tables 1, 2, Figs. 1C, 3E-H). However, Ki-67 could not identify a significant difference of labeling between FHI and LK ($p > 0.05$). Ki-67 positivity was distributed (Fig. 3E-H) in the basal layer in FIH group, basal and a few cells labeled in suprabasal layers in LK, basal up to a large

Table 1. Mean (M) and standard deviation (SD) of p53, PCNA and Ki-67 quantitative immunohistochemical expression for each histopathological grade of oral lesions, performed by image analyse (IM) and interobserver quantification (IQ).

| | FIH | | LK | | DLK | | OSCC | |
|--------------------|-----------|----------|-----------|-----------|-----------|-----------|-----------|-----------|
| | IM | IQ | IM | IQ | IM | IQ | IM | IQ |
| p53 ^a | | | | | | | | |
| (M+ SD) | 8.1±7.7 | 8.7±6.2 | 9.7±8.4 | 10.9±7.3 | 29.2±10.4 | 30.8±11.1 | 41.3±32.7 | 40.5±30.1 |
| PCNA ^b | | | | | | | | |
| (M+ SD) | 88.4±9.8 | 92.6±8.2 | 88.5±11.5 | 87.3±9.9 | 98.5±4.8 | 97.3±3.5 | 94.2±9.7 | 93.4±9.9 |
| Ki-67 ^c | | | | | | | | |
| (M+ SD) | 24.9±10.0 | 22.3±9.8 | 31.4±11.0 | 29.9±10.5 | 38.9±9.4 | 35.2±9.9 | 50.4±16.1 | 51.1±14.2 |

FIH: Fibrous inflammatory hyperplasia; LK: leukoplakia; DLK: dysplastic leukoplakia; OSCC: Oral squamous cell carcinoma. ^a: Kruskal-Wallis, $P = 0.006$; $p < 0.05$; ^b: Kruskal-Wallis, $P = 0.6899$; $p > 0.05$; ^c: Kruskal-Wallis, $P = 0.0003$; $p > 0.05$. ^{a, c} Dunn's Multiple Comparison post test $p < 0.05$: p53: FIH vs DLK, FIH vs OSCC, LK vs OSCC, LK vs DLK; Ki-67: FIH vs DLK, FIH vs OSCC, LK vs OSCC, LK vs DLK, DLK vs OSCC.

number of cells labeled in suprabasal layer in DLK and in all layers from basal to epithelial cell surface in the OSCC group. No biopsies were negative for PCNA or Ki-67 immunostaining.

Discussion

Semi-quantitative evaluation and manual cell counting are the commonly used procedures to assess positive staining of molecular markers in tissue sections (Colleta et al., 2001; Garcia-Pola et al., 2001). In the present study, no difference was found between manual

and image analysis of the three immunohistochemistry markers. However, manual cell counting might be replaced by image analyses methods which provide several benefits such as speed analysis, consistency and automation (Loukas et al., 2003).

Thus, as exposed, our quantitative results demonstrate that p53 positivity increased gradually in order of histological progression from benign through pre-malignant to malignant (Piatelli et al., 2002). Higher nuclear scores were related with dysplastic and oral cancer cells while low nuclear scores are more effective in normal and benign lesions (Liu et al., 1999). p53 has been reported as a predictor of tumor differentiation (Yamamoto et al., 2002) and together with histological diagnosis of epithelial dysplasia might accurately predict the malignant cell transformation (Sittel et al., 1999). Thus, p53 could be used in order to identify more precisely those lesions likely to become cancerous (Silverman and Sugerma, 2000). In addition, we found that p53 was expressed only in basal layers in FIH, in basal and suprabasal layers in LK, in basal and predominantly the suprabasal layers in DLK and all layers, with a diffuse pattern in OSCC. Distribution of p53 immunohistochemical expression in the different cell layers and dysplastic atypia have been regarded as important parameters for prediction of neoplasm transformation (Cruz et al., 1998, 2000; Piatelli et al., 2002). However, the value of p53 immunostaining distribution pattern is still controversial, although it has been considered as a feature associated with potential malignant transformation in oral tissues (Cruz et al., 2002) or unable to establish this relationship (Chang et al., 2000). Despite the controversy, our results demonstrated that p53 overexpression, assessed by quantitative and tissue distribution measurements, might be useful to verify the potential of malignant transformation of oral lesions.

In contrast, our findings also demonstrated that some pre-malignant (LK and DLK) and malignant oral lesions were negative to p53 immunohistochemical expression. The absence of p53 does not preclude malignant transformation and other factors may have led to p53 dysfunction (e.g. HPV, EBV, MDM2), resulting in

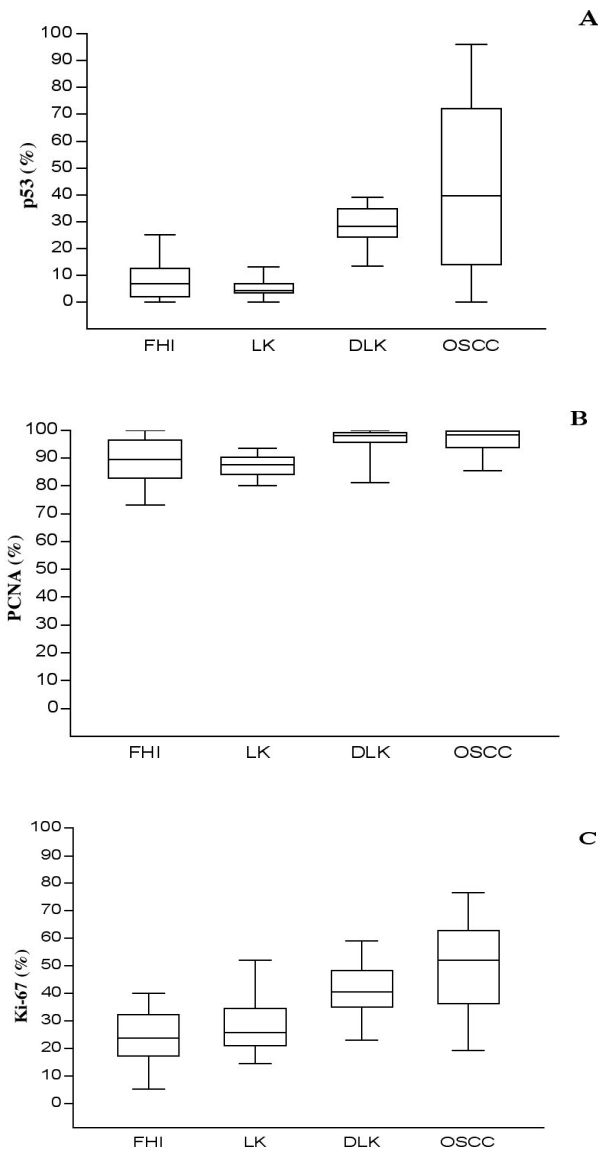


Fig. 1. Box plot of p53, PCNA and Ki-67 quantitative immunohistochemistry expression (A, B and C, respectively), for each histopathological group of oral lesions.

Table 2. Distribution of oral biopsies in positivity index for p53, PCNA and Ki-67 immunostaining.

| | p53 ^a | | | | PCNA ^b | | Ki-67 ^c | | | |
|------|------------------|----|-----|----|-------------------|----|--------------------|----|-----|----|
| | I | II | III | IV | I | II | I | II | III | IV |
| FIH | 6 | 20 | 1 | 0 | 3 | 21 | 3 | 7 | 7 | 0 |
| LK | 2 | 13 | 1 | 0 | 1 | 13 | 0 | 2 | 8 | 1 |
| DLK | 1 | 15 | 8 | 0 | 1 | 23 | 0 | 6 | 12 | 6 |
| OSCC | 6 | 6 | 4 | 12 | 2 | 15 | 0 | 2 | 10 | 14 |

FIH: Fibrous inflammatory hyperplasia; LK: leukoplakia; DLK: dysplastic leukoplakia; OSCC: Oral squamous cell carcinoma; Chi-squared (χ^2) Test: ^a P=0.0072, p<0.005; ^b P=0.7346; p>0.05; ^c P=0.0003; p<0.05

Cell-cycle proteins and oral cancer

negative immunoeexpression (Soares et al., 2003). Moreover, mutation of p53 could result in a different p53 protein, which may be undetectable by commercial antibodies, resulting in oral cancer p53 negative (Nylander et al., 2000).

Conventionally, oral tumor kinetics have been assessed by the manual quantification of PCNA and Ki-67 immunostaining (Chiang et al., 2000; Liu and Klein-Szanto, 2000; Colleta et al., 2001; Hafian et al., 2004) and few studies have quantified Ki-67 immunostaining through the morphometric computer program of the image-analysis equipment (Kushner et al., 1997; Tumuluri et al., 2002). In the present study, we verified the quantitative Ki-67 immunoeexpression, assessed by computer-assisted system, increasing steadily among

benign, pre-malignant and OSCC lesions. Ki-67/Mib-1 has been considered a more reliable tool for measuring proliferation activity in human tissues and could be detected in the nuclei of proliferating cells in all active phases of the cell-division cycle but is absent in non-proliferating cells (Endl and Gerdes, 2000). The assessment of cell proliferation activity by Ki-67 immunoreaction has been extensively studied in the search for new prognosis parameters in a wide variety of tumors (Ikeguchi et al., 1997; Krescicki et al., 1999). Previous studies demonstrated that Ki-67 immunohistochemical expression increased regularly according the histological grade (Matsumoto et al., 1999; Warmakulasuriya, 2000). In agreement with this studies, our result seems also to demonstrate that Ki-67

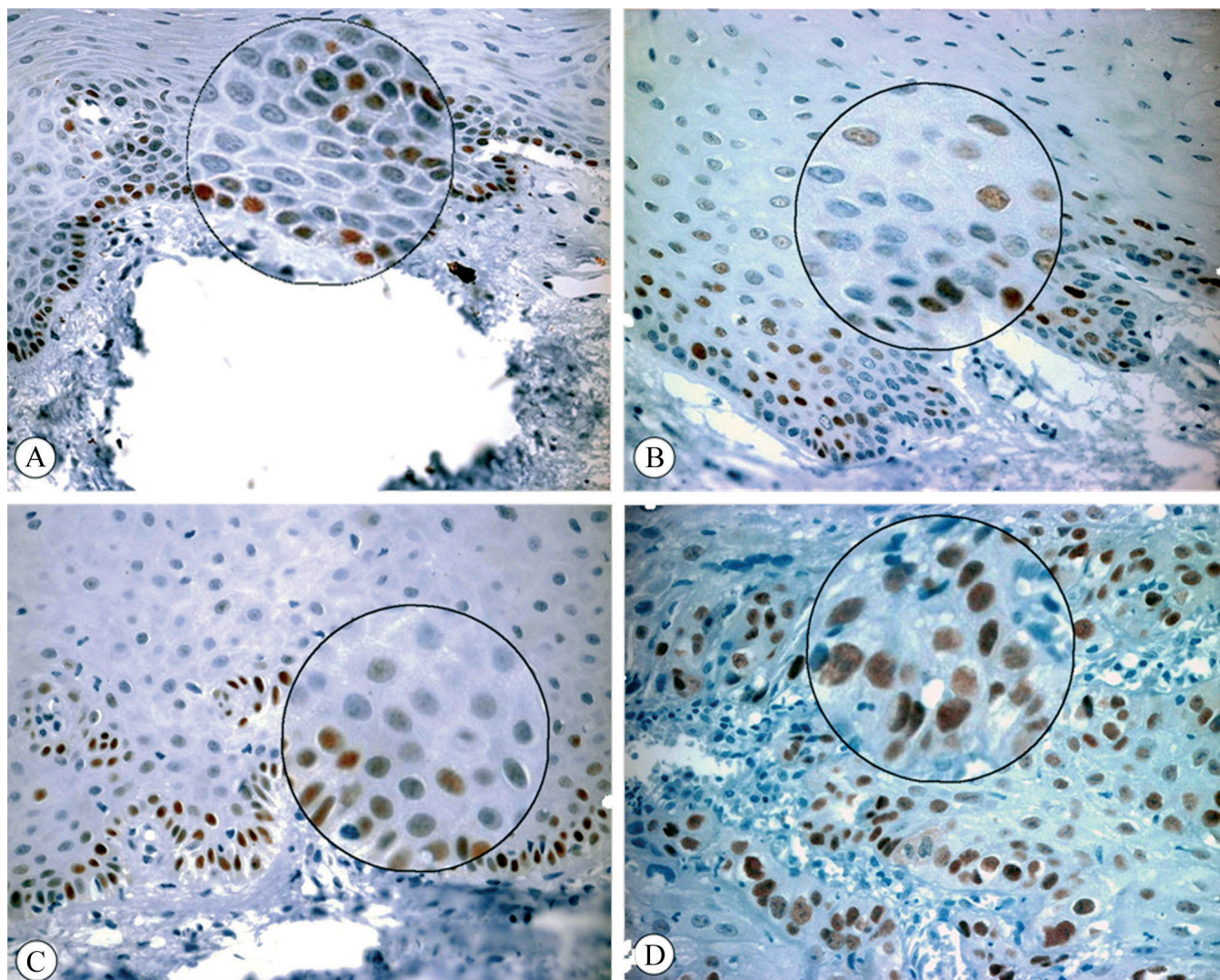


Fig. 2. Immunohistochemical expression of p53 in benign, pre-malignant and malignant oral lesions and a detailed view. **A.** Fibrous inflammatory hyperplasia. **B.** Leukoplakia. **C.** Dysplastic leukoplakia. **D.** Oral squamous cell carcinoma. x 400

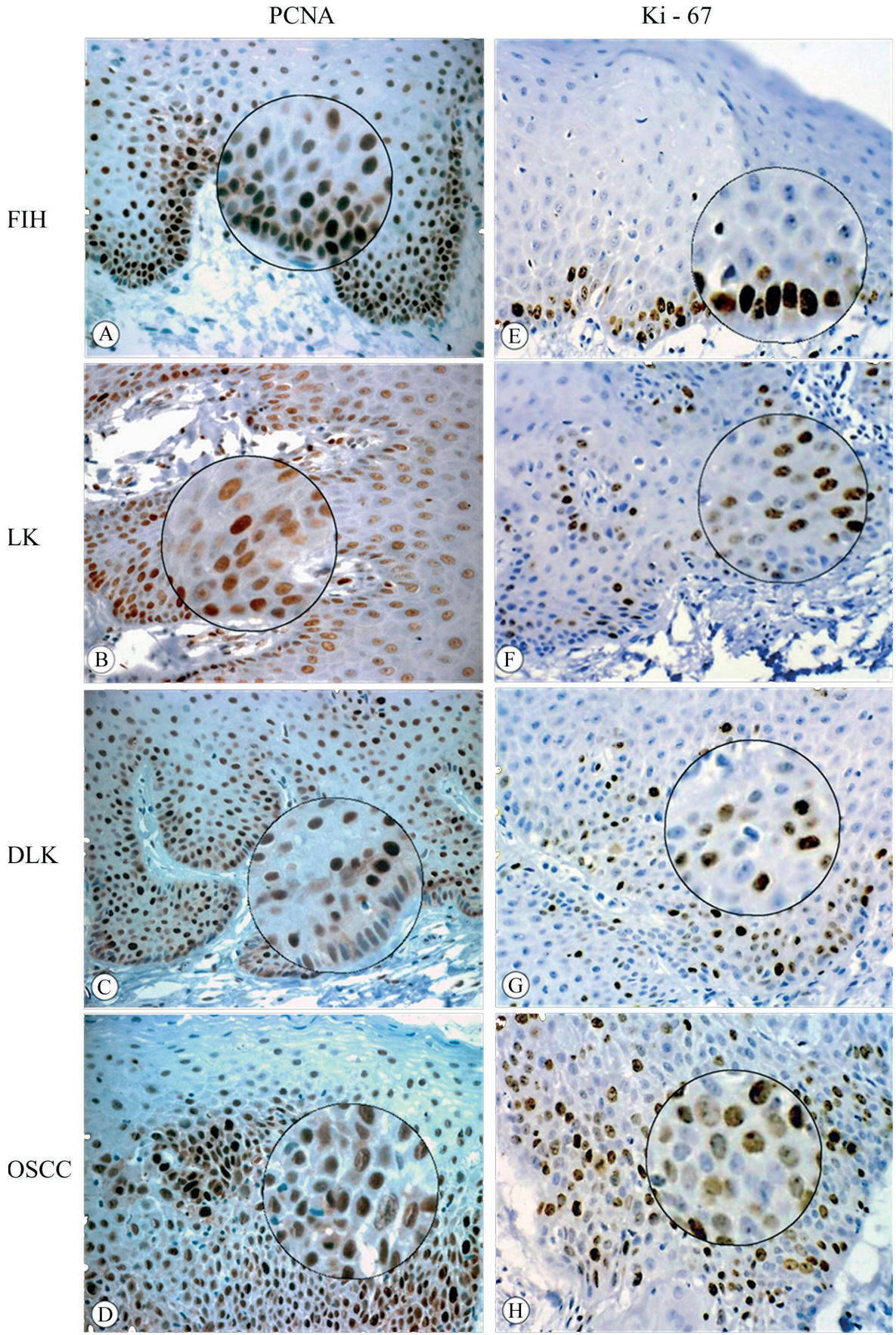


Fig. 3. Immunohistochemical expression of PCNA and Ki-67 in benign (FIH), pre-malignant (LK and DLK) and malignant (OSCC) oral lesions and a detailed view: (A to D) PCNA-positivity; (E to H) Ki-67-positivity. x 400

Cell-cycle proteins and oral cancer

immunohistochemistry evaluation could identify oral lesions with differences in proliferative status.

Ki-67 immunolabeling could distinguish LK from DLK, mainly in oral biopsies presenting moderate to severe dysplasia (15 out of 24 DLK, 62.5%). One of the important characteristics of neoplastic transformation of a steady-state epithelial system is the alteration of growth rate, commonly reflected as increased cell proliferation (Tumuluri et al., 2002) but the occurrence and evolution of dysplasia to malignant lesions, seems uncertain. Apparently a lower degree of dysplasia has less proliferative activity, implying a slower evolution to malignant status. Despite the significance of the degree of dysplasia, it has been claimed that patients with mild dysplasia or even without evidence of dysplasia are at risk of transformation and should be followed carefully (Schepman et al., 1998). Thus, in the present study it was possible to verify that Ki-67 might be able to detect a higher proliferative rate of leukoplakia.

The gradual rising and tissue distribution of PCNA labeling in benign, pre-malignant and oral cancer has been correlated with increased proliferative activity (Sandra et al., 2001). Some investigators have reported on the significance of PCNA, using grades of nuclear and histological differentiation (Chiang et al., 2000). We very able to verify in the present study that all oral biopsies showed high PCNA levels. The quantitative and tissue distribution of PCNA immunostaining are unable to distinguish progressive proliferative status among oral lesions independent of histological grade, according to some preliminary studies and in contrast to our Ki-67 labeling results (Birchall et al., 1997; Sittel et al., 1999). PCNA has a long half-life, resulting in staining of cells that recently left the cell cycle (Liu and Klein-Szanto, 2000) and it seems to be detected in a larger number of cycling cells than Mib-1 (Kawashira, 1999; Chiang et al., 2000). Our results could indicate that PCNA staining was not able to characterize gradual differences between oral lesions which, at first sight, have different proliferative status.

In conclusion, the overexpression and immunostaining patterns of p53, and increase cell proliferation detected by Ki-67 quantification, could be used to predict malignant transformation. On the other hand, PCNA seems not to be useful for this purpose.

Acknowledgements. We thank the financial support provided by FUNDUNESP and Department of Pediatric Dentistry (UNESP). We wish to thank Ana Maria Rocha for excellent technical assistance.

References

- Antunes J.L., Biazevic M.G., de Araújo M.E., Tomita N.E., Chinellato L.E. and Narvai P.C. (2001). Trends and spatial distribution of oral cancer mortality in São Paulo, Brazil, 1980-1998. *Oral Oncol.* 37, 345-350.
- Birchall M.A., Schock E., Harmon B.V. and Gobe G. (1997). Apoptosis, mitosis, PCNA and bcl-2 in normal, leukoplakic and malignant epithelia of the human oral cavity: prospective, *in vivo* study. *Oral Oncol.* 33, 419-425.
- Chang K.W., Lin S.C., Kwan P.C. and Wong Y.K. (2000). Association of aberrant p53 and p21 WAF1 immunoreactivity with the outcome of oral verrucous leukoplakia in Taiwan. *J. Oral Pathol. Med.* 29, 56-62.
- Chiang C.P., Lang M.J., Liu B.Y., Wang J.T., Leu J.S., Hahn L.J. and Kuo M.Y. (2000). Expression of proliferating cell nuclear antigen (PCNA) in oral submucous fibrosis, in oral epithelial hyperkeratosis and oral epithelial dysplasia in Taiwan. *Oral Oncol.* 36, 353-359.
- Coletta R.D., Cotrim P., Vargas P.A., Villalba H., Pires F.R., de Moraes M. and de Almeida O.P. (2001). Basaloid squamous carcinoma of the oral cavity: report of 2 cases and study of AgNOR, PCNA, p53, and MMP expression. *Oral Surg. Oral Med. Oral Pathol. Oral Radiol. Endod.* 91,563-9.
- Cruz I.B., Snijders P.J., Meijer C.J., Braakhuis B.J., Snow G.B., Walboomers J.M. and van der Waal I. (1998). p53 expression above the basal cell layer in oral mucosa is an early event of malignant transformation and has predictive value for developing oral squamous cell carcinoma. *J. Pathol.* 184,360-368
- Cruz I.B., Meijer C.J., Snijders P.J., Snow G.B., Walboomers J.M. and van der Waal I. (2000). p53 immunoeexpression in non malignant oral mucosa adjacent to oral squamous cell carcinoma: potential consequences for clinical management. *J. Pathol.* 191, 132-137.
- Cruz I.B., Napier S.S., van der Waal I., Snijders P.J., Walboomers J.M., Lamey P.J., Cowan C.G., Gregg T.A., Maxwell P. and Meijer C.J. (2002). Suprabasal p53 immunoeexpression is strongly associated with high grade dysplasia and risk for malignant transformation in potentially malignant oral lesions from Northern Ireland. *J. Clin. Pathol.* 55, 98-104.
- Endl E. and Gerdes J. (2000). The Ki-67 protein: Fascinating forms and an unknown function. *Exp. Cell Res.* 257, 231-237.
- Fabbrocini G., Russo N., Pagliuca M.C., Delfino M., Staibano S., Molea A., Virgili A., Valente M.G., Bratina G., Galbiati S., Marzaduri A., Orlandi K., Bottoni U., Calvieri S., Di Landro A., Cainelli T., Delfino S. and De Rosa G. (2000). p53, cyclin-d1, PCNA, AgNOR expression in squamous cell carcinoma of the lip: a multicenter study. *Photodermatol. Photoimmunol. Photomed.* 16, 172-177.
- Garcia-Pola V.M.J., Roldan A.M.J., Alvarez F.B.E., Martin G.J.M. and Lopez-Muniz A (2001). Study comparative of Ki-67 expression in oral lichen planus and oral leukoplakia. *Quantitative analysis. Med. Oral.* 6, 364-370.
- Gasco M. and Crook T. (2003). The p53 network in head and neck cancer. *Oral Oncol.* 39, 222-231.
- Hafian H., Venteo L., Sukhanova A., Nabiev I., Lefevre B. and Pluot M. (2004). Immunohistochemistry study of DNA topoisomerase II alpha, p53 and Ki-67 in oral preneoplastic lesions and oral squamous cell carcinomas. *Human Pathol.* 35, 745-751.
- Ikeguchi M., Saito H., Katano K., Tsujitani S., Maeta M. and Kaibara N. (1997). Clinicopathologic significance of the expression of mutated p53 protein and the proliferative activity of cancer cells in patients with esophageal squamous cell carcinoma. *J. Am. Coll. Surg.*185, 415-421.
- Kawahira K. (1999). Immunohistochemical staining of proliferating cell nuclear antigen (PCNA). in malignant and nonmalignant skin disease. *Arch. Derm. Res.* 291, 413-418.
- Kemp C., Alberti V.N., Lima G.R. and Carvalho F.M. (1998). How should PCNA be assessed? Total os stained cells or only the most intensely stained ones? *São Paulo Medical Journal/RPM.* 116, 1667-1674.

- Krecicki T., Jelen M., Zalesska-Krecicka M., Rak J., Szkudlarek T. and Jelen-Krzeszewska J. (1999). Epidermal growth factor receptor (EGFR), proliferating cell nuclear antigen (PCNA), and Ki-67 antigen in laryngeal epithelial lesions. *Oral Oncol.* 35, 180-186.
- Kushner J., Bradley G. and Jordan R.C. (1997). Patterns of p53 and Ki-67 protein expression in the epithelial dysplasia from the floor of mouth. *J. Pathol.* 183, 418-423.
- Levine A.J. (1997). p53, the cellular gatekeeper for growth and division. *Cell* 88, 323-331.
- Liu S.C., Hu Y., Sauter E.R., Clapper M.L., Chen S.Y., Lanfranchi H.E., Engstrom P.F. and Klein-Szanto A.J. (1999). Image analysis of p53 and cyclin D1 expression in pre-malignant and malignant oral lesions of the oral mucosa. *Anal. Quant. Cytol. Histol.* 21, 166-73.
- Liu S.C. and Klein-Szanto A.J.P. (2000). Markers of proliferation in normal and leukoplakic oral epithelia. *Oral Oncol.* 36, 145-151.
- Loukas C.G., Wilson G.D., Vojnovic B. and Linney A. (2003). An image analysis-based approach for automated counting of cancer cell nuclei in tissue sections. *Cytometry* 55A, 30-42.
- Matsumoto M., Komiyama K., Okaue M., Shimoyama Y., Iwakami K., Namaki S., Tanaka H., Moro I. and Sato H. (1999). Predicting tumor metastasis in patients with oral cancer by means of the proliferation marker Ki67. *J. Oral. Sci.* 41, 53-56.
- Nylander K., Dabelsteen E. and Hall P.A. (2000). The p53 molecule and its prognostic role in squamous cell carcinoma of the head and neck. *J. Oral Pathol. Med.* 29, 413-425.
- Piattelli A., Rubini C., Fioroni M., Iezzi G. and Santinelli A. (2002). Prevalence of p53, and ki-67 immunoreactivity and of apoptosis in normal oral epithelium and in pre-malignant and malignant lesions of oral cavity. *J. Oral Maxillofac. Surg.* 60, 532-540.
- Sandra F., Mitsuyasu T., Nakamura N., Shiratsuchi Y. and Ohishi M. (2001). Immunohistochemical evaluation of PCNA and Ki-67 in ameloblastoma. *Oral Oncol.* 37, 193-198
- Saranath D., Tandle A.T., Teni T.R., Dedhia P.M., Borges A.M., Parikh D., Sanghavi V. and Mehta A.R. (1999). p53 inactivation in chewing tobacco-induced oral cancers and leukoplakias from India. *Oral Oncol.* 35, 242-250.
- Schepman K.P., van der Meije E.H., Smeele L.E. and van der Waal I. (1998). Malignant transformation of oral leukoplakia: a follow-up study of a hospital-based population of 166 patients with oral leukoplakia from The Netherlands. *Oral Oncol.* 34, 70-275.
- Scully C., Field J.K. and Tanzawa H. (2000). Genetic aberrations in oral head and neck squamous cell carcinoma (SCCHN): 1. Carcinogen metabolism, DNA repair and cell cycle control. *Oral Oncol.* 36, 256-263.
- Silverman S. and Sugarman P.B. (2000). Oral premalignancies and squamous cell carcinoma. *Clinics Dermatol.* 18, 563-568.
- Sittel C., Ruiz S., Volling P., Kvasnicka H.M., Jungehulsing M. and Eckel H.E. (1999). Prognostic Significance of ki-67 (MIB1), PCNA and p53 in cancer of oropharynx and oral cavity. *Oral Oncol.* 35, 583-589.
- Soares C.P., Benatti Neto C., Fregonezi P.A., Teresa D.B., Santos R.T., Longatto Filho A. and Maeda M.Y. (2003). Computer-assisted analysis of p53 and PCNA expression in oral lesions infected with human papillomavirus. *Anal. Quant. Cytol. Histol.* 25, 19-24.
- Tumuluri V., Thomas G.A. and Fraser I.S. (2002). Analysis of the Ki-67 antigen at the invasive tumor front of human oral squamous cell carcinoma. *J. Oral Pathol. Med.* 32, 598-604.
- Van der Waal I. and Axéll T. (2002). Oral leukoplakia: a proposal for uniform reporting. *Oral Oncol.* 38, 521-526.
- Warmakulasuriya S. (2000). Lack of molecular markers to predict malignant potential of oral pre-cancer. *J. Pathol.* 190, 407-409.
- Wünsch-Filho V. (2002). The epidemiology of oral and pharynx cancer in Brazil. *Oral Oncol.* 38, 737-746.
- Xie X., De Angelis P., Clausen O.P. and Boysen M. (1999). Prognostic significance of proliferative and apoptotic markers in oral tongue squamous cell carcinomas. *Oral Oncol.* 35, 502-509.
- Yanamoto S., Kawasaki G., Yoshitomi I. and Mizuno A. (2002). p53, mdm2, and p21 expression in oral squamous cell carcinomas: Relationship with clinicopathologic factors. *Oral Surg. Oral Med. Oral Pathol. Oral Radiol. Endod.* 94, 593-600.

Accepted January 30, 2007