

Histomorphogenesis and immunohistochemical study of the bovine pineal gland (*Bos taurus*) during prenatal development (160 days of gestation to birth)

S. Regodón¹, D. Pozo² and V. Roncero¹

¹Department of Anatomy and Histology, Faculty of Veterinary Medicine, University of Extremadura, Cáceres, Spain and

²Department of Biochemistry and Molecular Biology, Faculty of Medicine, University of Seville, Seville, Spain

Summary. The ontogenesis of the pineal gland of 20 bovine embryos (*Bos taurus*) has been analysed from 160 days of gestation to birth by means of optical microscopy and immunohistochemical techniques. For this study, the specimens were grouped into two stage in accordance with the most relevant histological characteristics: Stage 1 (160 to 200 days of prenatal development) and Stage 2 (220 days of prenatal development to birth). At 160 days of gestation some rounded structures with a central lumen, which we refer to as glandular rosettes, begin differentiation from the epithelium of the pineal recess, experiencing an extraordinary increase in number and size at 200 days of intrauterine life. In the interior of the pineal parenchyma we observed some morphologically rounded cells with oval euchromatic nuclei and a well-differentiated nucleolus that we refer to as the pinealoblasts. We also observed other cells characterised by the presence of low cytoplasm and rounded and highly stained nuclei that we refer to as the interstitial cells. The glandular stroma is formed from the capsular, trabecular, and perivascular connective tissue as well as from the reticular network that comes from the cellular processes of the interstitial cells. The blood vessels, at 240 of gestation, show well-formed walls where the endothelial cells stand out.

At 160 days of gestation we witnessed some cells with small, dense, oval nuclei, positive to the glial fibrillary acidic protein (GFAP). At this age NPY positive fibres were detected, distributed around the blood vessels and among the pinealoblasts.

We conclude by clarifying that the changes detected in the morphology as well as in the number and size of glandular rosettes appear to be related to the functional activity of the pineal gland during embryonic development.

Key words: Histomorphogenesis, Immunohistochemical, Pineal gland, Bovine, Development

Introduction

Interest in the pineal gland increased after the discovery of melatonin by Lerner et al. (1958). From a phylogenetic point of view, the evolution of this structure is still not clear. It has a photoreceptor function in primitive vertebrates and a secretory function in mammals. In mammals, the pineal gland is known to be involved in the photoperiodic regulation of endogenous biological rhythms (Reiter, 1991). In light-dependent animals, melatonin secretion by the pineal gland is essential to the photoperiodic response.

The pineal gland, which in mammals develops from the diencephalic ependyma and during embryonic development is located between the anterior and the posterior commissure (Redondo et al., 1996; Regodón et al., 1998; Regodón and Roncero, 2005), has been extensively studied with a variety of biochemical, physiological and pharmacological techniques. However, throughout the years, one of the least analysed aspects of the pineal gland has been its embryonic development (ontogenesis). Similarly, it is worthwhile pointing out that very few studies have been published in relation to embryonic development of the bovine pineal gland (Brack, 1962; Anderson, 1965; Regodón and Roncero, 2005).

Brack (1962) analyses, from a morphogenic as well as histological point of view, the evolution of the bovine pineal gland throughout its development. It is of note that this development begins in embryos of 4 cm long as a simple evagination of the diencephalic roof; an evagination that will later be surrounded by ependymal cells. He concludes by showing that the final size of the pineal gland reaches approximately 90 cm. Anderson (1965) points out the characteristic layout of the pineal cells in the shape of rosettes around a small central

lumen. This arrangement mostly appears in the anterior, mid and posterior regions of the gland.

Regodón and Roncero (2005) analyses the ontogenesis of the pineal gland of bovine embryos (*Bos taurus*) from 30 until 135 days of gestation. At 1.7cm (30 days of intrauterine life) the first glandular outline becomes differentiated from the diencephalic ependyma of the third ventricle. This differentiation includes the phenomena of proliferation and multiplication of the ependymal cells that form the epithelium of the pineal outline in development. At 82 days of intrauterine life, in the interior of the pineal parenchyma, we witnessed some incipient pseudoglandular structures that at 135 days were well differentiated. The pineal parenchyma, at 70 days of embryonic development, is formed from two cellular types of structurally distinct characteristics: pinealoblasts and interstitial cells.

In the present study we describe the structural and immunohistochemical observations of the pineal gland during prenatal life (160 days of gestation to birth) in the bovine (*Bos taurus*).

Materials and methods

Animals

Twenty clinically healthy bovine embryos (*Bos taurus*) at different stages of development were used for this study. The embryos were obtained from a slaughterhouse in Olivenza (Badajoz, Spain), 5 min after the animals were killed. The animals were killed in the morning from June to November. The specimens were put into two age stage, each containing ten embryos, defined in terms of the most relevant histological features: Stage 1 (40 to 60 cm C-R, 160 to 200 days of prenatal development), and Stage 2 (70 to 90 cm C-R, 220 days of prenatal development to birth). Once separated from maternal linking, embryos were euthanized by umbilical vein administration of 1 g Pentothal (thiopental sodium, Abbott, Madrid, Spain) in a 10% aqueous solution. Size-age estimates were performed according to the methodology proposed by Evans and Sack (1973).

Fixation of tissues

The heads of the embryos of ages between 160 days of gestation to birth were transferred to the dissection laboratory of Anatomy and Embryology. The skull was opened by means of an oscillating surgical saw. Dissections were carried out (according to the methodology proposed by Gázquez, 1987) with the aim of extracting the encephalon block with its cranial layer in development. The encephalon block was transferred to an appropriate receptacle, containing physiological serum, and we proceeded with the identification of the cerebellum and both cerebral hemispheres based on their external morphological characteristics. After separating both cerebral hemispheres laterally we entered the pineal

gland. The bovine pineal gland with the adjacent epithalamic regions were immediately fixed in 4% paraformaldehyde in 0.1 M phosphate buffer (pH 7.4) at 4°C for about 48-72 hours.

Light microscopy

The bovine pineal gland and adjacent epithalamic regions were post-fixed in the same fixative for about 48 hours, and processed by the paraffin-embedding method. Sections 4 µm thick were cut sagittally and stained with hematoxylin and eosin (HE) and Gomori's method for reticulum fibres (RG). Finally, for detection of glial-type cells, staining with phosphotungstic acid hematoxylin (PTAH) was carried out.

Immunohistochemistry

ExtrAvidin Peroxidase Staining (EAS) was performed on deparaffinised pineal sections to detect glial cell markers (glial fibrillary acidic protein -GFAP-) and markers of peptidergic innervation (neuropeptide Y -NPY-). First, tissue was deparaffinised, hydrated and treated sequentially with 0.5% hydrogen peroxide for 20 min in order to block endogenous peroxidase activity. Sections were blocked by incubation in diluted (1:50) normal swine serum (Dako, Madrid, Spain) for 15 min to reduce background. Samples were incubated with the following dilution in PBS of primary antisera: 1:500 rabbit anti-bovine GFAP (Dako, Madrid, Spain) and 1:500 rabbit anti-NPY (Sigma/Aldrich Química, Madrid, Spain) for 4 hr at 20°C. After the incubation, the sections were washed for 3X10 min in PBS. Biotinylated swine anti-rabbit IgG (1:200 dilution) (Dako, Madrid, Spain) was then added to the sections for 30 min. Sections were finally incubated with diluted (1:50) ExtrAvidin-Horseradish Peroxidase (Sigma/Aldrich Química, Madrid, Spain) for 1 hr. After diaminobenzidine reaction, nuclear counterstaining with Mayer hematoxylin was applied. Finally the sections were mounted with Entellan.

The specificity of the staining reaction was determined in control experiments. These comprised, substitution of the primary antibody by PBS or normal rabbit serum 1:100; or omission of both primary and secondary antibodies; and prior absorption of the primary antibody (overnight preincubation of the primary antisera with the respective peptide 50-100 µM). Next, the antibody/peptide mixture was applied to sections in the identical manner and concentration of the primary antibody.

Morphometrical analysis

Numerical cell density was determined by calculating the number of PTAH and GFAP positive cells. Five sections, separated from each other by a distance of roughly 50 µm were taken for each gland. Ten fields measuring 10.000 µm² were randomly

Histomorphogenesis of bovine pineal gland

selected per section. Fields and sections were identical for both staining techniques. Calculations were made manually by using projected images. Morphometrical analysis was based on random sampling, the sample being considered satisfactory when the standard deviation was less than 5% of the mean; the formula proposed by Aherne and Dunnill (1982) was employed: $n = (s/0.05x)^2$, where n is the number of samples, s is the standard deviation of sample, x is the sample mean and 0.05 is the desired error.

Results

Histomorphogenesis observations

Stage 1 (160 to 200 days of prenatal development)

Macroscopically, the pineal gland in the fetuses that make up this age group (40 to 60 cm C-R) display an elongated type morphology, its distal end being thinner and more pointed than its proximal one. Its proximal end, or base, which is wider, remains joined to the rest of the nerve parenchyma by means of the habenular and posterior commissures. This base and both commissures delimit the pineal recess, which is extensively connected to the cavity of the third ventricle. In general terms, the appearance of the epiphysis is one of a compact gland.

At 40 cm C-R (160 days of gestation) and from a microscopic perspective (Fig. 1) we observed a well-formed gland, lengthened and surrounded by a thin connective capsule. The pineal parenchyma is compact, delimited by connective walls that go from the capsule (Fig. 2) and which are accompanied on their journey by vascular structures. These structures are well differentiated. This greater vascular differentiation can be appreciated by the greater number of reticular argyrophil fibres and by the presence of wider and more clearly defined lumina (Fig. 2). From the epithelium of the pineal recess we observed some rounded structures with a central lumen that displayed a glandular appearance, which we have named rosettes (Figs. 1, 3). These rosettes began to be formed from the bottom of the pineal recess sack. They were initially observed as some groupings and/or cell condensations with lengthened nuclei and extremely condensed chromatin (Fig. 3), similar to the cells that form the epithelium of both commissures.

In the interior of the parenchymal gland (Fig. 4) we continued to observe some morphologically rounded cells with abundant vacuolar cytoplasm, oval euchromatic nuclei and a well-differentiated nucleolus that we refer to as pinealoblasts.

On the other side, we observed other cells, less numerous than the previous ones, characterised by the presence of low cytoplasm, rounded and highly stained nuclei, referred to as the interstitial cells, that appear forming small groupings in all of the pineal parenchyma. These interstitial cells are PTAH positive (Fig. 4).

At 180 days of gestation (50 cm C-R),

microscopically, we continued to observe the progressive growth of the pineal gland, its trabecular and vascular components becoming clearer and clearer (Fig. 5). The cellular elements that make up the glandular parenchyma continue to be represented by the pinealoblasts and by the interstitial cells that in this stage of development are seen to be more and more dispersed around the aforementioned parenchyma (Fig. 6). The glandular structures that we have named rosettes proceed with their gradual growth in number.

At 60 cm (200 days of gestation) the pineal gland continues growing in size, becoming more and more elongated and finding itself covered by a more evident capsule. As a fundamental feature of this age we should express the extraordinary growth in number and size of the glandular rosettes (Fig. 7). These rosettes display different forms and are found present in the distal parts of the gland. Conversely, the parenchyma that surrounds the pineal recess is seen to be very compact and formed by numerous cellular elements.

The pineal recess (Fig. 7) becomes less and less evident, adopting an increasingly narrower morphology. This recess is seen to be delimited by both the habenular and posterior commissures, both of which display a progressive diminution in their diameters.

At this age, we start to observe an extraordinary cellular proliferation in the glandular periphery. As a result of this proliferation a grouping of these cells is produced, a grouping that will later end up forming what we have called the rosettes (Figs. 8, 9), which as their maturity is reached immediately emigrate towards the interior of the pineal parenchyma.

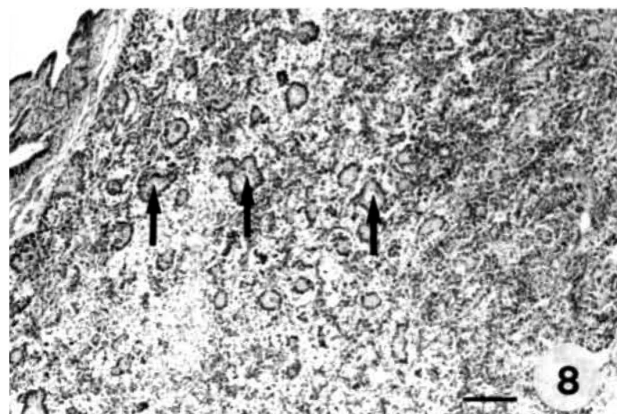
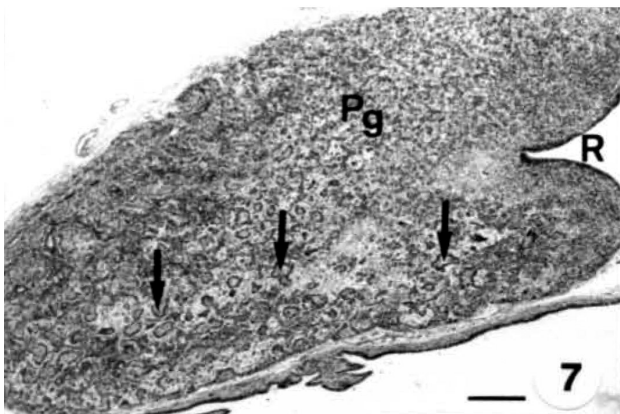
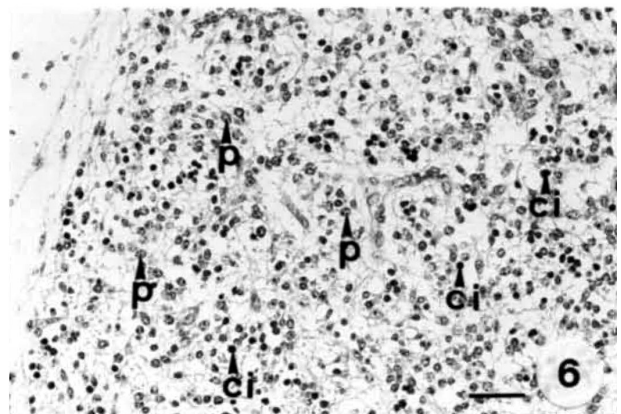

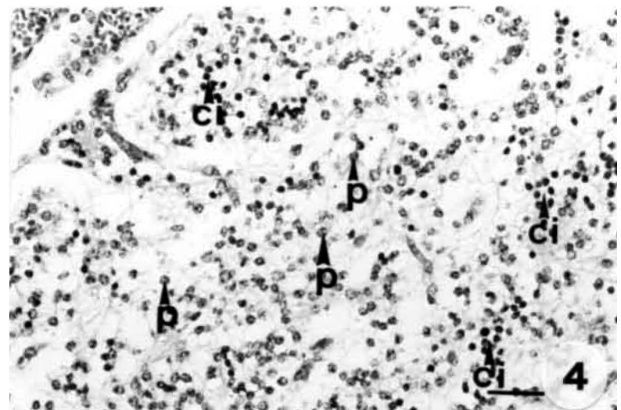
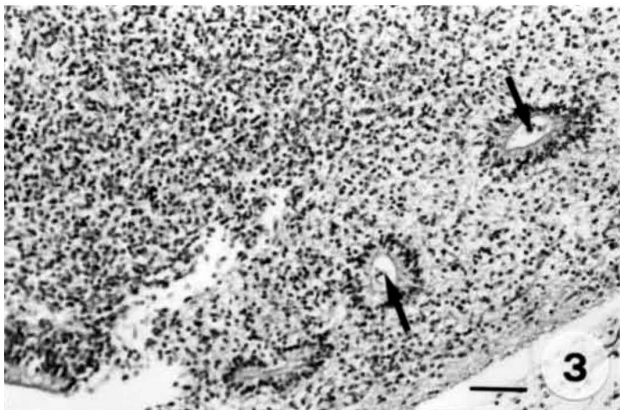
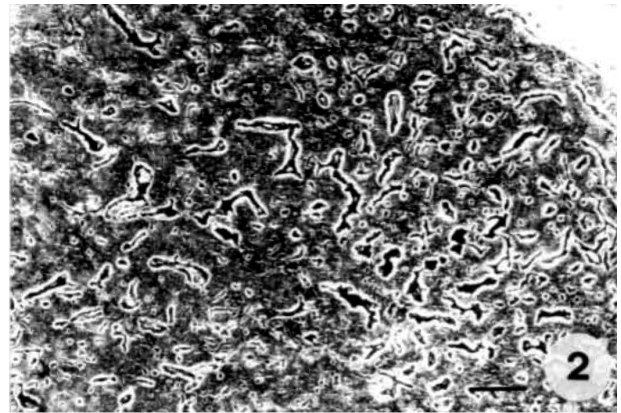
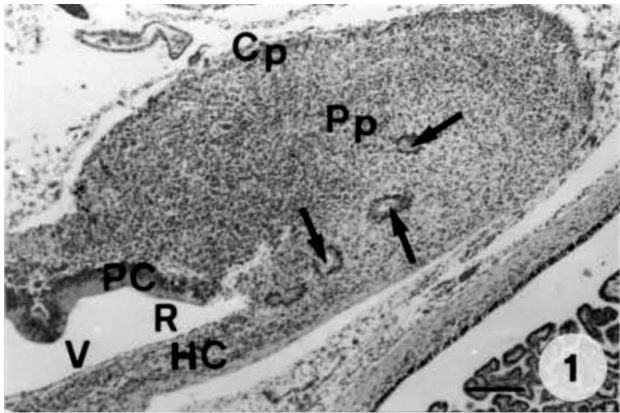
From a microscopic perspective, the developmental differentiation of the glandular rosettes is evident. At the beginning they are seen as large and irregular groupings with abundant cytoplasm, rounded and extremely numerous nuclei with heterochromatin (Fig. 10). Later, these rosettes acquire a more regular morphology predominated by the oval form (Fig. 11). These mature rosettes are characterised by having a wide central lumen, which on occasions contains small quantities of substance. The epithelium that forms these rosettes appears formed by cells with an elongated nucleus along the perpendicular axis of the cell, large, euchromatic and situated in the basal part. The cytoplasm is extensive, acidophilic and with a clear glycocalix.

Stage 2 (220 days of prenatal development to birth)

At 70 cm (220 days of gestation) we saw, in the pineal parenchyma, a marked decrease in the number of glandular structures, named rosettes.

At 240 days of gestation (80 cm C-R), macroscopically, the pineal gland loses its elongated morphology to adopt a rounded form of a larger size. Microscopically (Fig. 12) we witnessed a rounded gland that was compact and well delimited by a connective capsule. At this age, the practical disappearance of the glandular rosettes that we observed in previous groups is

Histomorphogenesis of bovine pineal gland



Histomorphogenesis of bovine pineal gland

evident (Figs. 13, 14).

The pineal parenchyma is shown to be very well developed, the presence of parenchymal cells standing out, within which the pinealoblasts of the interstitial cells are easily differentiated. This cellular mass is arranged like cellular wires in different directions, separated by a great quantity of blood vessels (Fig. 15).

The blood vessels show well formed walls (Fig. 16) where endothelial cells together with other cells with a rounded and euchromatic nucleus adjacent to the external wall of the vessel stand out. Likewise, there is a perivascular empty space that separates it from the actual glandular parenchyma.

At birth (280 days of gestation) the gland shows its characteristic rounded morphology. In the parenchyma we detected a great development of the vascular component just as we have observed in previous ages (Fig. 17). The cellular component is formed by means of a double cellular typology: pinealoblasts and interstitial cells. The pinealoblasts (Figs. 18, 19) are characterised by showing a rounded morphology with abundant vacuolar cytoplasm, oval euchromatic nuclei and a well-differentiated nucleolus. The interstitial cells, more numerous than in previous lots, (Figs. 18, 19) are characterised by having low cytoplasm, rounded and highly stained nuclei. These cells are PTAH positive. Both cellular types, present in equal quantities, form the cellular wires, mentioned in the previous lot and which are maintained separate from the capillaries by a spaced perivascular network.

Immunohistochemical observations

Glial fibrillary acidic protein (GFAP).

The immunological determination aimed at

identifying and localising the cells that are positive to the glial fibrillary acidic protein (GFAP) during pineal histomorphogenesis was carried out on all embryos of Stage 1 and 2.

In Stage 1 (160 to 200 days of gestation) at 40 cm C-R (160 days of gestation) we observed a small immunological reaction close to the habenular commissure. The immunomarked cells appeared at 50 cm C-R (180 days intrauterine life) in greater number. These cells were characterised by displaying small dense and ovoid nuclei. The immunoreaction affects the cytoplasm, its cytoplasmatic extensions being the negative nucleus of this technique (Fig. 20).

At 60 cm C-R (200 days of gestation) the immunomarked cells display a small number of cellular process, with diverse diameters and positions, longitudinally as well as transversally (Fig. 21). These said cellular processes are characterised by displaying different ramifications as they move away from the perikaryon, positioning themselves among the pinealocytes in form of a network and making a barrier limiting in its layout around the blood vessels.

In Stage 2 (220 days of gestation to birth) the immunomarked cells are arranged in a cluster form (Fig. 22). These GFAP positive cells are characterised by displaying alternately oval and elongated forms. In the same way as what took place in the previous group, these are cells that show an immunoreaction situated fundamentally in their cytoplasm and their extensions. The cytoplasmatic processes, in greater number than in the GFAP positive cells of Stage 1, displayed distinct diameters and positions (Fig. 23).

Neuropeptide Y (NPY).

We used this neuropeptide in order to show the

Fig. 1. Photomicrograph of a sagittal direction section of the embryo at 40 cm C-R, 160 days. Pineal parenchyma (Pp), capsule (Cp), habenular (HC) and posterior (PC) commissures, pineal recess (R), third ventricle (V) and glandular rosettes (arrows). H-E. Bar: 134 µm.

Fig. 2. Photomicrograph of a sagittal direction section of the embryo at 40 cm C-R, 160 days. Intense reaction of reticular fibres of the vascular structures. RG. Bar: 134 µm.

Fig. 3. Photomicrograph of a sagittal direction section of the embryo at 40 cm C-R, 160 days. Morphologically round glandular structures with a central lumen (arrows). H-E. Bar: 56 µm.

Fig. 4. Photomicrograph of a sagittal direction section of the embryo at 40 cm C-R, 160 days. Glandular parenchyma where we observed pinealoblasts (p) and interstitial cells (ci). PTAH. Bar: 46 µm.

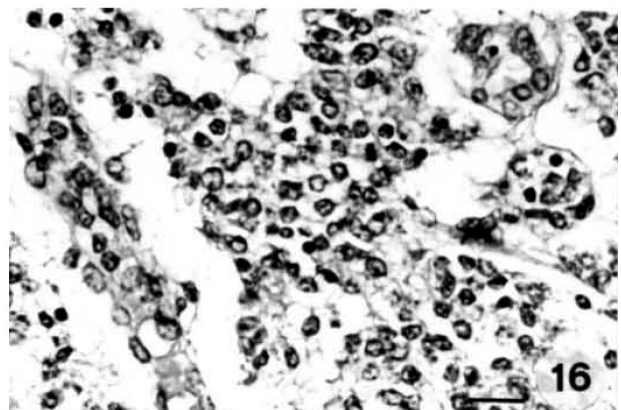
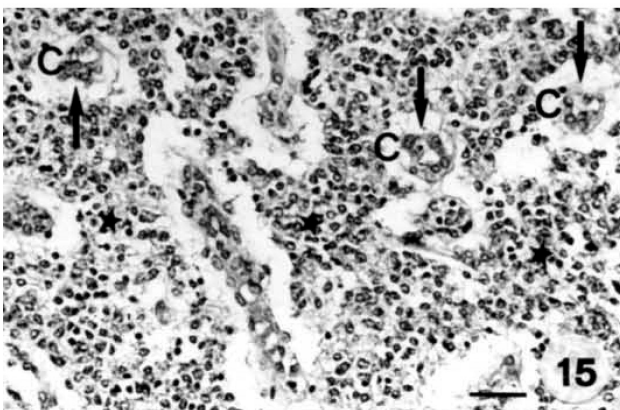
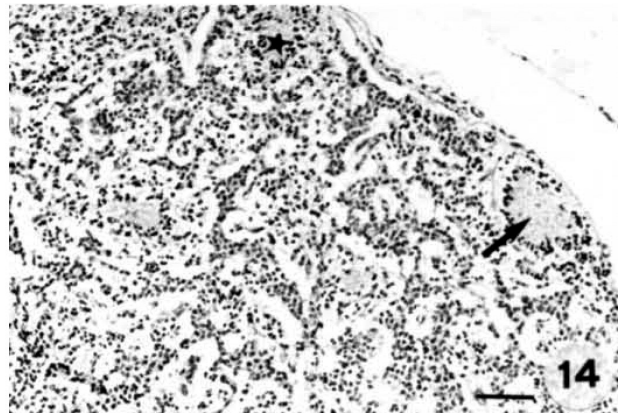
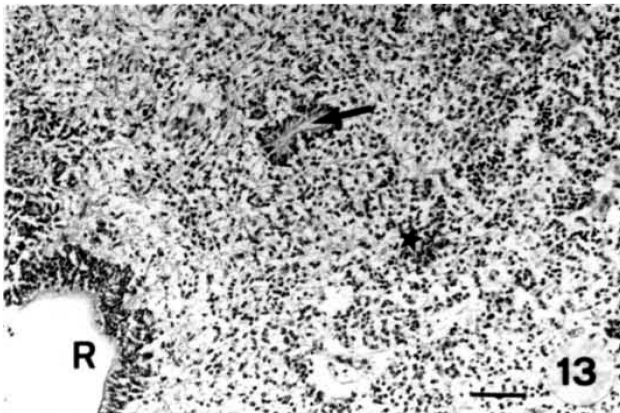
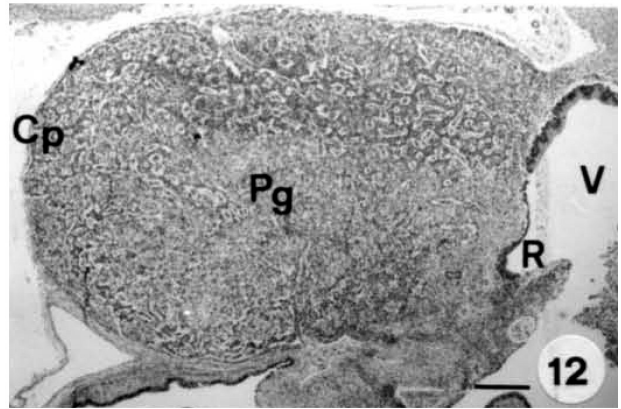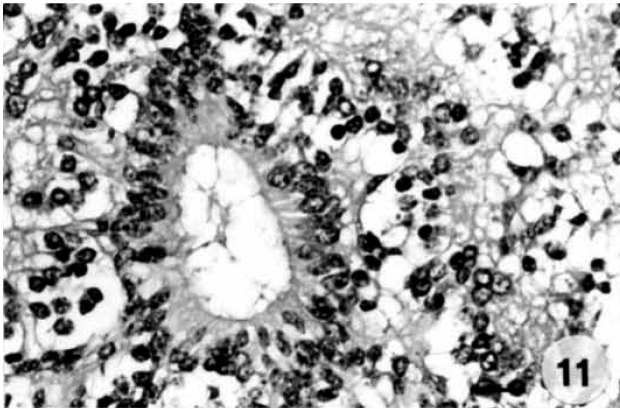
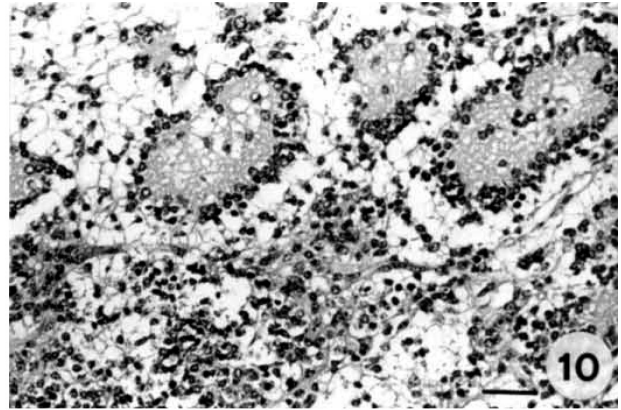
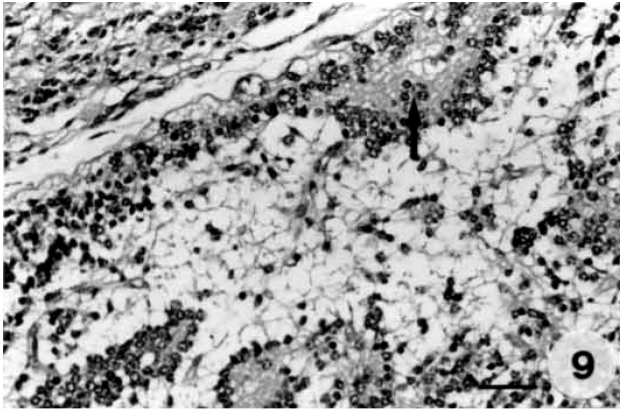
Fig. 5. Photomicrograph of a sagittal direction section of the embryo at 50 cm C-R, 180 days. Reticular fibres of the capsule (Cp), trabeculae (T) and vascular structures (arrows). RG. Bar: 56 µm.

Fig. 6. Photomicrograph of a sagittal direction section of the embryo at 50 cm C-R, 180 days. Glandular cytology: pinealoblasts (p) and interstitial cells (ci). PTAH. Bar: 46 µm.

Fig. 7. Photomicrograph of a sagittal direction section of the embryo at 60 cm C-R, 200 days. Compact pineal gland (Pg). Pineal recess (R). Large quantity of rosettes (arrows). H-E. Bar: 134 µm.

Fig. 8. Photomicrograph of a sagittal direction section of the embryo at 60 cm C-R, 200 days. Abundant presence of glandular rosettes in the glandular parenchyma (arrows). H-E. Bar: 56 µm.

Histomorphogenesis of bovine pineal gland



Histomorphogenesis of bovine pineal gland

presence of nerve fibres in both age stage. In all embryos analysed we found NPY-immunoreactive fibres. The NPY positive nerve fibres start to become clear from 160 days of gestation (40 cm C-R), progressively increasing throughout prenatal development until birth. Their distribution and localisation was similar in all embryos of the experiment.

Generally, these fibres enter the pineal gland through the pineal capsule, passing to the connective tissue of the glandular septae, occupying a perivascular localisation. NPY positive fibres could also be observed dispersed among the pinealocytes (Fig. 24).

Morphometric observations

Numerical cell density using the PTAH stain was 24 ± 2 cells/field in Stage 1 and around 32 ± 2 cells/field in Stage 2. The number of embryonic pineal gland cells expressing GFAP was greater in Stage 2 (15 ± 2) than in Stage 1 (6 ± 1).

Among all glial cells (PTAH positive cells) only a small amount express GFAP positivity. The numerical density of GFAP positive cells was lower than that of PTAH positive cells.

Discussion

Using topographical criteria as a basis, we classified the bovine pineal gland (in these stages of development) such as type A-B (intermediate-proximal); that is, elongated pineal and its length slightly more than double its greatest width. We based this classification on the anatomical considerations proposed by Vollrath (1979) for the pineal gland of domestic mammals. This classification is based on the position, form, tissue grouping and relations with neighbouring organs.

During prenatal development of the bovine pineal

gland, in the interior of the pineal parenchyma, we observed some pseudoglandular structures at 160 days of gestation. These pseudoglandular structures (called rosettes) appear well differentiated at 200 days of gestation. Our results show that these structures are found formed by morphologically similar cells to those that form the epithelium of the pineal recess. Due to this, our findings do not coincide with the studies carried out in the pineal gland of rabbit (García-Mauriño and Boya, 1992) in pointing out that these structures (called rosettes) are found made up by type II pinealocytes (interstitial cells). Neither do our findings coincide with those that describe the rosettes that appear during embryonic development of sheep (Anderson, 1965); bovine (Brack, 1962; Anderson, 1965); hamster (Clabough, 1973) and rat (Calvo and Boya, 1981) as being formed by undifferentiated cells.

On the other hand, it is worthwhile pointing out that although certain histological, immunohistochemical and physiological aspects of the pineal gland in different animals have been analysed to an extent, few studies have considered the bovine pineal gland during prenatal development (Brack, 1962; Anderson, 1965; Regodón and Roncero, 2005). Our interest in investigating the morphology of the bovine pineal gland in general and of the glandular rosettes in particular was motivated by previous publications (Greve et al., 1993; Akasaka et al., 1995; Jové et al., 1999). These authors show that the synthesis of melatonin during embryonic development of chicken is produced at day 13 of incubation. Given that the rosettes store secretion products produced by the pinealoblasts (Greve et al., 1993; Nowak et al., 1997), their appearance in the glandular tissue could be related to some secretion acts. The mechanism that regulates the synthesis of melatonin in chicken has been analysed during embryonic life (Akasaka et al., 1995) and the histochemical observations carried out support the

Fig. 9. Photomicrograph of a sagittal direction section of the embryo at 60 cm C-R, 200 days. Cellular groupings in the glandular periphery (arrow). H-E. Bar: 46 μ m.

Fig. 10. Photomicrograph of a sagittal direction section of the embryo at 60 cm C-R, 200 days. Pseudoglandular structures. H-E. Bar: 46 μ m.

Fig. 11. Photomicrograph of a sagittal direction section of the embryo at 60 cm C-R, 200 days. Morphologically oval glandular rosette with a wide central lumen. H-E. Bar: 32 μ m.

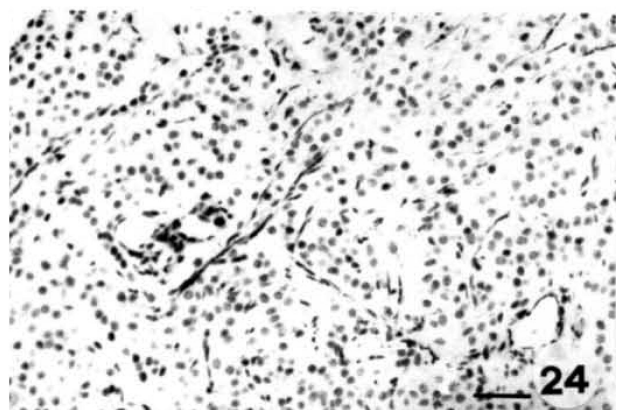
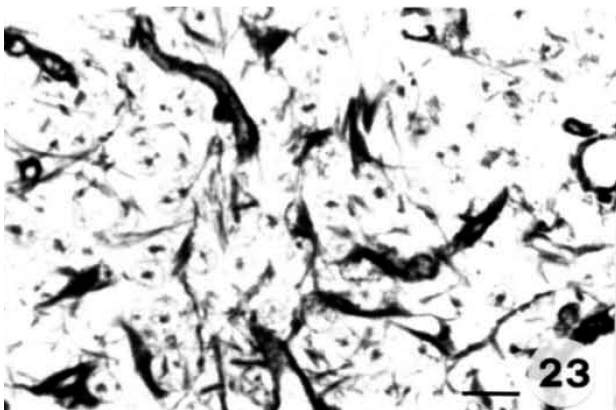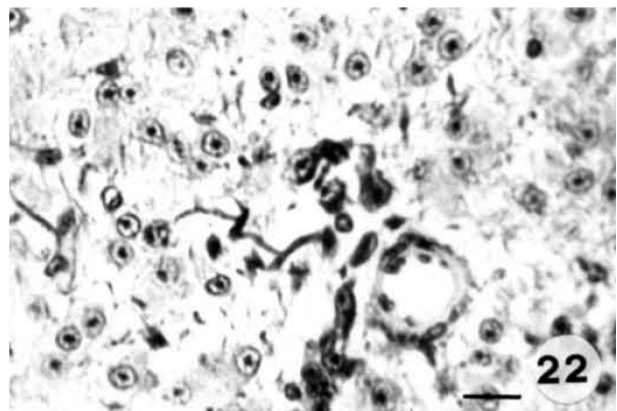
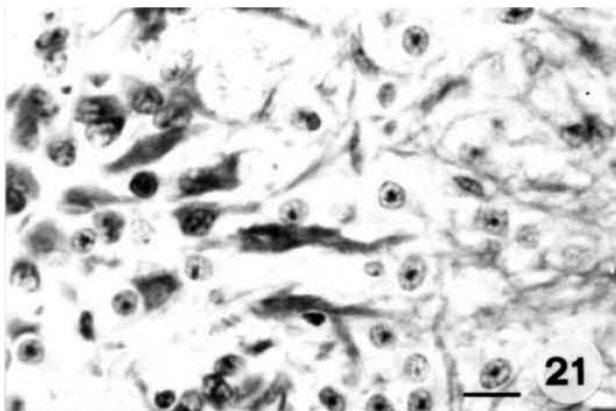
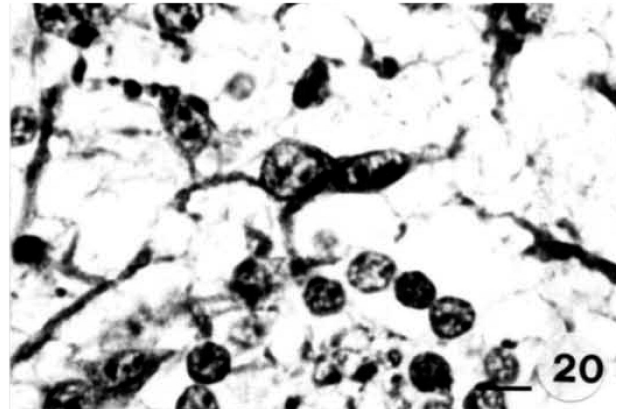
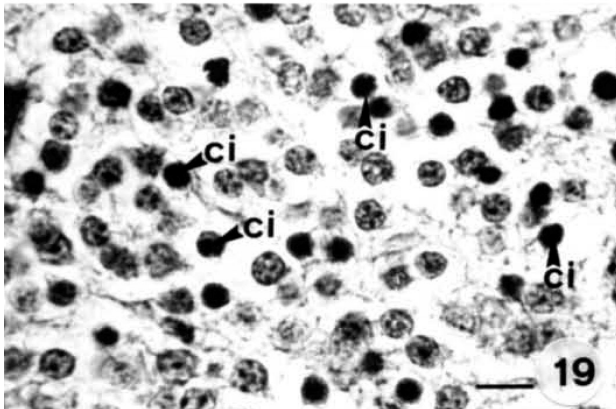
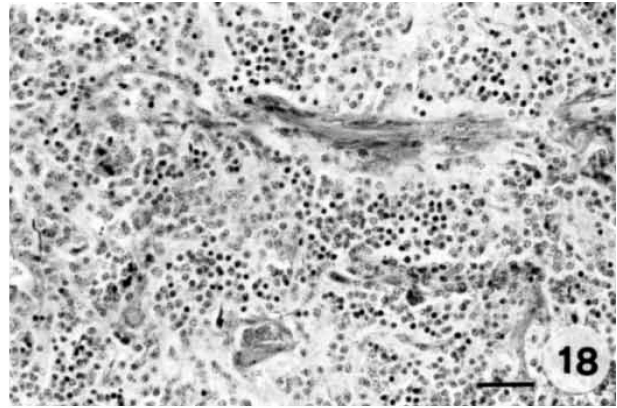
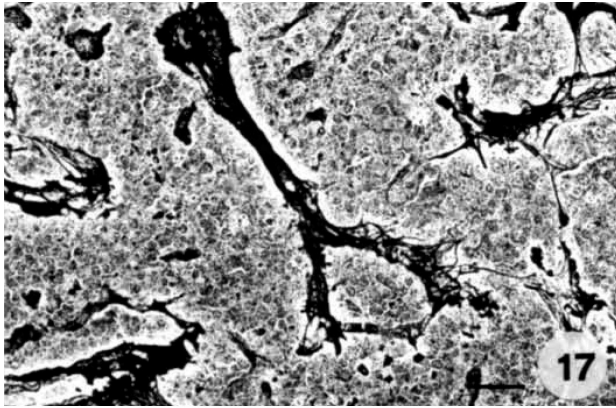
Fig. 12. Photomicrograph of a sagittal direction section of the embryo at 80 cm C-R, 240 days. Pineal gland (Pg), capsule of connective tissue (Cp), third ventricle (V) and pineal recess (R). H-E. Bar: 134 μ m.

Fig. 13. Photomicrograph of a sagittal direction section of the embryo at 80 cm C-R, 240 days. Pineal recess (R). Rosettes (arrow) and cellular groupings (asterisk). H-E. Bar: 56 μ m.

Fig. 14. Photomicrograph of a sagittal direction section of the embryo at 80 cm C-R, 240 days. Rosettes (arrow) and cellular groupings (asterisk). H-E. Bar: 56 μ m.

Fig. 15. Photomicrograph of a sagittal direction section of the embryo at 80 cm C-R, 240 days. Cellular cords (asterisks) of parenchymal and capillary cells (C) with clear perivascular space (arrow). H-E. Bar: 46 μ m.

Fig. 16. Photomicrograph of a sagittal direction section of the embryo at 80 cm C-R, 240 days. Well developed and formed blood vessels. H-E. Bar: 32 μ m.



Histomorphogenesis of bovine pineal gland

hypothesis that a greater secretory function exists between days 10 and 17 of incubation, after which point this secretory function decreases (Greve et al., 1993; Jové et al., 1999).

Our results show the existence of a considerable increase in number as well as in size of the rosettes from 180 until 200 days of intrauterine life of bovine embryos. However, from 70 cm C-R (220 days of gestation) the number of rosettes starts to considerably decrease. Due to these findings, we believe that these histological changes found at these specific ages could serve as a foundation for future immunohistochemical studies as morphological parameters associated with the functional activity carried out during embryonic development of the bovine pineal gland.

The pineal parenchyma in developing bovines is constituted by two cellular types: pinealoblasts and interstitial cells. The pinealoblasts appear in the first stages of prenatal life and continue throughout ontogenesis. The morphology and manner of distribution of these cells on the glandular surface are similar to the pattern described of other species of mammals (Ueck, 1986; Pevet, 1977; Regodón et al., 1998; Regodón and Roncero, 2005).

Many terms have been used to define the second cellular population of the pineal parenchyma in development: interstitial cells (Cozzi, 1986; Franco et al., 1997; Regodón et al., 1998); glial cells (Brack, 1962; Anderson, 1965; Calvo et al., 1988) and astrocytes (Boya and Calvo, 1993). We have chosen to call this second cellular population composed of PTAH and GFAP positive cells interstitial cells. These interstitial cells, less numerous than the pinealoblasts have similar characteristics to those described in other species of mammal: rats (Calvo and Boya, 1983; Calvo et al., 1988); carnivores (Boya et al., 1995); horses (Cozzi,

1986) and ruminants (Franco et al., 1997; Regodón et al., 1998).

With the aim of studying the knowledge and nature of the second cellular population in depth we carried out histochemical and immunological tests. The first step was to determine the presence of glial-like cells by PTAH immunostaining. The second step was thus to determine GFAP expression. The GFAP has been considered as a valid marker to determine the presence of cells of an astrocytic type with a certain degree of maturity (Franco et al., 1997; Regodón et al., 1998).

The number of PTAH positive cells increases from 160 days of gestation until birth. This increase is parallel to the increase in the numerical density of the GFAP positive cells. The comparative analysis of these two findings shows that of the total of glial cells (PTAH positive cells), only a percentage shows GFAP positivity. The fact that the number of GFAP positive cells is less than the number of PTAH positive cells leads us to believe that some glial cells (PTAH) are not GFAP positive, possibly due to the fact that they are immature astrocytes (Boya and Calvo, 1993; Franco et al., 1997; Regodón et al., 1998; Redondo et al., 2001). Our investigations suggest that during embryonic development of the bovine pineal gland a combination of cells of a glial astrocytic nature exists in different stages of maturity and which constitute the second cellular population.

With respect to the pineal stroma, it carries on progressively developing from the extensive connective walls that project from the pineal capsule. However, these connective walls never totally achieve lobular integration in the glandular parenchyma. The blood vessels accompany these connective walls and will be responsible for irrigating the pineal parenchyma. The walls appear formed by abundant reticular fibres of

Fig. 17. Photomicrograph of a sagittal direction section of the embryo to birth. High development of reticular argyrophil fibres in the adventitia of the vessels. RG. Bar: 46 µm.

Fig. 18. Photomicrograph of a sagittal direction section of the embryo to birth. Abundant presence of pinealoblasts and interstitial cells. PTAH. Bar: 46 µm.

Fig. 19. Photomicrograph of a sagittal direction section of the embryo to birth. PTAH positive interstitial cells (ci) distributed around the glandular parenchyma. PTAH. Bar: 26 µm.

Fig. 20. Photomicrograph of a sagittal direction section of the embryo at 50 cm C-R, 180 days. Somas and cellular processes positive to GFAP. EAS. Bar: 20 µm.

Fig. 21. Photomicrograph of a sagittal direction section of the embryo at 60 cm C-R, 200 days. Cellular processes of a longitudinal and transversal position. EAS. Bar: 29 µm.

Fig. 22. Photomicrograph of a sagittal direction section of the embryo at 80 cm C-R, 240 days. Perivascular arrangement of the GFAP positive cells. EAS. Bar: 29 µm.

Fig. 23. Photomicrograph of a sagittal direction section of the embryo to birth. Cytoplasmatic processes forming a network among the pinealoblasts. EAS. Bar: 20 µm.

Fig. 24. Photomicrograph of a sagittal direction section of the embryo at 80 cm C-R, 240 days. NPY-immunoreactive fibres located close to blood vessels and dispersed between pinealoblasts. EAS. Bar: 40 µm.

intense argyrophil (Calvo et al., 1990; Franco et al., 1997; Regodón et al., 1998; Regodón and Roncero, 2005) and few collagen fibres (Franco et al., 1997; Regodón et al., 1998; Regodón and Roncero, 2005). The reticulin and collagen fibres, which gradually increase until birth, are responsible for forming the intercellular and perivascular stroma. The connective tissue of the walls along with the perivascular connective tissue and the connective tissue of the adventitia of the blood vessels continue to fill the interstitial space and form, together with the reticular network that comes from the cytoplasmatic processes of the interstitial cells, the support framework of the entire glandular cytology.

From 160 days of gestation (40 cm C-R) we detected in the pineal gland some vascular structures that underwent an extensive increase in their density as prenatal development progresses. The greatest vascular differentiation was clear from the greater content of reticular argyrophil fibres (Redondo et al., 1996; Regodón et al., 1998). These are blood capillaries with extensive lumina and well-defined walls where the presence of endothelial cells stands out. These vascular structures are similar to the non-fenestrated capillaries described in carnivores (Calvo et al., 1990; Boya et al., 1995) and in sheep (Regodón et al., 1998).

In terms of glandular innervation, we have shown the presence of NPY immunoreactive nerve fibres from 160 days of gestation until birth. Previous studies show the existence of these NPY fibres in numerous species of mammals: cat (Moller et al., 1994); pig (Przybyska-Gornowicz et al., 1997); bovine (Phansuwan-Pujito et al., 1993) and in sheep (Regodón et al., 2003). Our studies show the presence of these NPY positive fibres in bovine pineal glands during prenatal development, from 160 days of gestation (40 cm C-R). At this age the NPY positive fibres are few, progressively increasing in number as development progresses. In the two age groups studied, these fibres appear localised around the blood vessels and in the interior of the pineal parenchyma among the pinealoblasts. Due to this localisation we believe that these NPY fibres could be involved in the functioning of the pinealocytes as well as in the blood vessels. In adult bovine pineal glands (Phansuwan-Pujito et al., 1993) similar results to ours were reached during prenatal development of the bovine pineal gland.

The distribution of these fibres in the pineal parenchyma was not homogeneous. In the bovine pineal gland (Phansuwan-Pujito et al., 1993) and in the sheep pineal gland (Regodón et al., 2003) a high density of NPY positive fibres in all of the glandular surface area was reported. In the cat (Moller et al., 1994) and in the pig (Przybyska-Gornowicz et al., 1997) a greater presence of NPY positive fibres in the medullar zone than in the cortical glandular zone has been described. Our results confirm the existence of NPY positive nerve fibres in all of the pineal parenchyma during prenatal development of the bovine pineal gland.

Future morphological and neuroendocrine studies

are essential in order to shed light in general on the glandular morphofunctionality and in particular on the moment that the glandular rosettes appear as well as on their possible function in the synthesis of melatonin during embryonic development of the bovine pineal gland.

Acknowledgements. We express our gratitude to Mrs. Carmen González Bravo of the Pathological Anatomy Unit at Coria Hospital, Cáceres for their excellent technical assistance.

References

- Aherne W.A. and Dunnill M.S. (1982). *Morphometry*. Arnold eds. London.
- Akasaka K., Nasut T., Katayama T. and Murakami N. (1995). Development of regulation of melatonin release in pineal cells in chick embryo. *Brain Res.* 692, 283-286.
- Anderson E. (1965). The anatomy of bovine and ovine pineals. Light and electron microscopic studies. *J. Ultrastruct. Res.* 12, 1-80.
- Boya J. and Calvo J.L. (1993). Immunohistochemical study of the pineal astrocytes in the postnatal development of the cat and dog pineal gland. *J. Pineal Res.* 15, 13-20.
- Boya J., Calvo J.L. and Rancaño D. (1995). Structure of the pineal gland in the adult cat. *J. Pineal Res.* 18, 112-118.
- Brack E. (1962). Morpho and histogenetische unteruchungen der epiphysis cerebri von rind. *Anat. Histol. Embryol.* 9, 905-924.
- Calvo J.L. and Boya J. (1981). Embryonic development of the rat pineal gland. *Anat. Rec.* 200, 491-500.
- Calvo J.L. and Boya J. (1983). Postnatal development of cell types in the rat pineal gland. *J. Anat.* 186, 185-195.
- Calvo J.L., Boya J., Borregón A. and García-Mauriño J.E. (1988). Presence of glial cells in the rat pineal gland: a light and electron microscopic immunohistochemical study. *Anat. Rec.* 220, 424-428.
- Calvo J.L., Boya J., García-Mauriño J.E. and López-Carbonell A. (1990). Prenatal development of the dog pineal gland: light microscopy. *Histol. Histopathol.* 5, 31-36.
- Clabough J.W. (1973). Cytological aspects of pineal development in rats and hamsters. *Am. J. Anat.* 137, 215-230.
- Cozzi B. (1986). Cell types in the pineal gland of the horse: an ultrastructural and immunocytochemical study. *Anat. Rec.* 216, 165-174.
- Evans H.E. and Sack W.O. (1973). Prenatal development of domestics and laboratory mammals. *Anat. Histol. Embryol.* 2, 11-45.
- Franco A., Regodón S., Masot A.J. and Redondo E. (1997). A combined immuno-histochemical and electron microscopic study of the second cell type in the developing sheep pineal gland. *J. Pineal Res.* 22, 130-136.
- García-Mauriño J.E. and Boya J. (1992). Postnatal maturation of the parenchymal cell types in the rabbit pineal gland. *Histol. Histopathol.* 7, 75-81.
- Gázquez A. (1987). *La necropsia en los mamíferos domésticos*. Ed. Interamericana. Mc Graw-Hill. Madrid.
- Greve P., Bernard M., Voisin P., Cogne M., Collin J.P. and Guerlotte J. (1993). Cellular localization of hydroindole-O-methyl transferase mRNA in the chicken pineal gland. *Neuroreport* 4, 803-806.
- Jové M., Cobos P., Torrente M., Gilabert R. and Piera V. (1999). Embryonic development of pineal gland vesicles: a morphological

Histomorphogenesis of bovine pineal gland

- and morphometrical study in chick embryos. *Eur. J. Morphol.* 37, 29-35.
- Lerner A.B., Case J.D., Takahashi Y., Lee T.H. and Mori W. (1958). Isolation of melatonin, the pineal gland factor lightens melanocytes. *J. Am. Chem. Soc.* 80, 2587.
- Moller M., Phansuwan-Pujito P., Pramulkijja S., Kotchabhakdi N. and Govitrapong P. (1994). Innervation of the cat pineal gland by neuropeptide Y immunoreactive nerve fibers: an experimental immunohistochemical study. *Cell Tissue Res.* 276, 545-550.
- Nowak J.Z., Zawilska J.B., Woldantambor A., Sek B., Voisin P., Lintunen M. and Panula P. (1997). Histamine in the chick pineal gland: Origin, metabolism and effects on the pineal function. *J. Pineal Res.* 22, 26-32.
- Pevet P. (1977). On the presence of different populations of pinealocytes in the mammalian pineal gland. *J. Neural Transm.* 40, 289-304.
- Phansuwan-Pujito P., Pramulkijja S., Govitrapong P. and Moller M. (1993). An immunohistochemical study of neuropeptide Y in the bovine pineal gland. *J. Pineal Res.* 15, 53-58.
- Przybyska-Gornowicz B., Lewczuk B. and Moller M. (1997). Demonstration of nerve fibers containing the C-terminal flanking peptide of neuropeptide Y (CPON) in the pig pineal gland (*Sus domesticus*): an immunohistochemical study by light and electron microscopy. *Anat. Rec.* 248, 576-582.
- Redondo E., Franco A. and Regodón S. (1996). Prenatal development of the sheep pineal gland: An ultrastructural study. *J. Pineal Res.* 21, 140-148.
- Redondo E., Franco A., Masot A.J. and Regodón S. (2001). Ultrastructural and immunohistochemical characterization of interstitial cells in pre- and postnatal developing sheep pineal gland. *Eur. J. Histochem.* 45, 249-258.
- Regodón S., Franco A., Masot A.J. and Redondo E. (1998). Structure of the ovine pineal gland during prenatal development. *J. Pineal Res.* 25, 229-239.
- Regodón S., Franco A., Regodón M^a.T., Masot A.J. and Redondo E. (2003). An immunohistochemical study of vasoactive intestinal peptide and neuropeptide Y in the sheep pineal gland during prenatal development. *Rev. Méd. Vét.* 154, 205-210.
- Regodón S. and Roncero V. (2005). Embryonic development of the bovine pineal gland (*Bos taurus*) during prenatal life (30 to 135 days of gestation). *Histol. Histopathol.* 20, 1093-1103
- Reiter R.J. (1991). Pineal gland. Interface between the photoperiod environment and the endocrine system. *TEM* 2, 13-29.
- Vollrath L. (1979). Comparative morphology of the vertebrate pineal complex. *Prog. Brain Res.* 9, 317-336.
- Ueck M. (1986). The morphogenesis of the mammalian pineal organ. In: The pineal gland during development from fetus to adult. Grupta D. and Reiter R.J. (eds). London pp. 43-55.

Accepted April 7 2006