

Male reproductive system in Senegalese sole *Solea senegalensis* (Kaup): Anatomy, histology and histochemistry

Á. García-López, G. Martínez-Rodríguez and C. Sarasquete

Institute of Marine Sciences of Andalucía (CSIC), Puerto Real, Cádiz, Spain

Summary. Despite the fact that the Senegalese sole *Solea senegalensis* is a target species for the aquaculture industry in Spain and Portugal, very little is known about its gametogenesis and especially about testicular development. Therefore, the male reproductive system in adult *S. senegalensis* was described using a histological and histochemical approach. Mean gonadosomatic index was very low ($0.094 \pm 0.004\%$) and suffered slight changes throughout the experimental period. In transverse sections, the testis presents a reniform structure with two main regions, a cortical one with seminiferous lobules where germ cells proliferate in spermatocysts (germ/Sertoli cells units), and a medullar one with spermatic ducts that collect and store the produced sperm. The germinal compartment is organized into branching lobules of the unrestricted spermatogonial type, although the majority of type A spermatogonia are located at the distal part of the lobules. Spermatogenesis seems to be semi-cystic, since spermatids are released into the lobule lumen, where they are transformed into spermatozoa. Proteins in general, especially those rich in arginine, and carboxylated mucosubstances/glycoproteins increased from spermatogonia to spermatozoa. 3β -Hydroxysteroid dehydrogenase enzymatic activity was exclusively observed in Leydig cells. The present study provides the first precise description of male reproductive apparatus in *S. senegalensis*.

Key words: Teleost, *Solea senegalensis*, Testis, spermatogenesis, Semi-cystic

Introduction

In Spain and Portugal, the Senegalese sole *Solea senegalensis* (Kaup) is a target species for marine fish aquaculture diversification, because it is well adapted to

warm climates and it has been traditionally raised in extensive earthen ponds (Drake et al., 1984; Dinis, 1992). Its good market price and the recent solving of numerous zootechnical problems in its culture are renewing the interest in its commercial farming. Although its reproduction in captivity has been the focus of research since the early 80's (Rodríguez, 1984; Dinis, 1992), there are numerous unanswered questions about the factors controlling the reproductive process. Current production (approximately 57.6 Tm in Spain during 2004; JACUMAR, 2005) is exclusively based on natural spawning during spring and/or autumn of captive wild broodstocks (Anguis and Cañavate, 2005). However, breeders often fail to spawn or spawning is erratic producing a small quantity of eggs, sometimes unfertilized or of poor quality (unpublished data).

Very few light and electron microscopy studies have been published on *S. senegalensis* reproductive system. Its ovarian cycle in the Gulf of Cadiz has been characterized histologically and histochemically by Rodríguez (1984) and Gutiérrez et al. (1985). Arellano (1999) described the histology, histochemistry and ultrastructure of their major organs and tissues, but little attention was focused on male reproductive apparatus. Finally, Medina et al. (2000) studied the spermatozoon ultrastructure.

The testis of teleost fish is usually a whitish organ that comprises two lobes separated by a septum or independent by themselves. Within the testis, there are two compartments: the germinal and the interstitial one, being separated from each other by a basement membrane (Lo Nostro et al., 2003). In the germinal compartment, Sertoli cells envelop with their cytoplasmic extensions a clone of germ cells all at the same stage of development, forming the spermatocyst (Pudney, 1995). Depending on the spermatogenetic events that occur within them, Mattei et al. (1993) distinguished two types of spermatogenesis in teleosts: cystic and semi-cystic. In the cystic type, spermatogenesis is completed within spermatocysts that break down at the end of spermiogenesis releasing spermatozoa into the lobules or tubules lumen. In the

semi-cystic type, the cysts open at a certain moment before the end of spermatogenesis which is then completed in the lobule lumen. Structurally, vertebrate testis can be classified according to the morphology of the germinal compartment and the distribution of germ cells within it (Weltzien et al., 2002). In lower teleosts, the germinal compartment is organized into anastomosing tubules, while those in higher teleosts are organized into branching lobules (Grier, 1993). Both types of testis can be further divided into an unrestricted spermatogonial testis-type, where spermatogonia can be found all along the tubules or lobules, and a restricted spermatogonial testis-type, where spermatogonia are restricted to the distal part of them (Selman and Wallace, 1986; Grier, 1993; Weltzien et al., 2004). The germinal compartment is surrounded and structurally supported by the interstitial compartment, constituted by connective tissue where myoid cells, fibroblasts, collagen fibres, blood vessels and Leydig cells can be found.

During spermatogenesis, male germ cells pass through three major phases (Schulz and Miura, 2002; Weltzien et al., 2004): mitotic proliferation (spermatogonial stem cells to differentiated spermatogonia), meiosis (spermatocytes to spermatids) and spermiogenesis (spermatids to spermatozoa).

The aim of this study was to describe the anatomy, histology, histochemistry and histoenzymatic properties of the male reproductive system of *S. senegalensis* during its annual cycle in captivity, in order to provide useful information on the biological aspects of reproduction for this species.

Materials and methods

Fish and rearing conditions

Senegalese sole adults (hatched in captivity during 1999) were held at PROMAN S.L. aquaculture station (Carchuna, Granada, Spain) under natural photoperiod in a circular pond (8 m diameter, 2.5 m water depth). Number of males/females was approximately 1.5 throughout all the experimental period. The pond was supplied with running sea water (5-8 renewals/day) from a submarine emissary located at 150 meters from the coast and at 5 meters depth. Water temperature fluctuated according to season between 14 and 24°C. Salinity ranged between 36 and 38 and pH between 7.7 and 8.1. The pond was partially covered with a black mesh in order to reduce light incidence. The fish were fed to satiation 5 days per week on a commercially available dry diet specific for breeders (Trow España, Spain) at a daily ration of 0.1-0.4 % of body mass.

Sampling

From November 2003 to July 2004, 4-6 males were sacrificed monthly by an anaesthetic overdose (2-phenoxiethanol, 600 ppm; Panreac, Spain). A total of 35 males (average total mass: 1212±35 g) were sampled

and investigated. For each fish, the total body mass (M_B ; precision: 1 g) was measured. The testis was excised and weighted (M_T) to nearest 0.01 g, and transverse fragments from the central part of both lobes (in this zone the whole cross section of the gonad can be observed) were taken for analysis.

Histology and histochemistry

For morphological examination, fragments of testicular tissue were fixed in 4% phosphate buffered (0.1 M, pH 7.2) formalin for 48-96 hours at room temperature. After rinsing in running tap water (16 hours) and dehydration in ascending concentrations of ethanol, samples were infiltrated and embedded in Leica Historesin (2-hydroxi-ethyl-metacrylate; Reichert-Jung, Germany). Sections were cut at 3 µm on a Supercut 2065 microtome (Reichert-Jung, Germany) and stained with Harris' Haematoxylin and Eosin (H-E). Histological and histochemical sections were examined and photographed on a Leitz Diaplan light microscope. Cell nuclei were measured microscopically.

For histochemical evaluation of carbohydrates and proteins, fragments of testicular tissue (fixed, rinsed and dehydrated as above) were cleared in xylene, infiltrated and embedded in paraffin. Sections were cut at 6 µm on a Leica RM 2025 microtome (Leica Instruments, Germany). Specific reactions for carbohydrates were: diastase-PAS (glycogen), PAS (neutral mucosubstances/glycoproteins), alcian blue pH 2.5 (carboxylated mucosubstances) and alcian blue pH 1 and 0.5 (sulphated mucosubstances) and their respective controls. Histochemical reactions for proteins and aminoacids were: bromophenol blue (proteins in general), ninhydrin-Schiff (lysine), thioglicolate-potassium ferricyanide Fe (III) (cystine), NQS (arginine), Millon's reaction (tyrosine), ferric ferricyanide Fe (III) (cysteine) and p-dimethylaminobenzaldehyde (tryptophan) and their respective controls. For lipid and enzymatic activity detection, testicular tissue was directly embedded and frozen in Tissue-Tek® and stored at -20°C. Samples were cut at 9-10 µm on a Leica CM 1510 cryostat (Leica Instruments, Germany) at -20°C. Lipid detection reactions were: Sudan black B (general lipids) and aqueous Nile blue (neutral and acidic lipids). The method of 3β-hydroxysteroid dehydrogenase (3β-HSD) enzymatic activity was performed for the detection of steroid-producing cells using epiandrosterone (5α-androstan-3β-ol-17-one) as substrate. References for the histochemical methods are quoted in Martoja and Martoja-Pierson (1970), Pearse (1985), Bancroft and Stevens (1990), and Lo Nostro et al. (2004).

Calculations and statistics

The gonadosomatic index (I_G) was calculated as: I_G (%) = $100 M_T M_B^{-1}$. Data, expressed as mean±standard error of mean (S.E.M.), were analysed for statistical

Male reproductive system in sole

differences by one-way ANOVA followed by Fisher's multiple range test with a significance level (p) of 0.05. When necessary, data were log-transformed in order to comply with normality and homogeneity of variance, which were tested by Kolmogorov-Smirnov's and Bartlett's methods, respectively.

Results

Anatomy of male reproductive system

The testis of *S. senegalensis* is a bilobulated, whitish and asymmetric organ that is attached in the visceral cavity by mesenteric tissue (Fig. 1). Testicular lobes could be named depending on their position in relation to the side in which eyes are located. Thus, the lobe from the ocular side is significantly larger (mass: 0.670 ± 0.047 g; $p < 0.01$), flat-shaped, and located over the anterior region of the central skeletal portion. The lobe located near the blind side is smaller (mass: 0.470 ± 0.031 g; $p < 0.01$), conic-shaped, and situated in a ventral position from the beginning of the central skeletal portion, with a certain angle in relation to the other lobe (Fig. 1).

The deferent duct emerges in ventral position from the ocular side lobe, and from the caudal region in the blind side lobe. Both ducts fuse in the anterior limit of the central skeletal portion constituting the spermatic duct that goes along this limit in ventro-cephalic sense. The spermatic duct opens through the urogenital pore, which is located in the ocular side (dorsal surface) very close to the pelvic fins (Fig. 1).

The mean I_G was 0.094 ± 0.004 %, ranging between 0.045 and 0.149%. Throughout the sampling period (data not shown), I_G was lower (0.067 ± 0.006 %; $p < 0.01$) in November and July (beginning and end of the spermatogenetic development) and higher (0.099 ± 0.005 %; $p < 0.01$) during the rest of the months.

Structural organization of the testis

In transverse sections, the testis of *S. senegalensis* is reniform (Fig. 2), with two main regions: the cortical and medullar one. In the cortical region, the tunica albuginea, a thin connective capsule that covers all the organ, can be observed, as well as the seminiferous lobules, the main location of spermatocysts, formed by germ cells associated with somatic Sertoli cells. In the medullar region, developing spermatocysts are scarce or inexistent and it is possible to find the efferent duct system that collects and stores the spermatozoa (SPZ). Central efferent ducts leave the testicular lobe and open into the main deferent duct, that canalises the sperm outwards.

Both seminiferous lobules and ducts are surrounded and structurally supported by the testicular interstitial tissue (or stroma), based on branches of connective tissue that run from the tunica albuginea into the cortex and medulla. Within the interstitial tissue, myoid cells, collagen fibres, Leydig cells, amyelinic nerves, melanomacrophage centres (MMC's), and capillaries can be observed.

The seminiferous lobules radiate from the medullar

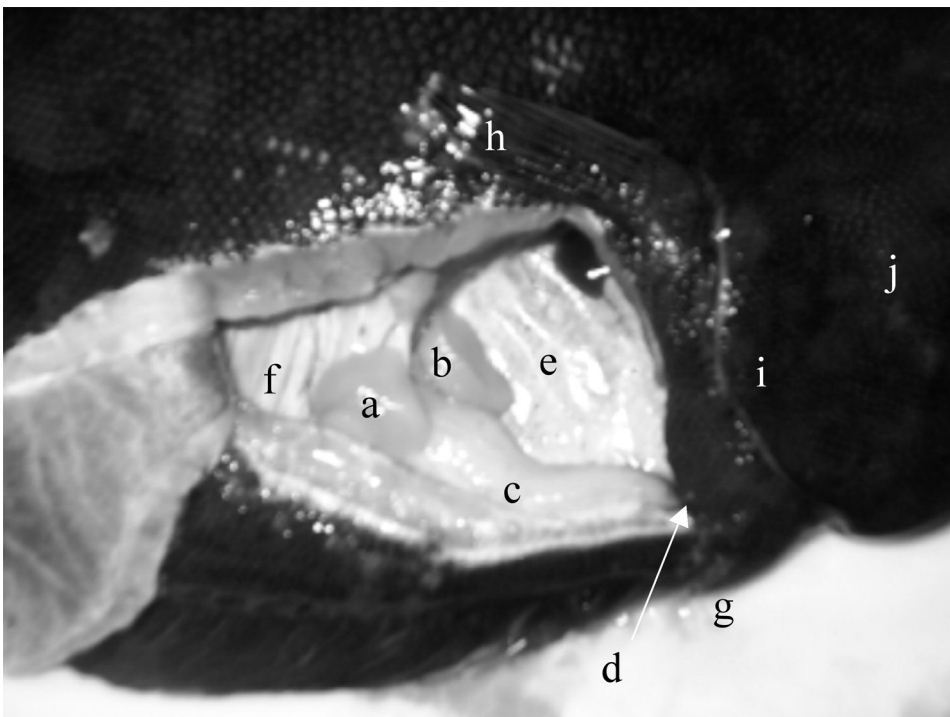


Fig. 1. Anatomy of male reproductive system in *S. senegalensis*. Specimen of 1.27 kg and 45.5 cm. a, ocular side testicular lobe; b, blind side testicular lobe; c, spermatic duct; d, urogenital pore; e, visceral cavity; f, central skeletal portion; g, pelvic fins; h, pectoral fin from the ocular side; i, operculum; j, head.

efferent ducts (without crossing each other) terminating blindly beneath the tunica albuginea at the cortex (Fig. 2B). The germinal compartment, composed of germ and Sertoli cells, is separated from the interstitial tissue by a basement membrane. Extensions of Sertoli cells envelop germ cells forming spermatocysts. In *S. senegalensis* testis, Sertoli cells only enclose spermatogonia (SPG)

and spermatocytes (SPC), because at a certain time during the end of meiosis, spermatocysts open and spermatids (SPD) are released into the seminiferous lobule lumen, where they are transformed into SPZ (Fig. 3). The spermatocysts (containing SPG or SPC) are distributed all along the lobules. However, the majority of them containing type A SPG (SPG-A) are found at the

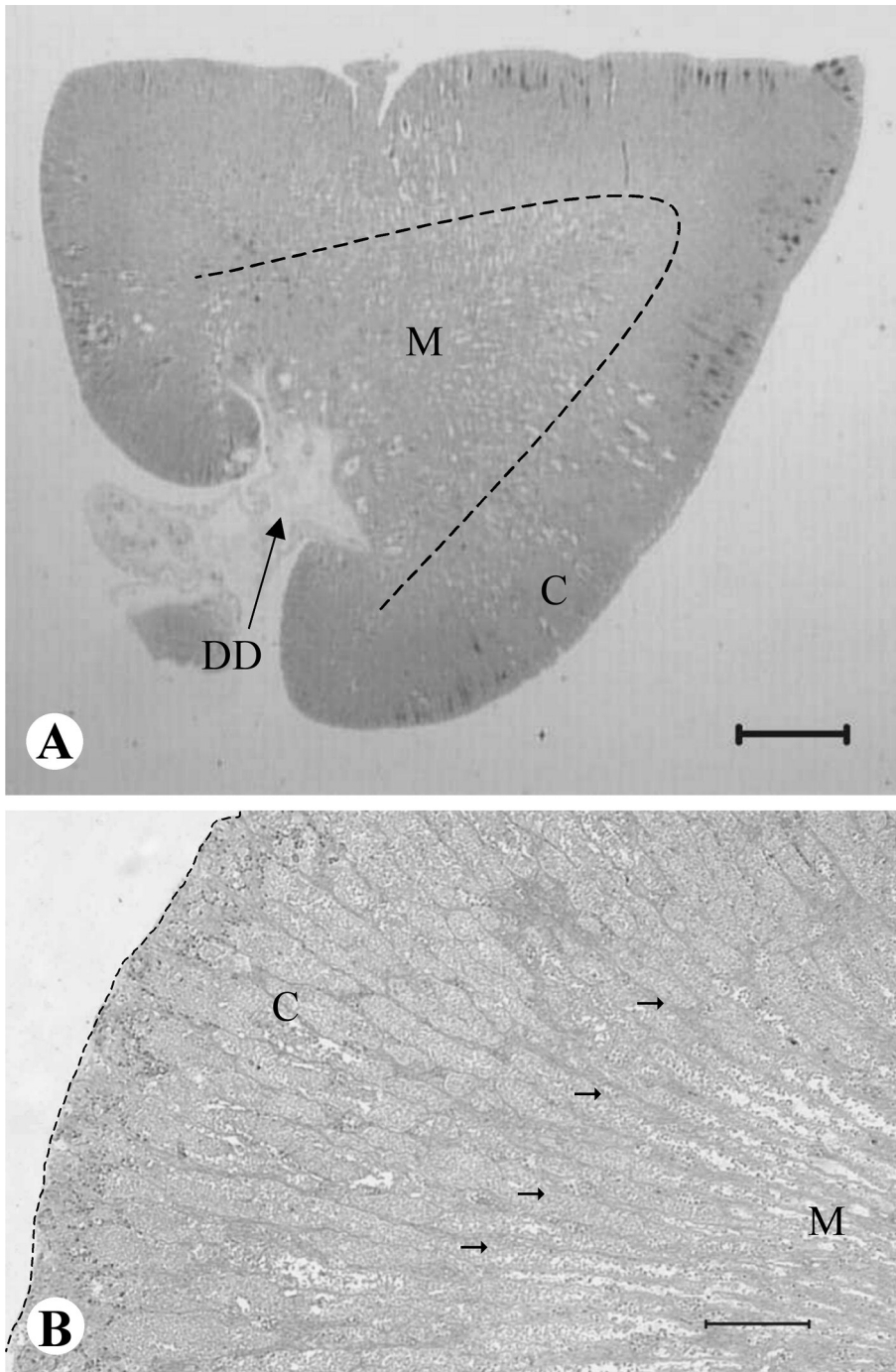


Fig. 2. Photomicrographs of cross-section of *S. senegalensis* testis. **A**, it is possible to distinguish two main regions: cortex (in the periphery of the organ; C) and medulla (internal or central region; M). **B**, shows the radial disposition of seminiferous lobules (arrows) from the central medulla (M) to the tunica albuginea (broken line) at the cortex (C). DD, deferent duct. Histoiresin; H-E. Scale bars: 1 mm (A), 200 μ m (B).

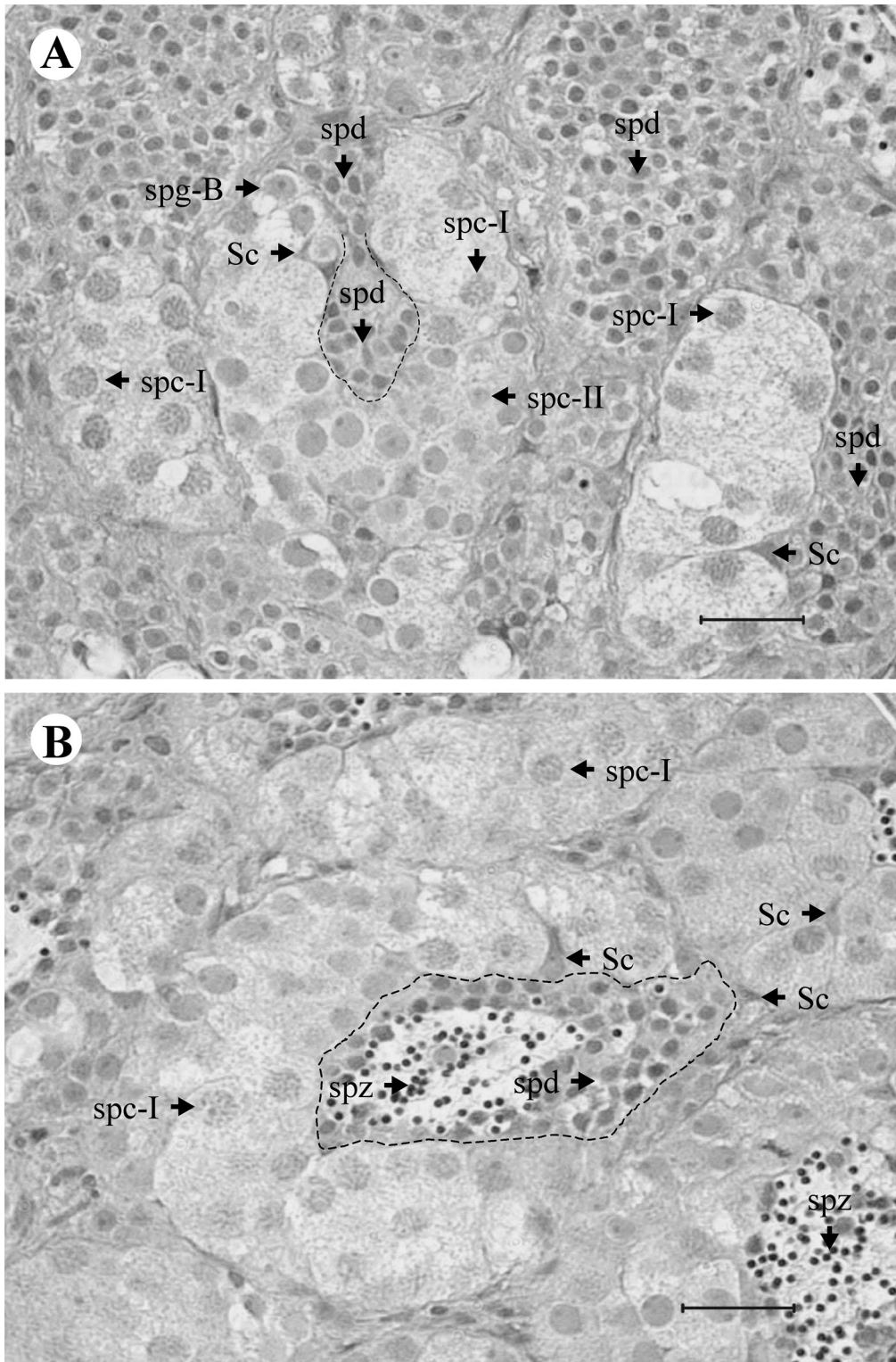


Fig. 3. Photomicrographs of cross-section of *S. senegalensis* seminiferous lobule. **A**, spermatids (spd) are released into the lumen of the lobule (broken line) after the opening of a spermatocyst. **B**, spermatids (spd) transform into spermatozoa (spz) in the lumen of the seminiferous lobule (broken line). spg-B, type B spermatogonia; spc-I, primary spermatocytes; spc-II, secondary spermatocytes; Sc, Sertoli cells. Histoiresin, H-E. Scale bars: 20 μ m.

distal part of the lobules.

Cellular components of the interstitial compartment

Myoid cells are elongated and thin, presenting a fusiform and slightly basophilic nucleus and an acidophilic cytoplasm (Fig. 4A). They are distributed bordering the seminiferous lobules and spermatic ducts, and are randomly surrounded by collagen fibres (Fig. 4A), which are very abundant in the interstitial tissue.

Leydig cells (Fig. 4B) are round shaped, have a spherical and basophilic nucleus (diameter: $3.18 \pm 0.14 \mu\text{m}$; $n=8$) with one or several nucleoli, and a clear cytoplasm in which a fine acidophilic dotted pattern can be seen. Leydig cells are mainly located near blood capillaries in small groups.

In the interstitial tissue of the medulla it is possible to distinguish some PAS-positive structures called MMC's (Fig. 4C). These groups of cells are yellowish to brown coloured (unstained sections) and commonly of nodular shape.

Testicular tissue is respectively irrigated and innervated by numerous capillaries and amyelinic nerves situated within the interstitial tissue (Fig. 4B).

Germ and associated cells: the germinal compartment

The Sertoli cells (Figs. 3, 5) have a triangular and slightly basophilic nucleus with one nucleolus and are usually in contact with the basement membrane that separates germinal and interstitial compartments. Their clear cytoplasm is difficult to distinguish because it does not stain differentially, and its expansions surround the developing germ cells (SPG or SPC).

SPG-A (Fig. 5) are large and oval-shaped cells. Their spherical nucleus, $8.44 \pm 0.48 \mu\text{m}$ in diameter ($n=8$), is slightly basophilic and has a single, prominent and strongly basophilic centrally located nucleolus. The nucleus occupies the vast majority of the cytoplasm and is located in a central or slightly eccentric position. SPG-A are found individually surrounded by Sertoli cell processes.

Type B SPG (SPG-B), resulting from successive mitoses of SPG-A, are found in small groups enclosed by Sertoli cells (Figs. 3A, 5). SPG-B have a similar aspect to SPG-A, though with a smaller size. Their nuclei (diameter: $5.86 \pm 0.21 \mu\text{m}$; $n=7$) have several nucleoli, are located in a central position and are slightly more basophilic than the nuclei of SPG-A, due to increasing chromatin condensation. After a differentiation process, SPG-B transform into primary SPC (SPC-I) which enter in meiosis.

SPC-I (Fig. 3) are similar to SPG-B in shape and size (nuclear diameter: $5.65 \pm 0.11 \mu\text{m}$; $n=26$), being also within spermatocysts. Their cytoplasm is clear and cellular limits are hard to distinguish. At the beginning of the first meiotic division prophase, the nucleus has an irregular or granular texture, due to the distribution of the genetic material. After this division, a new germ cell,

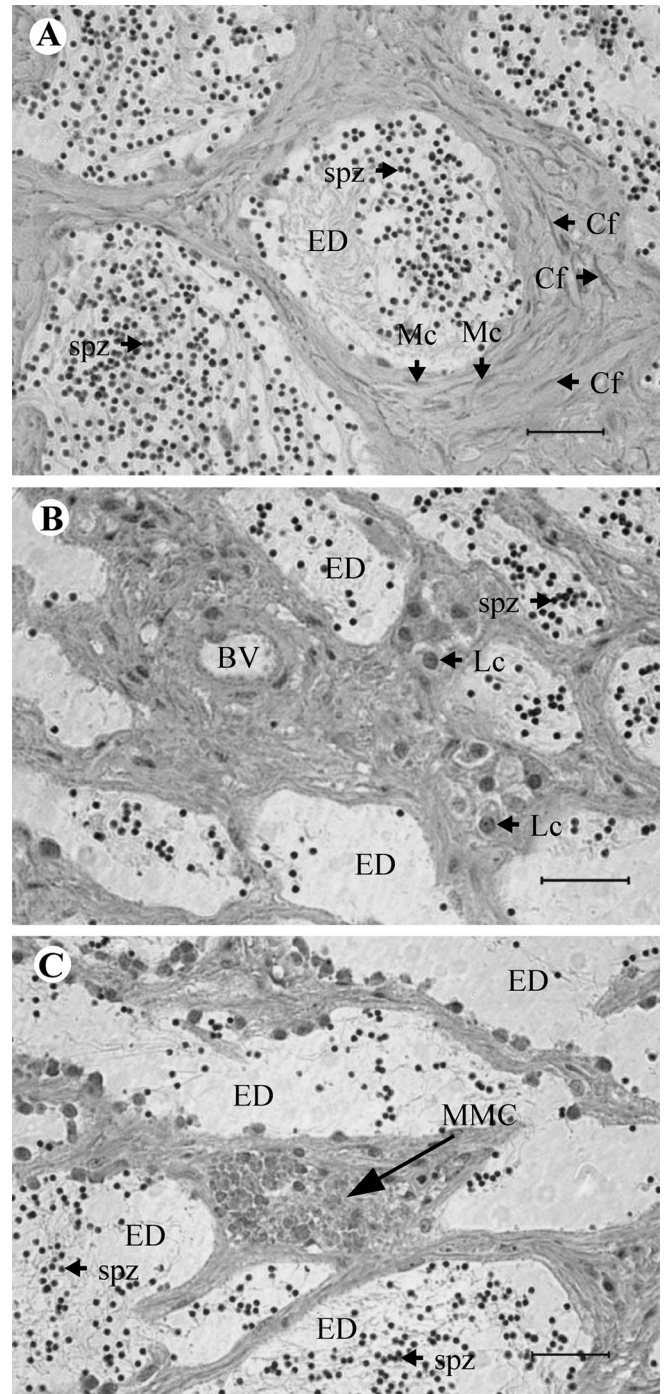


Fig. 4. Photomicrographs of *S. senegalensis* testis showing the cellular components of the interstitial compartment. Some spermatozoa (spz) are found in the lumen of the efferent ducts (ED). **A**, shows some myoid cells (Mc) and collagen fibres (Cf) bordering the efferent ducts (ED). **B**, shows two groups of Leydig cells (Lc) located near a blood vessel (BV). **C**, shows a melano-macrophage centre (MMC). Histoiresin, H-E. Scale bars: 20 μm .

Male reproductive system in sole

the secondary SPC (SPC-II), is formed.

SPC-II (Fig. 3A) are smaller in size compared to SPC-I. They possess a spherical nucleus, $3.46 \pm 0.09 \mu\text{m}$ in diameter ($n=19$), with condensed and basophilic chromatin. SPC-II are rarely observed throughout the testis since they enter rapidly in the second meiotic division forming haploid and genetically unique SPD.

SPD are released into the lobule lumen and differentiate into SPZ in this space (Figs. 3, 5). SPD are round-shaped with a scarce cytoplasm and possess a highly basophilic nucleus (diameter: $2.31 \pm 0.05 \mu\text{m}$; $n=40$). SPD are the most abundant germ cell type in the testicular tissue of *S. senegalensis*. SPD undergo a size reduction and shape remodelling giving rise to SPZ.

The highly specialized SPZ can be morphologically distinguished under the light microscope into head and tail (Figs. 3B, 4, 5). Their small and rounded head, $1.04 \pm 0.04 \text{ mm}$ in diameter ($n=13$), is strongly basophilic, while the tail, formed by one large flagellum, is acidophilic.

Histochemical characterisation of testicular tissue

Proteins in general, and especially those rich in basic aminoacids like arginine, increased as spermatogenesis proceeded (Fig. 6A). SPG were moderately rich in lysine and tyrosine, while in the rest of the germ cells the quantity of these aminoacids was low. Proteins rich in tryptophan, cysteine and cystine had a low presence in

all germ cell types. Leydig and Sertoli cells were moderately rich in proteins.

In general, carbohydrate quantity was low in all germ cells types and in Sertoli cells, except carboxylated mucosubstances /glycoproteins, which were abundant in SPZ and moderately abundant in Sertoli cells. Leydig cells were moderately stained with diastase-PAS reaction indicating the presence of glycogen.

Testicular tissue was unstained with Sudan black B and aqueous Nile blue, indicating the absence of lipids.

3 β -HSD activity was exclusively observed within the cytoplasm of Leydig cells from the interstitial tissue (Fig. 6B). Germ and Sertoli cells were not reactive.

Discussion

The shape and size of the testis of *S. senegalensis* are quite different to those of many Perciformes and Pleuronectiformes that have been studied. Concerning shape, *S. senegalensis* presents round testis, while the testis of the vast majority of teleosts (like English sole *Parophrys vetulus* (Girard) [Sol et al., 1998] and Atlantic halibut *Hippoglossus hippoglossus* (L.) [Weltzien et al., 2002]) usually have an elongated conformation. The testis morphology of *S. solea* (Baynes et al., 1994; Bromley, 2003) is similar to that of *S. senegalensis*, so it could be characteristic of this genus. Testis size and I_G in *S. senegalensis* were very reduced throughout all the spermatogenetic development ($I_G <$

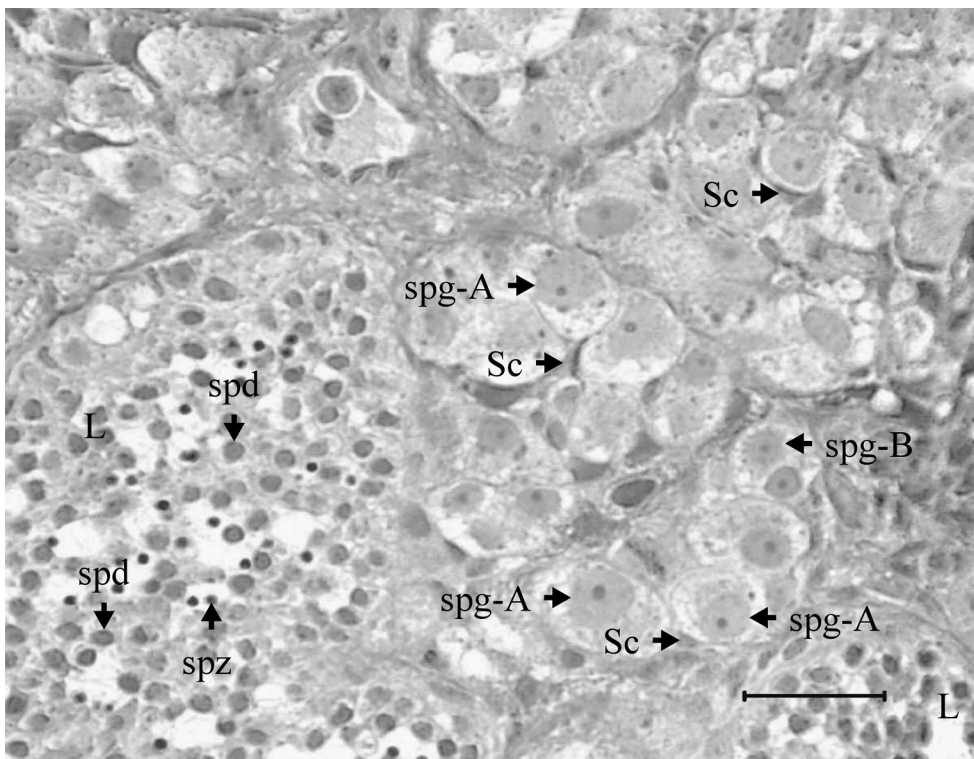


Fig. 5. Photomicrograph of cross-section of *S. senegalensis* testis, showing type A (spg-A) and B (spg-B) spermatogonia enclosed by Sertoli cells (Sc). Some spermatids (spd) and spermatozoa (spz) are occupying the lumen of the lobules (L). Histoiresin, H-E. Scale bar: 20 μm .

0.15%). This feature, also observed in *S. solea* (Baynes et al., 1994; Bromley, 2003), is rare in other teleosts that have been studied, where I_G changes significantly during spermatogenesis. Thus, I_G in *H. hippoglossus* (Weltzien et al., 2002) increased from approximately 0.1% at the beginning of testicular development to 3% at final maturation. Barr (1963) found a higher I_G in plaice *Pleuronectes platessa* (L.) at maturation (5.5%). In these

species, testis accumulates a great quantity of sperm during maturation, a feature that was not observed either in *S. solea* (Baynes et al., 1994; Bromley, 2003) or in *S. senegalensis* (unpublished data), in which testis stores only a few tens of microlitres of sperm.

The localization of genital pores in both sexes (dorsal surface in males and ventral surface in females) clearly matches the believed spawning behaviour in this

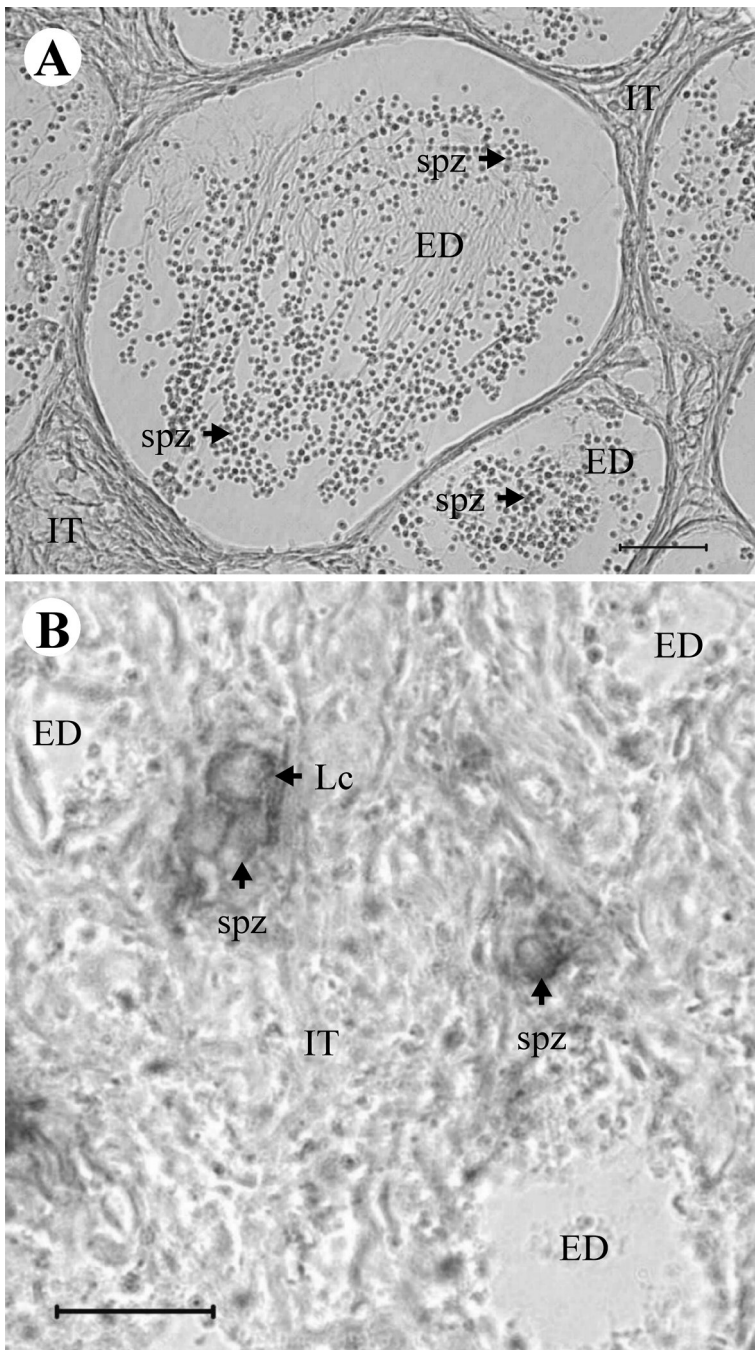


Fig. 6. Photomicrographs of cross-section of *S. senegalensis* testis showing some histochemical reactions. **A**, displays the proteins rich in arginine in spermatozoa (spz) and in the interstitial tissue (IT). Paraffin, NQS method. **B**, shows the results of 3 β -HSD method. A cytoplasmic deposit within the Leydig cells (Lc) was considered as a positive reaction. The rest of the elements within the interstitial tissue (IT) were not stained with this reaction. Tissue-Tek[®], 3 β -HSD method. ED, efferent duct. Scale bars: 20 μ m.

Male reproductive system in sole

species that is supposed to be quite similar to that reported in captive *S. solea* (Baynes et al., 1994). In this species, fish form pairs during spawning, with the male always positioned under the female, so that the genital pores were close together. In this paired swimming period, gamete release would take place, thus providing the most suitable opportunity for a large quantity of oocytes to be fertilized by spermatozoa.

Despite the differences in external morphology between *S. senegalensis* testis and the vast majority of teleosts that have been studied, transverse testis sections show more similarities. Testis of *S. senegalensis* presents a radial or reniform structure with two main regions, the cortical one where germ cells are produced, and the medullar one, which consists of the efferent duct system that collects and stores the sperm. Therefore, the function changes from germ cell production in the outer region to sperm collection and storage in the central medulla. This structure has been reported in many other teleosts species, like anglerfish *Lophiomus setigerus* (Vahl) (Yoneda et al., 1998), cobia *Rachycentron canadum* (L.) (Brown-Peterson et al., 2002), and bluefin tuna *Thunnus thynnus* (L.) (Abascal et al., 2004).

In *S. senegalensis* only SPG and SPC are inside the spermatocysts, because SPD are released into the lobule lumen, where they transform into SPZ. This unusual feature has been described in very few fishes like *Ophidion* sp. (Mattei et al., 1993), *L. setigerus* (Yoneda et al., 1998), and small red scorpionfish *Scorpaena notata* (Rafinesque) (Muñoz et al., 2002). In these species, several types of developing germ cells from SPC to SPD are released from the spermatocysts into the lobule or tubule lumen (Yoneda et al., 1998). Mattei et al. (1993) concluded that this type of spermatogenesis should be termed semi-cystic and distinguished from the cystic type which applies to most teleosts, like *P. americanus* (Harmin et al., 1995) and *H. hippoglossus* (Weltzien et al., 2002).

Spermatocysts are distributed all along the seminiferous lobules, as corresponds to unrestricted spermatogonial type (Grier, 1993). Despite this, the majority of them containing SPG-A are found at the distal part of the lobules, which may be reported as an intermediate type between the restricted spermatogonial type, reported in Atheriniformes and some Cyprinodontids like mummichog *Fundulus heteroclitus* (L.) (Selman and Wallace, 1986), and the unrestricted spermatogonial type, found in all other teleosts to date. Muñoz et al. (2002) described a similar situation for SPG in *S. notata*, though they pointed out that the different spermatogenetic stages appeared to develop as the germ cells approach the centre of the gonad, similar to the process in the restricted-type testis. This feature was not observed in *S. senegalensis*, where SPD can be released relatively near the distal part of the lobule.

S. senegalensis testis, as in all other vertebrates (Lo Nostro et al., 2003), is composed of a germinal compartment, where germ cells associated with Sertoli cells are located, and a non-germinal or interstitial

compartment, in which myoid cells, collagen fibres, Leydig cells, amyelinic nerves, MMC's, and capillaries can be observed.

Myoid cells, first described in teleosts testis by Billard (1970), border the lobules and ducts forming an incomplete layer, as other authors have reported (Grau, 1992; Lo Nostro et al., 2004). Grier et al. (1989) suggested that they could form a contractile network, which would facilitate the expulsion of sperm during spawning.

Leydig cells have been reported as typical components of testicular tissue in the studied teleost species (Billard, 1983; Nagahama, 1983). The positive reaction of 3 β -HSD demonstrated in *S. senegalensis* Leydig cells seems to confirm the steroidogenic capacity of these cells, as in Leydig cells from common goby *Padogobius martensi* (Günther) (Cinquetti and Dramis, 2003) and swamp eel *Synbranchus marmoratus* (Bloch) (Lo Nostro et al., 2004). These authors also reported that these cells are the only ones that display ultrastructural features of steroidogenic cells: extensive smooth endoplasmic reticulum and mitochondria with tubular cristae. Arellano (1999) reported the same ultrastructural characteristics in *S. senegalensis* Leydig cells. All these features, together with the absence of reactivity of germ and Sertoli cells to the 3 β -HSD enzymatic method, confirm that Leydig cells are the only cell type that produces androgens inside the testis of *S. senegalensis*. However, it remains to be investigated in flatfish whether the testis is the main androgen producer or whether extra-testicular tissues (Cavaco et al., 1997) also have the capacity of androgen production or conversion (Weltzien et al., 2004). In African catfish *Clarias gariepinus* (Burchell), Cavaco et al. (1997) concluded that the hepatic production of 11-Ketotestosterone, the main androgen in teleosts (Borg, 1994), was of primary relevance in vivo. Preliminary data indicate that *S. senegalensis* liver does not have this capacity, since 3 β -HSD enzymatic activity was not detected within this tissue (unpublished data).

MMC's are groups of different types of cells, mainly macrophages (Agius and Roberts, 2003; Lo Nostro et al., 2004) and granulocytes (Grier and Taylor, 1998). These structures have been reported as common components of fish spleen, kidney and liver (Haaparanta et al., 1996; Arellano, 1999; Simpson et al., 2000; Mizuno et al., 2002). Their presence in the testis has been described in several teleosts like common snook *Centropomus undecimalis* (Bloch) (Grier and Taylor, 1998) and *P. martensi* (Cinquetti and Dramis, 2003). Grier and Taylor (1998) pointed out that occurrence of MMC's in gonads could be a generalized mechanism of gonadal regression in animals with an annual reproductive cycle. Normally, MMC's accumulate pigments like hemosiderin, lipofuscin, ceroids and melanin (Sarasquete and Gutiérrez, 1984; Wolke, 1992).

In the germinal compartment, a specific number of Sertoli cells surround a clone of germ cells all at the same stage of development (Pudney, 1995). In this unit

(spermatocyst), Sertoli cells attach to one another by specialized junctional complexes resulting in a blood-testis barrier, that provide the germ cells with physical support and factors needed for its survival, proliferation and differentiation (Weltzien et al., 2004). Functions of somatic Sertoli cells seem to be metabolites transport (Grier, 1975; Billard et al., 1982) and phagocytosis of residual bodies and degenerating germ cells including residual sperm (Grier, 1993; Grier and Taylor, 1998).

Morphological features of *S. senegalensis* germ cells are similar to those described previously (Arellano, 1999) and comparable to those extensively reported in teleosts like flounder *Platichthys flesus* (L.) (Gill et al., 2002) and *H. hippoglossus* (Weltzien et al., 2002).

Our histochemical study showed an increase in total proteins, and especially in those rich in basic aminoacids like arginine, as spermatogenesis progresses. Similar results have been reported in toadfish *Halobatrachus didactylus* (Schneider) (Blanco, 1991) and amberjack (Risso) *Seriola dumerili* (Grau, 1992). In teleosts, it has been demonstrated that concomitantly with nuclear condensation during spermatogenesis, nuclear histones are replaced by protamins (Alfert, 1956; Louie and Dixon, 1972). Protamins are strongly basic proteins and contain abundant rests of lysine and arginine. Therefore, the increase in proteins rich in basic aminoacids during *S. senegalensis* spermatogenesis would be related to protamins synthesis and chromatin package. *S. senegalensis* SPZ contain a small quantity of reserves, mainly carboxylated mucosubstances /glycoproteins, and they lack lipids like SPZ from other teleosts (Blanco, 1991). Billard (1986) pointed out that these scarce reserves were typical of primitive SPZ that are present in species with external fertilization.

This study has precisely described the anatomy, histology and histochemical characteristics of the male reproductive system in *S. senegalensis*, a highly attractive flatfish for the aquaculture industry in Spain and Portugal. Gonadosomatic index values and the type of spermatogenesis, differ greatly from other Pleuronectiformes that have been studied. Therefore, the reproductive strategy in this species may also be different, a hypothesis that requires further investigation. The present work contributes to improve the knowledge of the reproductive biology of *Solea senegalensis* in our aim to control its reproduction in captivity.

Acknowledgements. This research has been funded by the Spanish MCYT project no. AGL2000-0179-P4-02 to G. Martínez-Rodríguez and by the CSIC grant (I3P programme, ESF) to A. García-López. The authors thank V. Fernández Pasquier, from PROMAN S.L., for providing the broodstock and F. Antonelli for her help in histological observations. Thanks are also given to J. L. Palazón, I. Viaña and F. Lo Nostro for their technical assistance in histochemical methods.

References

Abascal F.J., Megina C. and Medina A. (2004). Testicular development

- in migrant and spawning bluefin tuna (*Thunnus thynnus* (L.)) from the eastern Atlantic and Mediterranean. *Fish. Bull.* 102, 407-417.
- Agius C. and Roberts R.J. (2003) Melano-macrophage centres and their role in fish pathology. *J. Fish Dis.* 26, 499-509.
- Alfert M. (1956). Chemical differentiation of nuclear proteins during spermatogenesis in the salmon. *J. Biophys. Biochem. Cytol.* 2, 109-114.
- Anguis V. and Cañavate J.P. (2005). Spawning of captive Senegal sole (*Solea senegalensis*) under a naturally fluctuating temperature regime. *Aquaculture* 243, 133-145.
- Arellano J.M. (1999). Descripción morfoestructural e histoquímica en el lenguado senegalés, *Solea senegalensis* (Kaup, 1858). Cuantificación y efectos histopatológicos del cobre. Ph.D. Thesis. Universidad de Cádiz. Spain.
- Bancroft J.D. and Stevens A. (1990). Theory and practice of histological techniques. 2nd edition. Churchill Livingstone. Edinburgh.
- Barr W.A. (1963). The endocrine control of the sexual cycle in the plaice, *Pleuronectes platessa* (L.). III. The endocrine control of spermatogenesis. *Gen. Comp. Endocrinol.* 3, 216-225.
- Baynes S.M., Howell B.R., Beard T.W. and Hallam J.D. (1994). A description of spawning behaviour of captive dover sole, *Solea solea* (L.). *Neth. J. Sea Res.* 32, 271-275.
- Billard R. (1970). Ultrastructure comparée de spermatozoïdes de quelques poissons Téléostéens. In: *Comparative Spermatology*. Baccetti B. (ed). Academic Press. New York. pp 71-79.
- Billard R. (1983). A quantitative analysis of spermatogenesis in the trout, *Salmo trutta fario*. *Cell. Tissue Res.* 230, 495-502.
- Billard R. (1986). Spermatogenesis and spermatology of some teleost fish species. *Reprod. Nutr. Dev.* 26, 877-920.
- Billard R., Fostier A., Weil C. and Breton B. (1982). Endocrine control of spermatogenesis in Teleost fish. *Can. J. Fish. Aquat. Sci.* 39, 65-79.
- Blanco M.A. (1991). Estudio histológico y bioquímico durante la reproducción de *Halobatrachus didactylus* en la Bahía de Cádiz. Ph.D. Thesis. Universidad de Cádiz. Spain.
- Borg B. (1994). Androgens in teleost fishes. *Comp. Biochem. Physiol. C* 109, 219-245.
- Bromley P.J. (2003). The use of market sampling to generate maturity ogives and to investigate growth, sexual dimorphism and reproductive strategy in central and south-western North Sea sole (*Solea solea* L.). *ICES J. Mar. Sci.* 60, 52-65.
- Brown-Peterson N.J., Grier H.J. and Overstreet R.M. (2002). Annual changes in germinal epithelium determine male reproductive classes of the cobia. *J. Fish Biol.* 60, 178-202.
- Cavaco J.E.B., Vischer H.F., Lambert J.G.D., Goos H.J.Th. and Schulz R.W. (1997). Mismatch between patterns of circulating and testicular androgens in African catfish, *Clarias gariepinus*. *Fish Physiol. Biochem.* 17, 155-162.
- Cinquetti R. and Dramis L. (2003). Histological, histochemical, enzyme histochemical and ultrastructural investigations of the testis of *Padogobius martensi* between annual breeding seasons. *J. Fish Biol.* 63, 1402-1428.
- Dinis M.T. (1992). Aspects of the potential of *Solea senegalensis* Kaup for aquaculture: larval rearing and weaning to artificial diets. *Aquacult. Fish. Manag.* 23, 515-520.
- Drake P., Arias A.M. and Rodríguez, A. (1984). Cultivo extensivo de peces marinos en los esteros de las Salinas de San Fernando (Cádiz): II. Características de la producción de peces. *Inf. Tec. Inst. Inv. Pesq.* 116, 1-23.
- Gill M.E., Spiropoulos J. and Moss C. (2002). Testicular structure and

Male reproductive system in sole

- sperm production in flounders from a polluted estuary: a preliminary study. *J. Exp. Mar. Biol. Ecol.* 281, 41-51.
- Grau A. (1992). Aspectos histológicos, ciclo reproductor y principales procesos patológicos de *Seriola dumerili*, Risso 1810 (Carangidae). Ph.D. Thesis. Universidad Autónoma de Barcelona. Spain.
- Grier H.J. (1975). Aspects of the germinal cyst and sperm development in *Poecilia latipinna* (Teleostei: Poeciliidae). *J. Morphol.* 146, 229-250.
- Grier H.J. (1993). Comparative organization of Sertoli cells including the Sertoli cell barrier. In: The sertoli cell. Russel L.D. and Griswold M.D. (eds). Cache River Press. Clearwater (Florida). pp 704-739.
- Grier H.J. and Taylor R.G. (1998). Testicular maturation and regression in the common snook. *J. Fish Biol.* 53, 521-542.
- Grier H.J., Van der Hurk R. and Billard R. (1989). Cytological identification of cell types in the testis of *Esox lucius* and *E. niger*. *Cell Tissue Res.* 257, 491-496.
- Gutiérrez M., Sarasquete C. and Rodríguez R.B. (1985). Caracteres citohistoquímicos de carbohidratos y proteínas durante la ovogénesis del lenguado, *Solea senegalensis* Kaup, 1858. *Inv. Pesq.* 49, 353-363.
- Haaparanta A., Valtonen E.T., Hoffmann R. and Holmes, J. (1996). Do macrophage centres in freshwater fishes reflect the differences in water quality?. *Aquat. Toxicol.* 34, 253-272.
- Harmin S.A., Crim L.W. and Wiegand M.D. (1995). Plasma sex steroid profiles and the seasonal reproductive cycle in male and females winter flounder, *Pleuronectes americanus*. *Mar. Biol.* 121, 601-610.
- JACUMAR (Junta Asesora de Cultivos Marinos) (2005). Estadísticas de producción del año 2004. Ministerio de Agricultura, Pesca y Alimentación. Spain.
- Lo Nostro F.L., Grier H.J., Meijide F.J. and Guerrero G.A. (2003). Ultrastructure of the testis in *Synbranchus marmoratus* (Teleostei, Synbranchidae): the germinal compartment. *Tissue Cell* 35, 121-132.
- Lo Nostro F.L., Antonelli F.N., Quagio-Grassiotto I. and Guerrero G.A. (2004). Testicular interstitial cells, and steroidogenic detection in the protogynous fish, *Synbranchus marmoratus* (Teleostei, Synbranchidae). *Tissue Cell* 36, 221-231.
- Louie A.J. and Dixon G.H. (1972). Trout testis cells I. Characterization by deoxyribonucleic acid and protein analysis of cells separated by velocity sedimentation. *J. Biol. Chem.* 247, 5490-5497.
- Martoja R. and Martoja-Pierson M. (1970). Técnicas de histología animal. 1st edition. Toray Masson. Barcelona.
- Mattei X., Siau Y., Thiaw O.T. and Thiam D. (1993). Peculiarities in the organization of testis of *Ophidion* sp. (Pisces, Teleostei). Evidence of two types of spermatogenesis in teleost fish. *J. Fish Biol.* 43, 931-937.
- Medina A., Megina C., Abascal F.J. and Calzada A. (2000). The spermatozoon morphology of *Solea senegalensis* (Kaup, 1858) (Teleostei, Pleuronectiformes). *J. Submicrosc. Cytol. Pathol.* 32, 645-650.
- Mizuno S., Misaka N., Miyakoshi Y., Takeuchi K. and Kasahara N. (2002). Effects of starvation on melano-macrophages in the kidney of masu salmon (*Oncorhynchus masou*). *Aquaculture* 209, 247-255.
- Muñoz M., Casadevall M. and Bonet S. (2002). Testicular structure and semicyclic spermatogenesis in a specialized ovuliparous species: *Scorpaena notata* (Pisces, Scorpaenidae). *Acta Zool.* 83, 213-219.
- Nagahama Y. (1983). The functional morphology of teleost gonads. In: *Fish physiology*. Vol. IX. Part A. Hoar W.S., Randall D.J. and Donaldson E.M. (eds). Academic Press. New York. pp 223-275.
- Pearse A.G.E. (1985). Histochemistry. Theoretical and Applied. Vol. II: Analytical Technology. 4th edition. Churchill Livingstone. Edinburgh.
- Pudney J. (1995). Spermatogenesis in nonmammalian vertebrates. *Microsc. Res. Tech.* 32, 459-497.
- Rodríguez R.B. (1984). Biología y cultivo de *Solea senegalensis* Kaup 1858 en el Golfo de Cádiz. Ph.D. Thesis. Universidad de Sevilla. Spain.
- Sarasquete C. and Gutiérrez M. (1984). Caracteres histoquímicos de los granos de pigmento marrón-negro del riñón de dorada, *Sparus aurata* L. *Inv. Pesq.* 48, 539-547.
- Schulz R.W. and Miura T. (2002). Spermatogenesis and its endocrine regulation. *Fish Physiol. Biochem.* 26, 43-56.
- Selman K. and Wallace R.A. (1986). Gametogenesis in *Fundulus heteroclitus*. *Am. Zool.* 26, 173-192.
- Simpson M.G., Parry M., Kleinkauf A., Swarbreck D., Walker P. and Leah R.T. (2000). Pathology of the liver, kidney and gonad of flounder (*Platichthys flesus*) from a UK estuary impacted by endocrine disrupting chemicals. *Mar. Environ. Res.* 50, 283-287.
- Sol S.Y., Olson O.P., Lomax D.P. and Johnson L.L. (1998). Gonadal development and associated changes in plasma in plasma reproductive steroids in English sole, *Pleuronectes vetulus*, from Puget Sound, Washington. *Fish. Bull.* 96, 859-870.
- Weltzien F.A., Taranger G.L., Karlsten Ø. and Norberg B. (2002). Spermatogenesis and related plasma androgen levels in Atlantic halibut (*Hippoglossus hippoglossus* L.). *Comp. Biochem. Physiol. A* 132, 567-575.
- Weltzien F.A., Andersson E., Andersen Ø., Shalchian-Tabrizi K. and Norberg B. (2004). The brain-pituitary-gonad axis in male teleost, with special emphasis on flatfish (*Pleuronectiformes*). *Comp. Biochem. Physiol. A* 137, 447-477.
- Wolke R.E. (1992). Piscine macrophage aggregates: A review. *Ann. Rev. Fish Dis.* 2, 91-108.
- Yoneda M., Tokimura M., Fujita H., Takeshita N., Takeshita K., Matsuyama M. and Matsuura S. (1998). Reproductive cycle and sexual maturity of the anglerfish *Lophiomus setigerus* in the East China Sea with a note on specialized spermatogenesis. *J. Fish Biol.* 53, 164-178.

Accepted July 11, 2005