

DEC1 expression in 1p-aberrant oligodendroglial neoplasms

M. Preusser¹, P. Birner², I.M. Ambros³, P.F. Ambros³, H. Budka¹, A.L. Harris⁴ and J.A. Hainfellner¹

¹Institute of Neurology, ²Institute of Clinical Pathology, Medical University Vienna,

³Children Cancer Research Institute (CCRI), St. Anna Children Hospital Vienna, Austria, and

⁴Cancer Research UK, Growth Factor Group, Weatherall Institute of Molecular Medicine, John Radcliffe Hospital, Oxford, UK

Summary. Background. Expression of hypoxia-related tissue factors in 1p-aberrant oligodendroglial neoplasms diminishes patient outcome. Differentiated embryochondrocyte expressed gene 1 (DEC1) has been described as novel hypoxia-related tissue factor. In our study, we assessed the expression of DEC1 in 1p aberrant oligodendroglial neoplasms and its association with necrosis and expression of hypoxia-inducible factor 1 α (HIF-1 α), carbonic anhydrase-9 (CA9), and vascular endothelial growth factor-mRNA (VEGF). Materials and methods. 44 primary and 16 recurrent oligodendroglial neoplasms with 1p-aberrations were investigated immunohistochemically for the expression of DEC1, HIF-1 α , and CA9. Expression of VEGF was investigated using in situ hybridization. DEC1 expression was correlated with necrosis and with expression of HIF-1 α , CA9, and VEGF. Results. DEC1 was expressed in tumor cell nuclei, and occasionally in nuclei of endothelial cells, and glial and neuronal cells of surrounding brain tissue. High expression (>10% of tumor cells immunolabeled) of DEC1 was found in 56 cases, low expression (<10% of tumor cells immunolabeled) was found in 3 cases. In 1 case no expression of DEC1 was evident. DEC1 expression showed no topographical association with necrosis or expression of HIF-1 α , CA9, or VEGF. Conclusion. DEC1 expression is found in the majority of 1p-aberrant oligodendroglial neoplasms and does not correlate with necrosis or expression of HIF-1 α , CA9, VEGF. Thus, immunohistochemical analysis of DEC1 expression is in our hands not suitable for detection of tissue hypoxia in this type of primary brain tumor.

Key words: Oligodendroglioma, Immunohistochemistry, Hypoxia

Introduction

Oligodendroglial tumors are diffusely infiltrating primary neoplasms of the central nervous system (Kleihues and Cavenee, 2000). Standard therapy regimens include surgical tumor removal and postoperative adjuvant radiotherapy and/or chemotherapy (Kleihues and Cavenee, 2000). Patient outcome under adjuvant therapy is variable. In oligodendroglial neoplasms aberrations of chromosome arm 1p indicate increased chemosensitivity of the tumor tissue (Cairncross et al., 1998). Additionally, there is evidence that expression of hypoxia-related tissue factors influences therapeutic success: it has been shown that adjuvantly treated patients with 1p-aberrant oligodendroglial neoplasms whose tumors express hypoxia-related tissue factors have shorter survival times (Birner et al., 2004). This observation is compatible with the well known negative effect of tissue hypoxia on the sensitivity of tumor tissue to chemo- and radiotherapy (Knisely and Rockwell, 2002; Smits, 2002). Recent therapeutic advances allow manipulation of tissue oxygenation levels in vivo (Kaanders et al., 2002). These therapeutic strategies are aimed at increasing tumor tissue oxygenation levels and therefore sensitivity of tumor tissue to adjuvant radio- and chemotherapy. A reliable method of hypoxia detection is needed to specifically apply these therapeutic approaches to patients with hypoxic tumors. Histopathological techniques like immunohistochemistry or in situ hybridisation allow detection of tissue factors upregulated under hypoxic conditions, thus serving as indicators of tissue hypoxia (Vordermark and Brown, 2003). Such histopathological markers could become tools for adjuvant therapy decisions in the clinical setting. Therefore, there is a strong need to carefully assess each new hypoxia-related tissue factor for clinical usefulness. DEC1 has recently been proposed as potential clinically useful hypoxia-associated tissue factor (Giatromanolaki et al., 2003). DEC1 was described as a protein, which is involved in cell

differentiation, proliferation, and apoptosis and may be upregulated in response to hypoxic tissue conditions (Ivanova et al., 2001; Miyazaki et al., 2002; Giatromanolaki et al., 2003; Turley et al., 2004). Expression of DEC1 is found in various human cancers including breast, colon, lung, and head and neck cancers (Ivanova et al., 2001; Giatromanolaki et al., 2003; Turley et al., 2004).

In this study we aimed to evaluate the feasibility of DEC1 for detection of tissue hypoxia in 1p-aberrant oligodendroglial neoplasms. We immunohistochemically assessed DEC1 expression in 1p-aberrant oligodendroglial neoplasms and its association with necrosis and expression of the hypoxia-related tissue factors HIF-1 α , CA9, and VEGF-mRNA.

Materials and methods

Patients and materials

Tissues of these cases have been used in previous studies (Birner et al., 2001; Bredel et al., 2002; Gelpi et al., 2003). In brief, the total cohort of 44 patients comprised 29 men and 15 women. Mean age of patients with primary tumors was 44 \pm 9.2 years. In addition to surgery, 18 patients received adjuvant radiotherapy, and 9 patients combined radio-chemotherapy. No adjuvant therapy was administered to 13 patients; no information was available in 4 patients. Mean follow up time was 60 months (range 1-150 months), during this observation time, 13 patients (29.5%) died from their disease.

Routinely processed and paraffin-embedded tissue specimens of all 44 primary and of 16 recurrent oligodendroglial tumors (44 pure oligodendrogliomas and 16 oligoastrocytomas) were included in this study. Histological typing and grading was performed according to WHO criteria (Kleihues and Cavenee, 2000). 42 grade II (24 pure oligodendrogliomas and 18 oligoastrocytomas) and 18 grade III (all pure oligodendrogliomas) tumours were included in this study. All the specimens had aberrations (44 cases with deletion and 16 cases with imbalance status) of chromosome 1p. In addition, 45 cases had 19q deletion and 7 cases had 19q imbalance. Two tumours showed normal 19q status and in 6 cases 19q status was not assessed. Imbalance is the terminus technicus for a dysequilibrium of paracentromeric and subtelomeric hybridization signals exceeding a 2:1 ratio (e.g. 4:2). Imbalance usually represents deletion status in tumor cells harboring a polyploid genome (Ambros et al., 2001).

Methods

Immunostaining of DEC1 was performed on 4 μ m thick sections of formalin-fixed and paraffin-embedded tumor specimens using the rabbit polyclonal antiserum (CW27, dilution 1:5000) to the pDEC1 C-terminus. Sections were deparaffinized and peroxidase was

quenched with methanol and 3% H₂O₂ for 15 minutes. Thereafter, slides were placed in antigen unmasking buffer, pH 6.0 (code: TAR001, ILEM, Italy), followed by microwave treatment (3-4 minutes). The primary antibody was applied for 90 min at room temperature. Following washing with TBS, sections were incubated with a secondary mouse anti-rabbit antibody (Kwik Biotinylated Secondary, 0.69A Shandon-Upshaw, Pittsburgh, PA, USA) for 15 minutes and washed in TBS. Kwik streptavidin peroxidase reagent (039A Shandon-Upshaw, Pittsburgh, PA, USA) was applied for 15 minutes and sections were again washed in TBS. The colour was developed by 15 minutes incubation with DAB solution and sections were counterstained with haematoxylin. Normal liver sections with strong nuclear DEC1 expression were used as positive controls. Normal rabbit immunoglobulin-G was substituted for the primary antibody as the negative control, at a concentration where immunostaining of control slides gave faint cytoplasmic staining.

As described previously (Gelpi et al., 2003), fluorescent in situ hybridization (FISH) on isolated tumor nuclei extracted from paraffin-embedded tissue samples was performed using paracentromeric probe D1Z1 (1q12) and subtelomeric probe D1Z2 (1p36.3) for 1p. For 19q, probes were located on 19pter and 19q13.3 (all probes Q-BIOgene, Heidelberg). PCR analysis of 1p status was not used in this study. Immunostaining of HIF-1 α , and CA9 was performed as described previously (Birner et al., 2004). For anti-HIF-1 α (BD Transduction Laboratories, Franklin Lakes, NJ, #H72320) and anti-CA9 (M75, Oxford University) immunostainings the dilutions were 1:25 and 1:20, respectively.

For in situ hybridisation of VEGF-mRNA, 4 μ m thick sections of formalin fixed material were dewaxed and pretreated with HCl, Proteinase K and by acetylation as described previously (Breitschopf et al., 1992). In brief, the cDNA probes containing the human VEGF or FLT gene were digoxigenin labeled by in vitro transcription according to the producers manual (Roche) with an additional cleaning step using S-300 Sephacryl MicroSpin Columns (Amersham Biosciences) in order to completely remove unincorporated digoxigenin-labeled nucleotides. Hybridisation was performed over night at 65°C and after washing steps the result was visualised by developing with nitroblue tetrazolium chloride and 5-bromo-4-chloro-3-indolyl-phosphate (NBT/BCIP; Roche) over 3-5 days under daily control of the signal intensity.

Statistics

Chi-square test was used as appropriate. A two-tailed p-value of <0.05 was considered as significant.

Evaluation

DEC1 immunolabeling showed nuclear staining of

DEC1 in oligodendroglial neoplasms

variable intensity. Because of the high variability in staining intensity, no clear cut-off level could be defined. Therefore, nuclear staining intensity was not assessed. The fraction of immunolabeled tumor cell nuclei was semiquantitatively evaluated in the area with the highest density of labeled nuclei irrespective of staining intensity. No DEC1-expression: no tumor cell nuclei labeled, low DEC1-expression: <10% of tumor cells immunolabeled (estimated by visual impression), high DEC1-expression: >10% of tumor cells immunolabeled (estimated by visual impression).

A tumor was classified as positive for HIF-1 α when at least five unequivocal positive tumor cells (distinct immunoreactivity of nuclei) were found in the slide. A

tumor was classified as positive for CA9 or VEGF-mRNA-expression, if at least two distinct foci of tumor cells were stained.

Presence of necrosis was evaluated according to a “yes versus no”-principle on routinely Hematoxylin and Eosin stained sections.

Results

Nuclear anti-DEC 1 immunostaining was found in tumor cells (Fig. 1A), endothelial cells of vessels in non-neoplastic tissue, and endothelial cells of tumor vessels. Further, occasional and scattered glial and neuronal cells of surrounding brain tissue were also stained (Fig. 1B).

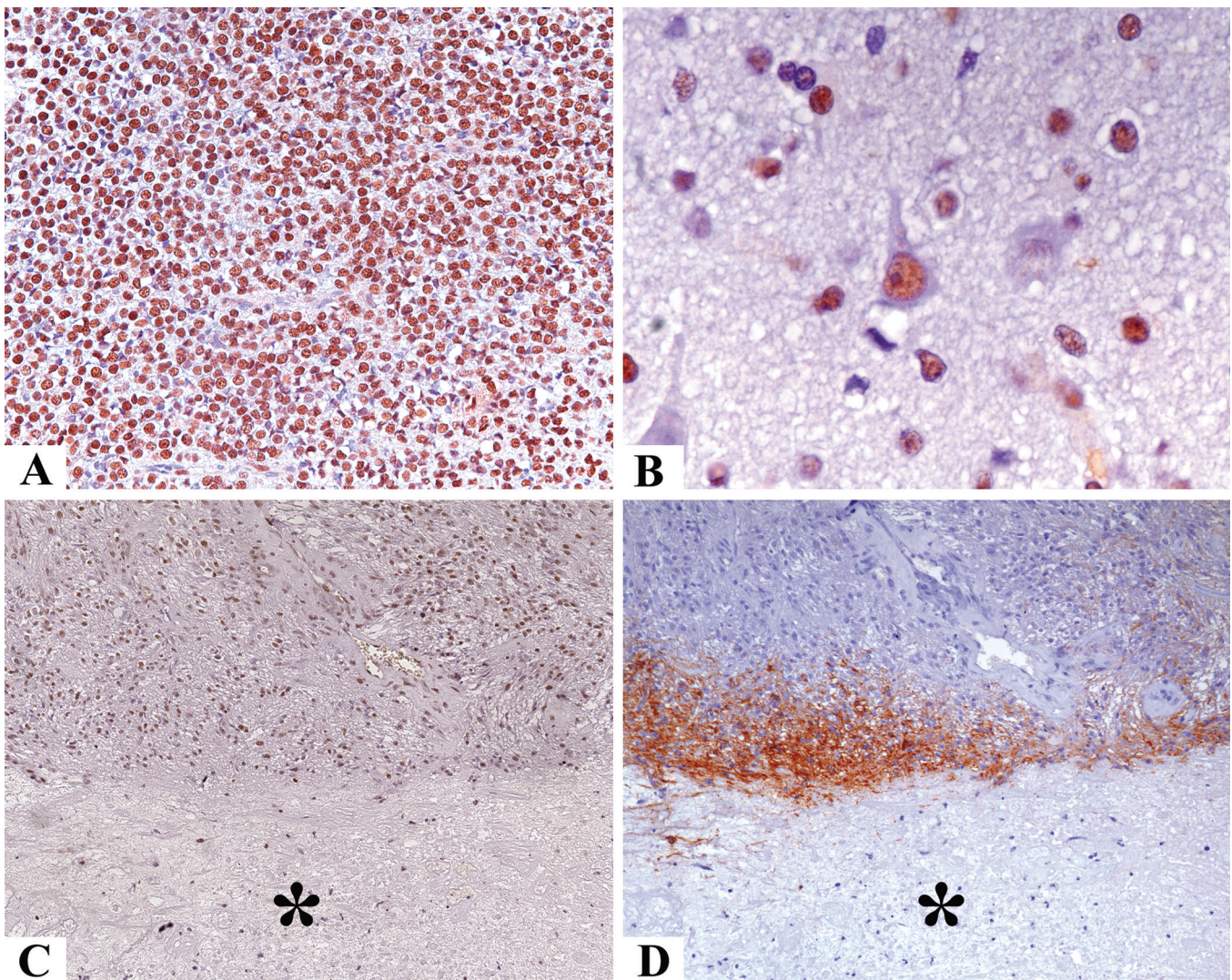


Fig. 1. **A.** Nuclear anti-DEC 1 immunostaining is evident in the majority of tumor cells (anti-DEC1, x 200). **B.** Nuclear anti-DEC 1 immunostaining is evident in neuronal and glial cells of surrounding brain tissue (anti-DEC1, x 600). **C.** There is no perinecrotic enhancement of anti-DEC1 immunolabeling of tumor cells (asterisk: necrotic tumor tissue; anti-DEC1, x 100). **D.** In contrast to DEC1, CA9 is intensely expressed in perinecrotic tissue (adjacent section showing the same microscopic field as in Figure 1C) (asterisk: necrotic tumor tissue; anti-CA9, x 100).

We did not observe anti-DEC1 immunoreactivity in cytoplasm or on cell membranes. Positive cases showed a diffuse distribution of tumor cells with anti-DEC1-immunolabeled nuclei (Fig. 1A). There was only one case devoid of anti-DEC1 immunostaining of tumour tissue. In this case, we found anti-DEC1 immunolabelling of few preexisting nerve cells in non-neoplastic tissue. In some cases, there was patchy accentuation of immunoreactive tumor cells. There was no perinecrotic accumulation of tumor cells with anti-DEC1-immunolabeled nuclei (Fig. 1C). In contrast, VEGF-mRNA, HIF-1 α , and CA9 expression (Fig. 1D) showed focal perinecrotic accentuation in overlapping tissue areas. In addition, a fraction of cases showed at lower intensity diffuse expression of these factors in tissue areas distant from necrosis. Expression of these factors in areas distant from necrosis showed no definite overlap. Necrosis was present in 10 of the primary tumours and 6 of the recurrent tumours. Results of semiquantitative evaluation of DEC1 expression are shown in Table 1.

Statistical analysis showed positive correlations of expression of HIF-1 α ($p=0.04$, Chi-square test), CA9 ($p<0.0001$, Chi-square test), and VEGF-mRNA ($p<0.0001$, Chi-square test) with presence of necrosis. As 59 of 60 of the cases showed expression of DEC1, no statistical correlation with presence of necrosis or expression of VEGF-mRNA, HIF-1 α , or CA9 was possible.

Discussion

Histopathological techniques like immunohistochemistry or in situ hybridisation allow detection of tissue factors upregulated under hypoxic conditions, thus serving as indicators of tissue hypoxia (Vordermark and Brown, 2003). Such histopathological markers could become tools for adjuvant therapy decisions in the clinical setting. However, hypoxia assessment using histopathological tissue factors cannot be based on a single-factor basis. We showed in a previous study that only combination of different hypoxia-associated factors indicates prognosis in oligodendroglioma (Birner et al., 2001). So, new factors in combination with established factors could improve accuracy of hypoxia assessment. We tested DEC1, because previous studies showed significant correlation with other hypoxia markers in non-small-cell lung cancer (Giatromanolaki et al., 2003) and

breast cancer (Chakrabarti et al., 2004).

In our series of 1p-aberrant oligodendroglial neoplasms we find expression of DEC1 in a majority of cases. As in previous studies DEC1 expression is confined to cell nuclei and is found both in tumour cells and occasionally in cells of non-neoplastic tissue (Giatromanolaki et al., 2003). DEC1 expression is not upregulated around necrosis, which is a feature commonly considered to be related to tissue hypoxia. Further, in contrast to the findings of previous studies (Giatromanolaki et al., 2003; Chakrabarti et al., 2004), DEC1 expression does not correlate topographically with expression of HIF1 α , VEGF, and CA9. These three factors have been shown to be expressed in a hypoxia-dependent manner in several previous studies (Plate et al., 1992; Viores et al., 1997; Chan et al., 1998; Birner et al., 2001, 2004; Acker and Plate, 2004; Uehara et al., 2004) and show statistical and topographical association with necrosis in our series. The missing association of DEC1 expression with necrosis or expression of HIF1 α , VEGF, CA9 contrast with previous findings in non-CNS neoplasms (Giatromanolaki et al., 2003; Chakrabarti et al., 2004) and argues against a hypoxia dependent regulation of DEC1 in oligodendroglial neoplasms.

We conclude that DEC1 expression is found in the majority of 1p-aberrant oligodendroglial neoplasms. In contrast to observations in non-CNS neoplasms, expression of DEC1 seems not to be influenced significantly by tissue hypoxia. Thus, immunohistochemical analysis of DEC1 expression is in our hands not suitable for detection of tissue hypoxia in this type of primary brain tumor.

Acknowledgements. This work was performed within the Austrian Neurooncology Network (ANN, www.ann.at) and was supported by the Children's Cancer Research Institute (CCRI), St. Anna Children's Hospital Vienna, and by the Scientific Funds of the Mayor of Vienna (Project-No. 2026). We thank Helene Breitschopf (Brain Research Institute, Medical University Vienna) for excellent technical assistance.

References

- Acker T. and Plate K.H. (2004). Hypoxia and hypoxia inducible factors (HIF) as important regulators of tumor physiology. *Cancer Treat. Res.* 117, 219-48.
- Ambros P.F., Ambros I.M., Kerbl R., Luegmayr A., Rumpler S., Ladenstein R., Amann G., Kovar H., Horcher E., De Bernardi B., Michon J. and Gadner H. (2001). Intratumoural heterogeneity of 1p deletions and MYCN amplification in neuroblastomas. *Med. Pediatr. Oncol.* 36, 1-4.
- Birner P., Gatterbauer B., Oberhuber G., Schindl M., Rossler K., Prodingner A., Budka H. and Hainfellner J.A. (2001). Expression of hypoxia-inducible factor-1 alpha in oligodendrogliomas: its impact on prognosis and on neoangiogenesis. *Cancer* 92, 165-171.
- Birner P., Preusser M., Gelpi E., Berger J., Gatterbauer B., Ambros I.M., Ambros P.F., Acker T., Plate K.H., Harris A.L. and Hainfellner J.A. (2004). Expression of hypoxia-related tissue factors correlates with diminished survival of adjuvantly treated patients with chromosome

Table 1. Results of semiquantitative evaluation of DEC1 expression: primary vs. recurrent tumors.

DEC1 EXPRESSION	PRIMARY TUMORS (n=44)	RECURRENT TUMORS (n=16)
none	1 (2.3%)	0 (0%)
low	3 (6.8%)	0 (0%)
high	40 (90.9%)	16 (100%)

DEC1 in oligodendroglial neoplasms

- 1p aberrant oligodendroglial neoplasms and therapeutic implications. *Clin. Cancer Res.* 10, 6567-6571.
- Bredel M., Gatterbauer B., Birner P., Haberler C., Strobel T., Budka H., Rossler K. and Hainfellner J.A. (2002). Expression of DNA topoisomerase IIalpha in oligodendroglioma. *Anticancer Res.* 22, 1301-1304.
- Breitschopf H., Suchanek G., Gould R.M., Colman D.R. and Lassmann H. (1992). In situ hybridization with digoxigenin-labeled probes: sensitive and reliable detection method applied to myelinating rat brain. *Acta Neuropathol.* 84, 581-587.
- Cairncross J.G., Ueki K., Zlatescu M.C., Lisle D.K., Finkelstein D.M., Hammond R.R., Silver J.S., Stark P.C., Macdonald D.R., Ino Y., Ramsay D.A. and Louis D.N. (1998). Specific genetic predictors of chemotherapeutic response and survival in patients with anaplastic oligodendrogliomas. *J. Natl. Cancer Inst.* 90, 1473-1479.
- Chakrabarti J., Turley H., Campo L., Han C., Harris A.L., Gatter K.C. and Fox S.B. (2004). The transcription factor DEC1 (stra13, SHARP2) is associated with the hypoxic response and high tumour grade in human breast cancers. *Br. J. Cancer* 91, 954-958.
- Chan A.S., Leung S.Y., Wong M.P., Yuen S.T., Cheung N., Fan Y.W. and Chung L.P. (1998). Expression of vascular endothelial growth factor and its receptors in the anaplastic progression of astrocytoma, oligodendroglioma, and ependymoma. *Am. J. Surg. Pathol.* 22, 816-826.
- Gelpi E., Ambros I.M., Birner P., Luegmayr A., Drlicek M., Fischer I., Kleinert R., Maier H., Huemer M., Gatterbauer B., Anton J., Rossler K., Budka H., Ambros P.F. and Hainfellner J.A. (2003). Fluorescent in situ hybridization on isolated tumor cell nuclei: a sensitive method for 1p and 19q deletion analysis in paraffin-embedded oligodendroglial tumor specimens. *Mod. Pathol.* 16, 708-715.
- Giatromanolaki A., Koukourakis M.I., Sivridis E., Turley H., Wykoff C.C., Gatter K.C. and Harris A.L. (2003). DEC1 (STRA13) protein expression relates to hypoxia-inducible factor 1-alpha and carbonic anhydrase-9 overexpression in non-small cell lung cancer. *J. Pathol.* 200, 222-228.
- Ivanova A.V., Ivanov S.V., Danilkovitch-Miagkova A. and Lerman M.I. (2001). Regulation of STRA13 by the von Hippel-Lindau tumor suppressor protein, hypoxia, and the UBC9/ubiquitin proteasome degradation pathway. *J. Biol. Chem.* 276, 15306-15315.
- Kaanders J.H., Bussink J. and van der Kogel A.J. (2002). ARCON: a novel biology-based approach in radiotherapy. *Lancet Oncol.* 3, 728-737.
- Kleihues P. and Cavenee W. (2000). World Health Organisation classification of tumours: Pathology and genetics of tumours of the nervous system. Lyon, IARC Press.
- Knisely J.P. and Rockwell S. (2002). Importance of hypoxia in the biology and treatment of brain tumors. *Neuroimaging Clin. N. Am.* 12, 525-536.
- Miyazaki K., Kawamoto T., Tanimoto K., Nishiyama M., Honda H. and Kato Y. (2002). Identification of functional hypoxia response elements in the promoter region of the DEC1 and DEC2 genes. *J. Biol. Chem.* 277, 47014-47021.
- Plate K.H., Breier G., Weich H.A. and Risau W. (1992). Vascular endothelial growth factor is a potential tumour angiogenesis factor in human gliomas in vivo. *Nature* 359, 845-848.
- Smits A. (2002). Low-grade gliomas: clinical and pathobiological aspects. *Histol. Histopathol.* 17, 253-60.
- Turley H., Wykoff C.C., Troup S., Watson P.H., Gatter K.C. and Harris A.L. (2004). The hypoxia-regulated transcription factor DEC1 (Stra13, SHARP-2) and its expression in human tissues and tumours. *J. Pathol.* 203, 808-13.
- Uehara M., Sano K., Ikeda H., Sekine J., Irie A., Yokota T., Tobita T., Ohba S. and Inokuchi T. (2004). Expression of vascular endothelial growth factor and prognosis of oral squamous cell carcinoma. *Oral Oncol.* 40, 321-325.
- Vinore S.A., Youssri A.I., Luna J.D., Chen Y.S., Bhargava S., Vinore M.A., Schoenfeld C. L., Peng B., Chan C.C., LaRochelle W., Green W.R. and Campochiaro P.A. (1997). Upregulation of vascular endothelial growth factor in ischemic and non-ischemic human and experimental retinal disease. *Histol. Histopathol.* 12, 99-109.
- Vordermark D. and Brown J.M. (2003). Endogenous markers of tumor hypoxia predictors of clinical radiation resistance? *Strahlenther. Onkol.* 179, 801-811.

Accepted July 8, 2005