

Tailgut cyst associated with a carcinoid tumor: case report and review of the literature

A. Mathieu¹, R. Chamlou², F. Le Moine³, C. Maris¹, J. Van de Stadt² and I. Salmon¹

¹Department of Pathology, Erase Hospital, Free University of Brussels, Belgium, ²Department of Digestive Surgery, Erasme Hospital, Free University of Brussels, Belgium and ³Department of Medicine, Erase Hospital, Free University of Brussels, Belgium

Summary. We report the case of a 49-year-old woman who presented a tailgut cyst lined by a variety of epithelium including squamous, columnar and transitional. Fortuitously a microscopic carcinoid tumor expressing immunohistochemically neuroendocrine markers was identified in the cystic wall.

Tailgut cysts are congenital abnormalities located in the presacrococcygeal area occurring usually in adult patients. Clinical diagnosis is difficult because they are often asymptomatic. Patients may present symptoms resulting from local mass effects or complications. The differential diagnoses include rectal duplication cysts, cystic sacrococcygeal teratomas, epidermal cysts, epidermoid cysts, anal duct or gland cysts. Magnetic resonance imaging has recently become the modality of choice to image the cyst. Malignant transformation is rare; 23 cases including 10 carcinoid tumors have been reported in the literature. To our knowledge, this is the eleventh case of carcinoid tumor arising in a tailgut cyst.

Key words: Tailgut cyst, Carcinoid tumor, Presacrococcygeal tumor

Introduction

Tailgut cysts (TGCs) are uncommon developmental lesions, which arise in the presacrococcygeal space. Most descriptions are anecdotal; the largest series including 53 cases was collected over a 35-year period by Hjerstad and Helwig (1988) from the American Armed Forces Institute of Pathology. Most of the cases were initially diagnosed as a variety of congenital cysts. Malignant transformation of the epithelial elements has only rarely been reported. After an extensive review of the literature, we were able to identify 23 other cases of malignancy including 10 carcinoid tumors. In this report we documented an additional case of carcinoid tumor

arising within a TGC and reviewed the cases reported under carcinoid tumor in the literature.

Material and methods

A 49-year-old white woman without any relevant medical history was referred to our surgical department for excision of a retrorectal mass. The patient presented with a sensation of rectal fullness and irregular mucus emission for a few months. Physical examination and colonoscopy were unremarkable. The results of the laboratory tests were within normal limits including all the tumoral parameters (CEA, CA19-9, NSE). Computed tomography (CT) showed a retrorectal, ovoid mass at the level of the sacrococcygeal junction. Magnetic resonance imaging (MRI) confirmed the presence of a well-circumscribed cystic retrorectal lesion of 2.3 cm in diameter showing a peripheral contrast enhanced after the injection of gadolinium (Fig. 1A). The 18[F] fluoro-D-glucose (FDG) whole body positron emission revealed a captation of the FDG in the lesion suggesting a neoplastic process. The tumor was resected successfully.

Results

The macroscopic specimen comprised a well-delimited and clearly demarcated unilocular cystic lesion with a maximum diameter of 2.5 cm. No contiguous osseous tissue was present. On sectioning, the cut surface revealed a cystic space containing mucinous material. The cyst wall was of variable thickness ranging from a few millimetres to a maximum of 1.1 cm. No hair, cartilage or other structures consistent with teratoma were identified. No obvious necrosis or haemorrhage was present. By gross examination, no tumor mass was observed. The entire lesion was included for examination.

Microscopically, multiple sections were analysed

Offprint requests to: Isabelle Salmon, MD, PhD, Laboratory of Pathology – Erasmus Hospital, 808 route de Lennik – B-1070. e-mail: isalmon@ulb.ac.be

Abbreviations: CT: Computed tomography, FDG: 18Ffluoro-D-glucose, MRI: Magnetic resonance imaging, TGC: Tailgut cyst

and showed similar features. The cyst was lined with a variety of epithelia. Stratified squamous epithelium was predominant among the mucin-secreting columnar and transitional cells (Fig. 1B-D). No heterologous elements to suggest a teratoma were noted and a well-developed muscular wall was not present, although the adjacent soft tissue contained some disorganised smooth muscle bundles. Immunoreactivity for smooth muscle actin show scattered discontinuous bundles of smooth muscle fibres. Fortuitously, microscopically we observed in the cystic wall a 3 mm carcinoid tumor composed of multiple solid nests of uniform epithelial cells, distributed within a rich capillary network. The tumor cells were cuboidal with slightly granular eosinophilic

cytoplasm and centrally located, uniformly sized nuclei with speckled chromatin and inconspicuous nucleoli (Fig. 1E). The tumor showed immunoreactivity for the neuroendocrine markers chromogranin (Fig. 1F), synaptophysin and neuron specific enolase. The tumor cells were also immunoreactive for keratin (CAM 5.2).

Discussion

TGCs also known as retrorectal cystic hamartoma are congenital disorders present in the presacrococcygeal space. The retrorectal region is a potential space surrounded by the rectum anteriorly, the sacrum and coccyx posteriorly, the peritoneal reflection superiorly,

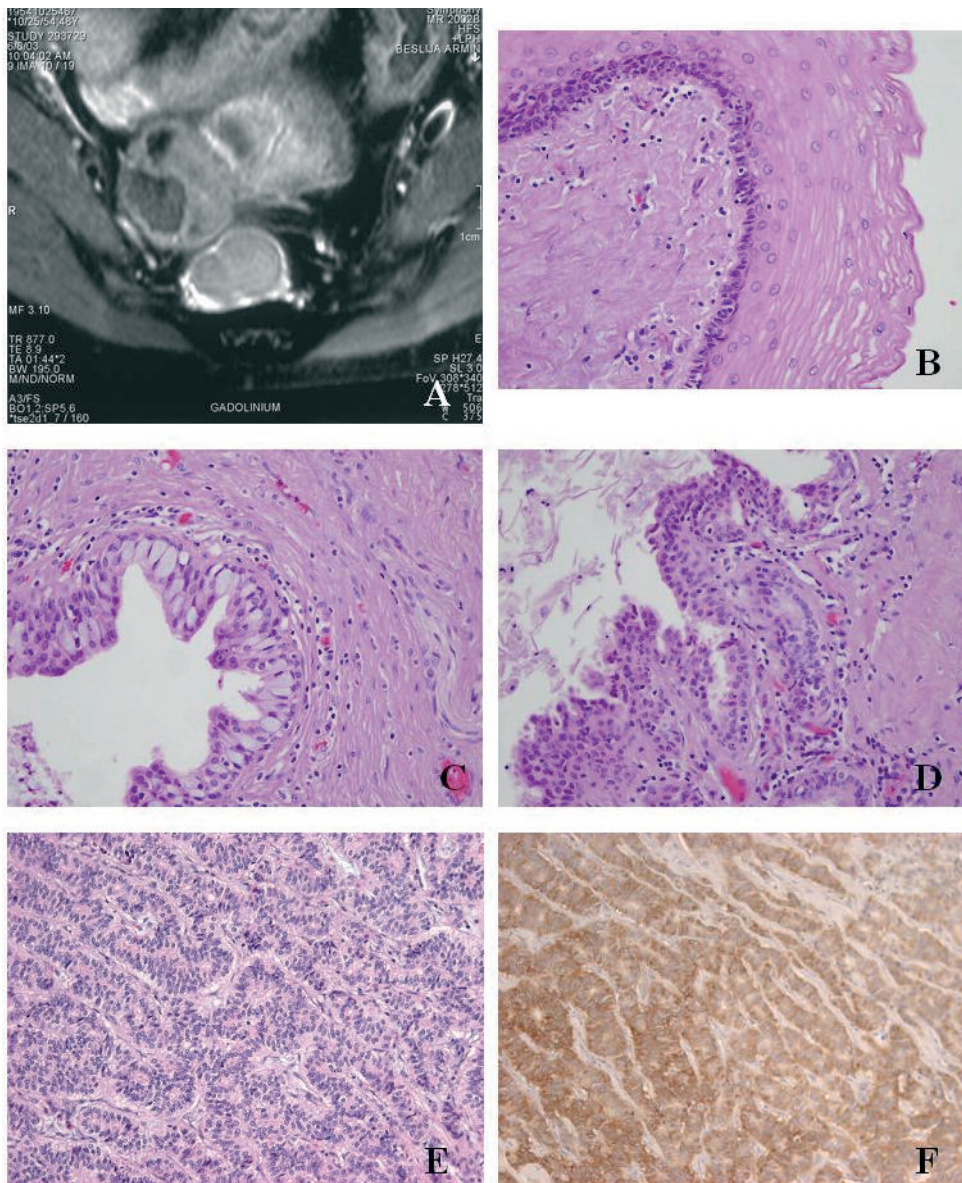


Fig. 1. MR imaging demonstrates a well-delimited round cystic mass with a peripheral gadolinium enhanced (A). Microscopy of the cyst wall showing the variation of the lining cells including squamous (B), columnar (C) and transitional epithelia (D). The carcinoid tumor is composed of ribbons of cuboidal cells with eosinophilic cytoplasm and uniform nuclei. The overall pattern is trabecular (E). There is intense, apical cytoplasmic reactivity for chromogranin (F). B-E: Hematoxylin-eosin; F: Chromogranin. B-D, x 200; E, F, x 100

Tailgut cyst

the elevator ani and coccygeal muscles inferiorly and the iliac vessels and the ureters laterally. A variety of congenital, neoplastic and inflammatory disorders may arise in this region. TGCs seem to be derived from tailgut vestiges. The embryological development of the hindgut and anus is such that the most caudal portion of the hindgut regresses following normal embryogenesis of the anus, rectum and hindgut. Persistence of this embryological remnant in the retrorectal area results in the development of a tailgut cyst. The term TGC is preferred rather than other proposals (retrorectal hamartoma, cyst of postnatal intestine, rectal cyst, myoepithelial hamartoma of the rectum) because it is descriptive and unambiguous (Hjermstad and Helwig, 1988).

TGCs occur predominantly in middle-aged women but it can be detected at any age, including infancy. They are often asymptomatic (Dahan et al., 2001). Patients may present symptoms resulting from a local mass effect (eg, constipation, rectal fullness, lower abdominal pain, and dysuria) with a palpable retrorectal mass at digital

rectal examination, or from a complication. Infections with fistulization and bleeding are the major complications reported.

TGCs should be distinguished from other lesions, which may occur in the retrorectal space: epidermoid and dermoid cysts, rectal duplication cysts, anal duct or gland cysts and teratomas (Dahan et al., 2001). Although TGCs also contain structures of all three germ layers (epithelium, blood vessels, fibrous tissues, smooth muscle), Hjermstad and Helwig (1988) do not accept the view that the lesions are cystic teratomas in view of their stereotyped histological appearance, cyst organisation and absence of tissue other than those of the normal foetal gastrointestinal tract.

Macroscopically, the diameter of the TGCs varies from 1 to 22 cm, half of the cysts appeared empty and the others contain unidentifiable amorphous debris, keratinous debris and mucinous material. According to Peyron and Hjermstad's criteria (Marco et al., 1982; Hjermstad and Helwig, 1988), TGCs are usually multiloculated cysts (81%) lined by squamous,

Table 1. Cases of TGCs with carcinoid tumor.

CASE	AUTHOR, Y	AGE/SEX	CLINICAL FEATURES	GROSS FEATURES	MICROSCOPIC FEATURES	FOLLOW-UP
1	Hood et al 1988	N/A	Constipation and bleeding; retrorectal mass on digital examination	Multilocular cyst	Trabecular gross pattern of typical carcinoid tumor; IH: NSE and AE1-AE3	N/A
2	Hood et al 1988	50/F	Constipation and bleeding; retrorectal mass on digital examination; complex solid and cystic mass on CT scan	Multilocular cyst	Insular gross pattern of typical carcinoid tumor; IH: NSE and AE1-AE3	N/A
3	Lin et al 1992	18/F	Perineal pain, dysuria; cyst with 1 solid area on CT scan	Multilocular cyst 10x6x5 cm	Carcinoid tumor cells grow in ribbons and festoons; IH: NSE	N/A
4	Schnee et al 1994	62/M	Chronic constipation and fecal impaction; CT: non-specific soft tissue mass	Tan-white lobulated parenchyma of 18 cm	Nests of polygonal cells; IH: CAM5.2 and neurofilament	ANED 2y post-operatively
5	Horenstein et al 1998	19/F	Pelvic pain; irregular menstrual cycle; cystic mass on ultrasound	Multicystic mass of 8 cm	Typical carcinoid tumor with a trabecular pattern	ANED 4y post-operatively
6	Prasard et al 2000	69/F	Rectal bleeding and pain	Presacral cystic mass of 4cm with a nodule of 1.5cm	Trabecular and acinar pattern of epithelial cells; IH: cytokeratin and chromogranin	ANED 2y post-operatively
7	Oyama et al 2000	52/M	N/A	Partially cystic lesion of 22cm with solid area	Typical carcinoid tumor; IH: chromogranin, synaptophysin, NSE	N/A
8	Mourra et al 2003	68/M	Anal pain since 3 years; solitary 1.7cm retrorectal tumor on CT	Cystic lesion of 2cm in diameter with a 1.2cm nodule	Trabecular solid nests; IH: cytokeratin, chromogranin, synaptophysin, NSE	ANED 1y post-operatively
9	Song et al 2004	41/F	Acute perianal pain; tumoral palpation at the anorectal junction	Multilocular cystic lesion of 4cm	Trabecular carcinoid tumor, lympho-vascular emboli; IH: AE1-AE3, synaptophysin, chromogranin	Liver and brain metastasis, death 15months later
10	Jacob et al 2004	N/A	N/A	N/A	N/A	N/A
11	Present report	49/F	Rectal fullness, mucus emission; cystic mass on CT scan	Unilocular cystic lesion	Trabecular carcinoid tumor; IH: CAM5.2, chromogranin, synaptophysin, NSE	ANED 2y post-operatively of 2.5cm

N/A: indicates not available, ANED: alive with no evidence of disease, IH: immunohistochemical expression.

transitional and glandular epithelium. Squamous epithelium present in 75% of the cyst is the most common type and probably represents in some cysts a metaplastic process secondary to inflammation. Poorly organised collections of smooth muscle fibres are present in the surrounding connective tissue but no well-formed smooth muscle coat has been seen.

Malignant transformation in TGCs is rare. Ballantyne in 1932 was the first to report a case of an adenocarcinoma arising in a TGC. Since then, 23 cases of malignant transformation in TGCs have been reported in the English literature including 11 adenocarcinomas (Ballantyne, 1932; Marco et al., 1982; Hjermsstad and Helwig, 1988; Lin et al., 1992; Pfannschmidt et al., 1995; Levert et al., 1996; Maruyama et al., 1998; Graadt van Roggen et al., 1999; Prasard et al., 2000; Schwarz et al., 2000; Andea et al., 2005), 10 carcinoid tumors (Hood et al., 1988; Horenstein et al., 1998; Oyama et al., 2000; Mourra et al., 2003; Jacob et al., 2004; Prasard et al., 2000; Schnee et al., 1994; Song et al., 2004), 1 squamous cell carcinoma (Umar et al., 2000) and 1 sarcoma (Moulopoulos et al., 1999). The potential for infection, occurrence of recurrent perianal fistulas and the possibility of malignant transformation emphasize the importance of a complete surgical excision of these lesions.

Carcinoid tumors arising in TGCs are neuroendocrine tumors that are derived from enterochromaffin cells, which are found scattered throughout the body but occur principally in the submucosa of the jejunum and ileum (26%), appendix (19%), rectum (13%) and main bronchi (25%) (Lips et al., 2003). Our case is the eleventh carcinoid tumor described in a TGC. As observed for TGCs without malignancy (Table 1), the patients that presented a carcinoid tumor developed in a TGC were mainly middle-aged women (6 women/3 men) between 18 and 69 years old. All patients for whom the data were available, including our case, presented symptoms resulting from local mass effect: nine patients had pelvic pain, five presented constipation or rectal fullness, three rectal bleeding and one dysuria. Typical signs of carcinoid syndrome, principally related to an excess of serotonin and characterised by paroxysmal flushing, wheezing, water diarrhoea, heart failure and oedema, occurred in none of the patients with a carcinoid tumor in a TGC. This clinical presentation is similar to those observed in carcinoid tumor arising in the colon and rectum (Lips et al., 2003). A digital examination was performed in 6 patients and revealed the presence of a retrorectal mass. Gross examination of the specimens was available for 10 cases and consisted of 9 multiloculated cystic masses and in the present report in a unilocular cystic lesion. The dimensions of the cysts varied from 2 to 22 cm. The presence of a solid mass was specified only for 4 patients (1.2 to 18 cm). We clearly report a fortuitous discovery of a carcinoid tumor arising in a TGC and underline the importance of a careful macroscopic and microscopic examination of the

specimen. The review of the microscopic features showed that all the tumors presented a classical histological carcinoid pattern. Immunohistochemically, the tumor cells expressed cytokeratin and one or more of the neuroendocrine markers (chromogranin, synaptophysin or neuron specific enolase). Three cases including the present report expressed all the neuroendocrine markers. The differential diagnosis of a carcinoid tumor arising in a TGC includes direct extension of colorectal carcinoid tumors into a pre-existing TGC or metastasis from other organs.

The prognosis of the patients depends on performance of complete tumoral resection and especially on tumor histology with a much better prognosis for endocrine tumors when compared with adenocarcinomas arising in TGCs (Edelstein et al., 1996). The reported follow-up revealed that 4 patients with a TGC associated with an adenocarcinoma died of the disease between 4 and 20 months post operatively and the patient with a squamous cell carcinoma died 3 months after the diagnosis. For the patients with a carcinoid tumor the follow-up was available for five of the cases reported in the literature: four are alive with no evidence of disease at 1, 2 or 4 years postoperatively and one patient died of a metastatic disease 15 months after the diagnosis. Our patient is still alive without recurrence 2 years after the diagnosis.

In conclusion, TGCs appear to be a distinct clinicopathologic entity occurring most commonly in young adult women. The anatomic location and the variety of epithelia seen in TGCs support its origin from the tailgut vestiges. Malignancy, although rare, does occur. Carcinoid tumors arising in TGCs didn't differ clinically and histologically from the carcinoid tumor of the colon and rectum. A solid mass may be present but as reported in the present case, the diagnosis can be fortuitous. We underline that a careful histological examination is required in TGC diagnosis.

References

- Andea A.A. and Klimstra D.S. (2005). Adenocarcinoma arising in a tailgut cyst with prominent meningotheelial proliferation and thyroid tissue: case report and review of the literature. *Virchows Arch.* 446, 316-321.
- Ballantyne E.N. (1932). Sacrococcygeal tumors: adenocarcinoma of a cystic congenital embryonal remnant. *Arch. Pathol.* 14, 1-9.
- Dahan H., Arrive L., Wendum D., Docou le Pointe H., Djouhri H. and Tubiana J.M. (2001). Retrorectal developmental cysts in adults: clinical and radiologic-histopathologic review, differential diagnosis, and treatment. *Radiographics* 21, 575-84.
- Edelstein P.S., Wong W.D., La Valleur J. and Rothenberger D.A. (1996). Carcinoid tumor: an extremely unusual presacral lesion. Report of a case. *Dis. Colon Rectum* 39, 938-942.
- Graadt van Roggen J.F., Welvaart K., de Roos A., Offerhaus G.J. and Hogendoorn P.C. (1999). Adenocarcinoma arising within a tailgut cyst: clinicopathological description and follow up of an unusual case. *J. Clin. Pathol.* 52, 310-312.
- Hjermsstad B.M. and Helwig E.B. (1988). Tailgut cysts. Report of 53

Tailgut cyst

- cases. *Am. J. Clin. Pathol.* 89, 139-147.
- Hood D.L., Petras R.E., Grundfest-Broniatowski S. and Jagelman D.G. (1988). Retrorectal cystic hamartoma: report of five cases with carcinoid tumor arising in two. *Am. J. Clin. Pathol.* 89, 433.
- Horenstein M.G., Erlandson R.A., Gonzalez-Cueto D.M. and Rosai J. (1998). Presacral carcinoid tumors: report of three cases and review of the literature. *Am. J. Surg. Pathol.* 22, 251-255.
- Jacob S., Dewan Y. and Joseph S. (2004). Presacral carcinoid tumour arising in a tailgut cyst: a case report. *Indian J. Pathol. Microbiol.* 47, 32-33.
- Lever L.M., Van Rooyen W. and Van Den Bergen HA. (1996). Cysts of the tailgut. *Eur. J. Surg.* 162, 149-152.
- Lin S.L., Yang A.H. and Liu H.C. (1992). Tailgut cyst with carcinoid: a case report. *Zhonghua Yi Xue Za Zhi (Taipei)*. 49, 57-60.
- Lips C.J., Lentjes E.G. and Hoppener J.W. (2003). The spectrum of carcinoid tumours and carcinoid syndromes. *Ann. Clin. Biochem.* 40, 612-27.
- Marco V., Autonell J., Farre J., Fernandez-Layos M. and Doncel F. (1982). Retrorectal cyst-hamartomas. Report of two cases with adenocarcinoma developing in one. *Am. J. Surg. Pathol.* 6, 707-714.
- Maruyama A., Murabayashi K., Hayashi M., Nakano H., Isaji S., Uehara S., Kusuda T., Miyahara S., Kondo A., Nakano H. and Yabana T. (1998). Adenocarcinoma arising in a tailgut cyst: report of a case. *Surg. Today* 28, 1319-1322.
- Moulopoulos L.A., Karvouni E., Kehagias D., Dimopoulos M.A., Gouliamos A. and Vlahos L. (1999). MR imaging of complex tail-gut cysts. *Clin. Radiol.* 54, 118-122.
- Mourra N., Caplin S., Parc R. and Flejou J.F. (2003). Presacral neuroendocrine carcinoma developed in a tailgut cyst: report of a case. *Dis. Colon Rectum.* 46, 411-413.
- Oyama K., Embi C. and Rader A.E. (2000). Aspiration cytology and core biopsy of a carcinoid tumor arising in a retrorectal cyst: a case report. *Diagn. Cytopathol.* 22, 376-378.
- Pfannschmidt J., Bottcher H., Hey A. and Graf L. (1995). Development of adenocarcinoma in a retrorectal pre-sacroccygeal hamartoma. *Chirurg.* 66, 735-738.
- Prasad A.R., Amin M.B., Randolph T.L., Lee C.S. and Ma C.K. (2000). Retrorectal cystic hamartoma: report of 5 cases with malignancy arising in 2. *Arch. Pathol. Lab. Med.* 124, 725-729.
- Schnee C.L., Hurst R.W., Curtis M.T. and Friedman E.D. (1994). Carcinoid tumor of the sacrum: case report. *Neurosurgery* 35, 1163-1167.
- Schwarz R.E., Lyda M., Lew M. and Paz I.B. (2000). A carcinoembryonic antigen-secreting adenocarcinoma arising within a retrorectal tailgut cyst: clinicopathological considerations. *Am. J. Gastroenterol.* 95, 1344-1347.
- Song D.E., Park J.K., Hur B. and Ro J.Y. (2004). Carcinoid tumor arising in a tailgut cyst of the anorectal junction with distant metastasis: a case report and review of the literature. *Arch. Pathol. Lab. Med.* 128, 578-580.
- Umar T., Mikel J.J. and Poller D.N. (2000). Carcinoma arising in a tailgut cyst diagnosed on fine needle aspiration (FNA) cytology. *Cytopathology* 11, 129-132.

Accepted May 23, 2005