

Consistent lack of CD34-positive stromal cells in the stroma of malignant breast lesions

N. Kuroda¹, Y.-L. Jin¹, T. Hamauzu¹, M. Toi¹, E. Miyazaki¹, M. Hiroi¹, T. Moriki² and H. Enzan¹

¹Department of Pathology, Program of Bioregulation and Genetics, and

²Department of Laboratory Medicine, Program of Organ System Control, Kochi Medical School, Kochi University, Kochi, Japan

Summary. To examine the distribution of CD34-positive and ASMA-positive stromal cells in various breast lesions, we performed immunohistochemical assays (using a streptavidin-biotin immunoperoxidase technique) of tissue specimens, obtained by excisional biopsy and partial or total mastectomy, from 62 patients with breast lesions. Specimens were obtained from 64 lesions as follows: fibrocystic disease (n=12), intraductal papilloma (n=4), fibroadenoma (n=17), invasive lobular carcinoma (n=6), invasive ductal carcinoma (n=20) and invasive micropapillary carcinoma (n=5). In normal breast tissue (controls), CD34-positive spindle cells were abundant in the intralobular stroma, but no ASMA-positive stromal cells were identified except myoepithelial cells. Small to large numbers of CD34-positive cells were observed in the stroma of 29 of 33 benign diseases. In all invasive carcinomas (lobular, ductal and micropapillary), no CD34-positive stromal cells were observed in the stroma. In the stroma of benign lesions, the number of ASMA-positive stromal cells was various, but the stroma of all invasive breast cancers contained ASMA-positive stromal cells. The present results indicate that disappearance of CD34-positive stromal cells consistently occurs in the stroma of invasive carcinoma of the breast, irrespective of histological type and may be associated with the presence of ASMA-positive stromal cells.

Key words: Breast cancer, Immunohistochemistry, CD34, ASMA

Introduction

CD34, a 110-kDa transmembrane cell-surface glycoprotein, has been identified as a marker of human hematopoietic cells (Van de Rijn, 1994). CD34-positive stromal cells are distributed in various normal organs including salivary gland, thyroid gland, tonsil, stomach, colon, uterus, Fallopian tube and testis (Yamazaki and Eyden, 1995, 1996a,b, 1997; Nakayama et al., 1999, 2000; Papadas et al., 2001; Barth et al., 2002a-c; Kuroda et al., 2004a-c). Several studies have been conducted to investigate the distribution of CD34-positive stromal cells in neoplasms of various organs including salivary gland, stomach, colorectal tissue, breast, pancreas and uterine cervix (Nakayama et al., 1999, 2000, 2003; Barth et al., 2002a,c; Kuroda et al., 2004a). CD34-positive stromal cells are present in the normal breast (Barth et al., 2002b). Some investigators have reported that CD34-positive stromal cells disappear in the stroma of invasive ductal carcinoma (IDC) of the breast (Barth et al., 2002b; Chauhan et al., 2002; Ramaswamy et al., 2003). However, there is uncertainty over whether disappearance of CD34-positive stromal cells is characteristic of cancer stroma in certain organs (Nakayama et al., 2003). On the other hand, it is well known that ASMA-positive stromal cells, namely myofibroblasts appear in the stroma of various breast lesions (Barth et al., 2002; Chauhan et al., 2002). In the present study, we examined the distribution of CD34-positive and ASMA-positive stromal cells in normal breast and various malignant breast lesions including invasive lobular carcinoma (ILC) and invasive micropapillary carcinoma (IMC).

Materials and Methods

Archival tissues

We examined 64 surgically resected specimens from breast lesions of 62 female patients. These specimens were obtained from the surgical pathology files of the

Departments of Pathology and Laboratory Medicine, Kochi Medical School, Kochi University, where they were deposited from 1990 to 2004. The mean age of the patients was 55.3 years (range, 13 to 97 years). The mean size of 31 malignant breast lesions was 1.84 cm (range, 0.5 to 5.0 cm). Metastasis to regional lymph node and distant metastasis were identified in three breast cancers and one breast cancer, respectively. The lesions were as follows: fibrocystic disease (n=12), intraductal papilloma (n=4), fibroadenoma (n=17), ILC (n=6), IDC (n=20) and IMC (n=5). According to WHO histological grading, one, one, five and thirteen of 20 invasive ductal carcinoma showed scores 3, 4, 5 and 6, respectively. Specimens from some of these lesions were also used in a previous study (Kuroda et al., 2005). Thirty-one normal breast tissue specimens located remotely from invasive carcinoma were used as normal controls. Specimens were embedded in paraffin and cut into sections that were stained with hematoxylin and eosin.

Immunohistochemistry

Using a streptavidin-biotin immunoperoxidase technique, 3- μ m sections of each specimen were assayed for ASMA (1:50 dilution, 1A4, Dako Cytomation, Glostrup, Denmark), high molecular weight caldesmon (h-CD) (1:50 dilution, h-CD, Dako Cytomation, CA, USA), CD34 (1:20 dilution, MY10, Becton-Dickinson, San Jose, CA, USA) and CD31 (1:20 dilution, JC/70A, Dako Cytomation, Glostrup, Denmark). Microwave and pronase treatments were performed for h-CD and CD31 assays, respectively. Vascular smooth muscle cells and endothelial cells were used as internal positive controls for immunostaining of alpha-smooth muscle actin (ASMA) and high molecular weight caldesmon (h-CD). and CD34 and CD31, respectively. We classified stromal cells positive for both ASMA and h-CD as smooth muscle cells, and ASMA-positive and h-CD-negative cells as ASMA-positive stromal cells. Additionally, stromal cells that were CD34-positive and CD31-negative were considered CD34-positive stromal cells. The assessment for the immunostaining was determined according to the percentage of positive cells as follows: -, negative (no); \pm , trivial (few); +, a small number, positive (focal), ++, a moderate number, positive (heterogenous), +++, a large number, positive (diffuse).

Results

Distribution of CD34-positive and ASMA-positive stromal cells in normal breast tissue

In normal mammary tissue, CD34-positive stromal cells were observed around glandular ducts and acini (Fig. 1) in the intralobular area. However, the number of CD34-positive stromal cells was low in the interlobular stroma. These cells had slender elongated dendrite-like processes. In contrast, no ASMA-positive stromal cells

except for myoepithelial cells were observed in the stroma of the normal breast tissue.

Distribution of CD34-positive stromal cells in various breast lesions

These immunohistochemical results are summarized in Table 1. In 29 of the 33 benign lesions, the stroma contained CD34-positive stromal cells. A small number of CD34-positive stromal cells was detected in one intraductal papilloma lesion and eight fibroadenoma lesions (Fig. 2a). The stroma of two fibrocystic disease lesions contained an intermediate number of CD34-positive stromal cells. The stroma of eleven fibrocystic disease lesions (Fig. 2b) and seven fibroadenoma lesions contained a large number of CD34-positive stromal cells. In contrast, the stroma of the remaining four benign lesions (one fibrocystic disease lesion and three

Table 1. The expression of CD34 in various breast lesions.

	~ \pm	+	++	+++
Benign lesions (n=33)				
Fibrocystic disease (n=12)	1/12	0/12	0/12	11/12
Intraductal papilloma (n=4)	3/4	1/4	0/4	0/4
Fibroadenoma (n=17)	0/17	8/17	2/17	7/17
Malignant lesions (n=31)				
Invasive lobular carcinoma (n=6)	6/6	0/6	0/6	0/6
Invasive ductal carcinoma (n=20)	20/20	0/20	0/20	0/20
Invasive micropapillary carcinoma (n=5)	5/5	0/5	0/5	0/5

-: negative; \pm : trivial; +: positive, a small number; ++: positive, a moderate number; +++, positive, a large number.

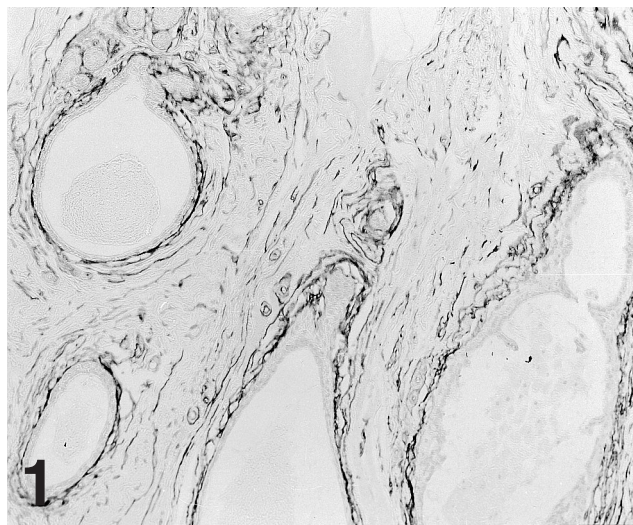


Fig. 1. The distribution of CD34-positive stromal cells in normal breast tissue. CD34-positive stromal cells are distributed around glandular ducts and acini. x 25

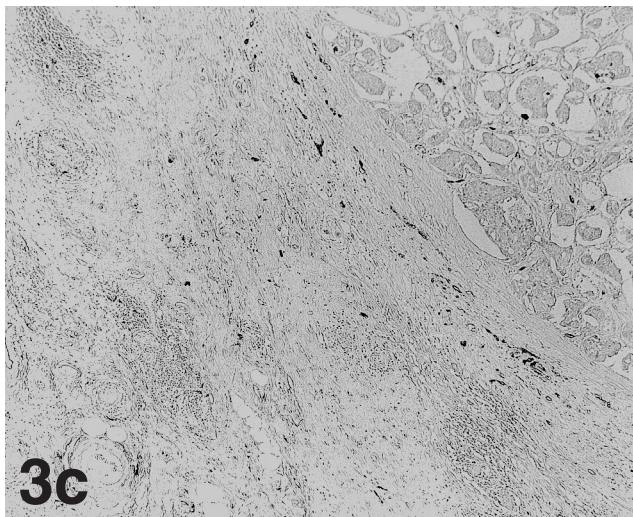
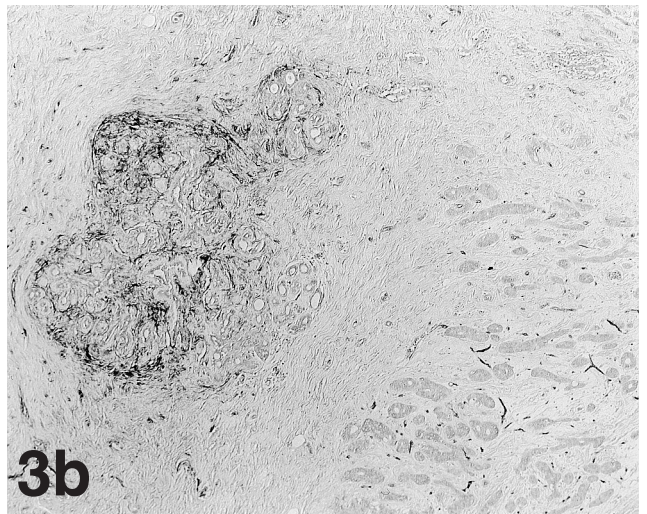
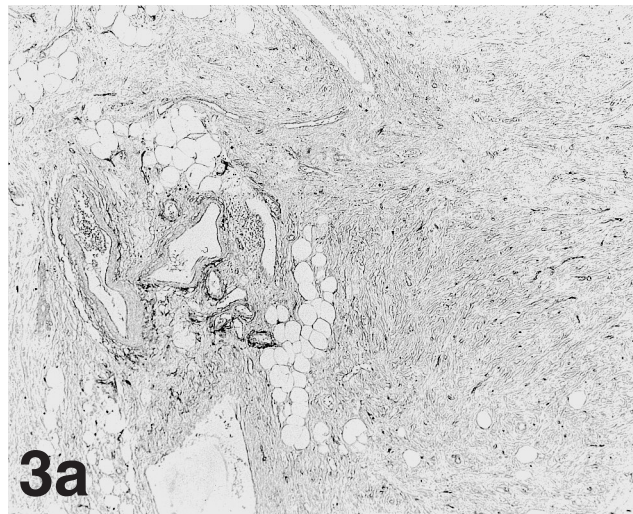
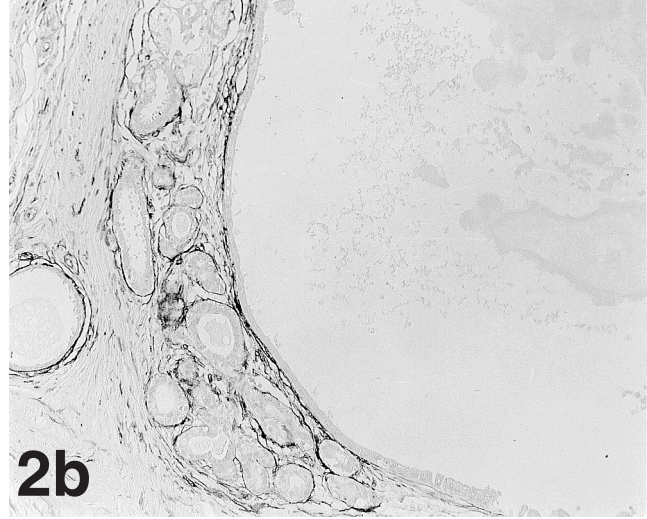
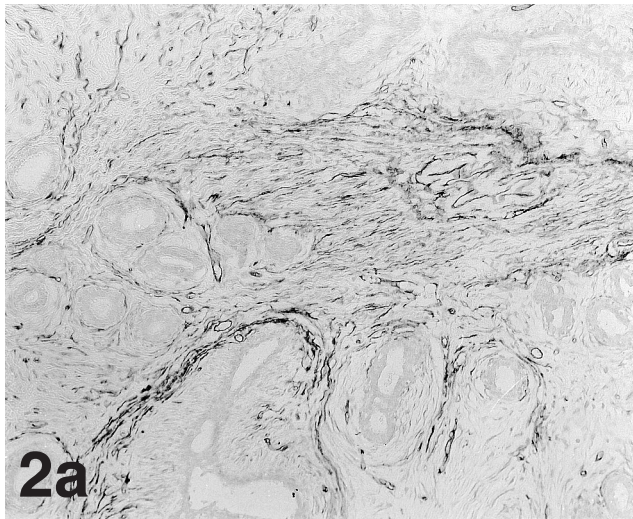


Fig. 2. Results of immunohistochemical assays of CD34 antigen in fibroadenoma (a) and fibrocystic disease (b). The stroma of these lesions contained CD34-positive stromal cells. x 25

Fig. 3. Results of immunohistochemical assays of CD34 antigen in invasive lobular carcinoma (a), invasive ductal carcinoma (b) and invasive micropapillary carcinoma (c). In all lesions, the stroma contained no CD34-positive stromal cells. The abrupt loss of CD34-positive stromal cells is observed in the intralobular interface between the cancer-free breast tissue and invasive cancers. x 10

intraductal papilloma lesions) contained no or few CD34-positive stromal cells. In all malignant lesions (ILC, Fig. 3a; IDC, Fig. 3b; IMC, Fig. 3c), the stroma contained no CD34-positive stromal cells. In the intralobular interface between all invasive breast cancers and each cancer-free tissue, the abrupt loss of CD34-positive stromal cells were observed.

Distribution of ASMA-positive stromal cells in various breast lesions

These immunohistochemical results are summarized in Table 2. In the stroma of benign lesions, the number of ASMA-positive stromal cells was various. In all intraductal papillomas, the abundant ASMA-positive

stromal cells were observed, but these cells seemed to be indistinguishable from myoepithelial cells. In contrast, the stroma of all invasive breast cancers contained ASMA-positive stromal cells. Compared with the stroma of ILC (Fig. 4a) and IDC (Fig. 4b), the stroma of IMC (Fig. 4c) generally contained the low number of ASMA-positive stromal cells. Additionally, the degree of fibrosis in the stroma seemed to have a reverse correlation with the presence of ASMA-positive stromal cells and the presence of ASMA-positive stromal cells in the invasive breast cancers seemed to be associated with the absence of CD34-positive stromal cells.

Discussion

IMCs are frequently associated with IDCs (Luna-More et al., 1994, 1996, 2000). Consequently, some investigators have suggested that micropapillary carcinoma may be a variant of ductal carcinoma. All

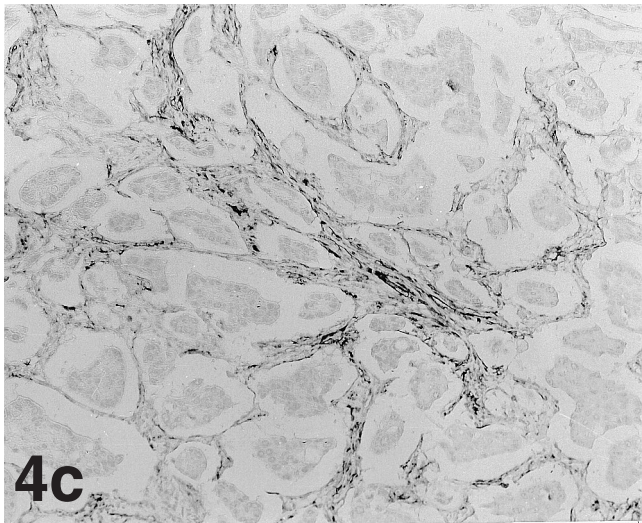
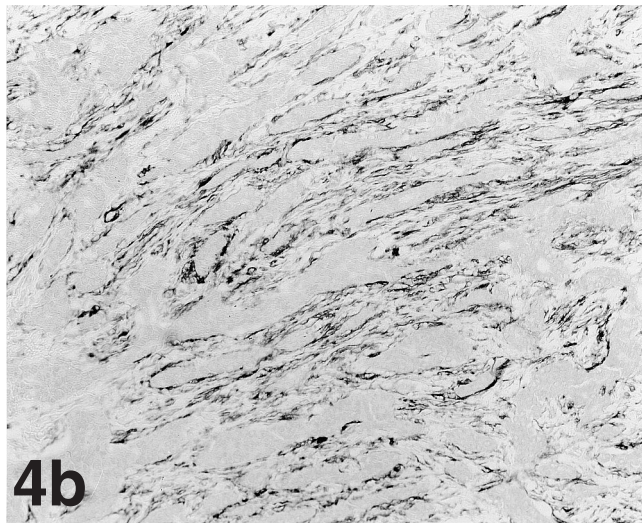
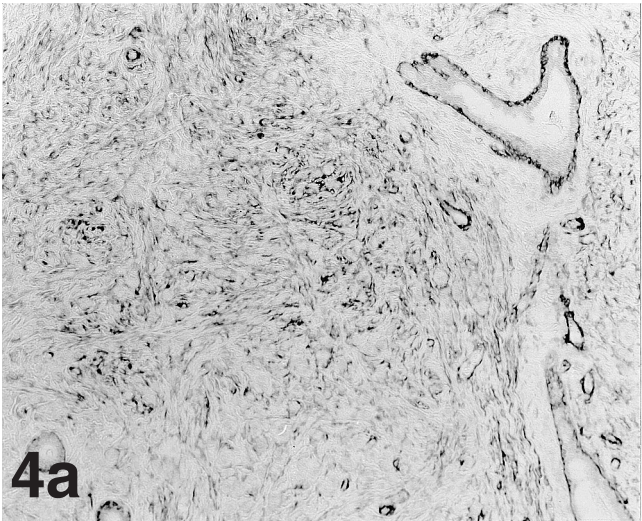


Table 2. The expression of ASMA in various breast lesions.

	~±	+	++	+++
Benign lesions (n=33)				
Fibrocystic disease (n=12)	1/12	7/12	2/12	2/12
Intraductal papilloma (n=4)	0/4	0/4	0/4	4/4
Fibroadenoma (n=17)	3/17	4/17	2/17	8/17
Malignant lesions (n=31)				
Invasive lobular carcinoma (n=6)	0/6	1/6	1/6	4/6
Invasive ductal carcinoma (n=20)	0/20	3/20	5/20	12/20
Invasive micropapillary carcinoma (n=5)	0/5	4/5	1/5	0/5

-: negative; ±: trivial; +: positive, a small number; ++: positive, a moderate number; +++, positive, a large number.

Fig. 4. Results of immunohistochemical assays of alpha-smooth muscle actin (ASMA) antigen in invasive lobular carcinoma (a), invasive ductal carcinoma (b) and invasive micropapillary carcinoma (c). Compared with the stroma of ILC and IDC, the stroma of IMC contains the low number of ASMA-positive stromal cells. x 25

CD34-positive cells in breast lesions

invasive micropapillary carcinoma lesions in the present study were associated with invasive ductal carcinoma. However, in a recent study, abnormalities of the short arm of chromosome 8 were detected in all IMC cases, and the frequency of this abnormality differed between IMC and IDC (Thor et al., 2002). That indicates that IMC is distinct from IDC, and we therefore classified IMC in a different category from IDC in the present study.

Nakayama et al. (2000) have reported that CD34-positive stromal cells are absent in the cancer stroma and peritumoral inflammatory tissue of colon cancer, but are present in normal colorectal tissue. They suggested that the lack of CD34-positive stromal cells in the stroma of colorectal carcinoma may be associated with a desmoplastic reaction. We previously reported that the lack of CD34-positive stromal cells in the stroma of pancreatic carcinoma resembled that of colorectal carcinoma (Kuroda et al., 2004a). These findings raise the possibility that the disappearance of CD34-positive stromal cells in the stroma of cancers at some anatomic sites is associated with the peculiar fibrotic process caused by the invasion of carcinoma cells. On the other hand, Nakayama et al. (2003) reported that CD34-positive stromal cells were present in some pulmonary adenocarcinoma lesions. Thus, the available evidence indicates that CD34-positive stromal cells do not disappear in the stroma of all carcinomas. Barth et al. (2002b) and Chauhan et al. (2002) have reported that CD34-positive stromal cells disappeared in the stroma of IDC of the breast, but those studies did not include cases of ILC or IMC. In a study by Chauhan et al. (2002), CD34-positive stromal cells were distributed in the stroma of all cases of lobular carcinoma in situ (LCIS). In the present study, we found that CD34-positive stromal cells disappeared in the stroma of all invasive breast carcinomas (ILC, IDC and IMC). Thus, present and previous findings suggest that disappearance of CD34-positive stromal cells consistently occurs in the stroma of invasive carcinoma of the breast, irrespective of histological type. Additionally, the presence of ASMA-positive stromal cells in invasive breast cancers seemed to be associated with the absence of CD34-positive stromal cells. Ramaswamy et al. (2003) state that the absence of CD34-positive stromal cells paralleled by the presence of ASMA-positive myofibroblasts indicate malignancy in most cases. Our results in the present study may support their hypothesis. On the other hand, we also found that CD34-positive stromal cells disappeared in the stroma of some benign lesions including fibrocystic disease and intraductal papilloma. Similarly, Ramaswamy et al. (2003) reported that CD34-positive stromal cells were absent in the center of radial scar of the breast. Thus, it appears that an immunohistochemical assay for CD34 antigen is not sufficient to distinguish between benign and malignant breast lesions. However, detection of a large number of CD34-positive stromal cells in the stroma of a breast lesion strongly suggests that the lesion is benign. Further

research is needed to clarify the role of CD34-positive stromal cells in breast lesions.

In conclusion, the present results indicate that CD34-positive stromal cells consistently disappear in the stroma of invasive carcinoma of the breast, irrespective of histological type.

Acknowledgements. We are grateful to Mr. Tadatoshi Tokaji, Ms. Hisayo Yamasaki and Ms. Kanako Yamaoka, of the Department of Pathology, Program of Bioregulation and Genetics, Kochi Medical School, for their excellent technical assistance. This work was supported by a grant for Encouragement of Young Scientists (14770074) from the Ministry of Education, Science and Culture, Japan.

References

- Barth P.J., Ebrahimsade S., Hellinger A., Moll R. and Ramswamy A. (2002a). CD34(+) fibrocytes in neoplastic and inflammatory pancreatic lesions. *Virchows Arch.* 440, 128-133.
- Barth P.J., Ebrahimsade S., Ramswamy A. and Moll R. (2002b). CD34(+) fibrocytes in invasive ductal carcinoma, ductal carcinoma in situ, and benign breast lesions. *Virchows Arch.* 440, 298-303.
- Barth P.J., Ramswamy A. and Moll R. (2002c). CD34(+) fibrocytes in normal cervical stroma, cervical intraepithelial neoplasia III, and invasive squamous cell carcinoma of the cervix uteri. *Virchows Arch.* 441, 564-568.
- Chauhan H., Abraham A., Phillips J.R.A., Pringle J.H., Walker R.A. and Lones J.L. (2002). There is more than one kind of myofibroblast: analysis of CD34 expression in benign, in situ, and invasive breast lesion. *J. Clin. Pathol.* 271-276.
- Kuroda N., Toi M., Nakayama H., Miyazaki E., Yamamoto M., Hayashi Y., Hiroi M. and Enzan H. (2004a). The distribution and role of myofibroblasts and CD34-positive stromal cells in normal pancreas and various pancreatic lesions. *Histol. Histopathol.* 19, 59-67.
- Kuroda N., Miyazaki E., Hayashi Y., Toi M., Hiroi M. and Enzan H. (2004b). The disappearance of CD34-positive and alpha-smooth muscle actin-positive stromal cells associated with human intra-uterine and tubal pregnancies. *Histol. Histopathol.* 19, 707-713.
- Kuroda N., Nakayama H., Miyazaki E., Hayashi Y., Toi M., Hiroi M. and Enzan H. (2004c). Distribution and role of CD34-positive stromal cells and myofibroblasts in human normal testicular stroma. *Histol. Histopathol.* 743-751.
- Kuroda N., Sugimoto T., Takahashi T., Moriki T., Toi M., Miyazaki E., Hiroi M. and Enzan H. (2005). Invasive micropapillary carcinoma of the breast: An immunohistochemical study of neoplastic and stromal cells. *Int. J. Surg. Pathol.* 13, 51-55.
- Luna-More S., Gonzalez B., Acedo C., Rodrigo I. and Luna C. (1994). Invasive micropapillary carcinoma of the breast. A new special type of invasive mammary carcinoma. *Pathol. Res. Pract.* 190, 668-674.
- Luna-More S., de los Santos F., Breton J.J. and Canadas M.A. (1996). Estrogen and progesterone receptors, C-ERBB-2, p53, and BCL-2 in thirty-three invasive micropapillary breast carcinomas. *Pathol. Res. Pract.* 192, 27-32.
- Luna-More S., Casquero S., Perez-Mellado A., Ruis F., Will B. and Gornemann I. (2000). Importance of estrogen receptors for the behavior of invasive micropapillary carcinoma of the breast. Review of 68 cases with follow-up of 54. *Pathol. Res. Pract.* 196, 35-39.
- Nakayama H., Naruse K., Miyazaki E., Hiroi M., Kiyoku H., Kuroda N.

- and Enzan H. (1999). The specific distribution of dendritic interstitial cells at the tumor border of major salivary gland pleomorphic adenomas. *Mod. Pathol.* 12, 445-449.
- Nakayama H., Enzan H., Miyazaki E., Kuroda N., Naruse K. and Hiroi M. (2000). Differential expression of CD34 in normal colorectal tissue, peritumoral inflammatory tissue, and tumour stroma. *J. Clin. Pathol.* 53, 626-629.
- Nakayama H., Enzan H., Yamamoto M., Miyazaki E., Hidaka C., Okumichi T., Okumichi A. and Kajihara H. (2003). CD34-positive stromal cells in primary lung carcinomas. *Oncol. Rep.* 10, 1213-1316.
- Papadas T., Batistatou A., Ravazoula P., Zolota V. and Goumas P. (2001). S-100 protein-positive dendritic cells and CD34-positive dendritic interstitial cells in palatine tonsils. *Eur. Arch. Otorhinolaryngol.* 258, 243-245.
- Ramaswamy A., Moll R. and Barth P. (2003). CD34+ fibrocytes in tubular carcinomas and radial scars of the breast. *Virchows Arch.* 443, 536-540.
- Thor A.D., Eng C., Devries S., Paterakos M., Watkin W.G., Edgerton S., Moore II.D.H., Etzell J. and Waldman F.M. (2002). Invasive micropapillary carcinoma of the breast is associated with chromosome 8 abnormalities detected by comparative genomic hybridization. *Hum. Pathol.* 33, 628-631.
- Van de Rijn M. and Rouse R.V. (1994). CD34. A review. *Appl. Immunohistochem.* 2, 71-80.
- Yamazaki K. and Eyden B.P. (1995). Ultrastructural and immunohistochemical observations on intralobular fibroblasts of human breast, with observations on the CD34 antigen. *J. Submicrosc. Cytol. Pathol.* 27, 309-323.
- Yamazaki K. and Eyden B.P. (1996a). Ultrastructural and immunohistochemical studies of stromal cells in lamina propria of human fallopian tube ampullar mucosa: the recognition of "CD34 positive reticular network" and its putative function for immune surveillance. *J. Submicrosc. Cytol. Pathol.* 28, 325-337.
- Yamazaki K. and Eyden B.P. (1996b). Ultrastructural and immunohistochemical studies of intralobular fibroblasts in human submandibular gland: the recognition of "CD34 positive reticular network" connected by a gap junction. *J. Submicrosc. Cytol. Pathol.* 28, 471-483.
- Yamazaki K. and Eyden B.P. (1997). Interfollicular fibroblasts in the human thyroid gland: recognition of a CD34 positive stromal cell network communicated by gap junctions and terminated by autonomic nerve endings. *J. Submicrosc. Cytol. Pathol.* 29, 461-476.

Accepted January 28, 2005