

## **p63 expression in benign and malignant breast lesions**

**D. Stefanou, A. Batistatou, A. Nonni, E. Arkoumani and N.J. Agnantis**

Department of Pathology, University of Ioannina Medical School, Ioannina, Greece

**Summary.** The p63 gene encodes six protein isoforms. The transactivating isoforms have similar actions with p53, while the N-isoforms inhibit transcription activation by p53 and transactivating isoforms. p63 is expressed in stratified epithelia and in basal cells of the prostate and salivary glands. In mammary epithelium p63 has been shown to be expressed only in the myoepithelial layer. In the present study we investigated the immunohistochemical expression of p63, in benign and malignant breast lesions, and compared it with known myoepithelial cell markers. Our material consisted of 140 benign and 126 malignant breast lesions. We used the antibodies anti-p63, anti- $\alpha$ -smooth muscle actin, anti-S-100 protein and anti-cytokeratin 14. In all benign lesions, p63 immunoreactivity was noted in the myoepithelial cell layer surrounding the luminal epithelial cells. A less continuous peripheral rim of myoepithelial cells was also highlighted with p63-staining in all situ carcinomas. All invasive breast carcinomas were devoided of peripheral p63 staining. Interestingly, strong nuclear p63 immunoreactivity was noted in a small fraction (5-15%) of epithelial cells in all cases of papillomatosis, in 62.5% of in situ ductal papillary-type carcinomas and in 33.3% of invasive papillary carcinomas. Comparable staining was observed with S-100. The stromal cells were unreactive to p63. Our findings suggest that p63 is a sensitive and specific myoepithelial marker, and may be included in immunohistochemical panels aiming to identify myoepithelial cells in problematic breast lesions. Regarding papillary neoplasms, it is possible that tumor cells acquire and exhibit at least in part a myoepithelial differentiation program.

**Key words:** p63, Breast, Myoepithelial, Papilloma

### **Introduction**

p63 and p73 are two genes coding for proteins homologous to p53 (Yang et al., 2002). p63 gene is located on 3q27 and in contrast to p53 is expressed in numerous splice variants making the analysis of its properties difficult (Little and Jochemsen, 2002). It has been shown that the p63 gene encodes six isoforms which differ in the C-terminal ( $\alpha$ ,  $\beta$ ,  $\gamma$ ) and in the N-terminal (transactivating and  $\Delta$ N-isoforms, respectively). The transactivating isoforms contain the transcription activation domain and are similar to p53, since they can activate transcription of specific genes and induce cell cycle arrest and apoptosis (Flores et al., 2002; Urist and Prives, 2002). The  $\Delta$ N-isoforms are not able to promote transcription of p53 reporting genes, and act in a dominant negative manner, inhibiting transcription activation by p53 and transactivating isoforms (Dietz et al., 2002; Flores et al., 2002; Urist and Prives, 2002). Valuable information has been provided by p63 knockout mice, which interestingly do not develop tumors. In fact, p63 negative mice die soon after birth and lack limbs, epidermis, prostate, breast and urothelial tissues, due to loss of stem cells required for their development (Van Bokhoven and McKeon, 2002).

p63 is expressed in epithelial cells of stratified epithelia (such as skin, esophagus, ectocervix, bladder) and in basal cells of the glandular structures of the prostate and salivary glands, as well as in bronchi (Di Como et al., 2002). In normal breast, where the ducts and tubuloalveolar structures are lined by two distinct cell types, the inner epithelial (luminal) and the outer myoepithelial cells, p63 has been shown to be expressed only to the myoepithelial layer. Strong and consistent expression of  $\Delta$ N-isoforms is detected in breast myoepithelial/basal cells (Barbareschi et al., 2001; Reis-Filho and Schmitt, 2002, 2003; Reis-Filho et al., 2002, 2003a,b; Wang et al., 2002; Werling et al., 2003). It has been speculated that this expression might be an alternative mechanism to overcome p53-driven apoptosis (Dietz et al., 2002). p63 expression in breast neoplasms is not completely characterized (Barbareschi et al., 2001; Wang et al., 2002).

In every day Pathology practice the identification of myoepithelial cells in breast lesions is of great diagnostic value, for discrimination between invasive carcinomas and noninvasive lesions, the latter including carcinoma in situ and benign breast diseases (Gusterson et al., 1982). For this purpose several immunohistochemical markers for myoepithelial cells are being used. These include basal cytokeratins, smooth muscle actin, muscle specific actin, smooth muscle myosin heavy chain, calponin, and S-100 protein (Heatley et al., 1995; Joshi et al., 1996; Yaziji et al., 2000). However, these markers have a wide range of specificity and sensitivity, and potential errors in interpretation.

In the present study we investigated the immunohistochemical expression and distribution pattern of p63, in benign and malignant breast lesions, and compared it with known myoepithelial cell markers.

### **Materials and methods**

Our material consisted of 266 formalin-fixed, paraffin-embedded archival breast samples, and included 140 benign and 126 malignant breast lesions. The benign lesions consisted of 20 papillomas, 10 fibroadenomas, 1 ductal adenoma, 2 adenomas of the nipple, 1 juvenile papillomatosis, 11 radial scars, 1 complex sclerosing lesion and 94 fibrocystic disease/changes (cysts, blind duct adenosis, ductal hyperplasia, atypical lobular hyperplasia, papillomatosis). The malignant lesions consisted of 30 in situ ductal carcinomas (comedo, solid, cribriform, papillary, micropapillary, clinging) and 62 invasive ductal carcinomas, NST (Not Specific Type) and 34 invasive carcinomas of other histotypes (3 tubular, 4 mucinous, 27 papillary).

### *Immunohistochemistry*

We used the EnVision System and the monoclonal antibodies anti-p63 (Biocare Medical, dilution 1:30), anti- $\alpha$ -smooth muscle actin (Biogenex, ready-to-use), anti-S-100 protein (Biogenex, ready-to-use) and anti-cytokeratin 14 (Biogenex, dilution 1:20). Briefly 5  $\mu$ m-thick, histological sections were dewaxed in xylene, rehydrated through graded alcohols, immersed in 10mM Tris and 0.5 M EDTA, pH 9.0, and microwaved twice for 5 minutes each time. Subsequently, the sections were incubated with 0.3% H<sub>2</sub>O<sub>2</sub> for 30 minutes to block endogenous peroxidase activity. The sections were then incubated overnight at 4 °C with the primary antibodies. Non specific binding was blocked by incubating the sections for 30 min with Blocking Solution (DAKO). Detection was carried out using the EnVision System kit (DAKO) with diaminobenzidine as chromogen. Counterstaining was performed with hematoxylin Harris.

To co-localize p63 and myoepithelial cell markers consecutive serial sections, from each sample were utilized. Normal squamous epithelium was used as a positive control. For negative controls the primary antibody was omitted.

### **Results**

#### *p63 immunoreactivity in benign breast lesions*

In all cases, p63 expression was nuclear. In normal breast tissue present in the examined sections, consistent, intense staining of nuclei of normal myoepithelial cells of breast lobules and ducts was noted. These cells also exhibited cytoplasmic immunoreactivity for S-100 protein and  $\alpha$ -smooth actin, and membranous immunoreactivity for Ck14. Although all cells with location and morphology of myoepithelial cells stained with anti-p63, occasionally (less than 1%) they did not stain for the other markers.

In all benign lesions, p63 immunoreactivity was noted in the myoepithelial cell layer surrounding the epithelial structures (Fig. 1A). Staining intensity was comparable to that of normal breast tissue. Scattered, weakly p63-positive epithelial cells (<5%) were found in almost half of the ductal hyperplasia cases (22/48, 45%). Similar luminal epithelial staining was noted with Ck14. A higher percentage of luminal epithelial cells (approximately 10-15%) stained positive with S-100.

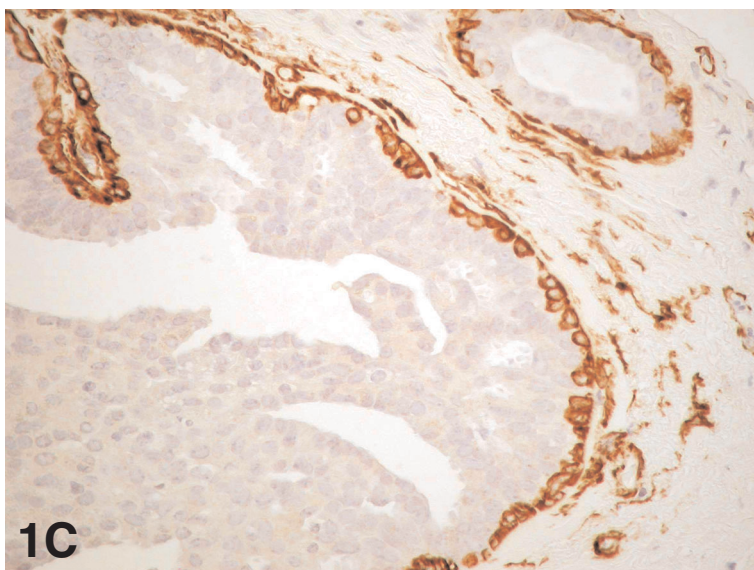
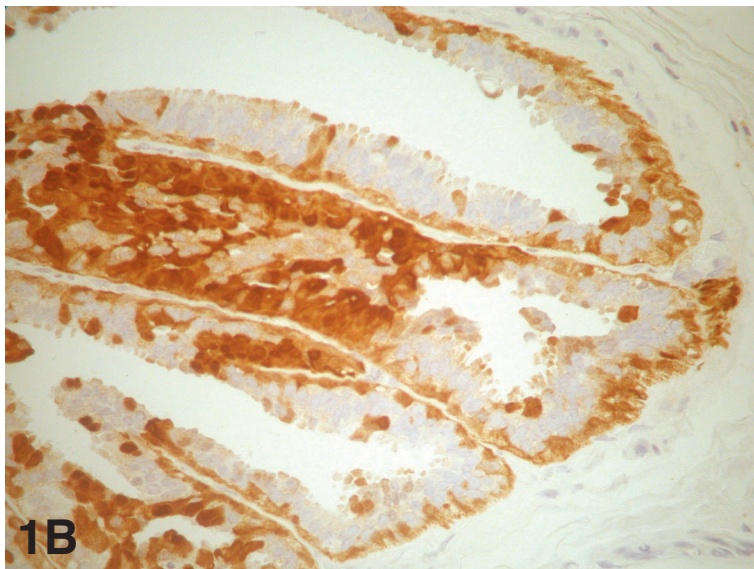
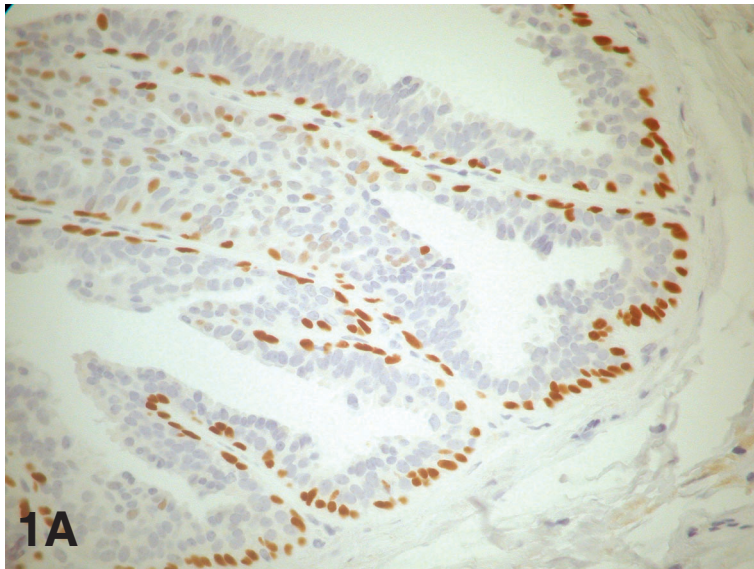
Interestingly, in all cases with papillomatosis there was strong p63- and S100-immunostaining in 5-10% and in 20-30% of luminal epithelial cells respectively (Fig. 1A,B). Weak staining was noted in <5% of epithelial cells with the antibody Ck14, while no epithelial staining was observed with anti- $\alpha$ -smooth actin (Fig. 1C).

#### *p63 immunoreactivity in malignant breast lesions*

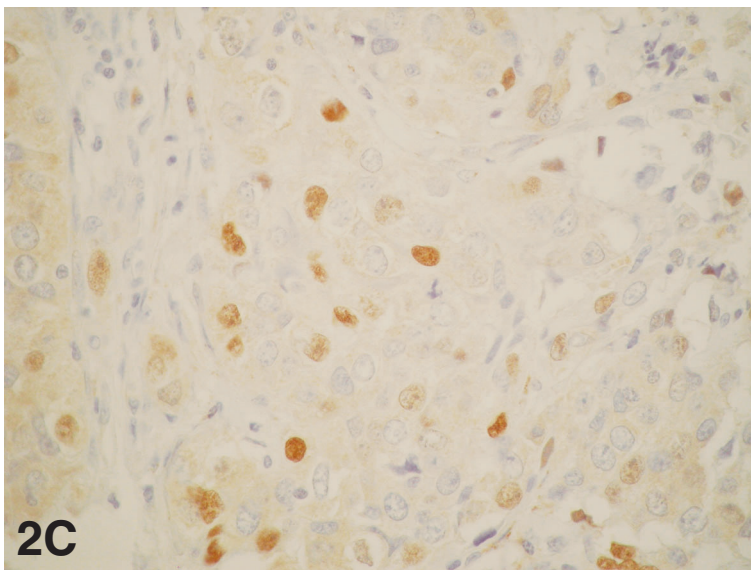
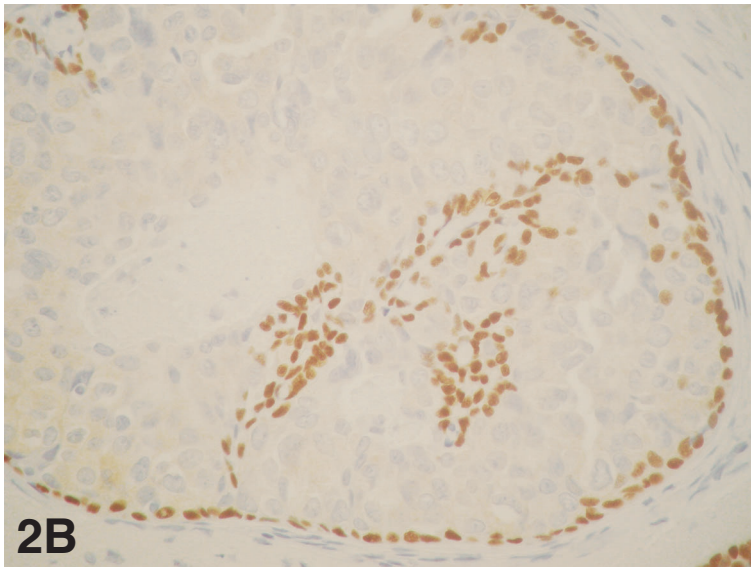
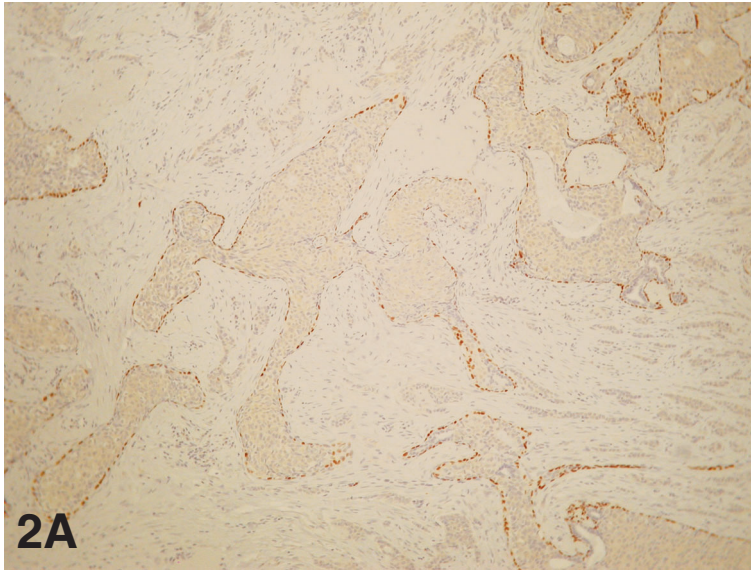
A peripheral rim of myoepithelial cells was also highlighted with p63-staining in all in situ carcinomas. Although the staining intensity was similar to that of non-neoplastic tissues, there was a less continuous peripheral rim of cells, as compared with normal structures (Fig. 2A). The p63-negative basally located cells were negative for the other myoepithelial cell markers as well.

Regarding epithelial cells, strong nuclear p63 immunoreactivity was noted in a minor fraction of neoplastic cells (10-15%) in 62.5% (15/24) of in situ ductal carcinomas papillary-type (Fig. 2B). Comparable staining was observed with S-100. All neoplastic cells in ductal carcinomas in situ, of non-papillary type, were negative for p63 and  $\alpha$ -smooth muscle actin, while a small fraction (less than 5%) was positive for S-100 and CK14.

All invasive breast carcinomas were devoid of p63 staining. A small fraction of p63-positive neoplastic cells (10-15%) was noted in 33.3% (9/27) of invasive papillary carcinomas (Fig. 2C). Comparable staining was observed with S-100. Positive neoplastic cell staining was found in 20% of invasive ductal carcinomas, NST, with S-100 (strong, cytoplasmic) and cytokeratin 14 (weak, membranous). The positive immunostaining was confined to the stromal-epithelial junction of the infiltrating tumor cells.



**Fig. 1.** Myoepithelial marker expression in a case of papillomatosis. **A.** Strong p63 immunoreactivity in the peripheral rim of myoepithelial cells. Positive staining of scattered luminal epithelial cells as well. x 400. **B.** Myoepithelial and epithelial cell immunostaining with S-100. x 400. **C.**  $\alpha$ -smooth actin-immunoreactivity of myoepithelial cells and stromal myofibroblasts. x 400



**Fig. 2.** p63 expression in breast carcinomas. **A.** Strong, focally discontinuous, p63 immunoreactivity in the peripheral rim of myoepithelial cells in DCIS. Invasive ductal carcinoma is completely devoid of nuclear p63 staining. x 100. **B.** p63 positive peripheral myoepithelial and luminal epithelial cells in a case of in situ papillary carcinoma. x 400. **C.** Scattered p63 positive neoplastic epithelial cells in a case of invasive papillary carcinoma. x 400

The stromal cells were unreactive to p63, whereas many myofibroblasts of the stroma were positive to smooth muscle actin (Fig. 1C).

## **Discussion**

The mammary myoepithelial cells have attracted much attention in recent years (Deugnier et al., 2002). In ducts myoepithelial cells are elongated and form a continuous layer between the luminal epithelial layer and the basement membrane, while in lobules they are stellate and form a basket-like structure around the acini. Differentiated myoepithelial cells are contractile and contain microfilaments and smooth-muscle specific cytoskeletal and contractile proteins. In addition, being epithelial cells, they express cytokeratins 5 and 14. The important role of myoepithelial cells in milk ejection during lactation is well established. However their potential role in mammary development and tumorigenesis has been speculative, but not fully elucidated (Lakhani et al., 1999; Petersen et al., 2001). In hyperplasias the myoepithelia are admixed with the epithelial proliferation and play an active role in this process, because we know that both cell types that normally populate the ductal and lobular walls, proliferate. The in situ carcinomas are neoplasms, and this fact implies a monoclonal expansion of one cell population, which results in a very monomorphic histologic appearance. One of the reasons for this monomorphic appearance is that the myoepithelial cells are excluded from the neoplastic process (Agnantidis and Ioannidou-Mouzaka, 1997).

The precise location and molecular characteristics of myoepithelial precursor cells are still not clear. Several data suggest the presence of a bipotent mammary progenitor cell, that can give rise to both luminal and myoepithelial cells (Lakhani et al., 1999; Petersen et al., 2001; Deugnier et al., 2002; DiRenzo et al., 2002). In addition Petersen and colleagues have suggested that luminal cells can give rise to myoepithelial and luminal cells (Pechoux et al., 1999; Gudjonsson et al., 2002a,b).

The identification of a peripheral rim of myoepithelial cells is a valuable information in the differential diagnosis of breast lesions, particularly in the limited material of core biopsies (Gusterson et al., 1982). Myoepithelial cells can be appreciated with standard hematoxylin-eosin stains, but the immunohistochemical detection of myoepithelial markers remains an optimal, widely used approach to distinguish between invasive and non-invasive tumors. The available markers though (basal cytokeratins, smooth muscle actin, muscle specific actin, smooth muscle myosin heavy chain, calponin, and S-100 protein) have a wide range of specificity and sensitivity (Heatley et al., 1995; Joshi et al., 1996; Yaziji et al., 2000). For example S-100 protein is poorly specific and sensitive for myoepithelial cells, whereas other markers with increased sensitivity, such as actins and calponin, stain stromal myofibroblasts as well, leading to potential errors in interpretation.

Recent studies have demonstrated that mammary myoepithelial cells express the nuclear protein p63, a member of the p53-gene family (Barbareschi et al., 2001; Reis-Filho and Schmitt, 2002, 2003; Reis-Filho et al., 2002, 2003a,b; Ribeiro-Silva et al., 2003a,b; Wang et al., 2002; Werling et al., 2003). However, the possible usefulness of p63 in immunohistochemical distinction of invasive from noninvasive breast lesions, is not clear. Thus, Barbareschi et al. using double immunohistochemical methods has shown that p63 is a selective nuclear marker of myoepithelial cells (Barbareschi et al., 2001). p63-positive myoepithelial cells were noted surrounding benign epithelial lesions, and forming a consistent but discontinuous rim around epithelial cells of in situ carcinomas. Comparable results were reported by Werling et al. (2003). However, Wang et al. (2002), showed that p63 was expressed in myoepithelial cells of normal breast, partially expressed in ductal hyperplasia, rarely expressed in carcinoma in situ and not expressed in invasive carcinomas.

From our results, it appears that there is a definite difference in p63-staining between benign lesions and in situ carcinomas on one hand and invasive carcinomas on the other. Our results are in accordance with earlier reports by Gusterson et al. (1982), who reported the distribution not only of myoepithelial cells but also of basement membrane proteins in benign and malignant breast lesions. p63-immunostaining can be of great value for distinguishing between these lesions. p63-immunostaining, being intense nuclear, is superior to the often weak and vague cytoplasmic staining with other myoepithelial markers, making interpretation easier. Moreover, it appears that p63 is a more sensitive and specific myoepithelial marker than those currently used, with no staining of secretory cells, stromal myofibroblasts, smooth muscle cells or pericytes.

Therefore, p63 seems to be a sensitive and highly specific myoepithelial marker, and may be included in immunohistochemical panels aiming to identify myoepithelial cells in problematic breast lesions.

In recent years the hypothesis that neoplastic breast cells have different differentiation pathways available in response to tumor microenvironment has gained acceptance (Petersen et al., 2001). If this is the case then intra-tumor and inter-tumor heterogeneity of breast neoplasms might not be just the result of the genetic instability of malignant neoplasms but could be due to the following of a distinct differentiation pathway (i.e. reversion to the progenitor cell phenotype). Several studies have shown that although the expression of a complete myoepithelial differentiation program is extremely rare in breast cancer, the expression of single myoepithelial markers is not unusual. Both cytokeratins 14 and 17 as well as vimentin have been detected in 20-33% of invasive breast carcinomas (Lakhani et al., 1999; Deugnier et al., 2002).

An intriguing find in our study was the strong p63-immunostaining of a fraction of epithelial cells (5-15%) in lesions with papillary morphology. Specifically, such

positive staining was noted in all papillomatosis cases, in 62.5% of in situ papillary-type ductal carcinomas and in 33.3% of invasive papillary carcinomas. Comparable staining was observed with the marker S100. Based on these observations we speculate that in papillary neoplasms the tumor cells acquire and exhibit at least in part a myoepithelial differentiation program. The implications of this partial conversion to a myoepithelial phenotype are not known. Interestingly though, in vitro studies have shown that all myoepithelial-specific proteins (e.g. maspin,  $\alpha 6$ -integrin, cytokeratin 5,  $\alpha$ -smooth muscle actin) have tumor suppressor activity (Lakhani et al., 1999; Deugnier et al., 2002). Current studies in our laboratory (Bai et al., 2001) address the issue of the differentiation program that characterizes the whole spectrum of papillary lesions (papillomas, in situ ductal carcinomas papillary-type, invasive papillary carcinomas).

In conclusion, our findings suggest that p63 is a sensitive and specific myoepithelial marker, and may be included in immunohistochemical panels aiming to identify myoepithelial cells in problematic breast lesions. Regarding papillary neoplasms, it is possible that tumor cells acquire and exhibit at least in part a myoepithelial differentiation program.

---

*Acknowledgements.* We thank Mrs A. Christodoulou and Mr M. Alexiou for expert technical assistance.

---

## References

- Agnantis N.J. and Ioannidou-Mouzaka L. (1997). Histopathological diagnosis of D.C.I.S. breast cancer. In: Proceedings of the 10th international meeting of gynaecological oncology. De Oliveira C.F. and Oliveira H.M. (eds). Monduzzi Editore SpA, Bologna, Italy. pp 335-338.
- Bai M., Agnantis N.J., Kamina S., Demou A., Zagorianakou P., Katsaraki A. and Kanavaros P. (2001). In vivo cell kinetics in breast carcinogenesis. *Breast Cancer Res.* 3, 276-283.
- Barbareschi M., Pecciarini L., Cangi M.G., Macri E., Rizzo A., Viale G. and Doglioni C. (2001). p63, a p53 homologue, is a selective nuclear marker of myoepithelial cells of the human breast. *Am. J. Surg. Pathol.* 25, 1054-1060.
- Deugnier M.A., Teuliere J., Faraldo M.M., Thiery J.P. and Glukhova M.A. (2002). The importance of being a myoepithelial cell. *Breast Cancer Res.* 4, 224-230.
- Di Como C.J., Urist M.J., Babayan I., Drobnyak M., Hedvat C.V., Teruya-Feldstein J., Pohar K., Hoos A. and Cordon-Cardo C. (2002). p63 expression profile in human normal and tumor tissues. *Clin. Cancer Res.* 18, 494-501.
- Dietz S., Rother K., Bamberger C., Schmale H., Mossner J. and Engeland K. (2002). Differential regulation of transcription and induction of programmed cell death by human p53-family members p63 and p73. *FEBS Lett.* 525, 93-99.
- DiRenzo J., Signoretti S., Nakamura N., Rivera-Gonzalez R., Sellers W., Loda M. and Brown M. (2002). Growth factor requirements and basal phenotype of an immortalized mammary epithelial cell line. *Cancer Res.* 62, 89-98.
- Flores E.R., Tsai K.Y., Crowley D., Sengupta S., Yang A., McKeon F. and Jacks T. (2002). p63 and p73 are required for p53-dependent apoptosis in response to DNA damage. *Nature* 416, 560-564.
- Gudjonsson T., Ronnov-Jessen L., Villadsen R., Rank F., Bissell M.J. and Petersen O.W. (2002a). Normal and tumor-derived myoepithelial cells differ in their ability to interact with luminal breast epithelial cells for polarity and basement membrane deposition. *J. Cell Sci.* 115, 39-50.
- Gudjonsson T., Villadsen R., Nielsen H.L., Ronnov-Jessen L., Bissell M.J. and Petersen O.W. (2002b). Isolation, immortalization, and characterization of a human breast epithelial cell line with stem cell properties. *Genes Dev.* 16, 693-706.
- Gusterson B.A., Warburton M.J., Mitchell D., Ellison M., Neville A.M. and Rusland P.S. (1982). Distribution of myoepithelial cells and basement membrane proteins in the normal breast and in benign and malignant breast diseases. *Cancer Res.* 42, 4763-4770.
- Heatley M., Maxwell P., Whiteside C. and Toner P. (1995). Cytokeratin intermediate filament expression in benign and malignant breast disease. *J. Clin. Pathol.* 48, 26-32.
- Joshi M.G., Lee A.K., Pedersen C.A., Schnitt S., Camus M.G. and Hughes K.S. (1996). The role of immunohistochemical markers in the differential diagnosis of proliferative and neoplastic lesions of the breast. *Mod. Pathol.* 9, 57-62.
- Lakhani S.R., Chaggar R., Davies S., Jones C., Collins N., Odel C., Stratton M.R. and O'Hare M.J. (1999). Genetic alterations in "normal" luminal and myoepithelial cells. *J. Pathol.* 189, 496-503.
- Little N.A. and Jochemsen A.G. (2002). p63. *Int. J. Biochem. Cell Biol.* 34, 6-9.
- Pechoux C., Gudjonsson T., Ronnov-Jessen L., Bissell M.J. and Petersen O.W. (1999). Human mammary luminal epithelial cells contain progenitors to myoepithelial cells. *Dev. Biol.* 206, 88-99.
- Petersen O.W., Nielsen H.L., Gudjonsson T., Villadsen R., Ronnov-Jessen L. and Bissell M.J. (2001). The plasticity of human breast carcinoma cells is more than epithelial to mesenchymal conversion. *Breast Cancer Res.* 3, 213-217.
- Reis-Filho J.S. and Schmitt F.C. (2002). Taking advantage of basic research: p63 is a reliable myoepithelial and stem cell marker. *Anat. Pathol.* 9, 280-289.
- Reis-Filho J.S. and Schmitt F.C. (2003). p63 expression in sarcomatoid/metaplastic carcinomas of the breast. *Histopathology.* 42, 94-95.
- Reis-Filho J.S., Milanezi F., Amendeira I., Albergaria A. and Schmitt F.C. (2002). p63 staining of myoepithelial cells in breast fine needle aspirates: a study of its role in differentiating in situ from invasive ductal carcinomas of the breast. *J. Clin. Pathol.* 55, 936-939.
- Reis-Filho J.S., Milanezi F., Amendeira I., Albergaria A. and Schmitt F.C. (2003a). Distribution of p63, a novel myoepithelial marker, in fine-needle aspiration biopsies of the breast: an analysis of 82 samples. *Cancer* 99, 172-179.
- Reis-Filho J.S., Milanezi F., Paredes J., Silva P., Pereira E.M., Maeda S.A., de Carvalho L.V. and Schmitt F.C. (2003b). Novel and classic myoepithelial/stem cell markers in metaplastic carcinomas of the breast. *Appl. Immunohistochem. Mol. Morphol.* 11, 1-8.
- Ribeiro-Silva A., Zambelli Ramalho L.N., Britto Garcia S. and Zucoloto S. (2003a). The relationship between p63 and p53 expression in normal and neoplastic breast tissue. *Arch. Pathol. Lab. Med.* 127, 336-340.
- Ribeiro-Silva A., Zambelli Ramalho L.N., Britto Garcia S. and Zucoloto S. (2003b). Is p63 reliable in detecting microinvasion in ductal

*p63 expression in breast lesions*

- carcinoma in situ of the breast? *Pathol. Oncol. Res.* 9, 20-23.
- Urist M. and Prives C. (2002). p53 leans on its siblings. *Cancer Cell.* 1, 311-313.
- Van Bokhoven H. and McKeon F. (2002). Mutations on the p53 homolog p63: allele-specific developmental syndromes in humans. *Trends Mol. Med.* 8, 133-139.
- Wang X., Mori I., Tang W., Nakamura M., Sato M., Saku K. and Kakudo K. (2002). p63 expression in normal, hyperplastic and malignant breast tissues. *Breast Cancer* 9, 216-219.
- Werling R.W., Hwang H., Yaziji H. and Gown A.M. (2003). Immunohistochemical distinction of invasive from noninvasive breast lesions: a comparative study of p63 versus calponin and smooth muscle myosin heavy chain. *Am. J. Surg. Pathol.* 27, 82-90.
- Yang A., Kaghad M., Caput D. and McKeon F. (2002). On the shoulders of giants: p63, p73 and the rise of p53. *Trends Genet.* 18, 90-95.
- Yaziji H., Gown A.M. and Sneige N. (2000). Detection of stromal invasion in breast cancer: the myoepithelial markers. *Adv. Anat. Pathol.* 7, 100-109.

Accepted December 9, 2003