

Therapeutic trials for a rabbit model of EBV-associated Hemophagocytic Syndrome (HPS): Effects of vidarabine or CHOP, and development of *Herpesvirus papio* (HVP)-negative lymphomas surrounded by HVP-infected lymphoproliferative disease

K. Hayashi¹, H. Joko¹, T.R. Koirala¹, S. Onoda¹, Z-S. Jin¹, M. Munemasa¹, N. Ohara¹, W. Oda¹, T. Tanaka¹, T. Oka¹, E. Kondo¹, T. Yoshino¹, K. Takahashi³, M. Yamada² and T. Akagi¹

¹Department of Pathology, ²Department of Virology, Okayama University Graduate School of Medicine and Dentistry, Okayama and

³School of Health Science, Okayama University, Okayama, Japan

Summary. Epstein-Barr virus-associated hemophagocytic syndrome (EBV-AHS), which is often associated with fatal infectious mononucleosis or T-cell lymphoproliferative diseases (LPD), is a distinct disease characterized by high mortality. Treatment of patients with EBV-AHS has proved challenging. To develop some therapeutic interventions for EBV-AHS, we examined the effectiveness of an antiviral agent (vidarabine) or chemotherapy (CHOP), using a rabbit model for EBV-AHS.

Fourteen untreated rabbits were inoculated intravenously with cell-free virions of the EBV-like virus *Herpesvirus papio* (HVP). All of the rabbits died of HVP-associated (LPD) and hemophagocytic syndrome (HPS) between 21 and 31 days after inoculation. Furthermore, three HVP-infected rabbits treated with vidarabine died between days 23 and 28 after inoculation, and their clinicopathological features were no different from those of untreated rabbits, indicating that this drug is not effective at all to treat HVP-induced rabbit LPD and HPS.

Three of the infected rabbits that were treated with one course, with an incomplete set of three courses, or with three full courses of CHOP treatment died of HVP-induced LPD and HPS with a bleeding tendency and/or with opportunistic infections. They died on the 26th, 62nd and 105th day after virus inoculation, respectively. CHOP treatment transiently suppressed the HVP-induced LPD and contributed to the prolonged survival time of two infected rabbits. However, it did not remove all of the HVP-infected cells from the infected rabbits, and residual HVP-infected lymphocytes caused recurrences of rabbit LPD and HPS. The most

interesting finding of this experiment was observed in the infected rabbit with the longest survival time of 105 days: HVP-negative lymphomas surrounded by HVP-induced LPD developed in the larynx and ileum of this rabbit, causing an obstruction of the lumen. We concluded that these were not secondary lymphomas caused by CHOP treatment, because no suspicious lesions were detected in three uninfected rabbits that were treated with three courses of CHOP for 120 days. It is therefore necessary to clarify the mechanism by which HVP-negative lymphomas associated with HVP-induced LPD can develop.

Our data from therapeutic trials using EBV-AHS animal models indicate that vidarabine is not effective as an agent to treat HVP-infected rabbits, and even the cytotoxic chemotherapy of CHOP is not sufficient to cure the HVP-infected rabbits or to prolong the survival time of infected rabbits. Further studies will therefore be required to develop better therapies to treat EBV-AHS.

Key words: EBV, HS, HVP, LPD, Lymphoma, Vidarabine, Chop

Introduction

Epstein-Barr virus (EBV) is one of the human herpesviruses and is a member of the gamma herpesvirus family (lymphocryptovirus). EBV was the first tumor virus identified from cultured lymphoblasts of Burkitt's lymphoma (Epstein et al., 1964), and its potential role as a causative agent of EBV-associated tumors has been an important subject of investigation for approximately 40 years. EBV is widely dispersed in the human population. Most adults who remain asymptomatic are infected persistently and have antibodies to the virus. EBV has been classically associated with infectious mononucleosis (IM), Burkitt's lymphoma in equatorial

Offprint requests to: Kazuhiko Hayashi, M.D., Department of Pathology, Okayama University Graduate School of Medicine and Dentistry, 2-5-1 Shikata-cho, Okayama-city 700-8558, Japan. e-mail: kazuhaya@md.okayama-u.ac.jp

Africa and nasopharyngeal carcinoma (Rickinson and Kieff, 2001). The range of EBV-associated diseases has recently expanded to include oral hairy leukoplakia and leiomyosarcoma from AIDS patients, Hodgkin's lymphoma, some settings of B-cell or T-cell lymphoma, Ki-1 lymphoma, lymphoproliferative diseases (LPD) of primary and secondary immunodeficiency, lympho-epithelioma-like carcinoma of the stomach, thymus, lung and salivary gland (Weiss et al., 1989; Chang et al., 1992; Anagnostopoulos and Hummel, 1996; Weiss and Chang, 1996; Kawa, 2000; Rickinson and Kieff, 2001), and EBV-associated hemophagocytic syndrome (EBV-AHS) (Favara, 1992; Su et al., 1993, 1994, 1995; Kikuta et al., 1993, 1995; Okano and Gross, 1996; Chen et al., 1997; Imashuku et al., 1999a,b, 2002).

Hemophagocytic syndrome (HPS), or hemophagocytic lymphohistiocytosis (HLH), is an unusual syndrome characterized by common clinicopathological features such as fever, skin lesions, lung infiltrates, hepatosplenomegaly with jaundice and liver dysfunction, pancytopenia, and coagulopathy, and pathologic findings of hemophagocytosis in bone marrow and other tissues. HPS may be diagnosed in association with malignant, genetic, or autoimmune diseases, but it is also prominently linked with EBV infection (Fisman, 2000; Imashuku, 2002).

The clinical courses of human EBV-associated hemophagocytic syndrome (EBV-AHS) are often fulminant and result in poor outcomes, while patients with non-viral pathogen-associated HPS often respond to treatment of the underlying infection. Rare cases of primary EBV infection develop into fatal IM (Mroczek et al., 1987; Okano and Gross, 1996), which is commonly accompanied by VAHS, whereas infectious mononucleosis is usually a self-limiting disease (Okano and Gross, 1996). EBV-AHS is also associated not only with B-cell LPD, most cases of XLP (Okano and Gross, 1996) and sporadic or familial HPS (Gaffey et al., 1993), but also with T-cell LPD in patients with fatal childhood T-cell LPD (Su et al., 1994, 1995; Kikuta, 1995), chronic active EBV infection (Yamashita et al., 1998; Okano, 2002), and EBV-infected T-cell lymphoma (Craig et al., 1992; Cheng et al., 1993; Su et al., 1993). A Vietnamese case of EBV-associated natural killer cell proliferation with fatal VAHS has been reported (Dolezal et al., 1995). Increased serum levels of many cytokines, including soluble interleukin (IL)-2, IL-1, IL-3, IL-6, IL-10, IL-18, macrophage-colony stimulating factor (M-CSF), interferon- γ , prostaglandins, and tumor necrosis factor-alpha (TNF- α), have also been reported (Su et al., 1995; Lay et al., 1997; Imashuku, 2002). Although EBV-AHS in previously healthy children or young adults is usually considered a reactive process, high-risk groups of EBV-AHS patients, such as younger children or patients with clonal cytogenetic abnormalities, mimic T-cell lymphomas biologically. They should be considered malignant entities and be treated with intensive cytotoxic chemotherapy or stem-cell transplantation (Su et al., 1995; Dolezal et al., 1995; Chen et al., 1997; Ito et al.,

2000; Yagita et al., 2001; Imashuku, 2002). Many cases of HPS have been associated with viral infections, particularly EBV, but the pathogenesis of the syndrome still remains unclear. Developing the best therapy for EBV-AHS has been one of the most challenging goals in medicine. The rapid fatal course of EBV-AHS has not allowed the opportunity to test both conventional and new therapies for this disease. However, there are several treatment strategies designed to control the cytokine storm and suppress the proliferating virus-infected cells and macrophages (Su et al., 1995; Okano and Gross, 1996; Imashuku, 2002). The reported HPS treatments include antiviral agents, cytotoxic chemotherapy, glucocorticoids, cyclosporine A (CsA), intravenous immunoglobulin and stem-cell transplantation (Su et al., 1995; Imashuku, 2002).

Herpesvirus papio (HVP) is a lymphocryptovirus from baboons that is similar to EBV both biologically and genetically (Falk, 1979; Franken et al., 1996; Yates et al., 1996; Fuentes-Panana, et al., 1999). The epidemiology of HVP infection in baboons closely parallels that of EBV infection in humans (Jenson et al., 2000) and HVP can immortalize B lymphocytes from humans and various monkeys. HVP also has the potential to induce B-cell LPD in the cotton-topped marmoset, a New World monkey (Falk, 1979).

We have previously reported the first *in vivo* animal model of EBV-associated fatal HPS in which fatal LPD with HPS frequently developed in New Zealand White and Japanese White rabbits inoculated with HPV (Hayashi et al., 2001, 2002, 2003). In this study, we report data from preliminary therapeutic trials that were carried out using a rabbit model of HVP-induced LPD with hemophagocytosis. In addition, an unexpected and interesting finding was observed in one treated rabbit. This rabbit had the longest survival and developed HVP-negative rabbit lymphoma surrounded by HVP-positive LPD. A comparative analysis of therapies used for this rabbit model and for human EBV-AHS, as well as the pathogenesis of HVP-negative lymphoma development, will be discussed herein.

Materials and methods

HVP-producing cells

An HVP-producing baboon lymphoblastoid cell line (594S) was cultured.

Inoculation of cell-free virion pellets of HVP from culture supernatants

Specific-pathogen-free normal Japanese White rabbits (2.5kg) obtained from Shimizu Laboratory Supplies (Kyoto, Japan) were inoculated intravenously (i.v.) with the cell-free virion pellets from 200 ml supernatants of 594S culture, prepared as described below. Culture supernatants obtained from 594S culture (5×10^5 cells/ml) were first centrifuged at 8,000 g for 30

Therapy using a rabbit model for EBV-AHS

min to remove cell debris (Himac CR20, Hitachi, Tokyo, Japan) and then at 100,000 g for 60 min to obtain the pellets (Hitachi Himac Centrifuge SCP85H). These pellets were stocked in a freezer at -80 °C until the experiments were carried out. The stocked pellets from the supernatant (4,000 ml) were mixed and then divided into twenty crude virus fractions (each fraction was consistent with pellets from the 200 ml supernatant) (Table 1).

Antibody responses to VCA of EBV or HVP

The titers of anti-VCA-IgG in pre- and post-inoculation sera reserved from rabbits were examined

retrospectively by an indirect immunofluorescence (IF) test using the P3HR-1 cell line as a standard antigen of VCA and fluorescein isothiocyanate (FITC)-labeled goat anti-rabbit IgG (Cappel, West Chester, PA, USA) as a secondary antibody.

Therapy against HVP-infection of rabbits

Therapies began on the 20th day after intravenous inoculation with cell-free virions of HVP. HVP infection of the rabbits was confirmed on the 19th day post-inoculation by increased anti-EBV-VCA titers and detection of HVP-infected lymphocytes in peripheral blood by in situ hybridization (ISH). As controls, the

Table 1. Summary of therapeutic trials against HVP-infection of rabbits.

THERAPY RABBITS	INOCULUM	19th DAY BEFORE THERAPY	20th DAY START THE THERAPY	LAB DATA AFTER THE THERAPY	TOTAL THERAPY PROGNOSIS (SURVIVAL)	PATHOLOGY MACROSCOPY	PATHOLOGY MICROSCOPY. LPD, HPS
Anti-herpesvirus drug (vidarabine) 3 rabbits	HVP, iv	VCA: x160~x640 HVP-EBER1+Ly; 45~293	Vidarabine, 6mg, iv, (x5d), 2 courses start	26th day, EBER1+Ly; 140-168	Vidarabine, iv, 3~6 times; death (3/3); (23d, 28d, 28d)	nasal bleeding, bloody ascites, hepatosplenomegaly, rupture of splenomegaly, LN swelling with bleeding	Severe LPD with HVP-EBER1+ (3/3), HPS (2/3)
CHOP, J33	HVP, iv	VCA: x640 HVP-EBER1+ Ly; 844	CHOP start; C:100mg, ADM; 10mg, O; 0.25mg, P;5mgx 5d	28th day, VCA;x20-40, EBER1+Ly;3	CHOP, 3 courses; death 38 days after last CHOP; (105d)	pneumonia, obstructive lesions of larynx and ileum, mild splenomegaly, LN swellings	generalized LPD with HVP-EBER1+, HVP-EBER1-negative ML of larynx and ileum, HPS+, pneumonia
CHOP, J34	HVP, iv	VCA: x20, HVP-EBER1+ Ly; 972	CHOP start; C: 100mg, ADM; 10mg, O;0.25mg, P;5mgx5d	28th,VCA;<x20 EBER1+Ly; 50	CHOP, incomplete 3 courses; death (62d)	pneumonia with hemorrhages, moderate splenomegaly, congestion of liver	LPD with HVP-EBER1+, pneumonia with hemorrhages
CHOP, J35	HVP, iv	VCA: x20 HVP-EBER1+Ly; 806	CHOP start; C: 100mg, ADM; 10mg, O;0.25mg, P;5mgx5d	ND	CHOP,1 course; death (26d)	Massive hemorrhage of stomach, hemorrhage of gingiva and LN, splenomegaly(-), pneumonia (-)	residual very mild LPD with HVP-EBER1+, HPS+, marked hemorrhage of stomach
No therapy, 14 rabbits	HVP, iv	VCA: x80~x1280, HVP-EBER1+Ly; 39~256	No therapy	ND	No therapy; all dead (14/14); (21-31 d)	bleeding tendency, hepatosplenomegaly, LN swellings	LPD with HVP-EBER1+ (14/14), HPS (10/14), bleeding, liver damage
Control, CHOP, 3 rabbit	No virus	ND	ND	ND	CHOP 3 courses, killed (120d)	Nothing particular.	Nothing particular (3/3)
Control, vidarabine, 3 rabbit	No virus	ND	ND	ND	Vidarabine, 6mg, iv, (x5d), 2 courses, killed (120d)	Nothing particular.	Nothing particular (3/3)

HVP, Herpesvirus papio; iv, intravenously; VCA, anti-EBV-VCA-IgG titer; CHOP, cyclophosphamide, doxorubicin, oncovine (vincristine), prednisone; ML, malignant lymphoma; ND, Not Done. HVP-EBER1+Ly, HVP-encoded small RNA1 expressing lymphocyte; LN, lymph node; LPD, lymphoproliferative diseases; HPS, hemophagocytic syndrome.

following therapies were carried out in each of the three rabbits that had not been infected with HVP.

1) Anti-herpesvirus drug:

Vidarabine (Mochida Pharmaceutical Co. LTD, Tokyo) was administered in each three rabbits without or with HVP infection. Two courses of consecutive five-day intravenous vidarabine (6 mg) inoculations, with one course given per week, were planned.

2) Cytotoxic Chemotherapy (CHOP)

Three courses of CHOP [cyclophosphamide (Shionogi, Osaka), doxorubicin (Kyowa Hakko Kogyo, Tokyo), oncovine (vincristine) (Eli Lilly Japan, Kobe), prednisone (Shionogi, Osaka)] were planned in each three rabbits without or with HVP infection (J33, J34 and J35). CHOP doses were as follows: cyclophosphamide, 100mg (40 mg/kg), given intravenously (i.v.); doxorubicin, 10 mg (4 mg/kg), i.v.; vincristine, 0.25 mg (0.1 mg/kg), i.v.; and prednisone, 5 mg (2 mg/kg), i.v.. every day for five days.

Morphological examination

Six HVP-infected rabbits receiving therapy and 14 untreated infected rabbits were observed until their death. Other uninfected rabbits treated with vidarabine or CHOP were killed by intravenous inoculation with excess pentobarbital sodium (Abbott Laboratories, North Chicago, IL) on day 120. The organs including the spleen, liver, lymph nodes, lungs, thymus, kidneys, bone marrow, heart, and gastrointestinal tract were examined macroscopically and microscopically.

Phenotypic analysis of HVP-induced LPD and cell lines

Tissue samples from rabbit LPD induced by HVP (594S) inoculation were immunostained using the avidin-biotin-peroxidase complex (ABC) method (Immuno Mark Biotin Avidin Universal Kit; ICN Biochemical, Costa Mesa, CA, USA) or by the peroxidase antiperoxidase (PAP) method using antibodies to rabbit CD45, CD5, CD4, MHC class II DQ (Serotec, Oxford, England), rabbit CD8, CD25, CD79a (Spring Valley Laboratories Inc., MD, USA), RT1, RT2 (antibodies to rabbit T-cells, Cedarlane Laboratories, Ontario, Canada), or RABELA (rabbit bursal equivalent to lymphocyte antisera, Cedarlane Laboratories).

Detection of HVP genome in 594S cells and HVP-induced rabbit LPD

1) HVP-encoded small RNA-1 (HVP-EBER-1) expression

The HVP RNA ISH was performed using a single-stranded 30-base FITC-labeled oligonucleotide

complementary (anti-sense probe) or anti-complementary (sense, negative control probe) to a portion of the HVP 1 RNA (HVP-EBER-1) gene (Howe and Shu., 1988). The sequence of the anti-sense probe was 5'AGACGCTACCGTCACCTCCCGGGACTTGTA-3'. The ISH was carried out as described previously on routinely processed sections of paraffin-embedded samples of 594S cells, and of the HVP-induced LPD lesions, using the DAKO in situ hybridization kit (Hayashi et al., 2001). Cytosmears of 594S cells or PBMC from HVP-infected rabbits were also fixed in 10% conventional formalin, and HVP-EBER1-ISH was performed. Finally, the numbers of HVP-EBER-1+ cells in each PBMC sample (1×10^4 cells) were counted.

2) Polymerase chain reaction (PCR)

Digests with proteinase K (500 mg/ml) in digestion buffer (10 mM Tris-HCl, 10 mM EDTA, 0.1% SDS) were carried out using the 594S cells (HVP) as the positive control, the B95-8 (human EBV-producing), Ts-B6 (Cynomolgus-EBV-producing) cells and the spleen or peripheral blood from normal rabbits as the negative controls, and tissues from HVP-induced rabbit LPD lesions as the samples. Samples were digested at 37 °C for two days. DNA was extracted by the phenol/chloroform method and ethanol precipitation. Thirty cycles of PCR were performed on 100 ng of DNA in 100 ul of PCR mixture, which consisted of 50 mM KCl, 10 mM Tris-HCl (pH 8.3), 2.5 mM MgCl₂, 0.02% porcine gelatin (Sigma, St. Louis, MO), 200 nM dNTPs, 200 mM primer pair, and 2.5 units of Taq polymerase (Takara, Kyoto, Japan). One primer pair for HVP-EBNA-1 and one primer pair for HVP-EBNA-2 were employed as previously described (Ling et al., 1993; Yates et al., 1996; Hayashi et al., 2001). Primer pair sequences were: 1) HPNA-1S: 5'CTGGGTTGTTGCGT TCCATG 3', HPNA-1A: 5'TTGGGGGCGTCTCCTAAC AA 3'; and 2) HPNA2-1231S: 5'ACCACTGGGACCAG TTTGGT 3', HPNA2-1612A: 5'AGAGGACTGAGGTT CTTGC 3'. Amplified PCR products were electrophoresed in 2% NuSieve gel and visualized with 0.5 mg/ml ethidium bromide.

PCR using HVP-EBER-1-ISH-guided microdissected materials: The paraffin-embedded sample sections were examined with HVP-EBER-1-ISH. The HVP-EBER-1 (+) rabbit LPD and HVP-EBER-1 (-) malignant lymphomas from the laryngeal and intestinal lesions of the J33 rabbit were collected separately after microdissection. Microdissected samples were digested by proteinase K and used as templates for PCR to detect HVP-EBNA-1 or HVP-EBNA-2 DNA.

Statistical methods

Overall survival was defined as the time between the virus inoculation and death or the last follow-up. Survival curves were calculated using the Kaplan-Meier method, and differences between them were tested for

significance using the log-rank test. All statistical analyses were performed using StatView (version 5.0, SAS Institute Inc. Cary, NC 27513).

Results

Incidence of LPD with VAHS in rabbits inoculated with cell-free virion pellets from 594S cell culture

The pathological findings for the rabbit experiments are summarized in Table 1. All 14 of the rabbits inoculated intravenously with the cell-free virions of HVP died of LPD and VAHS 21 to 31 days after inoculation. LPD was also accompanied by VAHS in 10 of these 14 rabbits. All three HVP-inoculated rabbits treated with vidarabine died of HVP and VAHS between the 23rd and 28th day after inoculation. The HVP-infected J35 rabbit died of massive stomach bleeding on the 26th day, just two days after the first CHOP treatment. The J34 rabbit died of opportunistic pneumonia on the 62nd day during the third CHOP treatment. The J33 rabbit treated with three courses of CHOP died of HVP-induced LPD associated with HVP-unrelated lymphomas on the 105th day. No lesions were detected in any of the three non-infected rabbits that were treated only with vidarabine or with three courses of CHOP.

Antibody responses to VCA of EBV and laboratory data

All of the sera from rabbits inoculated intravenously with HVP (594S) showed increased anti-EBV-VCA IgG antibody titers (x20 - x1280). This titer decreased for 1-2 weeks after the CHOP treatment, but then it gradually increased again. In contrast, the pre-experimental sera and the sera from the control rabbits without inoculation of HVP were negative (Table 1).

Pathological findings of Japanese white rabbits inoculated with HVP

Macroscopic characteristics of the infected rabbits

HVP-infected rabbits, untreated or treated with vidarabine. The HVP-inoculated rabbits that did not receive therapy appeared physically healthy for two to three weeks, but then showed severe rhinorrhea admixed with blood and dyspnea in the several days preceding their death. Pathological findings of HVP-infected rabbits treated with vidarabine were not essentially different from those of the infected rabbits that did not receive therapy. The autopsy of the infected rabbits revealed mild or marked splenomegaly (Fig. 1A). Dark purple, swollen lymph nodes were usually observed in the neck, mediastinum, axilla, mesentery, para-stomach, hepatic hilus, or inguinal regions (Fig. 1B). Mild hepatomegaly usually accompanied these symptoms. White nodules were sometimes found in cross-sections of the spleen, liver, or heart. The thymus appeared

normal. Lungs showed congestion and edema, often accompanied by pulmonary hemorrhage.

HVP-infected rabbits treated with CHOP. The HVP-infected J35 rabbit, which died of massive stomach bleeding on the 26th day post-inoculation, just two days after the first CHOP treatment, showed gingival bleeding, but neither splenomegaly nor lymph node swelling. The J34 rabbit, which died of opportunistic pneumonia accompanied by hemorrhage on the 62nd day, during its third CHOP treatment, showed moderate splenomegaly and congestion of the liver, but no lymph node swelling. Obstructive tumors in the larynx and ileum as well as mild swelling of spleen and lymph nodes were observed in the J33 rabbit that was treated with three courses of CHOP. This rabbit died on the 105th day post-inoculation.

Microscopic characteristics of HVP-induced rabbit LPD

HVP-infected rabbits, untreated or treated with vidarabine. Histological examination of rabbit tissues revealed mild to severe infiltration of atypical lymphoid cells involving many organs. Lymph nodes (Fig. 1C), spleen and liver were frequently and markedly involved. Atypical large or medium-sized lymphoid cells infiltrated around the perivascular areas with a diffuse or nodular pattern. The basic structure of the infiltrated organs was usually preserved. Mitotic figures were numerous and atypical cell karyorrhexis (apoptotic cells) were prominent, indicating the high growth rate and high cell turnover of these atypical lymphoid cells. Many macrophages containing cellular debris or apoptotic bodies from individual cell necrosis were distributed among the atypical cell-infiltrated lesions, showing a "starry sky" pattern. Some of these macrophages also showed erythrophagia.

Most of the involved lymph nodes showed replacement of parenchyma by diffusely infiltrated atypical lymphoid cells. The nodal sinus also contained atypical lymphoid cells as well as many hemophagocytes, but nodal sinus structures were usually not effaced. Severe periportal and moderate sinusoidal infiltration of atypical lymphoid cells was usually observed in the fully involved liver, and this was often accompanied by central degeneration of the hepatic lobules. Mild to moderate infiltration of atypical lymphoid cells was often observed in the kidneys and lungs. In some cases, focal infiltration of atypical lymphoid cells was found in the heart, thymus or bone marrow. Atypical lymphoid cells also invaded the gastrointestinal tract, adrenal glands, tongue, salivary gland, fat tissues and muscle. Atypical lymphocytes were often found in the blood vessels. Hemophagocytosis was also found in the spleen and thymus.

HVP-infected rabbits treated with CHOP. The J35 rabbit (one course of CHOP, 26 days survival) showed

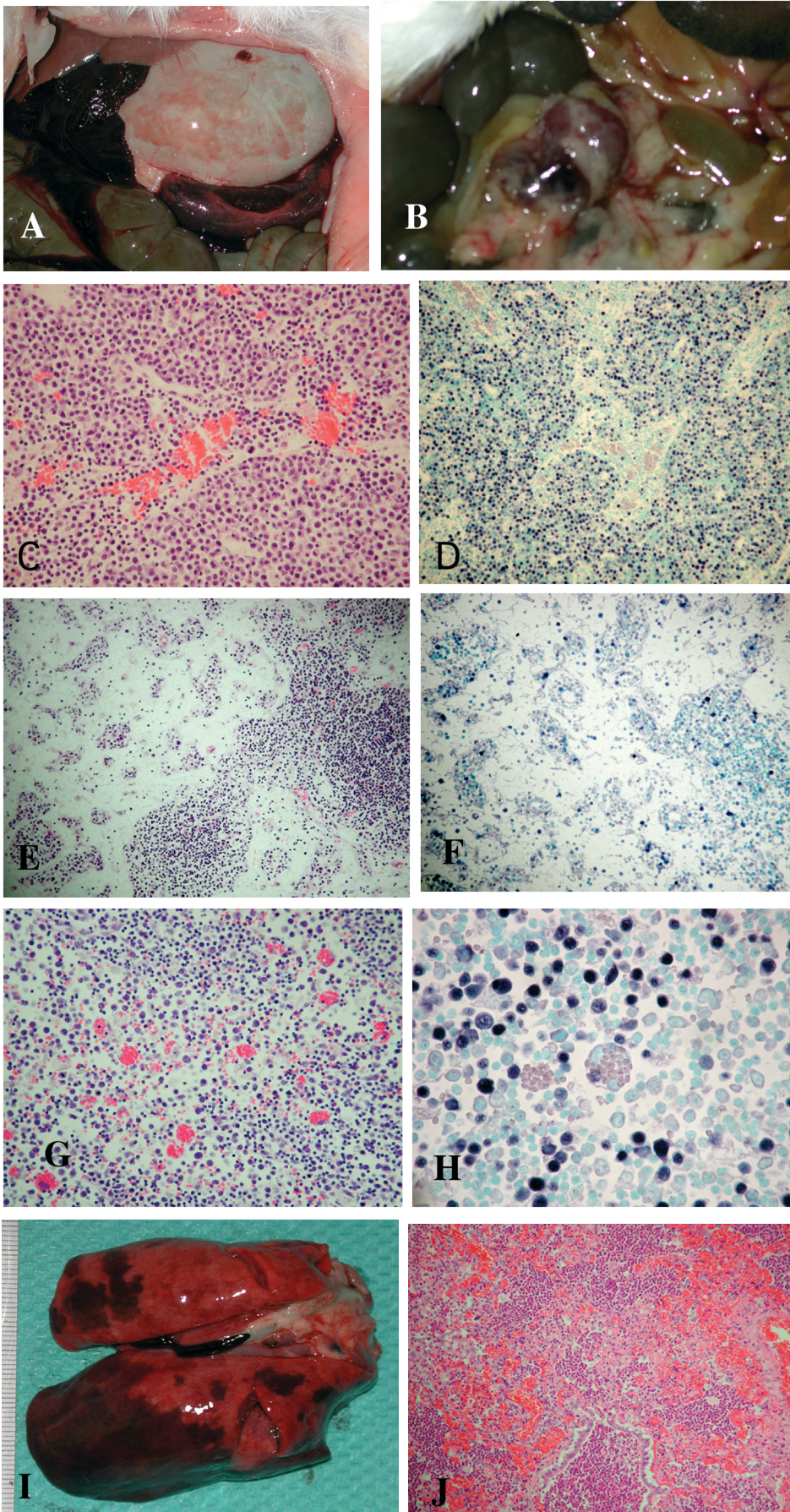


Fig. 1. A-D. An HVP-infected rabbit treated with Vidarabine. **A.** Massive peritoneal bleeding from the ruptured enlarged spleen (survival, 23 days). **B.** Lymph node swelling with hemorrhages in the mesentery (survival, 28 days). **C and D.** HVP-induced lymphoproliferative disease (LPD); Atypical lymphoid cells with HVP-EBER1 expression replace the parenchyma of the lymph node, and are also observed in the sinus, accompanied by sinus hemorrhage (survival, 28 days). **E-H.** Rabbit J35 treated with one course of CHOP, 26 days survival. The involuted lymph node caused by CHOP therapy shows a sparse distribution of lymphocytes with few atypical cells (**E**), but unexpected numbers of HVP-EBER1+ lymphocytes are disclosed by ISH (**F**). The normal-sized spleen still retains considerable numbers of HVP-EBER1+ atypical lymphocytes and also shows hemophagocytosis (**G and H**). Note an HVP-EBER1+ lymphocyte (arrow) in a hemophagocytic macrophage (**H**). **I and J.** Rabbit J34 treated with three incomplete courses of CHOP, 62 days survival. Severe acute pneumonia as an opportunistic infection, accompanied by massive hemorrhage. **C, G** (H.E), x 120; **E** (H.E), x 80; **H** (H.E), x 480; **J** (H.E), x 60; **D, F** (HVP-EBER1-ISH), x 80; **H** (HVP-EBER1-ISH), x 480

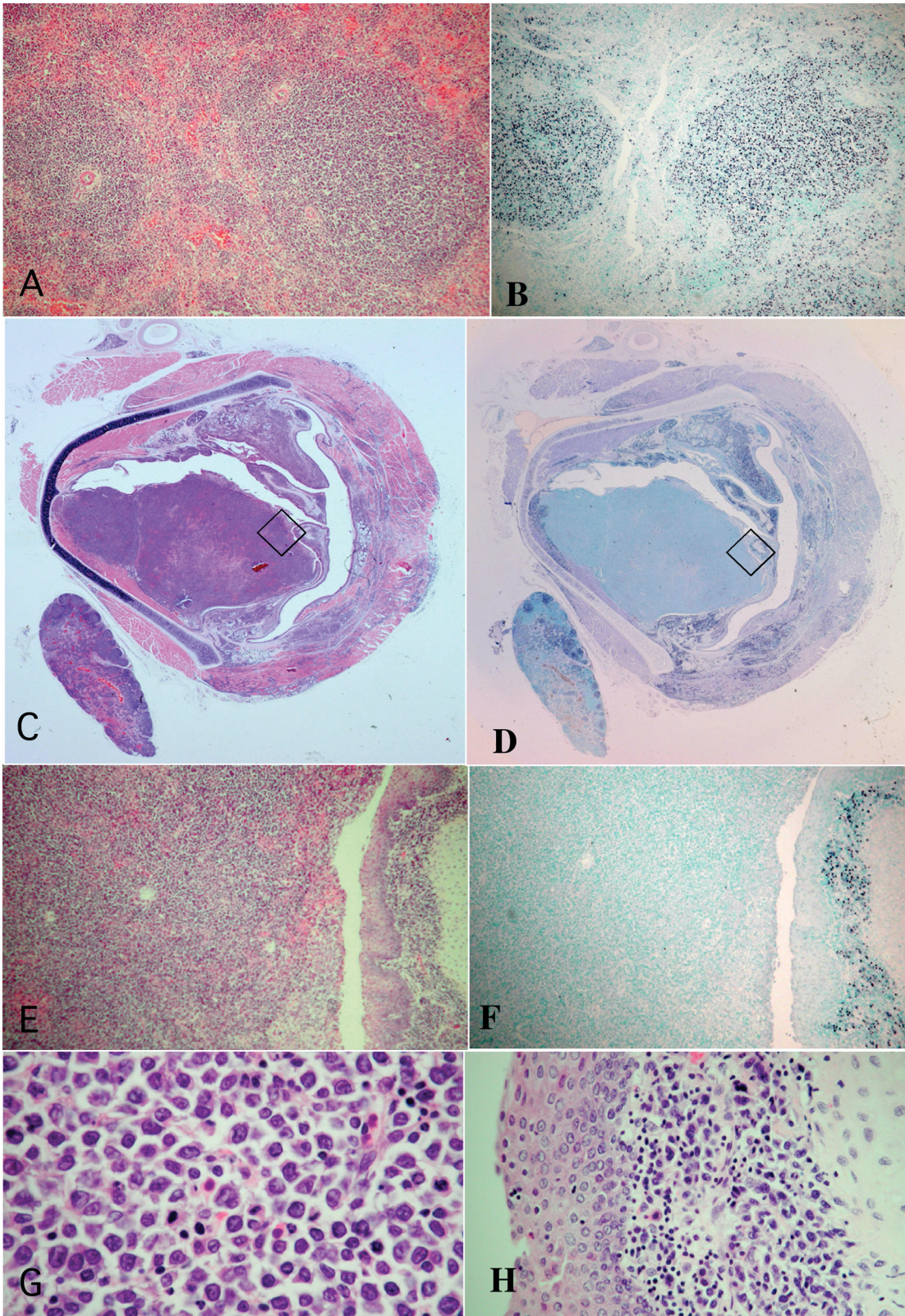


Fig. 2. Rabbit J33 treated with three courses of CHOP, 105 days survival. **A and B.** LPD with HVP-EBER1 expression in the spleen. **C-H.** Transection of the larynx and surrounding tissues including a lymph node. **C and D.** A large space-occupying lymphoma of the left vocal cord, without HVP-EBER1 expression. This is surrounded by HVP-EBER1+ LPD, which nearly causes an obstructed airway, while the right vocal cord and surrounding tissues including muscles and the lymph node have HVP-EBER1+ LPD. **E-H.** Higher magnification of the quadrilateral regions of figures C and D. HVP-EBER1-negative lymphoma (left side of E and F, G) and HVP-EBER1+ LPD in the vocal cord (right side of E and F, H). Malignant lymphomas are composed of larger cells with severe atypia (G), compared with atypical cells of LPD (H). A (H.E), x 60; B (HVP-EBER1-ISH), x 60; C (H.E), x 4; D (HVP-EBER1-ISH), x 4; E (H.E), x 80; F (HVP-EBER1-ISH), x 80; G (H.E), x 400; H (H.E), x 320

involved lymphoid tissues of lymph nodes and spleen, which had a dramatically decreased number of lymphoid cells due to CHOP therapy. Therefore, these appeared to contain no or few HVP-infected atypical lymphoid cells upon hematoxylin and eosin staining (H.E.) (Fig. 1E). The normal-sized spleen had considerable numbers of atypical lymphoid cells accompanied by hemophagocytosis (Fig. 1G). Marked gastric bleeding was found in the J35 rabbit, which was the direct cause of death. The J34 rabbit (incomplete three courses of CHOP, 62 days survival) showed moderate LPD as well as acute pneumonia with severe hemorrhage (Fig. 1I,J), which was the cause of death. The J33 rabbit (three courses of CHOP, 105 days survival) developed generalized LPD (Fig. 2A) and hemophagocytosis. In addition, there were obstructive tumors in the larynx and ileum, which consisted of large malignant lymphoma cells surrounded by LPD lesions (Fig. 2C). Larger magnification light microscopy revealed that the lymphoma cells were larger and more atypical than the atypical cells of LPD were (Fig. 2E,G,H).

Immunophenotypes of the HVP-induced rabbit LPD

The immunohistochemical analyses using frozen tissues revealed that the dominant atypical lymphoid cells were frequently positive for rabbit CD45, CD5, MHC class II DQ, CD25, and also for rabbit CD4 or CD8. Rabbit CD79a-positive cells were also observed as a small component of infiltrated lymphoid cells. These atypical lymphoid cells showed no expression of rabbit RABELA (rabbit B-cell marker). The dominant lymphoid cells that infiltrated the liver were T cells (CD-8), while both T and B cells were detected in the examined spleen and lymph nodes.

Detection of the HVP genome

1) HVP-EBER-1 expression

HVP-infected rabbits, untreated or treated with

vidarabine. The HVP-EBER-1-ISH revealed that most of the 594S cells expressed HVP-EBER-1. In all cases of LPD, HVP-EBER-1 expression was detected in virtually all of the atypical lymphoid cells (Fig. 1D). The HVP-EBER-1 signal was mostly nuclear. Rare and scattered small non-atypical lymphocytes with HVP-EBER-1 expression were also identified in some rabbits with LPD.

HVP-infected rabbits treated with CHOP. Unexpectedly, considerable numbers of HVP-EBER1+ lymphocytes were detected in the involuted or normal-sized lymphoid tissues of the J35 rabbit (Fig. 1F,H). Not only large atypical lymphocytes, but also several small lymphocytes expressed HVP-EBER1 (Fig. 1F,H). HVP-EBER1+ lymphocytes or their debris were rarely engulfed in hemophagocytic macrophages (Fig. H). The J34 rabbit showed moderate LPD, which was characterized by HVP-EBER1+ lymphocytes. The J33 rabbit showed generalized HVP-EBER1+ LPD (Fig. 2B), and it also developed two HVP-EBER1-negative lymphomas in the larynx and ileum, which were surrounded by HVP-EBER1+ LPD (Fig. 2D,F).

HVP-EBER1+ lymphocyte numbers in peripheral blood from the infected rabbits decreased dramatically after CHOP treatment (Table 1), but gradually increased later (data not shown).

PCR

PCR using one primer pair for the HVP-EBNA-1 region (HPNA-1S and HPNA-1A) revealed amplified DNA at the position of 389 bp in the positive control (HVP-producing 594S cells) and rabbit LPD. PCR using the primer pair for the HVP-EBNA-2 region (HPNA2-1231S and HPNA2-1612A) showed DNA amplification at the position of 382 bp in the positive control (HVP-producing 594S cells) and in the HVP-induced rabbit LPD lesions. However, no amplification by PCR was seen in the negative controls [Ts-B6 (Cyno-EBV) or B95-8 (human EBV)].

PCR of HVP-EBNA2

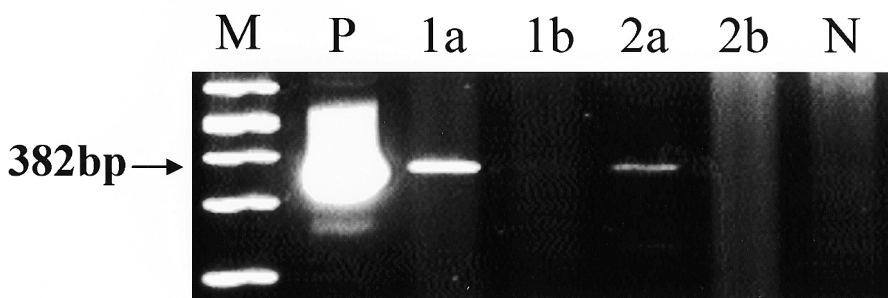


Fig. 3. PCR for HVP-EBNA2 in the HVP-EBER1-positive LPDs (1a and 2a) and HVP-EBER1-negative lymphomas (1b and 2b) from the HVP-infected J33 rabbit, which was treated with three courses of CHOP. HVP-EBNA2 DNA is amplified at the 382 base pair position, shown in the positive control [lane P, 594S (HVP)] and the HVP-EBER1-positive LPDs from the intestine and larynx (lanes 1a and 2a, respectively), but not in the negative control [lane N, Ra1 (HTLV-I) and HVP-EBER1-negative lymphomas from the intestine and larynx (lanes 1b and 2b, respectively)].

HVP-EBER1-positive LPDs and HVP-EBER1-negative lymphomas in the J33 rabbit

PCR using microdissected materials from each of the HVP-EBER1-positive LPDs and from the HVP-EBER1-negative lymphomas revealed that HVP-DNA was amplified in HVP-EBER1-positive LPDs, but not in HVP-EBER1-negative lymphomas (Fig. 3).

Analysis of survival

The overall survivals of the HVP-inoculated rabbits with or without therapies were shown in Figure 4. The viral infected rabbits treated with vidarabine showed the similar mean survival (26.3 days) to the untreated infected rabbits (24 days) and the overall survival was not significantly different ($P=0.2112$). The CHOP-treated infected rabbits showed the longer mean survival (64.3 days) than the untreated infected rabbits (24 days) and vidarabine-treated infected rabbits (26.3 days) and the overall survival was significantly different from that of untreated infected rabbits ($P=0.0163$) but not from vidarabine-treated infected rabbits ($P=0.2254$).

Discussion

We have previously reported an animal model of EBV-associated lymphomagenesis in humans: the malignant T-cell lymphoma induction of rabbits by EBV-like viruses from cynomolgus monkeys (Hayashi et al., 1994, 1995, 1999, 2000; Chen et al., 1997; Koirala et al., 1997). We have also reported the first in vivo animal model for EBV-AHS (Hayashi et al., 2001, 2002, 2003). In the latter study we showed that intravenous or peroral inoculation of HVP in New Zealand White rabbits resulted in a high rate of fatal HVP-infected LPD with HPS induction within a few months. This rabbit model is useful for studying the pathogenesis, prevention, and treatment of human EBV-AHS (Hayashi et al., 2001,

2002, 2003). This rabbit model of fatal LPD with VAHS induced by primary infection of HVP showed clinicopathological features similar to childhood EBV-AHS (Su et al., 1994, 1995). or fulminant EBV-positive T-cell LPD and hemophagocytosis after acute/chronic EBV infection (Quintanilla-Martinez et al., 2000). These characteristics were indicated by the following facts: (1) the rabbits used were previously healthy and had no immunodeficiency background; (2) the affected rabbits showed seroconversion and a fulminant course and high mortality after anytime from three weeks to three months; hepatosplenomegaly with liver injury or necrosis, systemic lymph node swelling, and a bleeding tendency were frequently observed; (3) atypical lymphoid cell infiltration was detected in many organs, particularly the lymph nodes, spleen and liver; (4) fatal rabbit LPD with HPS was induced by atypical T-cell proliferation; (5) hemophagocytosis was also present, most markedly in the lymph nodes, moderately in the spleen, and mildly in bone marrow; and (6) this rabbit system could also be developed by delivering an oral spray of HVP, indicating that infection occurs by the same natural transmission route as does human EBV.

Six IL-2-dependent rabbit lymphoid cell lines were established from the transplanted scid tumors of LPD in three out of five HVP-infected rabbits, whereas no cell line was obtained from the ten HVP-induced rabbits with LPD without using IL-2. These IL-2-dependent rabbit cell lines carrying an HVP infection had a T-cell phenotype (CD8) and latency types I/II of HVP-infection. A normal rabbit karyotype was detected in five out of six IL-2-dependent cell lines and in all primary LPD lesions in the spleens and lymph nodes of five HVP-infected rabbits that were used for primary culture. Three out of six cell lines showed tumorigenicity in nude mice (Hayashi et al., 2003).

In the present study, we have also confirmed HVP-induced fatal LPD and VAHS in Japanese White rabbits. Atypical lymphocytes in the HVP-induced LPD of Japanese White rabbits expressed HVP-EBER1 and were found to contain HVP-DNA by PCR analysis, but not human EBV or cynomolgus EBV. In this study, we focused especially on examining the effectiveness of an anti-viral agent or cytotoxic chemotherapy (CHOP) for treatment of HVP-induced rabbit LPD and VAHS. We observed several unexpected and interesting phenomena, and obtained data on therapeutic trials. In addition, some important new findings have been seen that were not disclosed in the previous report (Hayashi et al., 2001), such as: (1) the dominant infiltrating lymphoid cells in LPD of the liver were T-cells (CD8), while both T-cells and B-cells were observed in the spleen and lymph nodes; (2) the newly-developed HVP-EBER1-ISH system is the best way to identify HVP-infected cells, and is superior to the EBV-EBER1-ISH used in the previous study (Hayashi et al., 2001); and (3) the Japanese White rabbits used in this HVP infection study showed similar clinicopathological features to those of HVP-infected New Zealand White rabbits used in the

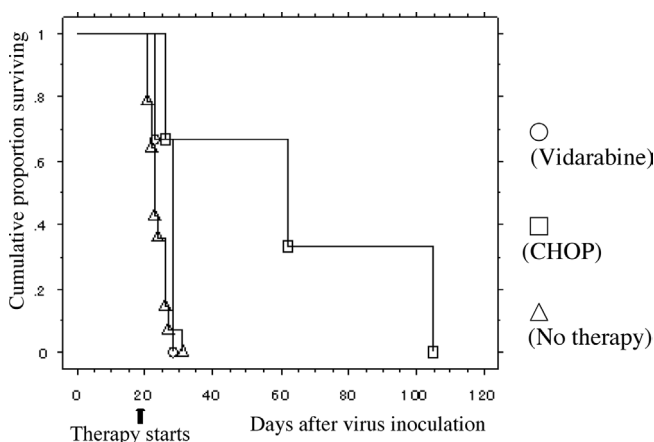


Fig. 4. Overall survival of the HVP-inoculated rabbits with or without therapies.

previous report (Hayashi et al., 2001). All untreated Japanese White rabbits infected by intravenous HVP inoculation died within three to four weeks of VAHS, and death typically involved liver damage and bleeding, especially terminal hemorrhage of the lungs.

The proliferating lymphoid cells in the acute HVP-infected rabbit model for EBV-AHS in this study were polyclonal HVP-infected cells (Hayashi et al., 2003). We speculate that HVP-infected Japanese White rabbits died of fulminant LPD before the development of completely monoclonal neoplastic lymphoma with clonal cytogenetic abnormalities. However, it is possible that these rabbit LPD lesions may contain some small components of neoplastic or pre-neoplastic T-cells with HVP infection. These can progress to neoplastic cells with tumorigenicity by selections occurring through transplantation and culture using IL-2 (Hayashi et al., 2003). It is likely that HVP-infected rabbit T-cells with latency type I/II can be saved from attacks of host immunity, but rabbit cells with latency type III, which may involve B-cells, provoke the immunity of rabbits and transplanted mice. For these reasons, only T-cell lymphomas or T-cell LPD were induced in rabbits inoculated with simian EBV-like viruses in previous reports (Hayashi et al., 1995, 1999, 2001).

CD8+ cells are particularly important for eliminating the virus-infected cells. Callan et al. (1996) showed that large monoclonal or oligoclonal populations of CD8+ T-cells account for a significant proportion of the lymphocytosis in acute infectious mononucleosis. The selective and massive expansion of a few dominant clones of CD8+ T-cells is driven by antigens of EBV, and this is an important feature of the primary response to EBV. The dominant EBV-infected cell populations were found to be CD8+ lymphocyte sub-populations in all four Japanese patients with EBV-HLH (Kasahara et al., 2001). In our HVP-infected rabbit model, the dominant lymphoid cells that infiltrated in LPD of the liver were T-cells (CD8+). In addition, rabbit CD8+ clones were a major source of the established rabbit cell lines from HVP-induced LPD and VAHS (Hayashi et al., 2003).

The newly-developed HVP-EBER1-ISH system is superior to the human EBV-EBER1-ISH used in the previous study, because probes for HVP-EBER1-ISH were synthesized according to the sequence of the HVP-EBER1 region. HVP-EBER1 is a homologue of EBV-EBER1 and has a significant similarity in both sequence and predicted secondary structure of EBV-EBER1 (Howe and Shu, 1988). HVP-EBER1 expression was detected in virtually all of the atypical lymphoid cells in the previous study (Hayashi et al., 2001). However, the intensity of HVP-EBER1 expression varied among lymphoid cells of different tissues or organs, and pseudonegative expression of HVP-EBER1 was seen in some samples. Therefore, repeated trials of ISH were sometimes needed. The newly-developed HVP-EBER1-ISH enables us to detect the precise distribution of HVP-infected cells with strong and clear HVP-EBER1

expression in both New Zealand White and Japanese White rabbits with HVP-infection. For example, this new ISH revealed many HVP-infected lymphoid cells in the lymph node sinuses or vessels, whereas few HVP-EBER1-positive cells were detected by the previous human EBV-EBER1 ISH.

The HVP-induced LPD with VAHS in Japanese White rabbits described in this study is essentially the same as that in the New Zealand White rabbits that were used in our previous study (Hayashi et al., 2001). However, among the rabbits that were infected by oral inoculation with HVP, the infectivity of HVP in the Japanese White rabbits was higher than that in New Zealand rabbits (unpublished data).

Deaths resulting from EBV-AHS are largely caused by the cytokine storm that is induced by extreme activation of T/natural killer (NK) cells and macrophages. This cytokine storm can result in multiple organ failure of heart, lungs, liver or kidneys, as well as severe hemorrhage and immunodeficiencies (Imashuku, 2002). Immunodeficiencies then become a major cause of opportunistic infections. To avoid these risks, the physician has to interrupt the virus-induced inflammatory cascade. Early admission and early adequate treatment after diagnosis are important for the most effective therapy and good prognosis of patients with EBV-AHS. The treatment objective is to control the cytokine storm induced by virus infection and to eradicate the proliferating virus-infected cells. This can be achieved by treatment with etoposide and other chemotherapeutic agents (Imashuku, 2002).

Profound hypercytokinemia plays a key role in the pathophysiology of severe EBV-AHS. Marked elevated serum levels of many cytokines, including soluble IL-2, IL-1, IL-3, IL-6, IL-10, IL-18, M-CSF, interferon- γ , prostaglandins, and TNF- γ , have been reported in the active phase of this disease (Su et al., 1995; Imashuku, 2002). Controlling this cytokine storm is the first step in saving the patient's life. Plasma exchange with or without corticosteroids has been employed as a first-aid treatment. CsA infusion with corticosteroids has also been found to be effective. Intravenous immunoglobulin or anti-thymocyte globulin inoculation has also been employed for control of hypercytokinemia. We made a preliminary examination of the cytokine levels in sera from several rabbits that had developed LPD with HPS, using ELISA kits for human TNF- α , interferon γ , M-CSF, and IL-1 β . However, no cytokine elevation was detected (data not shown), as there must have been no or only very low cross-reactivity between the human and rabbit cytokines examined.

In cases where there is a severe bleeding tendency, a coagulopathy induced by hypercytokinemia, which is a major cause of death, the treatment with a protease inhibitor as well as plasma exchange is useful. For mild cases of EBV-AHS, anti-viral agents such as acyclovir or gancyclovir could be used, but their effectiveness has not been determined by a large cohort study (Imashuku, 2002). In the present study, vidarabine did not produce

any effects at all in the three HVP-infected rabbits. One of the reasons for this lack of effectiveness may be that vidarabine inoculation was carried out at too late a stage of HVP-induced LPD and VAHS, i.e. very close to the terminal stage leading up to the death of the rabbits, when they were in a high risk state.

In these therapeutic trials using a rabbit HPS model, the anti-viral agent vidarabine was not effective at all, and the overall survival of the vidarabine-treated infected rabbits was not significantly different from the untreated infected rabbits ($P=0.2112$). CHOP therapy showed the significant longer overall survival ($P=0.0163$) and effectiveness only in somewhat prolonging the survival of the HVP-infected rabbits by causing a temporary decrease of the virus-infected cells. Further studies on better therapy protocols using this rabbit model are needed.

One very interesting finding was that HVP-EBER1-negative lymphomas surrounded by HVP-EBER1-positive LPDs developed in the CHOP-treated rabbit with the longest survival (105 days). What is the pathogenesis mechanism underlying this phenomenon? We propose three hypotheses that may explain this observation: (1) these lymphomas derived from the cells without HVP infection as a second malignancy that was caused by the CHOP therapy; (2) HVP genomes existed in the lymphomas, but the EBER1 expression pattern was altered due to reasons such as chromosomal translocation, deletion or point mutations of HVP; and (3) the presence of HVP-EBER1-negative lymphomas means that HVP genomes were lost, or else these lymphomas developed from subclones among the HVP-induced LPDs that had lost the HVP. These hypotheses are discussed in detail below.

Hypothesis 1. Second malignancies are known to be an important iatrogenic complication in the treatment for Hodgkin's lymphoma or non-Hodgkin's lymphoma (Ellis and Lishner, 1993; Leone et al., 1999; Varady et al., 2001). For the non-Hodgkin's lymphoma patients treated with alkylating agents, the risk of myelodysplastic syndrome (MDS) and acute non-lymphocytic leukemia (ANLL) was reported to be increased 10-105-fold over that of the general population (Ellis and Lishner, 1993). Secondary leukemias account for 10-30% of all AML (Leone et al., 1999). In our experiment, the possibility that HVP-negative lymphoma was induced by CHOP therapy could not be completely ruled out. However, CHOP treatment does not appear to cause rabbit lymphoma development, because no suspicious lesions were detected 120 days after the first inoculation of three non-infected rabbits that received three courses of CHOP.

Hypothesis 2. Altered EBER expression patterns have been reported in both normal and malignant tissues (Gilligan et al., 1990; Greifeneffer et al., 1998; Sugawara et al., 1999). Gan et al. (2002) reported that defective heterogenous EBV DNA was detected in 10 out of 32 (31%) EBER-positive cases of Hodgkin's disease (HD) and in 8 out of 24 EBER-negative cases of

HD using both standard PCR and PCR in situ hybridization analysis. An absence of EBERs despite EBV infection may be related to experimental variations in the fixation procedures within the tissue block and to RNA degradation. In some cases where there is episome loss from the Burkitt's line in tissue culture, fragments of the EBV genome are incorporated into cellular DNA (Srinivas et al., 1998). In a series of non-endemic Burkitt's lymphomas, similar fragments of the EBV genome were found in tumors that, according to standard criteria (EBER-ISH or EBNA1 immunohistochemistry), would be classified as virus-negative, insofar as these parts of the genome were not retained (Razzouk et al., 1996).

Hypothesis 3. The gammaherpesviruses (EBV, HHV-8) generally persist as episomes in tumor cells. The episomes, tethered to cellular chromatin by viral-encoded nuclear proteins, are not continuous with the cellular DNA. EBV episomes are lost when there is no selective pressure for their maintenance. Although the Burkitt's lymphoma cell lines usually retain their episomes in tissue culture, nasopharyngeal carcinoma cell lines may consistently lose their episomes in culture. Loss of episomes in some of the other Burkitt's cell lines has not been associated with loss of a malignant phenotype (Srinivas et al., 1998). Kaposi's cell lines in tissue culture also lose their episomes. In vitro studies of Burkitt's lymphoma, nasopharyngeal carcinoma and Kaposi's sarcoma cell lines suggest that loss of viral episomes is possible, and a "hit and run" role for EBV or HHV-8 in some diseases cannot be excluded. EBV might be an important cofactor for Hodgkin's disease in general, but the viral episome might be lost from malignant cells where tumor progression has rendered the viral episome unnecessary for survival. This could also occur in patients with relatively intact immune systems, where the presence of the viral episome and the expression of associated viral antigens has rendered the tumor susceptible to immune surveillance (Ambinder, 2000). In fact, no fragments of the viral genome were detected in the cases of LMP1-negative classical Hodgkin's lymphoma (Staratschek-Jox et al., 2000). John Sixbey argued that a rare subclone of proliferating cells that has spontaneously lost EBV at some point after tumor initiation but is now capable of sustaining virus-independent growth may have a survival advantage through avoidance of immune surveillance (Ambinder, 2000).

The experiments reported here raise the possibility that HVP-EBER1-negative lymphomas have defective HVP genomes. However, "hit and run" oncogenesis may be a more likely mechanism for the development of HVP-EBER1-negative lymphomas with the background of HVP-positive LPD, because the absence of HVP-EBER1 expression was reinforced by the absence of both HVP-EBNA1 and HVP-EBNA2 DNA, according to PCR analyses. In addition, another interesting observation was that HVP-DNA was either not detected or was barely detectable by Southern blotting in the

following two rabbit cell lines with tumorigenicity: 1) the J13Sp-scid-livT line was established from liver metastatic foci of transplanted scid LPD tumors; and 2) the J13LN-scid2T-II-nudeT line, which is IL-2-independent, was established from transplanted nude tumors of the IL-2 dependent- J13LN-scid2T line (Hayashi et al., 2003). These results suggest that higher tumorigenic cell lines show a tendency to be composed chiefly of the HVP-negative cells. This experiment might form the basis for a first animal model of "hit and run" oncogenesis by gammaherpesvirus. However, further studies are needed to establish "hit and run" oncogenesis in rabbits. More rabbit models should be developed, and analyses of additional clonalities of the HVP-EBER1-negative lymphomas and HVP-EBER1-positive LPDs could then be carried out.

The reasons for the high susceptibility of rabbits to LPD with VAHS by HVP remain to be elucidated. If the pathogenic mechanism of human VAHS were the same as that of this rabbit model, we could speculate that HVP-infected proliferating T-cells secrete a non-regulated excess of cytokines, which activate macrophages and induce a storm of cytokine production from these macrophages, thus resulting in VAHS. The HVP-infected cells with immunogenic virus-related antigens that are recognized by cytotoxic T-cells may be excluded. The T-cells with latency type I/II infection can thus escape from host immunity and take advantage of proliferation, subsequently progressing to become neoplastic clones. Alternatively, disorders of the cytotoxic T-cell response may be caused by HVP-infected rabbit CD8 cells themselves. Further studies, including *in vitro* transformation experiments of rabbit lymphocytes, are needed to address these questions.

The clinicopathological features of this rabbit model are very similar to those of fatal childhood EBV-AHS with T-cell LPD (Su et al., 1994, 1995) or fulminant EBV-positive T-cell LPD following acute/chronic EBV infection (Quintanilla-Martinez et al., 2000). We therefore suggest that this rabbit model of fatal LPD with VAHS, induced by a primary HPV infection, represents a reasonable animal model for fulminant EBV-positive T-cell LPD with VAHS due to primary EBV infection. It may also become the first animal model of "hit and run" oncogenesis by gammaherpesvirus. In view of the scarcity and expense of non-human primates, these rabbit models are very useful and an inexpensive alternative experimental model for the study of human EBV-AHS pathogenesis, prevention, and treatment.

Acknowledgements: We are very grateful to Ms Reiko Endo, Ms Yoshiko Sakamoto, Ms Hiromi Nakamura, Ms Rika Watanabe, Ms Mutsumi Okabe, and Ms Miyuki Shiotani, Department of Pathology, Okayama University Medical School, and also to Mr. Hiroshi Okamoto and Ms Ai Tomosada, the Central Research Laboratory, Okayama University Medical School. This study was partially supported by grants from the Ministry of Education, Science, Sports, and Culture (11470058 and 14570190), Japan.

References

- Ambinder R.F. (2000). Gammaherpesviruses and "hit-and-run" oncogenesis. *Am. J. Pathol.* 156, 1-3.
- Anagnostopoulos I. and Hummel M. (1996). Epstein-Barr virus in tumours. *Histopathology* 29, 297-315.
- Callan M.F., Steven N., Krausa P., Wilson J.D., Moss P.A., Gillespie G.M., Bell J.I., Rickinson A.B. and McMichael A.J. (1996). Large clonal expansions of CD8+ T cells in acute infectious mononucleosis. *Nat. Med.* 2, 906-911.
- Chang K.L., Chen Y.Y., Shibata D and Weiss L.M (1992). Description of an *in situ* hybridization methodology for detection of Epstein-Barr virus RNA in paraffin-embedded tissues, with a survey of normal and neoplastic tissues. *Diagn. Mol. Pathol.* 1, 246-255.
- Chen H-L., Hayashi K., Koirala T.R., Ino H., Fujimoto K., Yoshikawa Y., Choudhury C.R. and Akagi T. (1997). Malignant lymphoma induction in rabbits by oral inoculation of crude virus fraction prepared from Ts-B6 cells (Cynomolgus B-lymphoblastoid cells harboring Epstein-Barr virus-related simian herpesvirus). *Acta Med. Okayama* 51,141-147.
- Chen J.S., Tzeng C.C., Tsao C.J., Su W.C., Chen T.Y., Jung Y.C. and Su I.J. (1997). Clonal karyotype abnormalities in EBV-associated hemophagocytic syndrome. *Haematologica* 82, 572-576.
- Cheng A.L., Su I.J., Chen Y.C., Uen W.C. and Wang C.H. (1993). Characteristic clinicopathologic features of Epstein-Barr virus-associated peripheral T-cell lymphoma. *Cancer* 72, 909-916.
- Craig F.E., Clare C.N., Sklar J.L., and Banks P.M. (1992). T-cell lymphoma and the virus-associated hemophagocytic syndrome. *Am. J. Clin. Pathol.* 97, 189-194.
- Dolezal M.V., Kamel O.W., van de Rijn M., Cleary M.L., Sibley R.K. and Warnke R.A. (1995). Virus-associated hemophagocytic syndrome characterized by clonal Epstein-Barr virus genome. *Am. J. Clin. Pathol.* 103, 189-194.
- Ellis M. and Lishner M. (1993). Second malignancies following treatment in non-Hodgkin's lymphoma. *Leuk. Lymphoma* 9, 337-342.
- Epstein M.A., Achong B.G. and Barr Y.M. (1964). Virus particles in cultured lymphoblasts from Burkitt's lymphoma. *Lancet* 1, 702-703.
- Falk L.A. (1979). A review of Herpesvirus papio, a B-lymphotropic virus of baboons related to EBV. *Comp. Immun. Microbiol. Infect. Dis.* 2, 257-264.
- Favara B.E. (1992). Hemophagocytic lymphohistiocytosis: a hemophagocytic syndrome. *Semin. Diagn. Pathol.* 9, 63-74.
- Fisman D.N. (2000). Hemophagocytic syndromes and infection. *Emerg. Infect. Dis.* 6, 601-8.
- Franken M., Devergne O., Rosenzweig M., Annis B., Kieff E. and Wang F. (1996). Comparative analysis identifies conserved tumor necrosis factor receptor-associated factor 3 binding sites in the human and simian Epstein-Barr virus oncogene LMP1. *J. Virol.* 70, 7819-7826
- Fuentes-Panana E.M., Swaminathan S. and Ling P.D. (1999). Transcriptional activation signals found in the Epstein-Barr virus (EBV) latency C promoter are conserved in the latency C promoter sequences from baboon and Rhesus monkey EBV-like lymphocryptoviruses (cercopithecine herpesviruses 12 and 15). *J. Virol.* 73, 826-833.
- Gaffey M.J., Frierson H.F. Jr, Medeiros L.J. and Weiss L.M. (1993). The relationship of Epstein-Barr virus to infection-related (sporadic) and familial hemophagocytic syndrome and secondary (lymphoma-related) hemophagocytosis: an *in situ* hybridization study. *Hum. Pathol.* 24, 657-667
- Gan Y.J., Razzouk B.I., Su T. and Sixbey J.W. (2002). A defective,

Therapy using a rabbit model for EBV-AHS

- rearranged Epstein-Barr virus genome in EBV-negative and EBV-positive Hodgkin's disease. *Am. J. Pathol.* 160, 781-786.
- Gilligan K., Rajadurai P., Resnick L. and Raab-Traub N. (1990) Epstein-Barr virus small nuclear RNAs are not expressed in permissively infected cells in AIDS-associated leukoplakia. *Proc. Natl. Acad. Sci. USA* 87, 8790-8794.
- Greifenegger N., Jager M., Kunz-Schughart L.A., Wolf H. and Schwarzmann F. (1998). Epstein-Barr virus small RNA (EBER) genes: differential regulation during lytic viral replication. *J. Virol.* 72, 9323-9228.
- Hayashi K., Ohara N., Koirala T.R., Ino H., Chen H.L., Teramoto N., Kondo E., Yoshino T., Takahashi K., Yamada M., Tomita N., Miyamoto K., Fujimoto K., Yoshikawa Y. and Akagi T. (1994). HTLV-II non-integrated malignant lymphoma induction in Japanese white rabbits following intravenous inoculation of HTLV-II-infected simian leukocyte cell line (Si-IIA). *Jpn. J. Cancer Res.* 85, 808-818.
- Hayashi K., Koirala T., Ino H., Chen H-L., Ohara N., Teramoto N., Yoshino T., Takahashi K., Yamada M., Nii S., Miyamoto K., Fujimoto K., Yoshikawa Y. and Akagi T. (1995). Malignant lymphoma induction in rabbits by intravenous inoculation of Epstein-Barr-virus-related herpesvirus from HTLV-II-transformed cynomolgus leukocyte cell line (Si-IIA). *Int. J. Cancer* 63, 872-880.
- Hayashi K., Chen H-L., Yanai H., Koirala T.R., Ohara N., Teramoto N., Oka T., Yoshino T., Takahashi K., Miyamoto K., Fujimoto K., Yoshikawa Y. and Akagi T. (1999). Cyno-EBV (EBV-related herpesvirus from cynomolgus macaques) induces rabbit malignant lymphomas and their tumor cell lines frequently show specific chromosomal abnormalities. *Lab. Invest.* 79, 823-835
- Hayashi K. and Akagi T. (2000). An animal model for Epstein-Barr virus (EBV)-associated lymphomagenesis in the human: Malignant lymphoma induction of rabbits by EBV-related herpesvirus from cynomolgus. *Pathol. Int.* 50, 85-97.
- Hayashi K., Ohara N., Teramoto N., Onoda S., Chen H.L., Oka T., Kondo E., Yoshino T., Takahashi K., Yates J. and Akagi T. (2001). An animal model for human EBV-associated hemophagocytic syndrome: herpesvirus papio frequently induces fatal lymphoproliferative disorders with hemophagocytic syndrome in rabbits. *Am. J. Pathol.* 158, 1533-1542.
- Hayashi K., Teramoto N. and Akagi T. (2002). Animal in vivo models of Epstein-Barr virus-related Diseases. Special reference to rabbit models. *Histol. Histopathol.* 17, 1293-1310,
- Hayashi K., Jin Z-S., Onoda S., Joko H., Teramoto N., Ohara N., Oda W., Tanaka T., Liu Y-X., Koirala T.R., Oka T., Kondo E., Yoshino T., Takahashi K. and Akagi T. (2003). Rabbit model for Human EBV-associated Hemophagocytic Syndrome (HPS): Sequential autopsy analysis and characterization of IL-2 dependent cell lines established from Herpesvirus papio-induced fatal rabbit lymphoproliferative diseases with HPS. *Am. J. Pathol.* 62, 1721-1736.
- Howe J.G. and Shu M.D. (1988). Isolation and characterization of the genes for two small RNAs of herpesvirus papio and their comparison with Epstein-Barr virus-encoded EBER RNAs. *J. Virol.* 62, 2790-2798.
- Imashuku S., Hibi S., Ohara T., Iwai A., Sako M., Kato M., Arakawa H., Sotomatsu M., Kataoka S., Asami K., Hasegawa D., Kosaka Y., Sano K., Igarashi N., Maruhashi K., Ichimi R., Kawasaki H., Maeda N., Tanizawa A., Arai K., Abe T., Hisakawa H., Miyashita H. and Henter J.I. (1999a). Effective control of Epstein-Barr virus-related hemophagocytic lymphohistiocytosis with immunochemotherapy. *Blood* 93, 1869-74.
- Imashuku S., Hibi S., Todo S., Sako M., Inoue M., Kawa K., Koike K., Iwai A., Tsuchima S., Akiyama Y., Kotani T., Kawamura Y., Hirose M., Hasegawa D., Kosaka Y., Yamaguchi H., Ishii E., Kato K., Ishii M. and Kigasawa H. (1999b). Allogeneic hematopoietic stem cell transplantation for patients with hemophagocytic syndrome (HPS) in Japan. *Bone Marrow Transplant.* 23, 569-572.
- Imashuku S. (2002). Clinical features and treatment strategies of Epstein-Barr virus-associated hemophagocytic lymphohistiocytosis. *Crit. Rev. Oncol. Hematol.* 44, 259-272.
- Ito E., Kitazawa J., Arai K., Otomo H., Endo Y., Imashuku S. and Yokoyama M. (2000). Fatal Epstein-Barr virus-associated hemophagocytic lymphohistiocytosis with clonal karyotype abnormality. *Int. J. Hematol.* 71, 263-265.
- Jenson H.B., Ench Y., Gao S.J., Rice K., Carey D., Kennedy R.C., Arrand J.R and Mackett M. (2000). Epidemiology of herpesvirus papio infection in a large captive baboon colony: similarities to Epstein-Barr virus infection in humans. *J. Infect. Dis.* 181, 1462-1466.
- Kasahara Y., Yachie A., Takei K., Kanegane C., Okada K., Ohta K., Seki H., Igarashi N., Maruhashi K., Katayama K., Katoh E., Terao G., Sakiyama Y. and Koizumi S. (2001). Differential cellular targets of Epstein-Barr virus (EBV) infection between acute EBV-associated hemophagocytic lymphohistiocytosis and chronic active EBV infection. *Blood.* 98, 1882-1888.
- Kawa K. (2000). Epstein-Barr virus-associated diseases in humans. *Int. J. Hematol.* 71, 108-117
- Kikuta H., Sakiyama Y., Matsumoto S., Oh-Ishi T., Nakano T., Nagashima T., Oka T., Hironaka T. and Hirai K. (1993). Fatal Epstein-Barr virus-associated hemophagocytic syndrome. *Blood* 82, 3259-3264.
- Kikuta H. (1995). Epstein-Barr virus-associated hemophagocytic syndrome. *Leuk Lymphoma.* 16, 425-429.
- Koirala T.R., Hayashi K., Chen H-L., Ino H., Kariya N., Yanai H., Choudhury C.R. and Akagi T. (1997). Malignant lymphoma induction of rabbits with oral spray of Epstein-Barr virus-related herpesvirus from Si-IIA cells (HTLV-II-transformed Cynomolgus cell line): A possible animal model for Epstein-Barr virus infection and subsequent virus-related tumors in humans. *Pathol. Int.* 47, 442-448.
- Lay J.D., Tsao C.J., Chen J.Y., Kadin M.E. and Su I.J. (1997). Upregulation of tumor necrosis factor-alpha gene by Epstein-Barr virus and activation of macrophages in Epstein-Barr virus-infected T cells in the pathogenesis of hemophagocytic syndrome. *J. Clin. Invest.* 100, 1969-1979.
- Leone G., Mele L., Pulsoni A., Equitani F. and Pagano L. (1999). The incidence of secondary leukemias. *Haematologica* 84, 937-945
- Ling P.D., Ryon J.J. and Hayward S.D. (1993). EBNA-2 of herpesvirus papio diverges significantly from the type A and type B EBNA-2 proteins of Epstein-Barr virus but retains an efficient transactivation domain with a conserved hydrophobic motif. *J. Virol.* 67, 2990-3003.
- Mroczek E.C., Weisenburger D.D., Grierson H.L., Markin R. and Purtilo D.T. (1987). Fatal infectious mononucleosis and virus-associated hemophagocytic syndrome. *Arch. Pathol. Lab. Med.* 111, 530-535.
- Nagata H., Numata T., Konno A., Mikata I., Kurasawa K, Hara S., Nishimura M., Yamamoto K. and Shimizu N. (2001) Presence of natural killer-cell clones with variable proliferative capacity in chronic active Epstein-Barr virus infection. *Pathol. Int.* 51, 778-785.
- Okano M. and Gross T.G. (1996). Epstein-Barr virus-associated

- hemophagocytic syndrome and fatal infectious mononucleosis. *Am. J. Hematol.* 53, 111-115.
- Okano M. (2002). Overview and problematic standpoints of severe chronic active Epstein-Barr virus infection syndrome. *Crit. Rev. Oncol. Hematol.* 44, 273-282.
- Quintanilla-Martinez L., Kumar S., Fend F., Reyes E., Teruya-Feldstein J., Kingma D.W., Sorbara L., Raffeld M., Straus S.E. and Jaffe E.S. (2000). Fulminant EBV (+) T-cell lymphoproliferative disorder following acute/chronic EBV infection: a distinct clinicopathologic syndrome. *Blood* 96, 443-451.
- Razzouk B.I., Srinivas S., Sample C.E., Singh V. and Sixbey J.W. (1996). Epstein - Barr virus DNA recombination and loss in sporadic Burkitt's lymphoma. *J. Infect. Dis.* 173, 529-35.
- Rickinson A.B. and Kieff E. (2001). Epstein-Barr virus. *Fields virology.* Knipe D.M. and Howley P.M. (eds). Philadelphia, Lippincott Williams & Wilkins, 2001. pp 2575-2627.
- Srinivas S.K., Sample J.T. and Sixbey J.W. (1998). Spontaneous loss of viral episomes accompanying Epstein-Barr virus reactivation in a Burkitt's lymphoma cell line. *J. Infect. Dis.* 177, 1705-1709.
- Staratschek-Jox A., Kotkowski S., Belge G., Rudiger T., Bullerdiek J., Diehl V. and Wolf J. (2000). Detection of Epstein-Barr virus in Hodgkin-Reed-Sternberg cells : no evidence for the persistence of integrated viral fragments in latent membrane protein-1 (LMP-1)-negative classical Hodgkin's disease. *Am. J. Pathol.* 156, 209-216.
- Su I.J., Hsu Y.H., Lin M.T., Cheng A.L., Wang C.H. and Weiss L.M. (1993). Epstein-Barr virus-containing T-cell lymphoma presents with hemophagocytic syndrome mimicking malignant histiocytosis. *Cancer* 72, 2019-2027.
- Su I.J., Chen R.L., Lin D.T., Lin K.S. and Chen C.C. (1994). Epstein-Barr virus (EBV) infects T lymphocytes in childhood EBV-associated hemophagocytic syndrome in Taiwan. *Am. J. Pathol.* 144, 1219-1225.
- Su I.J., Wang C.H., Cheng A.L. and Chen R.L. (1995). Hemophagocytic syndrome in Epstein-Barr virus-associated T-lymphoproliferative disorders: disease spectrum, pathogenesis, and management. *Leuk. Lymphoma* 19, 401-406.
- Sugawara Y., Mizugaki Y., Uchida T., Torii T., Imai S., Makuuchi M. and Takada K. (1999). Detection of Epstein-Barr virus (EBV) in hepatocellular carcinoma tissue: a novel EBV latency characterized by the absence of EBV-encoded small RNA expression. *Virology* 256, 196-202.
- Varady E., Deak B., Molnar Z.S., Rosta A., Schneider T., Esik O. and Eckhardt S. (2001). Second malignancies after treatment for Hodgkin's disease. *Leuk. Lymphoma.* 42, 1275-1281.
- Weiss L.M., Movahed L.A., Warnke R. and Sklar J. (1989). Detection of Epstein-Barr viral genomes in Reed-Sternberg cells of Hodgkin's disease. *N. Engl. J. Med.* 320, 502-506.
- Weiss L.M. and Chang K.L. (1996). Association of the Epstein-Barr virus with hematolymphoid neoplasia. *Adv. Anat. Pathol.* 3, 1-15.
- Yagita M., Iwakura H., Kishimoto T., Okamura T., Kunitomi A., Tabata R., Konaka Y. and Kawa K. (2001). Successful allogeneic stem cell transplantation from an unrelated donor for aggressive Epstein-Barr virus-associated clonal T-cell proliferation with hemophagocytosis. *Int. J. Hematol* 74, 451-454.
- Yamashita S., Murakami C., Izumi Y., Sawada H., Yamazaki Y., Yokota T.A., Matsumoto N. and Matsukura S. (1998). Severe chronic active Epstein-Barr virus infection accompanied by virus-associated hemophagocytic syndrome, cerebellar ataxia and encephalitis. *Psychiatry Clin. Neurosci.* 52, 449-452
- Yates J.L., Camiolo S.M., Ali S. and Ying A. (1996). Comparison of the EBNA1 proteins of Epstein-Barr virus and herpesvirus papio in sequence and function. *Virology* 222, 1-13.

Accepted June 16, 2003