

## Adenomatous hyperplasia of the *rete testis*. A review and report of new cases

M. Nistal<sup>1,2</sup>, M.C. Castillo<sup>1</sup>, J. Regadera<sup>2</sup> and M.A. García-Cabezas<sup>1,2</sup>

<sup>1</sup>Department of Pathology, La Paz University Hospital, Madrid and

<sup>2</sup>Department of Morphology, School of Medicine, University Autonoma of Madrid

**Summary.** Adenomatous hyperplasia of the *rete testis* (AHRT) is an uncommon benign lesion that preferentially involves the septal *rete testis* and mediastinal *rete testis*. It is usually an incidental finding in surgical specimens from cryptorchidism and testicular tumour. It can be found in autopsy specimens from patients dying with different chronic diseases and newborns with kidney diseases. Since its first description many articles have been published communicating new cases and putting forward some hypotheses on its aetiology and pathogenic mechanisms. Some authors suggest a role for hormonal changes, tumour invasion and action of chemical agents. We think that AHRT should be categorised into two main aetiological categories: congenital and acquired. The cases associated with different kidney and spermatic duct diseases, most cases associated with cryptorchidic testis and some cases associated with testicular germ cell tumour should be included in the congenital group. The remaining cases associated with chemical agents, some hormonal changes (i.e. androgen blockade) and most of the germ cell tumour cases can be considered as acquired AHRT. Differential diagnosis must be established mainly with metastatic adenocarcinoma of prostate to testis and primary adenocarcinoma of the *rete testis*. Pseudohyperplasia of the *rete testis* must also be considered in atrophic testes. Here we review the papers published on this subject and report our recent cases.

**Key words:** *Rete testis*, Cryptorchidism, Hyperplasia, Adenoma, Testicular tumour

### Introduction

The term adenomatous hyperplasia of the *rete testis* (AHRT) was first used by Nistal et al. (1976) in an article on cystic dysplasia of the testis. They described,

seated in the testicular mediastinum, an epithelial proliferation made up of numerous tubular structures of variable size, separated by scant stroma that extended peripherally into the testicular parenchyma. This observation was made in a newborn showing bilateral kidney dysplasia. The authors diagnosed this histological finding as being a hamartomatous lesion and a noncystic variant of testicular dysplasia. They explained the absence of cysts due to a better connection between genital ridge derivatives and mesonephric ducts.

The first adult case of AHRT was reported twelve years later by Nistal and Paniagua (1988), again as an autopsy finding, in a 55-year-old patient who died due to meningeal carcinomatosis secondary to an infiltrating ductal breast carcinoma. They found bilateral *rete testis* (RT) replaced by a tubular, glandular and papillary proliferation whose cells bore great similarity to normal epithelial RT cells. The lesion was in continuity with both the branching channels of the RT and the *tubuli recti*. Further autopsy findings were bronchioloalveolar carcinoma and left adrenocortical adenoma. The authors pointed out the main differential diagnoses of this lesion: metastatic adenocarcinoma of prostate to testis and primary adenocarcinoma of the RT. They also proposed a pathogenic mechanism based on the influence of local factors stemming from either the seminiferous tubules or the RT epithelial cells themselves. They related these factors to the chemotherapy given for treatment of the breast carcinoma, due to the action of chemical agents permeable to the blood-testis barrier.

Soon after, a third AHRT case was published by Channer and MacIver (1989). These authors reported a case of metastasis from a prostate adenocarcinoma to the RT and another case of unilateral AHRT in two male patients aged 77 and 79 years, respectively. They established the AHRT differential diagnosis based on morphological (small glands lined by simple epithelium, lack of atypia) and immunohistochemical (lack of Prostatic Specific Antigen -PSA- and Prostatic Acid Phosphatase -PAP- labelling) features. In addition to being unilateral in nature, these cases showed another difference as compared to Nistal and Paniagua's adult case: the absence of intraluminal spermatozoa.

Cooper and Govender (1990) reported the first series of AHRT. They studied 13 cases associated with cryptorchidism. They found multiple foci of micronodular tubules or papillary structures supported by a thin lamina propria involving the septal region of the RT. The testicular parenchyma showed hypospermatogenesis. These authors suggested that the differential diagnosis should include the benign papillary adenoma, aside from metastatic adenocarcinoma of prostate to testis and primary adenocarcinoma of the RT. Concerning the pathogenic mechanisms underlying the lesion, the authors stressed that its presence within undescended testes supported Nistal and Paniagua's hypothesis, according to which testicular fluid disturbance was responsible for the initiation of glandular proliferation.

Ulbright and Gerssel (1991) documented the association of AHRT with various types of neoplasias of the testis and hyaline globule formation in the cytoplasm of RT cells. Their series consisted of 31 cases of normal RT, 9 of RT with hyaline globules and 11 of RT with hyaline globules and AHRT. Of the 11 cases of RT with hyaline globules and AHRT, 7 were associated with mixed germ-cell tumour and 4 with seminoma. Of the 20 cases associated with hyaline globule formation, 19 showed the presence of tumour adjacent to the RT or *tubuli recti*, and 13 cases showed RT and *tubuli recti* tumour invasion with intraluminal tumour cells. Of the 15 cases not showing RT anomalies, 11 presented adjacent tumour, with 2 cases of pagetoid spread and 1 with RT tumour invasion. The authors suggested that both the cytoplasmic hyaline globule accumulation and AHRT seemed to be the result of the RT neoplastic invasion. They attributed the absence of identifiable invasion noted in some cases to deficient sampling. They also suggested that the main differential diagnosis should include yolk sac tumour, which may show intracytoplasmic hyaline globules and microcystic pattern.

Hartwick et al. (1991) published a clinico-pathological series consisting of 9 cases of AHRT with different diagnoses: from cryptorchidism to embryonic carcinoma through epididymal and tuberculous orchitis. They expanded the differential diagnoses to other benign (testicular Pick's adenoma or Sertoli cell tumour, epididymal cystadenoma, adenomatoid tumour, reactive mesothelial hyperplasia of the *tunica vaginalis*, benign papillary mesothelioma) and malignant (epididymal carcinoma, borderline malignant serous papillary tumour, malignant mesothelioma) conditions. The authors also provided further pathogenic evidence supporting the hormonal imbalance hypothesis (one of the patients had received diethylstilbestrol and androgenic blockers) and other evidences against the chemical agent action hypothesis.

In 1992, Butterworth and Bisset studied 200 orchietomy cases, 110 for cryptorchidic and atrophic testes, two for tumour and the remaining ones for normal testes. The authors recognized 16 cases of cribriform

intra-tubular epididymal change. Ten of these 16 cases were associated with AHRT. The authors hypothesized that AHRT was the result of hormonal imbalance since it was frequently associated with testis atrophy and hypospermatogenesis in their series and the literature.

Lee and Theaker (1994) reported a series of 71 orchietomy specimens: 47 for untreated germ cell tumour, 18 for germ cell tumour previously treated with chemotherapy and 6 for tumours other than germ cell tumour. Pagetoid spread was noted in 14 of the 47 cases with germ cell tumour. AHRT was found in 6 cases: 1 with untreated germ cell tumour and pagetoid spread, 2 with untreated intratubular germ cell neoplasia (IGCN) and pagetoid spread, 1 with germ cell tumour and IGCN without pagetoid spread, and 2 with cell germ tumour and IGCN without pagetoid spread previously treated with chemotherapy. The authors discussed the different pathogenic hypotheses of AHRT (atrophy, hypospermatogenesis, hormonal effects, cryptorchidism, tumour invasion) and also added pagetoid spread by malignant cells.

Perry and Albores-Saavedra (1994), replying to a letter from the latter authors, reported two further cases of AHRT associated with IGCN without pagetoid spread. This fact led them to detract the hypothesis that pagetoid spread is a causal factor for AHRT.

Hasan et al. (1995) reported the case of a 24-year-old male who had undergone orchietomy for left-sided cryptorchidism. Cryptorchidic lesions, IGCN, pagetoid spread and AHRT were found. The authors agreed with Lee and Theaker (1994) that pagetoid spread might be a causal mechanism.

Of interest was a report by Gruber et al. (1997). The authors reported the case of a 55-year-old male patient who had undergone surgery for a left fibrotic hydrocele. Ten years later he was diagnosed of primary adenocarcinoma of the RT. AHRT was diagnosed re-examining the fibrotic hydrocele sample. The patient was a fireman and had been exposed to multiple chemical agents. To date this is the only case of primary adenocarcinoma of the RT associated with AHRT published in the medical literature. The authors recommended follow-up of patients with AHRT.

Nistal and Jiménez-Heffernan (1997) reported a series of cryptorchidic testes describing the RT lesions. The authors defined three types of RT dysgenesis: diffuse hypoplastic (37.5%), hypoplastic-cystic (50%) and adenomatous pseudohyperplastic (12.5%). The latter lesion morphologically corresponds to AHRT, as pointed out by Jones et al. (2000).

Jones et al. (2000) reviewed all the cases of cysts and proliferations involving the testes, including RT, published in the literature. The most common associations with AHRT were testicular atrophy and hypospermatogenesis, cryptorchidism, epididymal cribriform change (so called "hyperplasia" by Butterworth and Bisset in 1992), bilateral kidney dysplasia, breast carcinoma and germ cell tumour with or without pagetoid spread or stromal invasion of the RT.

## Hyperplasia of the rete testis

**Table 1.** Our own AH RT cases.

CASES	AGE	CLINICAL DIAGNOSIS	TESTICULAR LESIONS
<i>Biopsy</i>			
1	20 y.	Cryptorchidism	Mixed testicular atrophy, granular changes in Sertoli cells
2	36 y.	Cryptorchidism, infertility	Tubular hyalinization, incomplete spermatogonia arrest
3	56 y.	Cryptorchidism	Tubular hyalinization
4	19 y.	Cryptorchidism	Mixed testicular atrophy, granular changes in sertoli cells
5	8 y.	Cryptorchidism	Absence of germ cells
6*	21 y.	Cryptorchidism	Mixed testicular atrophy, granular changes in Sertoli cells
7*	16 y.	Postmumps orchitis	Testicular atrophy, Sertoli cells only
8*	21 y.	Cryptorchidism	Dysgenetic Sertoli cells only
9*	17 y.	Cryptorchidism	Dysgenetic Sertoli cells only
10*	20 y.	Cryptorchidism	Mixed testicular atrophy
11*	2 m.	Cryptorchidism, cystic fibrosis	Minimal testicular changes
12	3 m.	Cryptorchidism, cystic fibrosis	Minimal testicular changes
13	38 y.	Testicular tumour	Seminoma with IGCN, tubular hyalinization, pagetoid RT spread
14	21 y.	Testicular tumour	Mixed germ cell tumour
15	26 y.	Testicular tumour	Seminoma with syncytial giant cells
16	38 y.	Testicular tumour	Seminoma
<i>Autopsy</i>			
17	74 y.	Rheumatoid arthritis	Atrophic Sertoli cells only
18	20 y.	HIV, chronic hepatitis	Mixed testicular atrophy, Sertoli cells only, interstitial orchitis
19**	55 y.	Breast carcinoma, pulmonar carcinoma, adrenocortical adenoma	Testicular atrophy, hipospermatogenesis
20	72 y.	Urinary bladder carcinoma with prostatic infiltration	Atrophic Sertoli cells only
<i>D.D.</i>			
21	78 y.	Prostate adenocarcinoma	Metastasis in testis, dysgenetic Sertoli cells only
22	67 y.	HIV, non-hodgkin lymphoma	RT pseudohyperplasia
23	67 y.	Testicular tumour	RT adenocarcinoma

D.D.: differential diagnosis. \*: already published by Nistal and Jimenez-Hefferman (1997) \*\*: already published by Nistal and Paniagua (1988). IGCN: intratubular germ cell neoplasm. RT: *rete testis*.

**Table 2.** Diagnostic Criteria for AHRT.

1. Epithelial proliferation with testicular mediastinum expansion
2. Loss of normal <i>rete testis</i> architecture. Solid/glandular Cribriform Papillary pattern
3. Continuity with normal <i>rete testis</i> epithelium
4. Absence of malignant features

On pathogenic mechanisms the authors referred to hormonal imbalance (oestrogenic stimulation, diethylstilbestrol, androgenic blockers, cryptorchidism). Among their own cases, they reported 5 cases of AHRT associated with different conditions.

### Material and methods

#### Subjects

We have reviewed the surgical and autopsy specimens diagnosed of AHRT as well as the corresponding clinical records. We used 26 testes belonging to 20 patients. Table 1 shows patients' age, clinical diagnoses and associated testicular lesions. Three cases of RT anomalies that were thought to be potentially misdiagnosed were included in the present

investigation: RT pseudohyperplasia due to testis atrophy (67-year-old patient), primary adenocarcinoma of the RT (67-year-old patient) and metastatic adenocarcinoma of prostate to testis (78-year-old patient). Eight testes from 4 child patients, 2 mature pubertal testes from 1 patient and 6 testes belonging to 3 adults were used as controls. All these testes came from autopsy. None of these patients had died due to a condition known to alter hormonal imbalance or had undergone a medical treatment suspected to affect testicular function.

#### Tissue preparation

The testicular tissues were fixed in formalin solution. The right child testes were cross sectioned and all the sections were paraffin embedded. The left testes were longitudinally sectioned and a block with both testicular and epididymal parenchyma was carefully paraffin embedded. Three blocks were obtained from each adult testis: two cross sections and one longitudinal section (Fig. 1). Six-micron thick sections were cut and hematoxylin-eosine and Mason's trichromic stained. Three to six histological preparations for each testis were studied. In each case an RT and testicular parenchyma study was performed. AHRT diagnosis criteria, published elsewhere (Nistal and Paniagua, 1988), are summarized in Table 2. To study testicular parenchyma

in child testes we measured the mean seminiferous tubular diameter, the tubular fertility index and the number of germ cells for each seminiferous tubule (Nistal and Paniagua, 1999). To evaluate spermatogenesis in adult testes we measured the tubular diameter of 30 seminiferous tubules and carried out a quantitative analysis of spermatogonia, spermatocytes and young and adult spermatids for each tubular section according to our method described elsewhere (Nistal and Paniagua, 1997). Leydig cells were quantified according to the number of accumulations for each seminiferous tubule (Nistal and Paniagua, 1997). Representative RT samples from case 19 were obtained from formalin-fixed material and embedded in Epon. The 40-nanometer thick sections were enhanced with uranyl acetate and lead citrate for ultrastructural study.

#### Immunohistochemistry

Immunohistochemical staining was conducted in six cases. The testes belonged to a normal newborn, a normal adult and four cases of AHRT. The following antibodies were used: anti-human pankeratin AE1/AE3 (Immunon<sup>®</sup>); anti-vimentin VIM 3B4 (Progen<sup>®</sup>); anti-epithelial membrane antigen, clone E-29 (Dako<sup>®</sup>); anti-human muscle actin, clone HH F35 (Dako<sup>®</sup>); anti-human desmin, clone D33 (Dako<sup>®</sup>), and rabbit anti-cow S-100 (Dako<sup>®</sup>).

## Results

#### Control cases

The RT of the newborn (Fig. 2) is lodged in the testicular mediastinum. It is made up of cord-like structures, most of them lacking lumen, lined by low cube-shaped epithelium. The RT barely experiences changes through childhood. When the individual reaches puberty, coinciding with Sertoli cell maturity, fluid appears inside the lumens. The adult RT occupies Highmore's body of connective tissue within the testicular mediastinum. It has a comma-shaped structure, with its head located at the cephalad testis pole, and consists of three sharply distinctive portions: septal RT, mediastinal RT, and extratesticular RT.

The septal RT corresponds to the *tubuli recti* according to classical terminology (Bannister and Dyson, 1995). It consists of tubular structures of 0,5 to 1 mm in length (Trainer, 1997). One of its ends, which is funnel-shaped, connects with a seminiferous tubule. The opposite one opens onto the mediastinal RT. The epithelium lining the septal RT is cube-shaped, whereas the epithelium fitting the seminiferous duct is made up of high cylindrical cells. These cells, which to some extent resemble Sertoli cells, are not arranged perpendicularly to the basal lamina but they lean in the direction of seminiferous tubule fluid. The seminiferous tubules drain into the septal RT through some 1400 orifices. The end segments located at the upper testicular

parenchyma form a right angle with the *tubuli recti*, while the end segments located at the lower testis parenchyma form a 180° angle. Some seminiferous tubules may open directly onto the mediastinal RT.

The mediastinal RT (Fig. 3) itself is in the testicular mediastinum and consists of different superimposed interconnected cavities. These cavities are lined by two types of epithelium: simple squamous and cylindrical (Fig. 4). These islets of cylindrical cells are most prominent at the angle of the cavities. Both types of cells present similar features, except for their size and shape. They possess nuclei with a nuclear fold, scant organelles, some lysosomes and keratin filaments. On the apical edge, there are some microvilli and a cilium for each cell. On the lateral sides union complexes and some desmosomes can be seen (Fig. 5). The cavities are obliquely crossed by tendinous cords. They are structures consisting of a central axle made up of collagen fibres and lined by RT epithelium. Some capillaries and isolated fibroblasts can be seen in the thickest ones.

The extratesticular RT emerges from the most superficial and cephalad cavities of the mediastinal RT, crosses the tunica albuginea and protrudes into the epididymal head. At this level it is always dilated and forms the *bullae testis* (Bustos-Obregon and Holstein, 1976; Roosen-Runge and Holstein, 1978; Trainer, 1997)

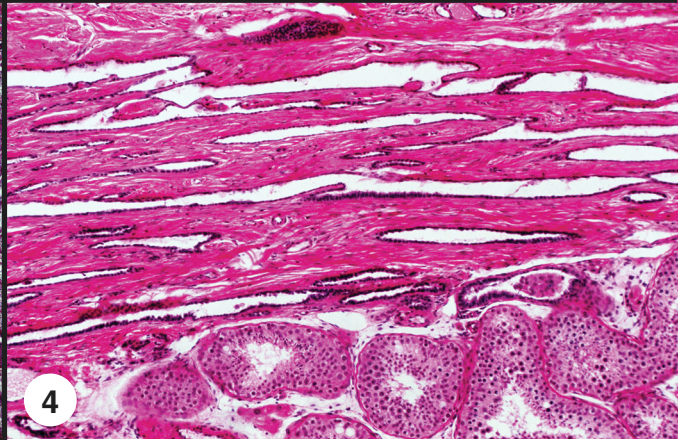
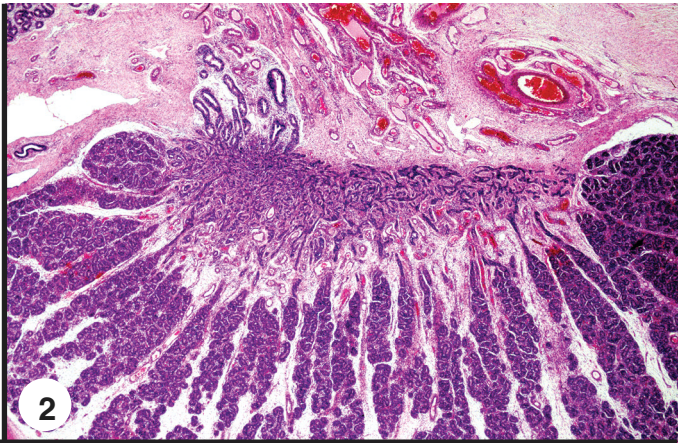
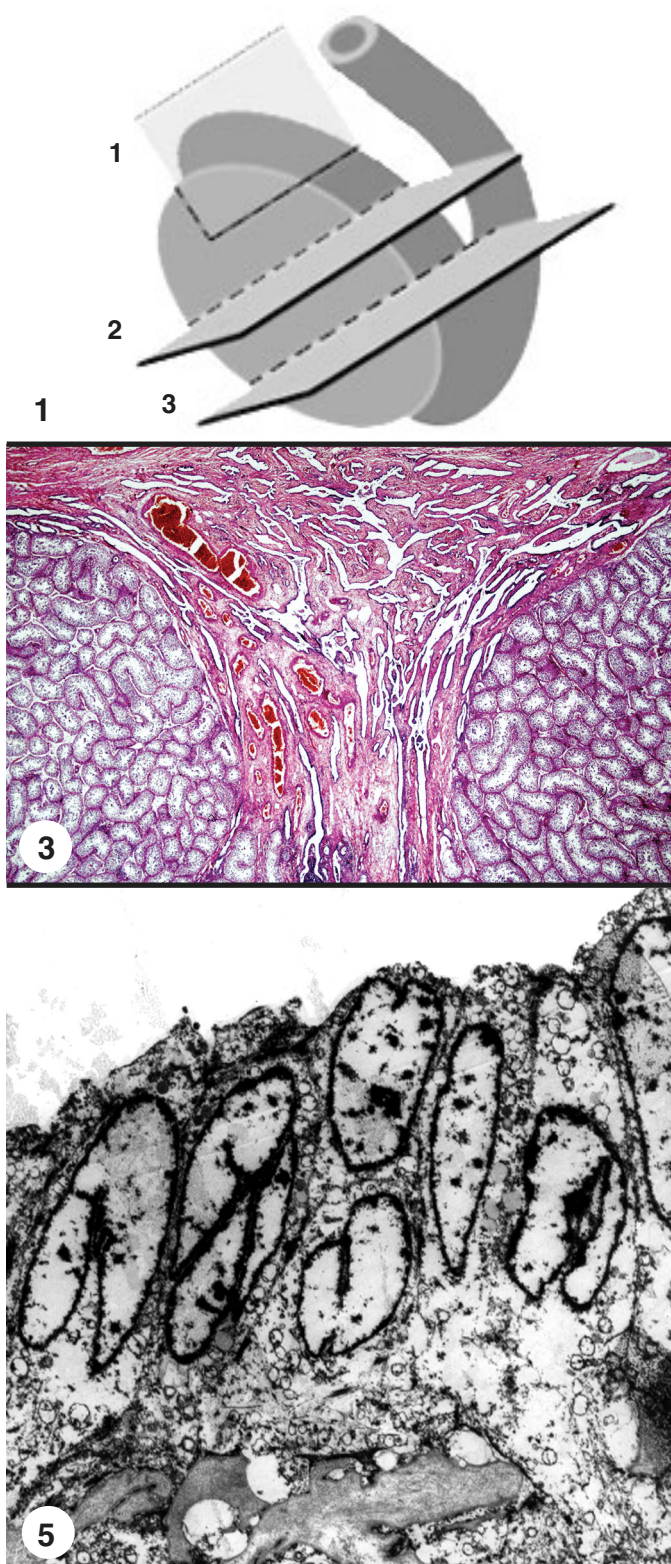
#### AHRT cases

The patients' age varied from childhood to old age; Table 1 shows the most significant clinical data. All the AHRT cases were incidental findings.

In child cases, the AHRT was seen as a solid, cord-like and trabecular proliferation of RT cells with occasional lumen that gave rise to a harmonious thickening of the testicular mediastinum (Figs. 6, 7). Ductal structures close to seminiferous tubules presented slight cystic changes. The proliferation was accompanied by a marked reduction in the connective tissue of the testicular mediastinum. In the newborn cases (cases 11 and 12) the mean tubular diameter was 66 and 67  $\mu\text{m}$ , the testicular fertility index was 73 and 90 and the number of germ cells for each tubule was 1.3 and 2, respectively. We observed a trend for germ cells to group together in adjoining tubules. The epididymis of case number 1 was atrophic. The epididymes of cases 11 and 12 showed small-sized efferent ducts surrounded by loose stroma with non-differentiated muscular layer at the head. The main epididymal duct was hypoplastic. The 8-year-old child's testicular parenchyma (case 5) showed a 34-mm DTM (50% normal diameter) and lack of germ cells; the epididymis was hypoplastic.

In adult testes, the AHRT showed a solid/glandular (Fig. 8), cribriform (Fig. 9) or papillary pattern (Fig. 10). The most affected RT portion was the septal one followed by the mediastinal, with extratesticular RT virtually spared. Epithelial cells were cube-shaped or cylindrical and presented an euchromatic nucleus with

## Hyperplasia of the rete testis



**Fig. 1.** Scheme of testicular gross sections. Slide number 1 includes testicular parenchyma, apical pole of the RT, efferent ducts and head of epididymis. Slide number 2 includes testicular parenchyma, RT and body of the epididymis. Slide number 3 includes testicular parenchyma and tail of epididymis.

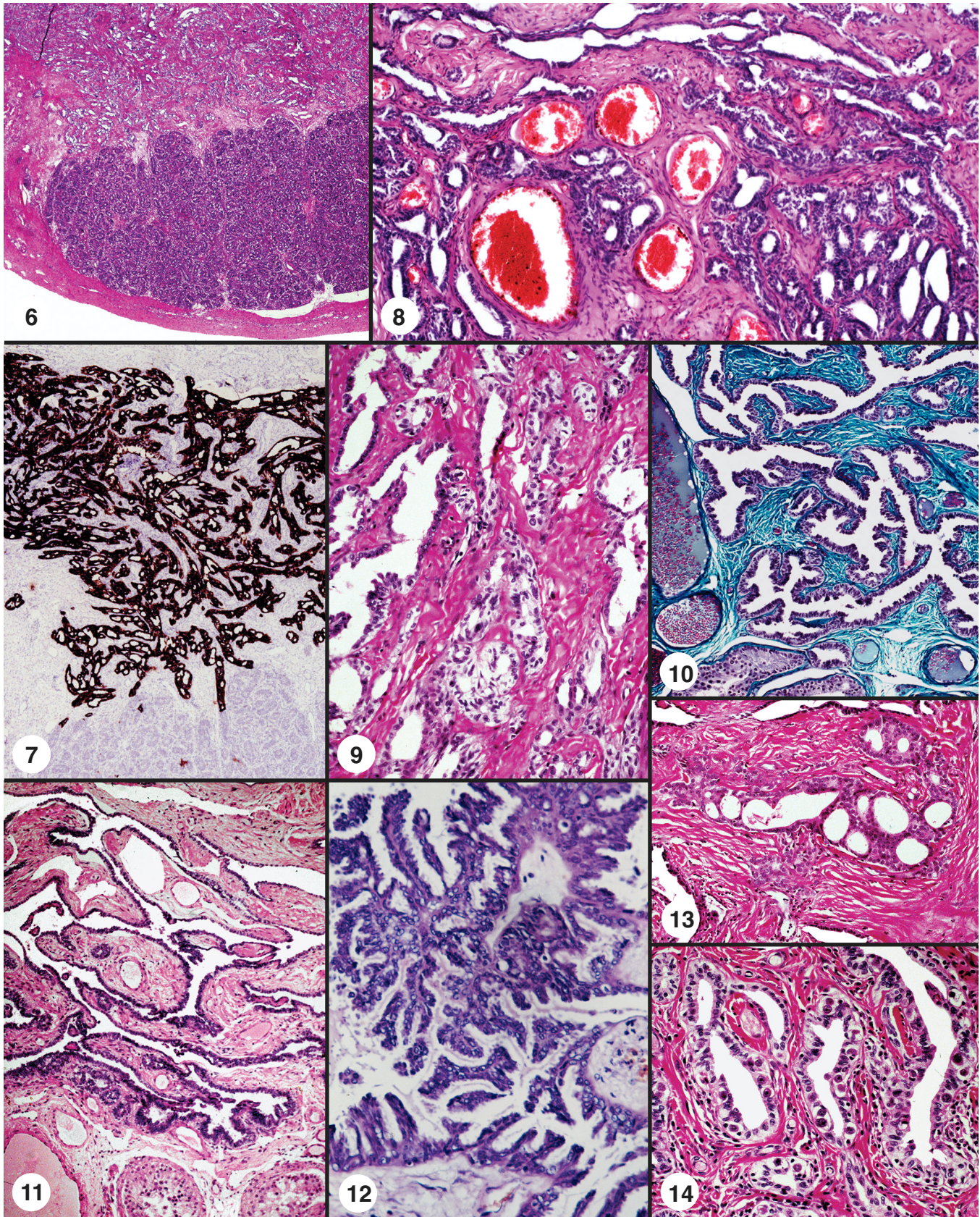
**Fig. 2.** Newborn RT. The RT has a comma shape lodged in the testicular mediastinum. It is made up of cord-like structures, most of them lacking lumen, lined by a low-cube-shaped epithelium. Hematoxylin and eosin. x 2

**Fig. 3.** Panoramic view of adult RT. Mediastinal RT consists of different superimposed interconnected cavities surrounded by Highmore's body connective tissue. Hematoxylin and eosin. x 2

**Fig. 4.** In adults, the RT cavities are lined by two types of epithelium: simple squamous and cylindrical. Hematoxylin and eosin. x 10

**Fig. 5.** RT cells of adult men show nuclear folding, scant organelles, some lysosomes and keratin filaments. Some microvilli can be seen on the apical edge. x 8,000

*Hyperplasia of the rete testis*



## *Hyperplasia of the rete testis*

**Fig. 6.** AHRT in newborn. A solid, cord-like and trabecular proliferation of RT cells gives rise to a harmonious thickening of the testicular mediastinum. Hematoxylin and eosin. x 2

**Fig. 7.** The AHRT of a newborn shows epithelial proliferation, accompanied by a marked reduction in the connective tissue of the testicular mediastinum. Anti AE1/AE3 keratin and Hematoxylin. x 4

**Fig. 8.** Solid/glandular pattern of AHRT in an adult patient. Normal cavities are replaced by numerous gland-like structures lined by a cylindrical epithelium. Hematoxylin and eosin. x 10

**Fig. 9.** Cribriform pattern of AHRT in an adult case. Nests of epithelial cells show multiple gland-like lumens. Hematoxylin and eosin. x 20

**Fig. 10.** Papillary pattern of adult man. Many papillary structures lined by a cylindrical epithelium are seen in the cavities of the RT. Masson trichrome. x 10

**Fig. 11.** Pseudohyperplasia of the RT seen in an atrophic testis of an adult patient. RT cavities are slightly dilated. They form clusters of gland-shaped structures at the septal RT. Hematoxylin and eosin. x 10

**Fig. 12.** Primary adenocarcinoma of the RT. Papillary proliferation lined by an atypical epithelium. Hematoxylin and eosin. x 20

**Fig. 13.** Metastases from a prostate adenocarcinoma. Tumour cells are arranged in well-delimited cribriform nests located between the RT cavities. Hematoxylin and eosin. x 10

**Fig. 14.** AHRT associated to IGCN. Malignant cells infiltrate the hyperplastic RT cavities in a pagetoid fashion. Hematoxylin and eosin. x 20

folds on the karyotheca and pale eosinophilic cytoplasm. No mitoses or nuclear atypias were observed. In a majority of cases a transition between the hyperplastic RT and spared areas could be established. In six cases there were intraluminal spermatozoa, young spermatids and spermatozoa. Connective tissue between the tubular or glandular structures as well as that forming the papillae axle contained thin wall vessels and spindle cells with elongated nuclei and scant cytoplasm. The principal testicular lesions are shown in Table 1. The epididymes were studied in all cases with the following results: normal, 4 cases; atrophic, 4; and hypoplastic, 12.

Ultrastructurally, epithelial cells of the RT showed ovoid nuclei with deep folds. On the apical edge there were isolated microvilli. Numerous interdigitations and desmosomes stood out between one cell and the next. The cytoplasm had low organelle content. Some mitochondrias, lysosomes, and smooth endoplasmic reticulum were noted. Small bundles of intervening filaments arranged in a compact pattern were seen between the nucleus and lateral sides.

Most of the epithelial cells were positive to epithelial markers such as pankeratin (AE1/AE3) and epithelial membrane antigen. Immunoexpression for cytokeratin was intense throughout the cytoplasm, especially on its basal portion. The highest positivity to epithelial membrane antigen was seen at the apical cell membrane. The same positivity was observed on the adjoining areas of the normal RT. Many stromal cells showed immunostain to muscle actin and vimentin. Positivity to desmin and S-100 protein was noted in isolated cells.

### *Differential diagnosis cases*

Testes showing RT pseudohyperplasia (Fig. 11) presented marked seminiferous tubule atrophy, with the special feature of being multicentric in nature.

Hypospermatogenesis was seen in the most spared tubules. The RT cavities were slightly dilated. At the septal RT these cavities became transformed into clusters of gland-shaped formations. The more severe the seminiferous tubule atrophy, the more prominent were such formations. The cells lining these formations were cube-shaped with no nuclear atypias or mitoses. Neither mediastinal nor extratesticular anomalies were seen.

The testis bearing an RT adenocarcinoma (Fig. 12) was 5x4.5x 4 cm in size. On section it showed a whitish non-encapsulated area located in the testicular mediastinum, which extended to the neighbouring testicular parenchyma. The tumour was made up of a proliferation, preferentially papillary in nature, which not only grew toward the RT lumen but infiltrated into the mediastinum and the intertubular interstice. There were some necrotic areas and the mitotic index was high.

The testis with metastases from a prostatic adenocarcinoma showed slightly dilated RT (Fig. 13); however, the epithelium neither presented cube-shaped nor cylindrical metaplasia or formed papillae. Tumour cells were arranged in well-delimited nests located between RT cavities, giving a characteristic cribriform pattern. These cells showed immunostain to both PSA and PAP. On the other hand, an important association of AHRT with cancer was the presence of the pagetoid spread of the IGCN into the RT (Fig. 14).

### **Discussion**

AHRT is a benign lesion characterized by solid/glandular, papillary or cribriform proliferation of the epithelium with self-limited growth. It can appear at any time during the lifespan.

The RT is the first portion of the excretory ducts of the testis. Only in the last decade has this structure

### Hyperplasia of the rete testis

aroused pathologists' interest. The systematic study of surgical and autopsy specimens has enabled us to understand that the RT is prone to react to both local and systemic conditions, which results in tumour-like lesion development. To recognize such lesions is critical in order to make an accurate differential diagnosis of benign/malignant tumours. It will also help to gain a better understanding of the functional interplay between the RT and other genitourinary structures which the former is embryologically related to. (Satoh, 1991; Merchant-Larios et al., 1993; Merchant-Larios and Moreno-Mendoza, 1998; Gilbert, 2000; O'Rahilly and Müller, 2001).

The most frequently reported tumour-like lesions involving the RT include cystic transformation secondary to epididymal obstruction (Nistal et al., 1996b), cystic transformation and calcium oxalate deposits seen in patients undergoing dialysis (Nistal, et al., 1996a), RT hyperplasia with hyaline globule formation in patients diagnosed with tumour of the testis (Ulbright and Gersell, 1991), nodular proliferation of calcifying connective tissue associated with poor or altered peripheral perfusion (Nistal and Paniagua, 1989), RT dysgenesis characteristic of cryptorchidic testes (Nistal and Jimenez-Heffernan, 1997) and AHRT (Nistal

and Paniagua, 1988).

Embryologically, the RT of laboratory animals arises from the mesonephros once sexual cords have been formed. Mesonephric cells migrate into the gonad (Satoh, 1991; Merchant-Larios et al., 1993; Merchant-Larios and Moreno-Mendoza, 1998; Gilbert, 2000; O'Rahilly and Müller, 2001). Such a mesonephric origin explains why many types of RT lesions are often associated with kidney or urinary tract anomalies, as is the case with cystic dysplasia of the testis (Nistal et al., 1984), RT dysgenesis (Nistal and Jimenez-Heffernan, 1997), cystic transformation and calcium oxalate deposits seen in patients undergoing dialysis (Nistal et al., 1996a) and some cases of AHRT (Nistal et al., 1976).

In recent years several series of adult patients with AHRT have been reported (Cooper and Govender, 1990; Hartwick et al., 1991; Ulbright and Gersell, 1991; Butterworth and Bisset, 1992; Lee and Theaker, 1994; Jones et al., 2000). However, the first concern to be addressed is whether or not AHRT has been accurately diagnosed, since basic diagnostic criteria have not been established as yet. As a consequence, the condition is overdiagnosed. Prior to establishing diagnostic criteria, it would be convenient to clear up what AHRT is not.

**Table 3.** Cases of AHRT published by other authors.

AUTHORS	No. CASSES	AGE	CLINICAL DATA	ASSOCIATED TESTICULAR LESIONS
Channer and MacIver 1989	1	79 y.	Prostatic carcinoma, orchiectomy	UR
Cooper and Grovender 1990	13	13 to 36 y. (mean: 23 y.)	Cryptorchidism	Tubular atrophy, hypospermatogenesis
Ulbright and Gersell 1991	11	UR	Germ cell tumour	Hyaline globule formation
Hartwick et al., 1991	9	63 y. 30 y. 66 y. 74 y. 67 y. 53 y. 41 y. 74 y. 66 y.	Testicular torsion Testicular mass Epididymitis Tuberculous orchitis UR Cryptorchidism, embryonal carcinoma Prostatic carcinoma Prostatic carcinoma	Tubular atrophy (7 cases) Hypospermatogenesis (2 cases)
Butterworth and Bisset, 1992	10	15 to 62 y.	Testicular atrophy	Testicular atrophy, hypospermatogenesis, tubular hyalinization
Lee and Theaker, 1994	6	UR	Seminoma (1 case) Teratoma (1 case) IGCN (1 case) Germ cell tumour Post-CT	Pagetoid RT spread (3 cases)
Perry and Albores-Saavedra 1994	2	UR	Germ cell tumour	Non-Pagetoid RT spread
Hasan et al., 1995	1	24 y.	Cryptorchidism	IGCN, Pagetoid RT spread, absence of spermatogenesis
Gruber et al., 1997	1	55 y.	RT adenocarcinoma	Fibrotic hydrocele
Jones et al., 2000	5	75 y. 35 y. 60 y. 34 y. 27 y.	Inguinal hernia Cryptorchidism Cysts in hilum Mixed germ cell tumour Testicular atrophy	Testicular atrophy

UR: unreported data. RT: *rete testis*. IGCN: intratubular germ cell neoplasia. CT: chemotherapy.



### *Hyperplasia of the rete testis*

Among the most frequent conditions associated with AHRT found in the literature, is the testis with marked tubular atrophy secondary to a primary testicular anomaly, like cryptorchidism, and acquired testicular atrophy found during the routine histological study of autopsy specimens. In the former, the RT is composed of a small number of cavities whose epithelium has not developed into normality (i.e., cube-shaped epithelium remains in adulthood without differentiation towards the flat squamous epithelium), accompanied by gland-like straight duct transformation at the septal RT. In some cases it can be accompanied by a small-size cystic transformation at the mediastinal RT. This lesion is primarily an RT hypoplasia and, therefore, it should not be regarded as AHRT (Nistal and Jimenez-Heffernan, 1997). In testes with atrophic seminiferous ducts - whether toxic, ischaemic or hormonal, etc.-, focal or multiple gland-like appearance is also frequently noted at the septal RT and cavities close to the mediastinal RT. This finding stems from the collapse of this portion of RT since seminiferous tubules become atrophic within the testicular mediastinum.

Which are the proper diagnostic criteria for AHRT? Four key findings should be demonstrated: 1) a true epithelial proliferation causing the testicular mediastinum to expand; 2) RT architecture loss followed by the appearance of either gland-like, papillary or cribriform structures replacing the normal flat superimposed cavities with scant content; 3) continuity remaining between the AHRT and the normal RT epithelium, and 4) lack of diagnostic criteria for malignancy (Table 2).

AHRT differential diagnosis should include three different conditions, namely: tumour-like lesions, such as RT cystic transformations with epithelial metaplasia, benign conditions, like adenoma and papillary cystadenoma, and both primary (adenocarcinoma of the RT) and metastatic (adenocarcinoma of the prostate) malignant tumours.

RT cystic transformation is not commonly seen in AHRT testes; however, this lesion may be a coincidental finding with AHRT. Most of RT cystic transformations are related to ageing and are simple in nature (Nistal et al., 1996b). Squamous and columnar epithelial cells are usually seen. Despite the fact that cavities may become collapsed and creased by virtue of aging or tissue shrinking, it is not difficult to be distinguished from AHRT since here the epithelium is flat and true proliferation is lacking. The cause for such a cystic transformation is epididymis head atrophy secondary to upper epididymal artery arteriosclerosis. The same holds true for cystic transformations with metaplastic changes in patients on oestrogens or elderly patients with chronic liver failure (Sapino et al., 1987). In such cases, the epithelium is seen to be high-cube-like or cylindrical; however, no loss of architecture or gland-like, papillary or cribriform proliferation is observed. Differential diagnosis for the third type of cystic transformation (i.e., that combining metaplastic changes and calcium and

oxalate deposition) is even easier since to date the condition has been described uniquely in patients with chronic kidney failure undergoing dialysis (Nistal et al., 1996a). In these cases, testes show the characteristic calcium and oxalate crystals located at the RT and efferent duct unions. If they resemble AHRT, one can be sure that the diagnosis of pseudohyperplasia associated with testicular atrophy is the correct one.

RT benign tumours with growth restricted to the testicular mediastinum are exceedingly rare. Cases of adenoma (Altaffer et al., 1982), benign papillary tumour (Gupta, 1974), cystadenoma (Kosmehl et al., 1989), papillary cystadenoma (Yadav et al., 1969) and Sertoli-like cystadenoma (Jones et al., 2000) of the RT have been reported. All these cases were unilateral in nature. Adenomas and benign papillary tumours are circumscribed small-sized formations with solid appearance composed of an either solid or papillary proliferation whose cube-like cells without atypia strongly resemble the RT lining. Cystadenomas are generally larger than adenomas and benign papillary tumours and may involve the whole RT. The usual type of cystadenoma is exclusively made up of multicystic formations on a fibrous stroma with a cube-like lining epithelium without atypias. The cystadenoma papillar contains thick hoarse papillae lined by cube-shaped or cylindrical cells with no atypias. Sertoli-like cystadenomas show solid areas composed of a proliferation of small cord-like or tubular formations on a hyalinised stroma resembling the nodules of Sertoli cells in cryptorchidic testes (Ulbricht et al., 1999).

The most problematic AHRT differential diagnosis is that with malignant tumours, particularly primary adenocarcinoma of the RT and metastatic adenocarcinoma of prostate. The adenocarcinoma of the RT is defined as a tumour fulfilling histological criteria for malignancy with the following features: 1) absence of histologically similar extratesticular tumour; 2) tumour centered in the testicular mediastinum; 3) morphology incompatible with any other type of testicular or paratesticular tumour; 4) demonstration of a transition between the unaffected RT and the tumour; and 5) a predominantly solid gross appearance (Nochomovitz and Orenstein, 1984). Metastatic tumours most often seen in the RT showing a gland-like or cribriform growth pattern are adenocarcinomas of the prostate (Patel et al., 1989). In some cases the RT is seen to be slightly dilated; however it does not show epithelial proliferation. Tumoral nodules are located between the RT cavities. If in doubt, it is recommended to use immunohistochemical techniques in order to demonstrate PSA and/or PAP staining (Channer and MacIver, 1989).

AHRT aetiology seems to be multiple and is not well understood. On reviewing the literature, one can conclude that there are cases associated with the following conditions: several kidney diseases (Nistal et al., 1976); cryptorchidism (Cooper and Govender, 1990; Hartwick et al., 1991; Butterworth and Bisset, 1992;

Hasan et al., 1995; Nistal and Jimenez-Heffernan, 1997; Jones et al., 2000); and germ cell tumours of the testis (Hartwick et al., 1991; Ulbright and Gersell, 1991; Lee and Theaker, 1994; Perry et al., 1994; Jones et al., 2000). On the other hand, a case of AHRT associated with primary adenocarcinoma of the RT has been reported (Gruber et al., 1997). Finally, AHRT has also been reported in patients diagnosed with different chronic diseases (Nistal and Paniagua, 1988; Channer and MacIver, 1989; Hartwick et al., 1991). Accordingly, AHRT should be categorised into two main aetiological categories: congenital and acquired. The following cases can be included within the category of congenital AHRT: those associated with different kidney and spermatic duct diseases; most cases associated with cryptorchidic testis and some cases associated with testicular germ cell tumour. The remaining cases can be considered as being acquired AHRT.

The following discussion supports the hypothesis of the existence of a type of AHRT congenital in aetiology. Some AHRT cases in newborns show this condition as bilateral in nature and associated with a kidney parenchyma differentiation anomaly (i.e., bilateral kidney dysplasia) (Nistal et al., 1976). The anomaly is likely to stem from a metanephros induction defect due to a faulty mesonephric duct (Glassberg, 2002). Being an embryological derivative dependent on the mesonephros, the RT is also very likely to bear a developmental anomaly presenting as an uncontrolled epithelial proliferation within its cavities. This form of AHRT is likely to be related to a condition described as cystic dysplasia of the testis (Nistal et al., 1984), currently termed cystic dysplasia of the RT (Wojcik et al., 1997).

Concerning AHRT cases associated with cryptorchidism, the hypothesis of a congenital aetiology is also tempting. Patients with cryptorchidism are known in some cases to have both abnormal efferent ducts (derived from mesonephric ducts) and major epididymal duct (derived from Wolf duct) (Koff and Scaletsky, 1990; De Miguel et al., 2001). On the other hand, an anomaly of the spermatic ducts has been described in 36% to 79% of patients with cryptorchidism (Marshall and Shermeta, 1979; Gill et al., 1989; Mollaeian et al., 1994). In addition, histological studies of the RT from adult cryptorchidic testes have shown that in a majority of cases these bear different anomalies in differentiation and maturation. The term dysgenesis has been coined to collectively refer to these anomalies. They are characterised by the persistence of an epithelium resembling that of the child in the adult life. They also show an overall underdevelopment of cavities which, in some cases, are seen to bear a small-sized cystic transformation (i.e., hypoplastic-cystic RT). Within this picture, AHRT is observed at times. Cryptorchidic testes with dysgenetic development showing a true AHRT account for only 12.5% of RT dysgenesis cases. This figure is considerably lower than that suggested by those authors reporting series in which any testes showing tubular formation groups close to each other and lined

by a simple epithelium are included. The latter cases should be considered as being simple hypoplasia of the RT.

AHRT associated with germ cell tumour of the testis presents in two different ways. First, AHRT is seen in the RT that does not show further lesions. Second, AHRT presents in the context of RT infiltration by either direct invasion of the testicular mediastinum by a testis tumour or pagetoid spread (Fig. 14) (Lee and Theaker, 1994; Perry and Albores-Saavedra, 1994; Perry et al., 1994; Hasan et al., 1995). There is considerable evidence to link these two ways to a primary anomaly of the testis. Ten percent of testis tumours are seen in undescended testes (Ulbright et al., 1999). Semen study in patients with cancer of the testis frequently disclose oligozoospermia and even azoospermia (Berthelsen, 1984; Petersen et al., 1999). Study of seminiferous tubules spared by the tumour and IGCN most often reveals faulty spermatogenesis (Ho et al., 1992). On the other hand, a role for hormonal products derived from the tumour or drained by the RT should not be conclusively discarded. AHRT associated with pagetoid spread caused by IGCN seems to be primary in nature since RT pagetoid spread does not usually give rise to AHRT (Perry et al., 1994). The same holds true for AHRT associated with direct tumour invasion of the testicular mediastinum.

Hormonal imbalance has also been implicated in AHRT pathogenesis (Nistal and Paniagua, 1988; Cooper and Govender, 1990; Hartwick et al., 1991; Ulbright and Gersell, 1991; Jones et al., 2000). There is both clinical and experimental evidence suggesting a potential relationship between AHRT and excessive oestrogens. Immunohistochemical studies have revealed the presence of a 29-kDa oestrogen receptor-associated phosphoprotein in RT and efferent duct epithelial cells, suggesting that RT may be an oestrogen-dependent area (Sapino et al., 1987). Experimental studies in the mouse have shown that animals exposed in utero to diethylstilbestrol develop RT epithelium hyperplasia in varying degrees and, in some cases, adenocarcinoma (Newbold et al., 1986). Additionally, transsexuals on oestrogenic therapy ranging from 6 to 96 months have been seen to develop an increase in RT cells and cell stratification changes (Sapino et al., 1987). In addition, patients with chronic liver failure have been reported to develop diffuse RT epithelium transformation into columnar epithelium (Sapino et al., 1987). A case of a patient on diethylstilbestrol for 15 months suffering androgen blockade for 19 months before being diagnosed with AHRT has been reported (Hartwick et al., 1991). A large number of AHRT cases have been described in cryptorchidic testes (Cooper and Govender, 1990; Hartwick et al., 1991; Hasan et al., 1995; Nistal and Jimenez-Heffernan, 1997; Jones et al., 2000) and, though the causes for undescended testes are multiple, one of the most plausible hypotheses is that which holds excessive maternal oestrogen responsible (Hadziselimovic et al., 2000; Nef et al., 2000). It seems

## *Hyperplasia of the rete testis*

reasonable to suggest that excessive maternal oestrogens induce changes in the RT conditioning its development and promoting epithelial proliferation.

On the other hand, a role for a direct pharmacological effect on the RT in the remaining adult AHRT cases does not seem plausible because these patients are treated with a very wide range of drugs (cardiac drugs, diuretics, antibiotics, antifungal agents, cytotoxic chemotherapy) (Hartwick et al., 1991). However, a role for some drugs or their metabolites should not be discarded until further evidence is available. It is a matter of fact that in certain conditions, like kidney failure, the RT is able to eliminate the same products as kidney proximal tubule (Nistal et al., 1996a) because both structures are embryologically related to each other.

In conclusion, AHRT is a benign lesion usually found incidentally, whose main differential diagnoses are testicular metastasis of prostatic carcinoma and primary adenocarcinoma of the RT. AHRT is frequently associated with cryptorchidism and testicular tumours.

---

*Acknowledgements.* We must thank P. Rubio for her technical assistance and J.M. Martín for reviewing the English manuscript. This research has been financed, in part, by the Grant PI 021188 of the Fondo de Investigaciones Sanitarias, the Spanish Ministry of Health, and Grant 08.1/0015.1/2000 from the Comunidad de Madrid, Spain.

---

### References

- Altaffer L.F. 3rd, Dufour D.R., Castleberry G.M. and Steele S.M. Jr. (1982). Coexisting rete testis adenoma and gonadoblastoma. *J. Urol.* 127, 332-335.
- Bannister L.H. and Dyson M.C. (1995). Testis and epididymis. In: Gray's anatomy. 38th ed. Williams P.L. (ed.). Churchill-Livingstone. New York. pp 1852-1853.
- Berthelsen J.G. (1984). Sperm counts and serum follicle-stimulating hormone levels before and after radiotherapy and chemotherapy in men with testicular germ cell cancer. *Fertil. Steril.* 41, 281-286.
- Bustos-Obregon E. and Holstein A. F. (1976). The rete testis in man: ultrastructural aspects. *Cell. Tissue Res.* 175, 1-15.
- Butterworth D.M. and Bisset D.L. (1992). Cribriform intra-tubular epididymal change and adenomatous hyperplasia of the rete testis. A consequence of testicular atrophy? *Histopathology* 21, 435-438.
- Channer J. L. and MacIver A.G. (1989). Glandular changes in the rete testis: metastatic tumour or adenomatous hyperplasia? *J. Pathol.* 157, 81-82.
- Cooper K. and Govender D. (1990). Adenomatous hyperplasia of the rete testis in the undescended testis. *J. Pathol.* 162, 333-334.
- De Miguel M.P., Mariño J.M., Gonzalez-Peramato P., Nistal M. and Regadera J. (2001). Epididymal growth and differentiation are altered in human cryptorchidism. *J. Androl.* 22, 212-225.
- Gilbert S. F. (2000). Developmental biology. Sinauer Associates, Inc., Publishers. Sunderland, Ma. pp 523, 533.
- Gill B., Kogan S., Starr S., Reda E. and Levitt S. (1989). Significance of epididymal and ductal anomalies associated with testicular maldescent. *J. Urol.* 142, 556-558.
- Glassberg K.J. (2002). Normal and abnormal development of the kidney: a clinician's interpretation of current knowledge. *J. Urol.* 167, 2339-2350.
- Gruber H., Ratschek M., Pummer K., Breinl E., Spuller E. and Hubner G. (1997). Adenocarcinoma of the rete testis: report of a case with surgical history of adenomatous hyperplasia of the RT. *J. Urol.* 158, 1525-1526.
- Gupta R.K. (1974). Benign papillary tumour of rete testis. *Indian J. Cancer* 11, 480-481.
- Hadziselimovic F., Geneto R. and Emmons L.R. (2000). Elevated placental estradiol: a possible etiological factor of human cryptorchidism. *J. Urol.* 164, 1694-1695.
- Hartwick R. W., Ro J. Y., Srigley J.R., Ordoñez J.R. and Ayala A.G. (1991). Adenomatous hyperplasia of the rete testis. A clinicopathologic study of nine cases. *Am. J. Surg. Pathol.* 15, 350-357.
- Hasan N.A., Shareef D.S. and Al Jafari M.S. (1995). Pagetoid spread into the rete testis by intratubular germ cell neoplasia in an undescended testis. *Histopathology* 27, 391-392.
- Ho G. T., Gardner H., De Wolf W.C., Loughlin K.R. and Morgentaler A. (1992). Influence of testicular carcinoma on ipsilateral spermatogenesis. *J. Urol.* 148, 821-825.
- Jones E. C., Murray S. K. and Young R.H. (2000). Cysts and epithelial proliferations of the testicular collecting system (including rete testis). *Semin. Diagn. Pathol.* 17, 270-293.
- Koff W. J. and Scaletscky R. (1990). Malformations of the epididymis in undescended testis. *J. Urol.* 143, 340-343.
- Kosmehl H., Langbein L. and Kiss F. (1989). Papillary serous cystadenoma of the testis. *Int. Urol. Nephrol.* 21, 169-174.
- Lee A. H. and Theaker J. M. (1994). Pagetoid spread into the rete testis by testicular tumours. *Histopathology* 24, 385-389
- Marshall F. F. and Shermeta D.W. (1979). Epididymal abnormalities associated with undescended testis. *J. Urol.* 121, 341-343.
- Merchant-Larios H. and Moreno-Mendoza N. (1998). Mesonephric stromal cells differentiate into Leydig cells in the mouse fetal testis. *Exp. Cell. Res.* 244, 230-238.
- Merchant-Larios H., Moreno-Mendoza N. and Buehr M. (1993). The role of the mesonephros in cell differentiation and morphogenesis of the mouse fetal testis. *Int. J. Dev. Biol.* 37, 407-415.
- Mollaiean M., Mehrabi V. and Elahi B. (1994). Significance of epididymal and ductal anomalies associated with undescended testis: study in 652 cases. *Urology* 43, 857-860.
- Nef S., Shipman T. and Parada L.F. (2000). A molecular basis for estrogen-induced cryptorchidism. *Dev. Biol.* 224, 354-361.
- Newbold R.R., Bullock B.C. and McLachlan J.A. (1986). Adenocarcinoma of the rete testis. Diethylstilbestrol-induced lesions of the mouse rete testis. *Am. J. Pathol.* 125, 625-628.
- Nistal M. and Jimenez-Heffernan J.A. (1997). Rete testis dysgenesis. A characteristic lesion of undescended testes. *Arch. Pathol. Lab. Med.* 121, 1259-1264.
- Nistal M. and Paniagua R. (1988). Adenomatous hyperplasia of the rete testis. *J. Pathol.* 154, 343-346.
- Nistal M. and Paniagua R. (1989). Nodular proliferation of calcifying connective tissue in the rete testis: a study of three cases. *Hum. Pathol.* 20, 58-61.
- Nistal M. and Paniagua R. (1997). Non-neoplastic diseases of the testis. In: Urologic surgical pathology. 1st. ed. Bostwick D.G. (ed). Mosby-Year Book Incv. St. Louis, Mi. pp 457-455.
- Nistal M. and Paniagua R. (1999). Testicular biopsy. Contemporary interpretation. *Urol Clin. North. Am.* 26, 555-593.

*Hyperplasia of the rete testis*

- Nistal M., Garcia Villanueva M. and Sanchez J. (1976). Displasia quística del testículo. Anomalía en la diferenciación del parénquima testicular por probable fallo de la conexión entre los conductos de origen mesonéfrico y los cordones testiculares. *Arch. Esp. Urol.* 29, 430-444.
- Nistal M., Regadera J. and Paniagua R. (1984). Cystic dysplasia of the testis. Light and electron microscopic study of three cases. *Arch. Pathol. Lab. Med.* 108, 579-583.
- Nistal M., Jimenez-Heffernan J. A., Garcia-Viera M. and Paniagua R. (1996a). Cystic transformation and calcium oxalate deposits in rete testis and efferent ducts in dialysis patients. *Hum. Pathol.* 27, 336-341.
- Nistal M., Mate A. and Paniagua R. (1996b). Cystic transformation of the rete testis. *Am. J. Surg. Pathol.* 20, 1231-1239.
- Nochomovitz L. E. and Orenstein J. M. (1984). Adenocarcinoma of the rete testis. Case report, ultrastructural observations, and clinicopathologic correlates. *Am. J. Surg. Pathol.* 8, 625-634.
- O' Rahilli R. and Müller F. (2001). *Human embryology and teratology*. 3rd ed. Wiley-Liss, Inc. New York. pp 317-343.
- Patel S. R., Richardson R. L. and Kvols L. (1989). Metastatic cancer to the testes: a report of 20 cases and review of the literature. *J. Urol.* 142, 1003-1005.
- Perry A. and Albores-Saavedra J. (1994). Pagetoid spread of intratubular germ cell neoplasia into the rete testis. *Hum. Pathol.* 25, 1256.
- Perry A., Wiley E. L. and Albores-Saavedra J. (1994). Pagetoid spread of intratubular germ cell neoplasia into rete testis: a morphologic and histochemical study of 100 orchiectomy specimens with invasive germ cell tumours. *Hum. Pathol.* 25, 235-239.
- Petersen P. M., Skakkebaek N. E., Vistisen K., Rorth K. and Giwercman A. (1999). Semen quality and reproductive hormones before orchiectomy in men with testicular cancer. *J. Clin. Oncol.* 17, 941-947.
- Roosen-Runge E.C. and Holstein A.F. (1978). The human rete testis. *Cell. Tissue Res.* 189, 409-433.
- Sapino A., Pagani A., Godano A. and Bussolati G. (1987). Effects of estrogens on the testis of transsexuals: a pathological and immunocytochemical study. *Virchows Arch. (A)*. 411, 409-414.
- Satoh M. (1991). Histogenesis and organogenesis of the gonad in human embryos. *J. Anat.* 177, 85-107.
- Trainer T.D. (1997). Testis and excretory duct system. In: *Histology for pathologists*. 2nd ed. Sternberg S.S. (ed). Lippincott-Raven Publishers. Philadelphia. pp. 1019-1039.
- Ulbricht T.M. and Gersell D.J. (1991). Rete testis hyperplasia with hyalin globule formation. A lesion simulating yolk sac tumour. *Am. J. Surg. Pathol.* 15, 66-74.
- Ulbricht T.M., Amin T.M. and Young R.H. (1999). Tumour-like lesion of testis, paratestis, and spermatic cord. *Atlas of tumour pathology. Tumours of the testis, adnexa, spermatic cord and scrotum. Fascicle 25. Armed Forces Institute of Pathology. Washington, D.F.* pp 291-342.
- Wojcik L.J., Hansen K., Diamond D.A., Koyle M., Koff S.A., Copen D.E. and Caldamone A.A. (1997). Cystic dysplasia of the rete testis: a benign congenital lesion associated with ipsilateral urological anomalies. *J. Urol.* 158, 600-604.
- Yadav S.B., Patil P.N. and Karkhanis R.B. (1969). Primary tumours of the spermatic cord, epididymis and rete testis. *J. Postgrad. Med.* 15, 49-52.

Accepted March 7, 2003