

Review

Review of sarcomatoid renal cell carcinoma with focus on clinical and pathobiological aspects

N. Kuroda, M. Toi, M. Hiroi and H. Enzan

First Department of Pathology, Kochi Medical School, Kohasu, Oko-cho, Nankoku City, Kochi, Japan

Summary. In sarcomatoid renal cell carcinoma (RCC), it is generally accepted that the sarcomatoid portion is derived from metaplastic transformation of carcinoma. Sarcomatoid RCCs account for about 1-8% of all renal tumors. Macroscopically, tumors generally form encapsulated masses and show invasive growth. Sarcomatoid RCCs originate from all subtypes of RCCs, including conventional, papillary, chromophobe, and collecting duct carcinomas. With regard to the growth pattern of the sarcomatoid component, malignant fibrous histiocytomatous, fibrosarcomatous and unclassified sarcomatous patterns are frequently seen. Immunohistochemically, sarcomatoid RCCs are generally positive for AE1/AE3, epithelial membrane antigen (EMA) and vimentin and negative for desmin, actin and S-100. Little is known about genetic alterations in sarcomatoid RCCs. Further studies are therefore needed to identify the key gene involved in sarcomatoid transformation of RCCs.

Key words: Sarcomatoid renal cell carcinomas, Pathology

History of the establishment of the disease concept

The concept of sarcomatoid renal cell carcinoma (RCC) was first described by Farrow et al. in 1968. They suggested that the sarcomatoid portion is derived from metaplastic transformation of carcinoma. Therefore, the term "renal carcinosarcoma" used in early reports includes "true" carcinosarcoma (very rare) and "false" carcinosarcoma (so-called sarcomatoid RCC). Furthermore, the term "renal sarcoma" also used in early reports includes "true" sarcoma (very rare), "false" sarcoma (so-called sarcomatoid RCC) and "true" carcinosarcoma (Bonsib et al., 1987). Sarcomatoid RCCs have also been referred to as metaplastic carcinomas or spindle cell carcinomas (Reuter, 1993; de

Peralta-Venturina et al., 2001). In recent classifications, sarcomatoid RCC is not a distinct histological entity because it arises from all subtypes of RCCs (Kovacs et al., 1997; Störkel et al., 1997).

Epidemiology

Sarcomatoid RCCs account for about 1-8% of all renal tumors (Farrow et al., 1968; Tomera et al., 1983; Bertoni et al., 1987; Ro et al., 1987; Sella et al., 1987; DeLong et al., 1993; Reuter, 1993; Akhtar et al., 1997; de Peralta-Venturina et al., 2001). The mean age and range of ages of patients were 56.2 years and 30-81 years in a large series studied by Ro et al. (1987) and 60 years and 33-80 years in a large series studied by de Peralta-Venturina et al. (2001). The male-to female ratios in these two series were 1.3-1.6 (Ro et al., 1987; de Peralta-Venturina et al., 2001).

Clinical symptoms and signs

Flank or abdominal pain and hematuria are common. A palpable flank mass, generalized weakness, appetite loss and weight loss are also observed (Farrow et al., 1968; Tomera et al., 1983; Bertoni et al., 1987; Akhtar et al., 1997).

Other clinical settings

Distant metastasis frequently occur in the lung or bone (Bertoni et al., 1987). Metastasis to the adrenal gland and heart may occur (Bird et al., 1991). A case of sarcomatoid RCC associated with acquired cystic kidney disease has been reported (Suvarna et al., 1994).

Radiological findings

As sarcomatoid RCCs originate from renal parenchyma, they cannot be easily separated from usual type RCCs radiologically. In a computed tomography (CT) scan, a direct extension of the tumor into the paraaortic region and retroperitoneal adenopathy is frequently observed. In renal angiography, tumors are

hypervascular with areas of neovascularity (Shirkhoda and Lewis, 1987).

Pathological findings

1) Macroscopic findings

Macroscopically, tumors generally form encapsulated masses and show invasive growth (Farrow et al., 1968). The sarcomatous area is frequently described as dense and gray with a fleshy-to-fibrous cut surface (Bertoni et al., 1987; Ro et al., 1987; Reuter, 1993; de Peralta-Venturina et al., 2001). The mean size and range of sizes of tumors were 10.2 cm and 4.2-18.5 cm in a large series studied by Ro et al. (1987) and 9.2 cm and 3-25 cm in a large series studied by de Peralta-Venturina et al. (2001). Hemorrhage and necrosis are frequently seen (Bertoni et al., 1987; Ro et al., 1987; DeLong et al., 1993). Extension beyond the renal capsule or invasion into a renal vein are also frequently seen.

2) Microscopic findings

Sarcomatoid RCCs arise from all types of RCCs, including conventional, papillary, chromophobe, and collecting duct carcinomas (Farrow et al., 1968; Bertoni et al., 1987; Ro et al., 1987; Rumpelt et al., 1991; Baer et al., 1993; DeLong et al., 1993; Reuter, 1993; Akhtar et al., 1996, 1997; Aizawa et al., 1997; Gomez-Roman et al., 1997; Hirokawa et al., 1998; Kuroda et al., 1998; Mai et al., 1999b; Wilson et al., 1999; Nagashima et al., 2000; de Peralta-Venturina et al., 2001). Akhtar et al. (1997) reported that there is a high incidence of sarcomatoid transformation in chromophobe RCCs.

They suggested that the high incidence of sarcomatoid change in chromophobe RCCs is due to the unique racial, ethnic, cultural and geographic characteristics of Saudi Arabia. Nagashima (2000) suggested that the tendency toward sarcomatoid transformation in chromophobe RCCs is due to genomic instability. However, de Peralta-Venturina et al. (2001) found no significant differences between the rates of sarcomatoid change in different histological subtypes. Mai et al. (1999a) reported that the frequency of each subtype of RCCs is roughly equal to that of each subtype in the overall series. The sarcomatoid component is composed mainly of pleomorphic and spindle cells (Farrow et al., 1968; Tomera et al., 1983; Bertoni et al., 1987; Ro et al., 1987; DeLong et al., 1993; Reuter, 1993; Suvarna et al., 1994; Akhtar et al., 1997; de Peralta-Venturina et al., 2001). Additionally, a myxoid appearance and the formation of osteoid and cartilage or osteoclast-type multinucleated giant cells are sometimes found in the sarcomatoid area (Farrow et al., 1968; Aschokraj et al., 1981; Tomera et al., 1983; Macke et al., 1985; Ro et al., 1987; Chetty and Cvijan, 1997; Mai et al., 1999a; de Peralta-Venturina et al., 2001). With regard to the growth pattern of the sarcomatoid component, malignant fibrous histiocytomatous, fibrosarcomatous, unclassified sarcomatous, and hemangiopericytomatous patterns have been identified (Tomera et al., 1983; Bertoni et al., 1987; Ro et al., 1987; DeLong et al., 1993; Reuter, 1993; de Peralta-Venturina et al., 2001). Nuclei are large and hyperchromatic (Akhtar et al., 1997). The nuclear grade is generally high (grade 3 or 4 according to Fuhrman's nuclear grade classification) (Ro et al., 1987; de Peralta-Venturina et al., 2001). Abnormal mitotic figures are more common in the sarcomatoid area than in the carcinomatous area (Ro et al., 1987). Transitional zones

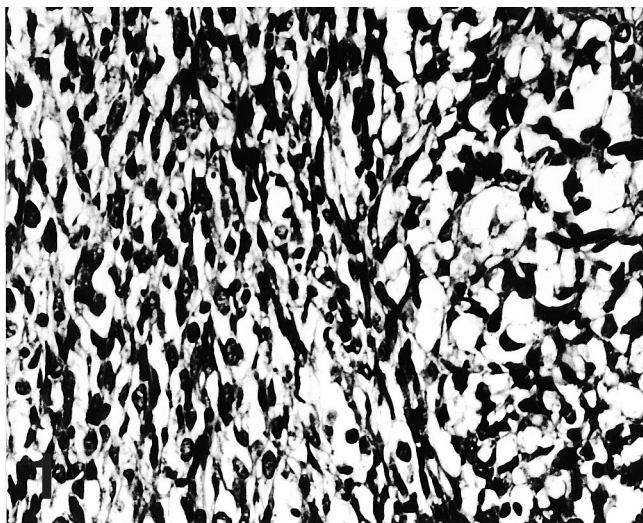


Fig. 1. Proliferation of clear cancer cells can be seen on the right side and proliferation of spindle cells (cancer cells with sarcomatoid transformation) can be seen on the left side. x 25

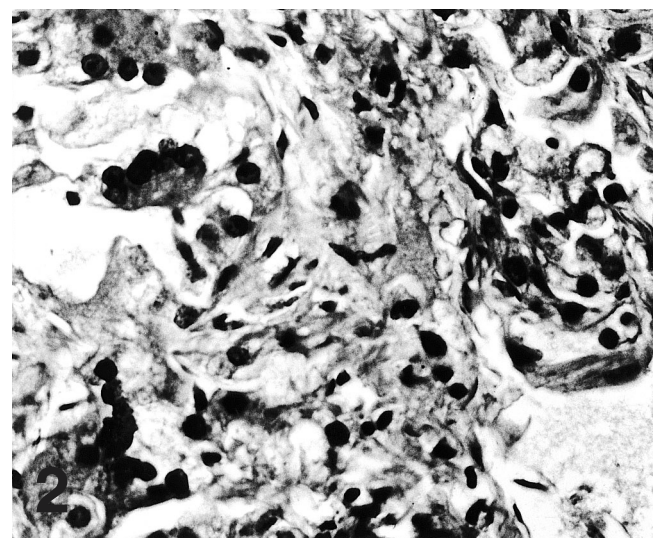


Fig. 2. Cancer cells with cytological pleomorphism are occasionally seen. x 50

Sarcomatoid RCC

between carcinomatous and sarcomatoid components are sometimes observed (Farrow et al., 1968; de Peralta-Venturina et al., 2001).

3) Histochemical and immunohistochemical findings

By reticulin fiber staining, reticulin fibers are limited to areas where spindle cells are present and to the supporting interstitium (Farrow et al., 1968). In lectin histochemistry, similar patterns of markers are seen in sarcomatoid and primary RCCs (Harris et al., 1989). Immunohistochemically, more than half of sarcomatoid RCCs are positive for AE1/AE3, epithelial membrane antigen (EMA) and vimentin (Harris et al., 1989; Delong et al., 1993; Reuter, 1993; Akhtar et al., 1997). However, sarcomatoid variants show stronger staining in a higher proportion of cases for vimentin and reduced positivity for EMA compared with conventional RCCs (Harris et al., 1989). Staining for other mesenchymal markers such as desmin, actin and S-100 is generally negative (DeLong et al., 1993; Reuter, 1993; Akhtar et al., 1997). As some sarcomatoid RCCs display a positive reaction for proteinase inhibitors (α 1-antitripsin and α 1-antichymotripsin) and CD68/KP1, these antibodies are not useful for distinguishing sarcomatoid RCCs and sarcomas (Fleming and Gibson, 1986; Khoury et al., 1999). The authors (2000) and Sakai et al. (2001) reported that sarcomatoid transformation from conventional RCCs is associated with expression of vinculin and SPARC in the tumor cell cytoplasm, respectively. The mean PCNA labeling index in sarcomatoid RCCs is higher than that in RCCs of low nuclear grade (Oda and Machinami, 1993). Furthermore, the mean Ki-67 labeling index in the sarcomatoid component is higher than that in the carcinomatous component (Deitchman and Sidhu, 1980).

4) Ultrastructural findings

Ultrastructurally, epithelial structures such as desmosomes, cell interdigitation, basal lamina or microvilli in the sarcomatoid component as well as in the carcinomatous component may be observed (Deitchman and Sidhu, 1980; Bonsib et al., 1987; Bird et al., 1991; Morikawa et al., 1993; Bolercia et al., 1995). Occasionally, features of epithelial as well as mesenchymal differentiation may be found within the same tumor or within the same cells (Bird et al., 1991; Akhtar et al., 1997). Bonsib et al. (1987) pointed out the limitation of light microscopy and the importance of ultrastructural study for diagnosis of tumors without a carcinomatous component at the level of light microscopy.

5) Cytological findings

In cytological examination of smears and cell blocks, two populations are observed. One population is composed of the epithelial component, which is

evidently characterized by individual or small clusters of round cells with moderately abundant cytoplasm, and the other population is composed of single spindle cells or, more commonly, of large clusters of spindle cells with elongated nuclei and scarcely to moderately abundant cytoplasm (Auger et al., 1993).

Flow cytometric findings

The DNA ploidy pattern is variable in the carcinomatous component of each subtype and in each component of the same tumor (Yu et al., 1991; Akhtar et al., 1997).

Chromosomal analyses (karyotyping and comparative genomic hybridization (CGH)) and other genetic changes

Little is known about genetic alterations in sarcomatoid RCCs. In karyotyping, Grammatico et al. (1993) demonstrated the involvement of chromosomes 1, 12, 16 and 19 and moreover their breakpoints, 1q21, 1q44, 12q15, 16q13.3 and 19p13.3, in a tumor with histologically both glandular and papillary structures. Based on the results of CGH analysis, Jiang et al. (1998) suggested that chromosomes 13q, 4q, 7p21-22 and 11q22-23 carry genes with relevance for sarcomatoid growth in RCCs.

Oda et al. (1995) showed that the rate of p53 mutation is extremely high in the sarcomatoid portion but not in the carcinomatous portion and suggested that p53 mutations are associated with sarcomatoid transformation of RCCs. On the other hand, Contractor et al. (1997) reported that p53 mutation occurs in chromophobe RCCs but not in sarcomatoid RCCs.

Differential diagnosis in histopathology

Differentiation between primary renal sarcoma, sarcomatoid urothelial carcinoma of the renal pelvis, and angiomyolipoma is necessary (Reuter, 1993; de Peralta-Venturina et al., 2001). As true renal sarcomas are extremely rare, extensive sampling for diagnosing all renal malignant spindle cell tumors is needed to distinguish sarcomatoid RCCs from renal sarcomas. Leiomyosarcoma is the most frequently occurring renal sarcoma (de Peralta-Venturina et al., 2001). An interlacing fascicular growth pattern, which is often seen in leiomyosarcomas, is rare in sarcomatoid RCCs. In sarcomatoid urothelial carcinomas, carcinoma in situ or papillary growth of transitional cell carcinoma can be found elsewhere. Angiomyolipomas may pose a diagnostic problem because they show intravascular invasion or multicentric occurrence in lymph nodes or other anatomic sites. Furthermore, the smooth muscle component of angiomyolipoma shows cellular atypia or an epithelioid appearance (3). Careful searches for adipose tissue and vascular elements are important. Immunohistochemical study of HMB-45 may also be

useful.

Treatment and prognosis

Radical nephrectomy and subsequent adjuvant therapy (chemotherapy, radiotherapy, combined chemotherapy and radiotherapy, and immunotherapy) are generally performed (Krutchik et al., 1978; Bertoni et al., 1987; Sella et al., 1987; Culine et al., 1995; de Peralta-Venturina et al., 2001). Sella et al. (1987) recommend a combined interferon and doxorubicin HCl chemotherapy regimen (CYVADIC). Sarcomatoid RCC is a highly aggressive neoplasm with a dismal prognosis (Tomera et al., 1983; Bertoni et al., 1987; Sella et al., 1987; Reuter, 1993; de Peralta-Venturina et al., 2001). According to a report by de Peralta-Venturina et al. (2001), the disease-specific survival rates are only 22% and 13% after 5 and 10 years, respectively (4). Sella et al. reported that metastasis at presentation, advanced stage and female sex are associated with poor prognosis. Ro et al. (1987) suggested that the pathological stage, degree of tumor necrosis and proportion of sarcomatoid components are important prognostic factors for clinical outcome. Using Kaplan-Meier survival analysis, de Peralta-Venturina et al. (2001) found that tumors with a high TNM stage, at least 50% sarcomatoid component, and angiolymphatic invasion are associated with decreased survival.

Conclusions and perspectives

In recent classifications, tumors composed of carcinoma and sarcomatous elements are categorized into histological subtypes of the primary carcinoma components, and tumors composed exclusively of sarcomatoid or spindle elements without a recognizable epithelial component are categorized as unclassified RCCs (Kovacs et al., 1997; Störkel et al., 1997). If these tumors are subjected to ultrastructural and chromosomal analysis, some unclassified RCCs may be able to be categorized into definite histological subtypes. However, the genetic events responsible for sarcomatoid transformation of RCCs have not been elucidated. Further studies are therefore needed to identify the key gene involved in sarcomatoid transformation of RCCs.

References

- Aizawa S., Chigusa M., Ohno Y. and Suzuki M. (1997). Chromophobe cell renal carcinoma with sarcomatoid component. A report of two cases. *J. Urol. Pathol.* 6, 51-59.
- Akhtar M., Kfiury H., Karder A., Linjawi T. and Kovacs G. (1996). Sarcomatoid chromophobe cell carcinoma of the kidney. *J. Urol. Pathol.* 4, 155-166.
- Akhtar M., Tulbah A., Karder A.H. and Ali M.A. (1997). Sarcomatoid renal cell carcinoma: The chromophobe connection. *Am. J. Surg. Pathol.* 21, 1188-1195.
- Ashokraj G., Bhatia A. and Sagreiya K. (1981). Sarcomatoid renal carcinoma- A histopathological study of two cases with a review of the literature. *Ind. J. Cancer* 18, 84-86.
- Auger M., Katz R.L., Sella A., Ordonez N.G., Lawrence D.D. and Ro J.Y. (1993). Fine-needle aspiration cytology of sarcomatoid renal cell carcinoma: A morphologic and immunocytochemical study of 15 cases. *Diagn. Cytopathol.* 9, 46-51.
- Baer S.C., Ro J.Y., Ordonez N.G., Maiese R.L., Loose J.H., Grignon D.G. and Ayala A.G. (1993). Sarcomatoid collecting duct carcinoma: A clinicopathologic and immunohistochemical study of five cases. *Hum. Pathol.* 24, 1017-1022.
- Bertoni F., Ferri C., Benati A., Bacchini P. and Corrado F. (1987). Sarcomatoid carcinoma of the kidney. *J. Urol.* 137, 25-28.
- Bird D.J., Semple J.P. and Seiler M.W. (1991). Sarcomatoid renal cell carcinoma metastatic to the heart: Report of a case. *Ultrastruct. Pathol.* 15, 361-366.
- Bolercia G., Bhan A.K. and Dickersin G.R. (1995). Sarcomatoid carcinoma: An ultrastructural study with light microscopic and immunohistochemical correlation of 10 cases from various anatomic sites. *Ultrastruct. Pathol.* 19, 249-263.
- Bonsib S.M., Fischer J., Plattner S. and Farron B. (1987). Sarcomatoid renal tumors: Clinicopathologic correlation of three cases. *Cancer* 59, 527-532.
- Chetty R. and Cvijan D. (1997). Giant (bizarre) cell variant of renal carcinoma. *Histopathology* 30, 585-587.
- Contractor H., Zariwala M., Bugert P., Zeisler J. and Kovacs G. (1997). Mutation of the p53 tumour suppressor gene occurs preferentially in the chromophobe type of renal cell tumour. *J. Pathol.* 181, 136-139.
- Culine S., Bekradda M., Terrier-Lacombe M.J. and Droz J.P. (1995). Treatment of sarcomaoid renal cell carcinoma: Is there a role for chemotherapy? *Eur. Urol.* 27, 138-141.
- Deitchman B. and Sidhu G.S. (1980). Ultrastructural study of a sarcomatoid variant of renal cell carcinoma. *Cancer* 46, 1152-1157.
- DeLong W., Grignon D.J., Eberwein P., Shum D.T. and Wyatt J.K. (1993). Sarcomatoid renal cell carcinoma: An immunohistochemical study of 18 cases. *Arch. Pathol. Lab. Med.* 117, 636-640.
- de Peralta-Venturina M., Moch H., Amin M., Tamboli P., Hailemariam S., Mihatsch M., Javidan J., Stricker H., Ro J.Y. and Amin M.B. (2001). Sarcomatoid differentiation un renal cell carcinoma: A study of 101 cases. *Am. J. Surg. Pathol.* 25, 275-284.
- Farrow G.M., Harrison E.G. and Utz D.C. (1968). Sarcomas and sarcomatoid and mixed malignant tumors of the kidney in adults- Part III. *Cancer* 3, 556-563.
- Fleming S. and Gibson A.A.M. (1986). Proteinase inhibitors in the kidney and its tumours. *Histopathology* 10, 1303-1313.
- Gomez-Roman J., Mayarga-Fernandez M.M., Fernandez-Fernandez F. and Val-Bernal J. (1997). Sarcomatoid chromophobe cell renal carcinoma: Immunohistochemical and lectin study in one case. *Gen. Diagn. Pathol.* 143, 63-69.
- Grammatico P., Ciaciulli A.M., Grammatico B., Rosa C.D. and Parto G.D. (1993). The first cytogenetic study of a sarcomatoid renal cell carcinoma. *J. Exp. Clin. Cancer* 12, 19-21.
- Harris S.C., Hird P.M. and Shortland J.R. (1989). Immunohistochemistry and lectin histochemistry in sarcomatoid renal cell carcinoma: a comparison with classical renal cell carcinoma. *Histopathology* 15, 607-616.
- Hirokawa M., Shimizu M., Sakurai T., Terayama K. and Manabe T. (1998). Sarcomatoid renal cell carcinoma with chromophobe cell foci. *APMIS* 106, 993-996.
- Jiang F., Moch H., Richter J., Egenter C., Gasser T., Bubendorf L., Gschwind R., Sauter G. and Mihatsch M.J. (1998). Comparative

Sarcomatoid RCC

- genomic hybridization reveals frequent chromosome 13q and 4q losses in renal carcinomas with sarcomatoid transformation. *J. Pathol.* 185, 382-388.
- Khoury J.D., Dawson D.M., Connell C.F., Bostwick D.G. and MacLennan G.T. (1999). Expression of the macrophage-associated antigen CD68/KP-1 by tumor cells of sarcomatoid renal cell carcinoma. *J. Urol. Pathol.* 11, 81-89.
- Kovacs G., Akhtar M., Beckwith J.B., Bugert P., Cooper C.S., Delahunt B., Eble J.N., Fleming S., Ljungberg B., Medeiros L.J., Moch H., Reuter V.E., Ritz E., Roos G., Schmidt D., Srigley J.R., Störkel S., van den Berg E. and Zbar B. (1997). The Heidelberg classification of renal cell tumours. *J. Pathol.* 183, 131-133.
- Krutchik A.N., Sullivan C., Sinkovics J.G. and Ayala A. (1978). Chemoimmunotherapy of sarcomatoid renal cell carcinoma. *Med. Pediatr. Oncol.* 5, 9-13.
- Kuroda N., Hayashi Y. and Itoh H. (1998). A case of chromophobe renal cell carcinoma with sarcomatoid foci and a small daughter lesion. *Pathol. Int.* 48, 812-817.
- Kuroda N., Naruse K., Miyazaki E., Hayashi Y., Yoshikawa C., Ashida S., Moriki T., Yamasaki Y., Numoto S., Yamamoto Y., Yamasaki I., Hiroi M., Shuin T. and Enzan H. (2000). Vinculin: its possible use as a marker of normal collecting ducts and renal neoplasms with collecting duct system phenotype. *Mod. Pathol.* 13, 1109-1114.
- Kuroiwa K., Konomoto T., Kumazawa J., Naito S. and Tsuneyoshi M. (2001). Cell proliferative activity and expression of cell-cell adhesion (E-cadherin, α -, β -, and γ -catenin, and p21) in sarcomatoid renal cell carcinoma. *J. Surg. Oncol.* 77, 123-131.
- Mai K.T., Blew B. and Collins J.P. (1999a). Renal cell carcinoma with extensive and minimal sarcomatoid change. *J. Urol. Pathol.* 11, 35-46.
- Mai K.T., Veinot J.P. and Collins J.P. (1999b). Sarcomatous transformation of chromophobe cell renal carcinoma. *Histopathology* 34, 557-559.
- Macke R.A., Hussain M.B., Imray T.J., Wilson R.B. and Cohen S.M. (1985). Osteogenic and sarcomatoid differentiation of a renal cell carcinoma. *Cancer* 56, 2452-2457.
- Morikawa Y., Tohya K., Kusuyama Y., Masui M. and Wakasugi C. (1993). Sarcomatoid renal cell carcinoma: An immunohistochemical and ultrastructural study. *Int. Urol. Nephrol.* 25, 51-58.
- Nagashima Y. (2000). Chromophobe renal cell carcinoma: Clinical, pathological and molecular biological aspects. *Pathol. Int.* 50, 872-878.
- Nagashima Y., Okudela K., Osawa A., Nakamura N., Kawasaki C., Moriyama M., Nakamura N., Nakatani Y., Kitamura H. and Aoki I. (2000). Chromophobe renal cell carcinoma with sarcomatoid change: A case report. *Pathol. Res. Pract.* 196, 647-651.
- Oda H., Nakatsuru Y. and Ishikawa T. (1995). Mutation of the p53 gene and p53 protein overexpression are associated with sarcomatoid transformation in renal cell carcinomas. *Cancer Res.* 55, 658-662.
- Oda H. and Machinami R. (1993). Sarcomatoid renal cell carcinoma: A study of its proliferative activity. *Cancer* 71, 2292-2298.
- Reuter V.E. (1993). Sarcomatoid lesions of the urogenital tract. *Semin. Diagn. Pathol.* 10, 188-201.
- Ro J.Y., Ayala A.G., Sella A., Samuels M.L. and Swanson D.A. (1987). Sarcomatoid renal cell carcinoma: Clinicopathologic study of 42 cases. *Cancer* 59, 516-526.
- Rumpelt H.J., Störkel S., Moll R., Schärfe T. and Thoenes W. (1991). Bellini duct carcinoma: Further evidence for this rare variant of renal cell carcinoma. *Histopathology* 18, 115-122.
- Sakai N., Baba M., Nagashima Y., Kato Y., Hirai K., Kondo K., Kobayashi K., Yoshida M., Kaneko., Kishida T., Kawakami S., Hosaka M., Inayama Y. and Yao M. (2001). SPARC expression in primary human renal cell carcinoma: Upregulation of SPARC in sarcomatoid renal carcinoma. *Hum. Pathol.* 32, 1064-1070.
- Sella A., Logothetis C.J., Ro J.Y., Swanson D.A.M. and Samuels M.L. (1987). Sarcomatoid renal cell carcinoma: A treatable entity. *Cancer* 60, 1313-1318.
- Shirkhoda A. and Lewis E. (1987). Renal sarcoma and sarcomatoid renal cell carcinoma: CT and amniographic features. *Radiology* 162, 353-357.
- Störkel S., Eble J.N., Adlakha K., Amin M.B., Blute M.L., Bostwick D.G., Darson M., Delahunt B. and Iszkowski K. (1997). Classification of renal cell carcinoma: Workgroup No.1. Union Internationale Contre le Cancer (UICC) and the American Joint Committee on Cancer (AJCC). *Cancer* 80, 987-989.
- Suvarna S.K., Ahuja M. and Brown C.B. (1994). Sarcomatoid renal cell carcinoma arising in hemodialysis-associated acquired cystic kidney disease presenting with disseminated bone marrow infiltration. *Am. J. Kid. Dis.* 24, 581-585.
- Tomera K.M., Farrow G.M. and Lieber M.M. (1983). Sarcomatoid renal carcinoma. *J. Urol.* 130, 657-659.
- Wilson E.J., Resnick M.I., Jacobs G. and MacLennan G.T. (1999). Sarcomatoid chromophobe renal cell carcinoma: Report of an additional case with ultrastructural findings. *J. Urol. Pathol.* 11, 113-122.
- Yu D.S., Wang J., Chang S.Y. and Ma C.P. (1991). Flow cytometric analysis of DNA ploidy, cell cycle and cytomorphometry in sarcomatoid renal cell carcinoma. *Eur. Urol.* 20, 227-231.

Accepted November 8, 2002