

Immunohistochemical localization of truncated midkine in developing human bile ducts

M. Kato¹, T. Shinozawa², S. Kato³ and T. Terada⁴

¹Second Department of Pathology, Faculty of Medicine, Tottori University, Yonago, Japan, ²Department of Biological and Chemical Engineering, Faculty of Engineering, Gunma University, Kiryu, Japan, ³Division of Neuropathology, Institute of Neurological Sciences, Faculty of Medicine, Tottori University, Yonago, Japan and ⁴Department of Pathology, Shimizu Municipal Hospital, Shimizu, Japan

Summary. Midkine (MK) is a heparin-binding growth factor whose gene has been identified in embryonal carcinoma cells in early stages of retinoic acid-induced differentiation. In the present study, we investigated the developmental localization of truncated MK protein in human bile ducts. Thirty specimens of the livers from 25 fetuses (from 9 to 40 gestational weeks) and from five neonates less than 4 weeks old were examined. Immunohistochemical analysis was performed using a mouse IgG_{2b} monoclonal antibody against recombinant-truncated MK. Truncated MK was expressed moderately in the fetal liver from 9 to 15 gestational weeks. The immunoreactivities were found in the primitive hepatocytes, ductal plates, migrating biliary cells and immature bile ducts. The reaction products were localized in the cytoplasm heterogeneously. The intensity of immunostaining was weak from 15 gestational weeks to 26 gestational weeks. After 27 gestational weeks, truncated MK was not detected in the fetal livers. It was suggested that primitive hepatocytes, ductal plates and immature bile ducts produced truncated MK transiently during human bile ducts development.

Key words: Midkine, Truncated midkine, Fetus, Bile duct, Immunohistochemistry

Introduction

Growth factors have important roles in cell growth and proliferation (Fausto and Mead, 1989; Naggy et al., 1989; Michalopoulos, 1990; Evarts et al., 1992; Marsden et al., 1992; Terada and Nakanuma, 1993). Midkine (MK) is a heparin-binding growth factor whose gene has been identified in embryonal carcinoma cells in the early stages of retinoic acid-induced differentiation

(Kadomatsu et al., 1988; Tomomura et al., 1990a,b; Muramatsu, 1993). MK is an approximately 15-kDa polypeptide that is rich in basic amino acids and cysteine (Kadomatsu et al., 1988; Tomomura et al., 1990a,b). MK is mitogenic in cell lines and induces neurite outgrowth of embryonic brain cells, PC12 cells and dorsal root ganglion cells (Tomomura et al., 1990b; Muramatsu and Muramatsu, 1991; Michikawa et al., 1993a,b). It also promotes the survival of astrocytes and mesencephalic neurons in culture (Kikuchi et al., 1993; Satoh et al., 1993). The detection of the MK gene or protein in mouse or rat embryos suggests that MK plays a fundamental role during mouse or rat embryogenesis (Kadomatsu et al., 1990; Muramatsu et al., 1993). We previously studied the expression of full length (or c-half) human midkine (cMK) throughout human liver development (Kato et al., 2000c). It was demonstrated that MK was expressed in the fetal liver in some developmental stages (Kato et al., 2000c). A truncated form of MK mRNA, which encodes MK lacking the N-terminal domain, has been detected in Wilms' tumor, pancreatic carcinoma, gastric carcinoma, colon carcinoma and breast carcinoma (Tsutsui et al., 1993; Kaname et al., 1996; Miyashiro et al., 1996, 1997). Therefore, the truncated MK was suspected to be specific for tumor cells. Recently, a new monoclonal antibody against this recombinant truncated MK has been purified and established (Paul et al., 2001a,b). In the present study, we applied this novel monoclonal antibody to human fetal livers and truncated MK was also detected in developing human bile ducts. It was suggested that primitive hepatocytes and bile duct cells transiently produced truncated MK in addition to cMK in certain developmental stages.

Materials and methods

We collected 25 human fetal livers at 9 to 40 gestational weeks and five neonatal livers at 0, 9, 17 days and 4 weeks after birth from several institutions in Japan. All of the fetuses had been spontaneously

Offprint requests to: Masako Kato, M.D., Ph.D., Second Department of Pathology, Faculty of Medicine, Tottori University, 86 Nishi-cho, Yonago 683-8503, Japan. Fax: +81-859-34-8348. e-mail: makato@grape.med.tottori-u.ac.jp

Truncated midkine localization in fetal bile ducts

aborted, and in all cases, informed consent was obtained from each mother or both parents. In addition, we obtained 10 surgical specimens of normal adult livers (mean age=63 years; 8 males, 2 females) during

Table 1. Immunohistochemical distribution of truncated midkine in developing human fetal bile ducts.

Case (GW)	HP	DP	MBC	IBD/BD
9W	+	+/-		
10W	+	+	+	
10W	+/-	+/-		
13W	++	++	++	
15W	++	++	++	+
15W	+	+	+/-	+/-
16W	+	+	+	+/-
22W	+/-		+/-	-
24W	+/-		+/-	-
25W	+/-		+/-	-
26W	+/-		-	+/-
26W	+/-		+/-	+/-
27W	-			-
27W	-			-
27W	-			-
28W	-			-
28W	-			-
30W	-			-
34W	-			-
34W	-			-
34W	-			-
36W	-			-
40W	-			-
0D	-			-
1D	-			-
17D	-			-
1M	-			-
1M	-			-

GW: gestational weeks; W: weeks; D: days after birth (full term); M: month; HP: hepatocytes; DP: ductal plates; MBC: migrating biliary cells; IBD/BD: immature bile ducts/bile ducts; ++: strong positive staining; +: positive staining; +/-: weak staining; -: negative

abdominal surgery for hepatocellular carcinomas without metastases. The liver specimens were fixed in 4% neutral-buffered formaldehyde solution and then embedded in paraffin. Several 4 μ m sections were obtained and one section was stained with hematoxylin and eosin (H&E), and the others were subjected to immunohistochemical staining.

Immunohistochemical procedure

Sections from each paraffin block were immunohistochemically stained with recombinant human-specific truncated MK monoclonal antibody that did not cross-react with synthetic full length human midkine (Kato et al., 1999; Paul et al., 2001a,b), using the avidin-biotin-complex (ABC) immunoperoxidase method (Hsu et al., 1981). In brief, after deparaffinization, endogenous peroxidase activity was quenched by immersing the sections for 20 min in absolute methanol containing 0.3% H₂O₂. The sections were then treated with normal serum for 60 min, followed by treatment at 4 °C overnight with monoclonal antibody to human-specific truncated MK (1 μ g/ml; mouse IgG_{2b} class): sections exposed to phosphate-buffered saline, pH7.4 and non-immunized mouse IgG served as controls. Visualization of the bound antibodies was achieved with the Vectastain ABC kit (Vector Laboratories, Burlingame, California, USA) following the manufacturer's protocols; 3,3'-diaminobenzidine tetrahydrochloride (DAB) (Dako, Glostrup, Denmark) was the final chromogen, and methylgreen was used as counterstain.

Results

Histological staging of intrahepatic bile duct development

The developing intrahepatic bile ducts were classified into the following three stages as previously

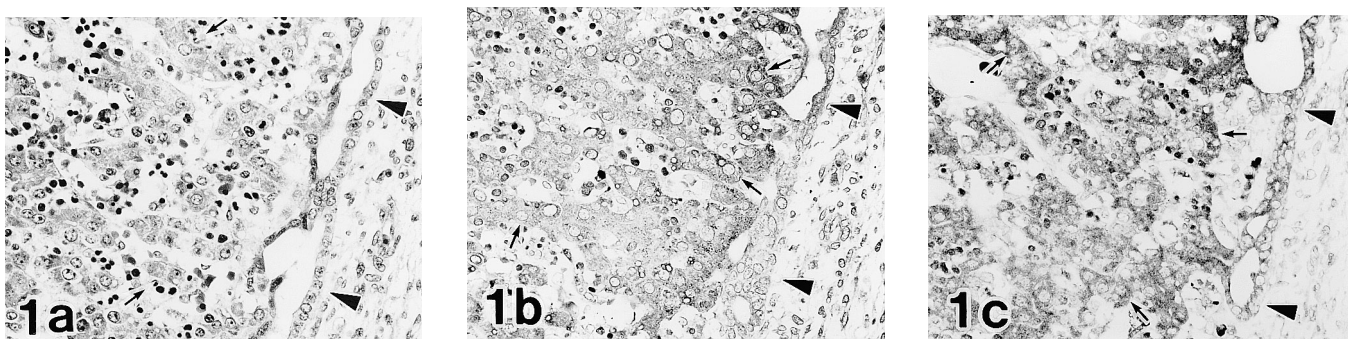


Fig. 1. Microscopical findings of a hilar portal region of a fetus at gestational week 9. **a.** The ductal plate (arrowheads) is seen at the interface between the primitive hepatocytes (arrows) and the portal mesenchyme. Hematoxylin and eosin (H&E) staining. **b.** Immunostaining for the mouse IgG_{2b} monoclonal antibody against recombinant truncated midkine (tMK). The primitive hepatocytes (arrows) are moderately positive for anti-tMK antibody. The ductal plates (arrows heads) are weakly positive for anti-tMK antibody. **c.** Immunostaining for the rat IgG_{2a} monoclonal antibody against the full length (carboxyl terminal region) human midkine (cMK). The primitive hepatocytes (arrows) and ductal plates (arrowheads) are strongly positive for anti-cMK antibody. x 220

Truncated midkine localization in fetal bile ducts

reported: the ductal plate (ductal plate stage); migration of biliary cells from the ductal plate into mesenchyme (remodeling stage); and immature bile ducts (remodeled stage) (Van Eyken et al., 1988; Desmet, 1992; Terada et al., 1994). In the ductal plate stage, single and double layers of ductal plates were observed between portal mesenchyme and primitive hepatocytes (Fig. 1a). A few endothelial cells and many hematopoietic cells were found in sinusoids (Fig. 1a). In the remodeling stage, migrating biliary cells into the portal mesenchyme were found (Fig. 2a). About 20 gestational weeks, immature hepatocytes and hematopoiesis were observed. Some parts of the ductal plates had disappeared (Fig. 3a). In the remodeled stage, an immature bile duct was seen in the portal mesenchyme (Fig. 4a).

Immunohistochemistry

The results of the immunohistochemical analyses of truncated MK are summarized in Table 1. The immunoreactivities for truncated MK were observed in the livers from 9 to 26 gestational weeks. Truncated MK

protein was distributed in the primitive hepatocytes, ductal plates, migrating biliary cells and immature bile ducts. The positive immunoreactivities were localized in the cytoplasm heterogeneously. No significant immunoreactivity of truncated MK was observed in mesenchymal cells or endothelial cells of vessels in the portal areas. Truncated MK was expressed moderately in the livers from 9 gestational weeks (ductal plate stage) (Fig. 1b). Truncated MK was expressed strongly in more immature hepatocytes adjacent to the ductal plates than immature hepatocytes around central veins in 15 gestational weeks (remodeling stage) (Fig. 2b). The luminal aspects of the bile ducts and migrating biliary cells were also stained strongly (Fig. 2a,b). After 20 gestational weeks, the intensity of truncated MK in the hepatocytes decreased gradually (Fig. 3b). The truncated MK-localization of immature bile ducts and hepatocytes was not detected after 27 gestational weeks (remodeled stage) (Fig. 4b). Truncated MK was not distributed in the hepatocytes or bile ducts of the neonate and adult livers. The staining pattern and localization of truncated MK were partially similar to those of cMK (Figs. 1-4b,c).

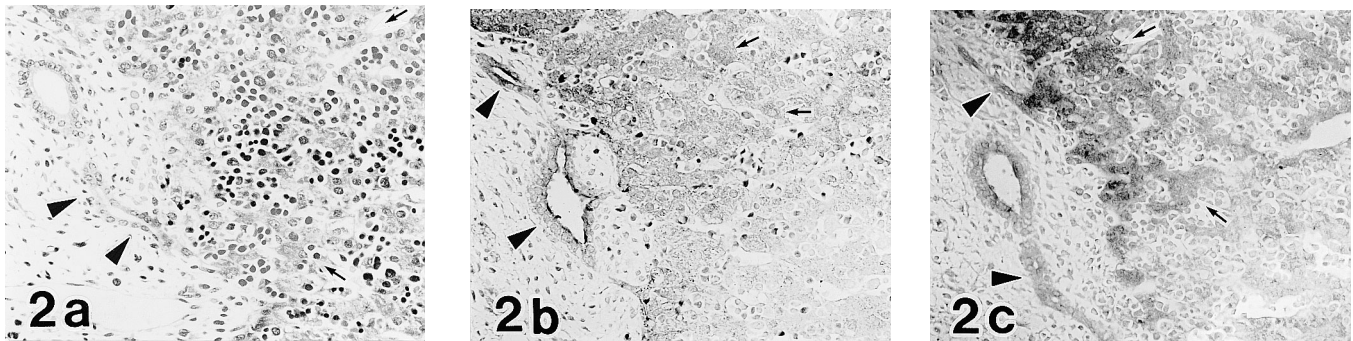


Fig. 2. Microscopic findings of a fetal liver at gestational week 15. **a.** The primitive hepatocytes (arrows) and migrating biliary cells (arrowheads) are observed. H&E staining. **b.** Immunostaining for anti-tMK antibody. tMK is expressed strongly in more immature hepatocytes adjacent to the ductal plates than mature hepatocytes. The luminal aspects of the bile ducts and migrating biliary cells are stained strongly. **c.** Immunostaining for anti-cMK antibody. The primitive hepatocytes (arrows) and migrating biliary cells (arrowheads) are positive for anti-cMK antibody. x 220

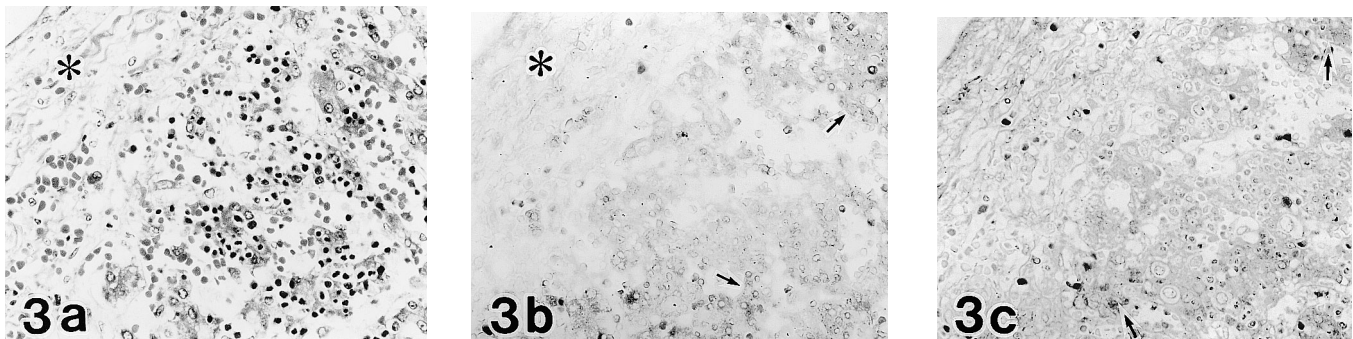


Fig. 3. Microscopic findings of a fetal liver at gestational week 24. **a.** The primitive hepatocytes and portal mesenchyme (asterisk) can be seen. H&E staining. **b.** Immunostaining for anti-tMK antibody. The primitive hepatocytes (arrows) are weakly positive for tMK. No significant immunoreactivity of tMK is observed in the portal mesenchyme (asterisk). **c.** Immunostaining for anti-cMK antibody. The primitive hepatocytes (arrows) are weakly positive for cMK. x 220

Discussion

The truncated form of MK mRNA lacks exon3 encoding the N-terminal half and is an aberrant form of MK mRNA (Paul et al., 2001a,b). The expression of this truncated form has been found in various carcinomas (Tsutsui et al., 1993; Kaname et al., 1996; Miyashiro et al., 1996, 1997). In human colorectal cancers or human breast cancers, MK gene expression is higher in cancer tissues compared with non-cancerous tissues (Miyashiro et al., 1996, 1997). Similarly, MK was expressed in gastric carcinoma cell lines, pancreatic carcinoma cell lines and Wilm's tumor cell lines (Tsutsui et al., 1993; Kaname et al., 1996; Paul et al., 2001b). Aridome et al. (1998) reported the elevated expression of truncated MK in hepatocellular carcinomas and esophageal carcinomas in addition to gastrointestinal carcinomas such as pancreatic, colon and stomach carcinomas. Furthermore, Aridome et al. (1998) found that truncated MK was detectable in lymph node metastases. It was suggested that truncated MK could become a good marker of nodal metastases in gastrointestinal tracts. Altered forms of growth factors or tumor-suppressor gene products, produced in tumor cells by alternative splicing mechanisms, may play important roles in tumorigenesis. In Wilms' tumor cells, the alternative splicing of WT1 is considered to modulate its tumorigenicity (Haber et al., 1993). The elevated expression of MK gene in human tumors has played an important role either in tumorigenesis or in the biological behavior of tumor cells such as metastatic activity (Aridome et al., 1998). Truncated MK has not previously been detected in non-cancerous liver tissues (Aridome et al., 1998). These results coincide with our findings that truncated MK was not localized in adult liver tissues. Although it has been reported that elevated expression of truncated MK has been observed only in the tumor cells previously, we have demonstrated novel findings that truncated MK was distributed transiently in primitive hepatocytes, ductal plates and immature bile ducts during normal human development.

In comparing the distribution of truncated MK with that of cMK in fetal livers, truncated MK showed the same distribution as cMK that was localized in immature hepatocytes, ductal plates, migrating biliary cells and immature bile ducts. Furthermore, cytoplasmic localization of truncated MK also coincided with that of cMK. cMK is highly expressed in various tissues during the midgestation period of mouse embryogenesis (Kadomatsu et al., 1990; Muramatsu et al., 1993) and of human fetal development (Kato et al., 2000c), and is considered to be involved in regulation of organogenesis in mice (Mitsiadis et al., 1995a,b). Furthermore, excess expression of cMK was also reported in some tumor tissues such as brain tumors, hepatocellular carcinomas and thyroid carcinomas (Kato et al., 1999, 2000a,b). In brain tumors, it was demonstrated that MK expression depended on the proliferation potential (Kato et al., 1999). After all, it was suggested that cMK might play an important role in cell proliferation, morphogenesis or organogenesis. Although the period of truncated MK expression was shorter than that of cMK (Kato et al., 2000c), truncated MK was localized in fetal livers. Together with the fact that anti-truncated MK antibody does not cross-react with cMK (Paul et al., 2001a,b), truncated MK was transiently distributed in normal fetal liver tissues. Therefore, it was suggested that there is a correlation between truncated MK distribution and the state of differentiation of bile duct cells.

Some truncated protein variants were detected in fetal organs and thought to regulate embryonic development (Mezquita et al., 1999; Holmberg et al., 2000; Massmann et al., 2000). It was suggested that these truncated protein variants were under developmental regulation of the fetal organs (Mezquita et al., 1999; Holmberg et al., 2000; Komuves et al., 2000; Massmann et al., 2000). Although the biological significance of the expression of truncated MK during human normal development is still unknown, truncated MK is transiently distributed in fetal bile ducts under normal developmental control and might play some roles in differentiation of fetal bile duct cells.

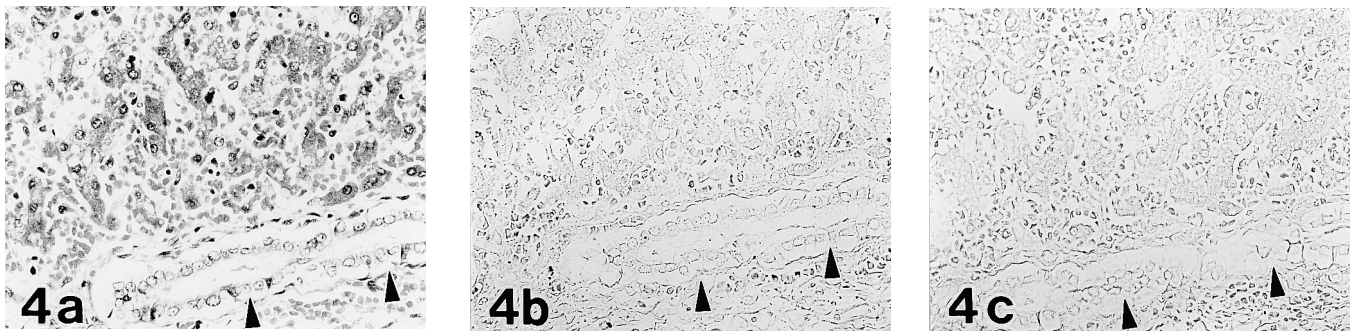


Fig. 4. Microscopical findings of a fetal liver at gestational week 40. **a.** The hepatocytes and bile ducts (arrowheads) are observed. H&E staining. **b.** Immunostaining for anti-tMK antibody. The hepatocytes and bile ducts (arrowheads) are negative for tMK. **c.** Immunostaining for anti-cMK antibody. The hepatocytes and bile ducts (arrowheads) are negative for cMK. x 220

Truncated midkine localization in fetal bile ducts

References

- Aridome K., Takao S., Kaname T., Kadomatsu K., Natsugoe S., Kijima F., Aikou T. and Muramatsu T. (1998). Truncated midkine as a maker of diagnosis and detection of nodal metastases in gastrointestinal carcinomas. *Br. J. Cancer* 78, 472-477.
- Desmet V.J. (1992). Congenital diseases of intrahepatic bile ducts: variations on the theme "ductal plate malformation". *Hepatology* 16, 1069-1083.
- Evarts R.P., Nakatsukasa H., Marsden E.R., Hu Z. and Thorgeirsson S.S. (1992). Expression of transforming growth factor- α in regenerating liver and during hepatic differentiation. *Mol. Carcinog.* 5, 25-31.
- Fausto N. and Mead J.E. (1989). Biology of disease. Regulation of liver growth: protooncogenes and transforming growth factors. *Lab. Invest.* 60, 4-13.
- Haber D.A., Park S., Maheswaran S., Englert C., Re G.G., Hazen-Martin D.J., Sens D.A. and Garvin A.J. (1993). WT1-mediated growth suppression of Wilms tumor cells expressing a WT1 splicing variant. *Science* 262, 2057-2059.
- Holmberg J., Clarke D.L. and Frisen J. (2000). Regulation of repulsion versus adhesion by different splice forms of an Eph receptor. *Nature* 408, 203-206.
- Hsu S.M., Raine L. and Fanger H. (1981). Use of avidin-biotin-peroxidase complex (ABC) in immunoperoxidase techniques: A comparison between ABC and unlabeled antibody (PAP) procedures. *J. Histochem. Cytochem.* 29, 577-580.
- Kadomatsu K., Tomomura M. and Muramatsu T. (1988). cDNA cloning and sequencing of a new gene intensely expressed in early differentiation stages of embryonal carcinoma cells and in mid-gestation period of mouse embryogenesis. *Biochem. Biophys. Res. Commun.* 151, 1312-1318.
- Kadomatsu K., Huang R.P., Suganuma T., Murata F. and Muramatsu T. (1990). A retinoic acid responsive gene MK found in the teratocarcinoma system is expressed in spatially and temporally controlled manner during mouse embryogenesis. *J. Cell Biol.* 110, 607-616.
- Kaname T., Kadomatsu K., Aridome K., Yamashita S., Sakamoto K., Ogawa M., Muramatsu T. and Yamamura K. (1996). The expression of truncated MK in human tumors. *Biochem. Biophys. Res. Commun.* 219, 256-260.
- Kato M., Maeta H., Kato S., Shinozawa T. and Terada T. (2000a). Immunohistochemical and *in situ* hybridization analyses of midkine expression in thyroid papillary carcinoma. *Mod. Pathol.* 13, 1060-1065.
- Kato M., Shinozawa T., Kato S., Awaya A. and Terada T. (2000b). Increased midkine expression in hepatocellular carcinoma: immunohistochemical and *in situ* hybridization analyses. *Arch. Pathol. Lab. Med.* 124, 848-852.
- Kato M., Shinozawa T., Kato S. and Terada T. (2000c). Divergent expression of midkine in the human fetal liver and kidney: immunohistochemical analysis of developmental changes in hilar primitive bile ducts and hepatocytes. *Liver* 20, 475-481.
- Kato S., Ishihara K., Shinozawa T., Yamaguchi H., Asano Y., Saito M., Kato M., Terada T., Awaya A., Hirano A., Dickson D.W., Yen S.H. and Ohama E. (1999). Monoclonal antibody to human midkine reveals increased midkine expression in human brain tumors. *J. Neuropathol. Exp. Neurol.* 58, 430-441.
- Kikuchi S., Muramatsu H., Muramatsu T. and Kim S.U. (1993). Midkine, a novel neurotrophic factor, promotes survival of mesencephalic neurons in culture. *Neurosci. Lett.* 160, 9-12.
- Komuves L.G., Shen W.F., Kwong A., Stelnicki E., Rozenfeld S., Oda Y., Blink A., Krishnan K., Lau B., Mauro T. and Largman C. (2000). Changes in HOXB6 homeodomain protein structure and localization during human epidermal development and differentiation. *Dev. Dyn.* 218, 636-647.
- Marsden E.R., Hu Z., Fujio K., Nakatsukasa H., Thorgeirsson S.S. and Evarts R.P. (1992). Expression of acidic fibroblast growth factor in regenerating liver and during hepatic differentiation. *Lab. Invest.* 67, 427-433.
- Massmann G.A., Zhang J., Sallah J. and Figueroa J.P. (2000). Developmental and regional expression patterns of type 1 nitric oxide synthase mRNA and protein in fetal sheep brain during the last third of gestation. *Brain Res. Dev. Brain Res.* 30, 141-152.
- Mezquita J., Mezquita B., Pau M. and Mezquita C. (1999). Characterization of a novel form of angiopoietin-2(Ang-2B) and expression of VEGF and angiopoietin-2 during chicken testicular development and regression. *Biochem. Biophys. Res. Commun.* 260, 492-498.
- Michalopoulos G.K. (1990). Liver regeneration: molecular mechanisms of growth control. *FASEB J.* 4, 176-187.
- Michikawa M., Kikuchi S., Muramatsu H., Muramatsu T. and Kim S.U. (1993a). Retinoic acid responsive gene product, midkine, has neurotrophic functions for mouse spinal cord and dorsal root ganglion neurons in culture. *J. Neurosci. Res.* 35, 530-539.
- Michikawa M., Xu R.Y., Muramatsu H., Muramatsu T. and Kim S.U. (1993b). Midkine is a mediator of retinoic acid induced neuronal differentiation of embryonal carcinoma cells. *Biochem. Biophys. Res. Commun.* 192, 1312-1318.
- Mitsiadis T.A., Muramatsu T., Muramatsu H. and Thesleff I. (1995a). Midkine (MK), a heparin-binding growth/differentiation factor, is regulated by retinoic acid and epithelial-mesenchymal interactions in the developing mouse tooth, and affects cell proliferation and morphogenesis. *J. Cell Biol.* 129, 267-281.
- Mitsiadis T.A., Salmivirta M., Muramatsu T., Muramatsu H., Rauvala H., Lehtonen E., Jalkanen M. and Thesleff I. (1995b). Expression of the heparin-binding cytokines, midkine (MK) and HB-GAM (pleiotrophin) is associated with epithelial-mesenchymal interactions during fetal development and organogenesis. *Development* 121, 37-51.
- Miyashiro I., Kaname T., Nakayama T., Nakamori S., Yagyu T., Monden T., Kikkawa N., Nishisho I., Muramatsu T., Monden M. and Akiyama T. (1996). Expression of truncated midkine in human colorectal cancers. *Cancer Lett.* 106, 287-291.
- Miyashiro I., Kaname T., Shin E., Wakasugi E., Monden T., Takatsuka Y., Kikkawa N., Muramatsu T., Monden M. and Akiyama T. (1997). Midkine expression in human breast cancers: expression of truncated form. *Breast Cancer Res. Treat.* 43, 1-6.
- Muramatsu T. (1993). Midkine (MK), the product of a retinoic acid responsive gene, and pleiotrophin constitute a new protein family regulating growth and differentiation. *Int. J. Dev. Biol.* 37, 183-188.
- Muramatsu H. and Muramatsu T. (1991). Purification of recombinant midkine and examination of its biological activities: functional comparison of new heparin binding factors. *Biochem. Biophys. Res. Commun.* 177, 652-658.
- Muramatsu H., Shirahama H., Yonezawa S., Maruta H. and Muramatsu T. (1993). Midkine, a retinoic acid-inducible growth/differentiation factor: immunohistochemical evidence for the function and

Truncated midkine localization in fetal bile ducts

- distribution. *Dev. Biol.* 159, 392-402.
- Nagy P., Everts R.P., McMahon J.B. and Thorgeirsson S.S. (1989). Role of TGF-beta in normal differentiation and oncogenesis in rat liver. *Mol. Carcinog.* 2, 345-354.
- Paul S., Mitsumoto T., Yamamoto I. and Shinozawa T. (2001a). Molecular cloning, expression and purification of truncated midkine and its growth stimulatory activity on Wilms' tumor (G401) cells. *Cancer Lett.* 163, 239-244.
- Paul S., Mitsumoto T., Asano Y., Kato S., Kato M. and Shinozawa T. (2001b). Detection of truncated midkine in Wilms' tumor by a monoclonal antibody against human recombinant truncated midkine. *Cancer Lett.* 163, 245-251.
- Satoh J., Muramatsu H., Moretto G., Muramatsu T., Chang H.J., Kim S.T., Cho J.M. and Kim S.U. (1993). Midkine that promotes survival of fetal human neurons is produced by fetal human astrocytes in culture. *Dev. Brain Res.* 75, 201-205.
- Terada T. and Nakanuma Y. (1993). Development of human intrahepatic peribiliary glands: histological, keratin immunohistochemical, and mucus histochemical analyses. *Lab. Invest.* 68, 261-269.
- Terada T., Ohta T. and Nakanuma Y. (1994). Expression of transforming growth factor-alpha and its receptor during human liver development and maturation. *Virchows Arch.* 424, 669-675.
- Tomomura M., Kadomatsu K., Matsubara S. and Muramatsu T. (1990a). A retinoic acid-responsive gene, MK, found in the teratocarcinoma system. Heterogeneity of the transcript and the nature of the translation product. *J. Biol. Chem.* 265, 10765-10770.
- Tomomura M., Kadomatsu K., Nakamoto M., Muramatsu H., Kondoh H., Imagawa K. and Muramatsu T. (1990b). A retinoic acid responsive gene, MK, produces a secreted protein with heparin binding activity. *Biochem. Biophys. Res. Commun.* 171, 603-609.
- Tsutsui J., Kadomatsu K., Matsubara S., Nakagawara A., Hamanoue M., Takao S., Shimazu H., Ohi Y. and Muramatsu T. (1993). A new family of heparin-binding growth/differentiation factors: increased midkine expression in Wilms' tumor and other human carcinomas. *Cancer Res.* 53, 1281-1285.
- Van Eyken P., Sciort R., Callea F., Van der Steen K., Moerman P. and Desmet V.J. (1988). The development of the intrahepatic bile ducts in man: a keratin- immunohistochemical study. *Hepatology* 8, 1586-1595.

Accepted September 24, 2002