

Effects of chronic administration of either ethanol or pentanol on rat duodenum morphology

J. Vaquera¹, A. Vaquera¹ and T. Girbes²

¹Department of Cell Biology and Anatomy, University of León, León, Spain and

²Department of Biochemistry and Molecular Biology, University of Valladolid, Valladolid, Spain

Summary. The morphology of the rat duodenum after chronic treatment with 15% (v/v) ethanol and 4% (v/v) pentanol was studied. Male Wistar rats of experimental groups were given ethanol and pentanol for 15 weeks with food and fluid freely available. Ethanol-15% and 4% pentanol-fed rats showed a significantly reduced fluid and food intake as compared with control rats. The study of the mucosa indicated that the number of chronic inflammatory infiltrating (mononuclear cells) and goblet cells was higher in the groups of the ethanol- and pentanol-fed rats than in the control group. There was an increase in the thickness of the brush border in pentanol-fed rats. Intervillus adhesion was concurrently observed in the pentanol-fed rats but not in the control or ethanol-fed rats. After ethanol feeding many of the villi developed blebs at the apex of the villus or laterally on its upper half. These blebs generally remained intact. In contrast, after pentanol feeding no bleb formation was appreciated. The intake of ethanol and other short chain alcohols present in alcoholic beverages leads to manifold disturbances on the rat duodenum. These findings suggest that the chronic ingestion of pentanol seems to promote cellular changes but less important than those observed after chronic ethanol ingestion.

Key words: Ethanol, Pentanol, Duodenum, Morphology, Rat

Introduction

Chronic alcoholism has deleterious effects in mammals and in particular upon the small intestine (Baraona et al., 1974; Buell and Beck, 1984; Nishizawa et al., 1987). During ethanol ingestion the upper gastrointestinal tract is exposed to concentrations of ethanol several times higher than those attained in other tissues. This raises the possibility of a direct enterotoxic

effect of ethanol. In fact, ingestion of ethanol is known to injure the gastric mucosa (Slomiani et al., 1984; Oates and Hakkinen, 1988). In contrast, its effects on the duodenum are less well established (Baraona et al., 1974; Pitchumoni and Glass, 1977; Casini et al., 1999). It is widely accepted that excessive intake of ethanol may cause duodenitis (Fox et al., 1978), although this is not supported by conclusive evidence. Along this line, the existence of alcoholic duodenitis seems to be based on somewhat inadequate evidence (Pitchumoni and Glass, 1977). Chronic ingestion of ethanol leads to the production of blebs and broken blebs in the small intestine of hamsters and rats, respectively (Nishizawa et al., 1987). Studies in humans with a high prevalence of alcohol abuse have indicated that histological changes in duodenum appear as focal areas of subepithelial haemorrhage accompanied by increased numbers of eosinophils in the lamina propria (Dalton, 1951). Endoscopic investigation in humans has shown that beer, wine and whisky induce injury on the gastric mucosa, but to a lesser extent than the comparable pure ethanol solutions, and no lesions were observed in the duodenum (Knoll et al., 1998). Damaging effects of alcohol are frequently the cause of hemorrhagic erosions in the stomach and/or the duodenum, which may lead to massive bleeding (Bode and Bode, 2000). Recent work has indicated that chronic ethanol promotes morphological alterations of the mucosa, the initial lesion being manifested as subepithelial accumulation of proteinaceous fluid and subsequent bleb formation in all species studied (Buell and Beck, 1984). Acute alcohol ingestion can damage the mucosa in the upper region of the small intestine and may lead to the disruption of the tip of the villi (Bode and Bode, 2000). In contrast to the relatively large number of studies on chronic ethanol action, to our knowledge there are very few data on the chronic ingestion of other short chain alcohols. Pentanol and other short chain alcohols constitute the "fusel oils" which are present in all distilled beverage alcohol. Pentanol, a highly toxic and poor water-soluble alcohol, is obtained by fermentation of the proteins associated to the carbohydrates present in starch. Recent works have

Offprint requests to: J. Vaquera, Department of Cell Biology and Anatomy, Campus de Vegazana, University of Leon, 24071 León, Spain. e-mail: dbcjvo@unileon.es

shown that chronic ingestion of either n-butanol (Muñoz et al., 1990, 1991a) or isopropanol (Muñoz et al., 1991b) by the rat leads to an adaptation of in vitro brain protein synthesis to the acute disordering effects of both ethanol and isopropanol. Finally, in the small intestine alcohol abuse interferes with the absorption of glucose, aminoacid, lipids, water, sodium and vitamins and may contribute to nutritional deficiencies frequently observed in alcoholics (Mincis et al., 1995; Bode and Bode, 2000). The aim of the present work was to study the potential morphological and morphometric changes of the rat duodenum induced by chronic ingestion of short chain alcohols, other than ethanol, present in alcoholic beverages. These results will be compared with the effects of chronic ingestion of ethanol. Here in we report our results on the action of chronic feeding with pentanol.

Materials and Methods

Animals and treatment

Thirty adult male Wistar albino rats weighing 200-250g from our colony were used for this study. Rats were housed individually in plastic cages (Polycarbonate type III Techniplast, Italy) and placed in a room at 21±1 °C temperature, humidity: 55±10%, 12:12 h light/dark cycle. The animals were divided into ethanol-treated rats (group A; 10 rats), pentanol-treated rats (group B; 10 rats) and control rats (group C; 10 rats). Chronic exposure to either ethanol or pentanol was carried out by giving the rats a solution containing the alcohol as the only available beverage. The schedule for ethanol was 5% (v/v) for the first week, 10% (v/v) for the second week, and 15% (v/v) until their sacrifice. The schedule for pentanol was 1% (v/v) for the first week, 2% (v/v) for the second week, and 4% (v/v) until their sacrifice (4% pentanol is the lowest concentration found injury on the duodenum morphology). The whole treatment took 15 weeks. Control animals received a solution in which alcohol was replaced isocalorically by sucrose. The three groups (A, B, and C) had free access to beverage and pellet food (Rodent maintenance diet A04, Panlab, Spain: Crude protein 15.5%, crude fat 2.7%, crude fiber 3.7%, metabolizable energy 3000 kcal/kg). The procedures and husbandry conditions were in accordance with the European and Spanish Regulations for the protection of experimental animals (Council Directive 86/609/CEE and Real Decreto 223/88, respectively).

Preparation of tissue for microscopy

The animals were anaesthetized by an intraperitoneal injection of sodium-pentobarbital (50 mg/Kg of body weight) and after which the abdominal cavity was opened. Thereafter, the aorta was cannulated with a polyethylene catheter, infusing fixative solution of 2% glutaraldehyde in 0.1M phosphate buffer (pH 7.4). For morphological studies, duodenal segments of approximately 2 mm in length were kept in the fixative solution overnight and then postfixed for 2h in 1% Osmium tetroxide. Thereafter the samples were dehydrated and embedded in Epon 812. Sections of 0.5 mm were cut and stained with 0.5% toluidine blue stain for light microscopy.

Morphometric and statistics analysis

The arithmetic mean thickness of the epithelium (T) was assessed by counting the number (N) of intersections of the lines of a lattice square with the epithelium and the number (P) of end-points lying on the epithelium according to a procedure described elsewhere (Weibel and Knight, 1964), using the equation:

$$T = \frac{P \cdot Z}{N \cdot M}$$

Z: test point distance; M: magnification of micrographs.

The ratio of goblet cells and mononuclear infiltrate cells to absorptive cells was established by counting a total of 1200 cells along the length of at least four perpendicularly sectioned villi. Results are expressed as means ± S.E. (Standard error). The significance of data was assessed by the ANOVA test with Tukey comparison test or Student's t – test for two independent samples.

Results

Chronic short chain alcohol ingestion in the rat promoted consistent changes in their feeding pattern. As shown in Table 1, control animals ingested 44% and 13% more fluid and food than ethanol-fed animals and pentanol-fed animals respectively. The amount of body weight gained for control animals was statistically significant with respect to ethanol-fed and pentanol-fed animals, but the amount of body weight gained for ethanol-fed animals was not statistically significant with

Table 1. Effects of chronic consumption of either ethanol or pentanol on fluid and food intakes and weight gain. Values are means ± S.E. Number of rats 30

ANIMAL GROUP	FLUID COMSUMPTION (ml/day)	FOOD COMSUMPTION (g/day)	WEGHT GAIN (g/week)
Ethanol-fed	25.28±0.74*	13.96±0.33**	3.57±0.65#
Pentanol-fed	39.15±1.36*	18.03±0.23**	3.96±0.80#
Control	44.17±0.90*	22.41±0.30**	4.24±0.90#

*: p<0.05 ANOVA and TUKEY comparison test.; **: p<0.05 ANOVA and TUKEY comparison test; #: p<0.05 ANOVA and TUKEY comparison test.

respect to pentanol-fed animals. Table 2 shows the data concerning the total amount of calories ingested by both groups of alcohol-fed animals. Since both groups of

alcohol-fed rats received the same amount of alcohol calories and gained the same weight, it seems that the differences in fluid and food ingestion could be

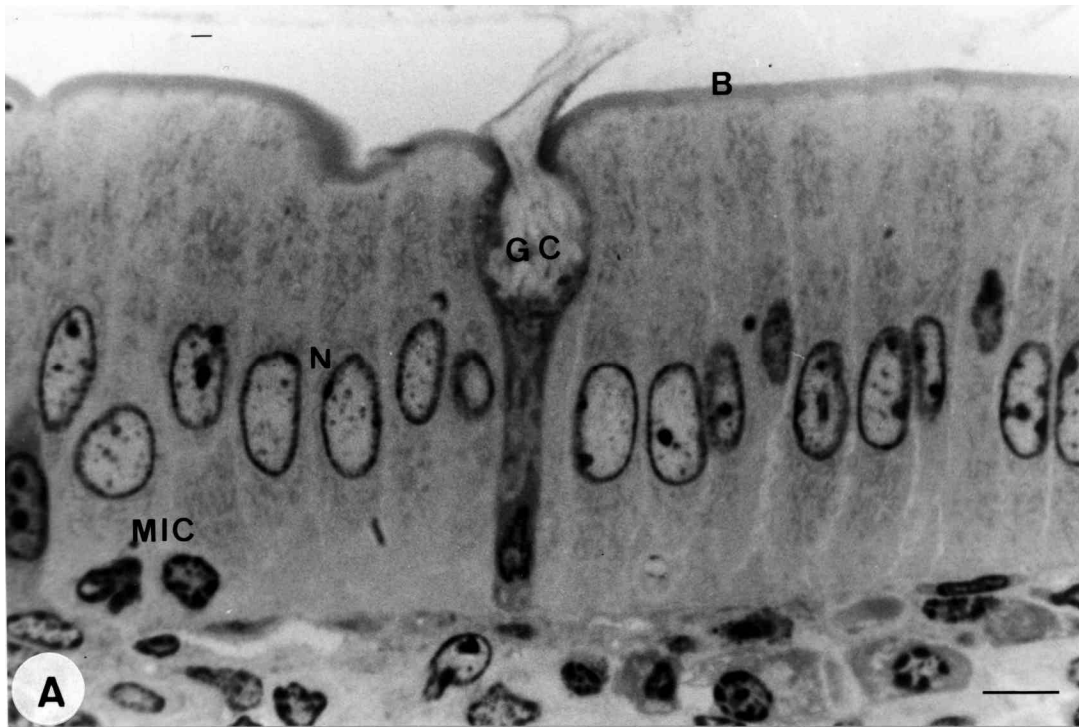
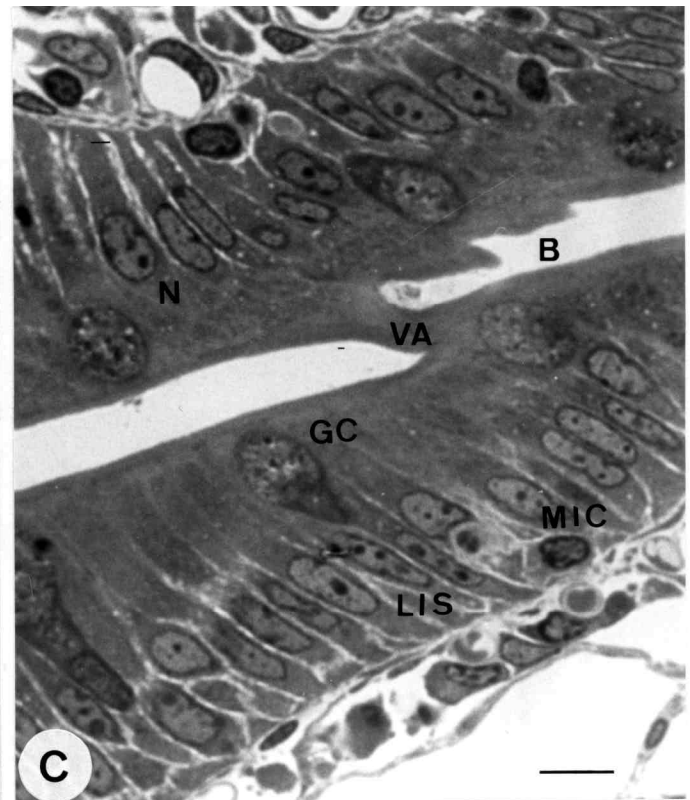
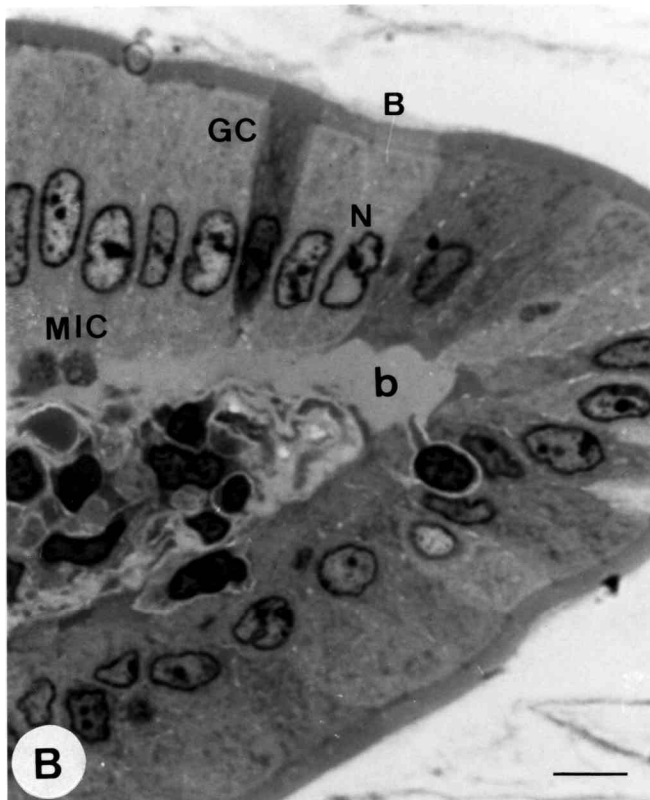


Fig. 1. Light microscopy photographs showing the effects of chronic ingestion of either ethanol and pentanol on rat duodenum morphology. **A.** Control duodenum. The villus epithelium is continuous and undamaged. Enterocytes are columnar with a well-defined brush border (B). **B.** Duodenum exposed to 15% (v/v) ethanol. The villi show bleb formation (b) laterally in the upper half of the villi. The blebs contain proteinaceous material and always seem to remain intact. **C.** Duodenum exposed to 4% (v/v) pentanol. The epithelial cells show lateral intercellular spaces (LIS) and intervillus adhesion (VA). Bar: 20 μ m.



promoted by a potential alcohol consumption-triggered tissue derangement rather than due to a metabolic effect, related to the oxidation of the alcohol carbon backbone, since the final point (weight gain) was the same. Other results from our laboratory have shown that pentanol is oxidized by rat liver cell-free extracts at a rate close to that of ethanol (data not shown). We then investigated the potential alcohol-promoted micromorphology derangement of the rat digestive tract, which is the first barrier to the entry of alcohol to the plasma. Since the duodenum is the first part of the tract that is unprotected to chemical injury, we first centered our study in this tissue. As shown in Fig. 1, control duodenal segments showed the typical morphology of this region. Finger-like villi were covered by a continuous columnar epithelium with a well-defined brush border (B). The median thickness of the columnar epithelium and brush border were, respectively, $32.82 \pm 1.04 \mu\text{m}$ and $1.58 \pm 0.24 \mu\text{m}$. The epithelial cells were closely adhered to the lamina propria and showed no lateral spaces. These cells had oval, poorly-stained nuclei (N) arrayed in a pseudoarrow located at the junction of the middle and basal thirds of the cell (Fig. 1A). An average of 11.4 ± 0.52 goblet cells (GC) and 14.6 ± 0.38 mononuclear infiltrate cells (MIC) per one hundred epithelial cells were present among the enterocytes. These goblet cells had a basally compressed oval nucleus with clumped chromatin and prominent nucleoli and were filled with mucoid material. The duodenal mucosa of rats exposed to 15% (v/v) ethanol was characterized by villi covered with a columnar epithelium of median height: $22.43 \pm 4.42 \mu\text{m}$ (Fig. 1B), a decrease statistically significant with respect to control animals but not to pentanol-fed animals. The epithelial cells of the mucosa were covered by a $1.37 \pm 0.15 \mu\text{m}$ -thick brush border (B) composed of microvilli and a glycocalyx. The enterocytes contained oval, poorly-stained nucleus (N) arrayed in a row near the base of the cell. An average of 13.15 ± 0.48 goblet cells (GC) and 26 ± 0.67 mononuclear infiltrate cells (MIC) per one hundred epithelial cells were present among the columnar epithelium. The amount of MIC in the ethanol-fed animals was higher and statistically significant with respect to control but not with respect to pentanol-fed animals. Goblet cell morphology was similar to that of the goblet cell in group C. Blebs (b) were occasionally found at the apex of the villi or laterally in their upper half. They were originated in the detachment of the surface epithelium from the underlying basal lamina and contained a proteinaceous material with a few remaining stroma cells. The lamina

propria directly under the blebs appeared to be compressed. The epithelial layers circumscribing the upper part of the blebs were intact and presented a normal brush border. Exposure of the rat duodenum to 4% (v/v) pentanol produced important changes (Fig. 1C). The general structure of the villi was normal but all their elements were modified as compared to the control and ethanol-fed animals. The median height of the columnar epithelium was $25.64 \pm 2.68 \mu\text{m}$; the decrease was statistically significant with respect to control animals. The epithelial cells were closely adhered to the lamina propria and showed lateral intercellular spaces (LIS). The enterocytes presented an oval nucleus with clumped chromatin (N) arrayed in a row near the base of the cell and they were covered by a $2.2 \pm 0.41 \mu\text{m}$ -thick brush border (B). The increase was statistically significant with respect to control and ethanol-fed animals. An average of 13.5 ± 0.35 goblet cells (GC) and 20.4 ± 0.63 mononuclear infiltrate cells (MIC) per one hundred epithelial cells were encountered among the enterocytes in the columnar epithelium. The morphology of the goblet cells was similar to that of the goblet cells in the control and pentanol-fed animals. Some abnormalities in the villi, such as intervillus adhesion (VA), were also common. No pentanol feeding-dependent bleb formation was detected in our samples.

Discussion

This study shows that chronic ingestion of either ethanol or pentanol has an adverse effect on the morphology of the duodenal epithelial layers. The ethanol-induced morphological alteration observed in the upper small intestine of several species seems to consist initially of an accumulation of subepithelial fluid leading to the detachment of the epithelium from the subjacent lamina propria, a process known as bleb formation (Nishizawa et al., 1987). Our findings with the ethanol-fed animals support this view and indicate that bleb formation must take place at the apex of the villus or laterally, in the upper half of the villi, accompanied by the detachment of the surface epithelium from the underlying lamina propria. These subepithelial blebs always seem to be intact. The pentanol-fed rats did not present either blebs or broken blebs, in clear contrast to the results obtained with ethanol-fed animals and with previous reports describing broken blebs in ethanol-fed rats (Nishizawa et al., 1987). Goblet cell increase was more common in the ethanol- and pentanol-fed rats than in the control animals, but was not statistically

Table 2. Mean intake of alcohol and calories per day in groups A and B. Values are means \pm S.E. Number of rats 30.

GROUP	ALCOHOL CONSUMPTION (g/day)	ALCOHOL CALORIES (Kcal/day)	TOTAL CALORIES (kcal/day)
Ethanol-fed	3.01 ± 0.13	$21.4 \pm 0.30^*$	$63.29 \pm 1.05^{**}$
Pentanol-fed	1.27 ± 0.05	$11.5 \pm 0.24^*$	$65.59 \pm 0.71^{**}$
Control	-	-	$83.63 \pm 0.50^{**}$

*: $p < 0.05$ Student t-test – 2 samples; **: $p < 0.05$ ANOVA and Tukey comparison test.

significant. This partially agrees with previous studies (Millan et al., 1980), since the mean goblet cell counts found here were approximately twice those reported. The increase in goblet cells in the alcohol-fed animals seems to be related to the development of chronic duodenitis. Intraepithelial mononuclear cells were common in all villi and seem to appear in large amounts. They could be inflammatory cells or dying cells, which are being sloughed. Quantification of the mononuclear cells among the columnar epithelium indicates that they were higher and statistically significant in the ethanol- and pentanol-fed rats with respect to the control animals. This is consistent with the reports of other workers who have described that mononuclear cell counts in duodenum of the cat (Henry and Al-Bagdadi, 1986) and acute ethanol intake (Millan et al., 1980), were higher in some cases of duodenitis. Intervillus adhesions, which are believed to be of inflammatory origin, were commonly observed in pentanol-treated rats but were never found in either the control or ethanol-fed groups. We found a direct correlation between the changes in the thicknesses of the epithelium and brush border of the alcohol-fed rats. The brush border thickness of pentanol-fed rats was higher than the values reported for ethanol feeding by Saario et al. (1988). The fact that 5% (v/v) of the ethanol-fed rats but not the pentanol-fed nor the control animals produced blebs suggests that ethanol per se would have a specific cellular metabolism-related mechanism able to induce morphological changes. In particular, concerning protein metabolism, it has recently been found that alcohols significantly alter protein synthesis (Girbes et al., 1989; Muñoz et al., 1990a, 1991b). However, ethanol has a specific action that is not shown by other alcohols in that it promotes the impairment of the cellular machinery, perhaps through the generation of a highly reactive compound such as acetaldehyde (Girbes and Alonso, 1986; Girbes, 1986; Majumdar et al., 1986). With regard to the gastric mucosa, recent studies have indicated that ethanol inhibits the sulfation of both galactosylceramide and lactosylceramide, thus leading to advanced cellular exfoliation and multiple gastric erosions (Slomiany et al., 1984). Our results also indicate that, at microscopic levels, pentanol does not share such effects with ethanol. What does seem clear from biochemical and structural studies is that ethanol promotes unique and characteristic destructive effects of the multicellular structure of the duodenum which most probably arises from its effects on the synthesis and metabolic transformation of structural macromolecules.

References

- Baraona E., Pirola R.C. and Lieber C.S. (1974). Small intestinal ingestion in the rat. *Gastroenterology* 66, 226-240.
- Bode J.C. and Bode C. (2000). Alcohol, the gastrointestinal tract and pancreas. *Ther. Umsch.* 57, 212-219.
- Buell M.K. and Beck I.T. (1984). Ethanol-induced mucosal microvascular stasis and enhanced plasma protein loss in the dog jejunum. *Gastroenterology* 86, 413-420.
- Casini A., Galli A., Calabro A., Di Lollo S., Orsini B., Arganini L., Jezequel A.M. and Surrenti C. (1999). Ethanol-induced alterations of matrix network in the duodenal mucosa of chronic alcohol abusers. *Virchows Arch.* 434, 127-135.
- Dalton A.J. (1951). Electron micrography of epithelial cells of the gastrointestinal tract and pancreas. *Am. J. Anat.* 89, 109-131.
- Fox J.E., McElligott T.F. and Beck I.T. (1978). Effect of ethanol on the morphology of hamster jejunum. *Digest. Dis.* 23, 201-209.
- Girbes T. (1986). The acute effects of ethanol on protein synthesis in isolated rat liver cells are pH-dependent. *Biochem. Int.* 2, 310-313.
- Girbes T. and Alonso P. (1986). Inhibition of protein synthesis by (aminooxy) acetate in rat liver. *Int. J. Biochem.* 18, 537-542.
- Girbes T., Ferreras J.M., Muñoz R. and Alonso P. (1989). Effect of acute ethanol administration and nutritional status on secretory protein synthesis in isolated rat liver cells. *Toxicol. In Vitro* 3, 7-12.
- Henry R.W. and Al-Bagdadi F.K. (1986). Duodenal microanatomy of the domestic cat. *Histol. Histopathol.* 1, 355-362.
- Knoll M.R., Kolbel C.B., Teyssen S. and Singer M.V. (1998). Action of pure ethanol and some alcoholic beverages on the gastric mucosa in healthy humans: a descriptive endoscopic study. *Endoscopy* 30, 293-301.
- Majumdar A.P.N., Haiman M.J., Zylbert B.A., Billy H.T., Vesenska G.D. and Geodas M.C. (1986). Acetaldehyde inhibition of protein synthesis in isolated rat pancreatic acini. *Toxicol. Appl. Pharm.* 83, 86-94.
- Millan M.S., Morris G.P., Beck I.T. and Henson J.T. (1980). Villous damage induced by suction biopsy and by acute ethanol intake in normal human small intestine. *Digest. Dis. Sci.* 25, 513-525.
- Mincis M., Chebli J.M., Khouri S.T. and Mincis R. (1995). Ethanol and the gastrointestinal tract. *Arq. Gastroenterol.* 32, 131-139.
- Muñoz R., Ferreras J.M., Iglesias R., Merino M.J. and Girbes T. (1990). Adaptation of in vitro rat brain protein synthesis to long-term ingestion of n-butanol. *Brain Res.* 51, 330-333.
- Muñoz R., Iglesias R., Ferreras J.M., Arias J., Rojo A. and Girbes T. (1991a). Effect of long-term n-butanol ingestion on rat brain polypeptide synthesis directed by endogenous messengers. *Cell. Mol. Biol.* 37, 671-677.
- Muñoz R., Iglesias R., Ferreras J.M., Rojo A., Arias J. and Girbes T. (1991b). Changes in sensitivity of in vitro rat brain protein synthesis to the acute action of ethanol and isopropanol as a consequence of the long-term ingestion of isopropanol. *Arch. Toxicol.* 65, 500-504.
- Nishizawa Y., Sakurai H., Yamato C. and Moriga M. (1987). Effects of ethanol alone or after pretreatment with 20% ethanol on phospholipid metabolism in rat gastric mucosa. *Biochem. Biophys. Acta* 917, 372-380.
- Oates P.J. and Hakkinen J.P. (1988). Studies on the mechanism of ethanol induced gastric damage in rats. *Gastroenterology* 94, 10-21.
- Pitchumoni C.S. and Glass G.B.J. (1977). Alcohol injury to gastrointestinal mucosa. In: *Progress in gastroenterology*. Glass G.B.J. (ed). Grune and Stratton. New York. pp 717-758.
- Saario I., Rosen S., Carter K. and Silen W. (1988). Effect of ethanol on frog gastric mucosa. *Gastroenterology* 94, 638-646.
- Slomiany A., Jozwiak Z., Liao Y.H., Murty V.L.N. and Slomiany B.L. (1984). Effect of ethanol on the enzymatic sulfation of glycosphingolipids in gastric mucosa. *J. Biol. Chem.* 259, 592-596.
- Weibel E.R. and Knight B.W. (1964). A morphometric study on the thickness of the pulmonary air-blood barrier. *J. Cell. Biol.* 21, 367-384.