

## Review

# Hepatitis C virus-associated mixed cryoglobulinemia. Clinical manifestations, histopathological changes, mechanisms of cryoprecipitation and options of treatment

P. Schott<sup>1</sup>, H. Hartmann<sup>2</sup> and G. Ramadori<sup>3</sup>

Department of Medicine, <sup>1</sup>Division of Cardiology, <sup>3</sup>Division of Gastroenterology and Endocrinology, Georg-August-University, Goettingen and <sup>2</sup>St. Martini Hospital, Duderstadt, Germany

**Summary.** Chronic hepatitis C virus (HCV) infection is frequently associated with a variety of autoimmune phenomena. Mixed cryoglobulinemia (MC) appears in up to 50% of chronic HCV-infected patients. Cryoglobulins consist of immunoglobulin complexes precipitating *in vitro* when cooled below body temperature. In most cases IgM with rheumatoid factor activity is found in cryoprecipitates which could lead to vasculitis induced by the deposition of immunocomplexes in small vessels. This vasculitis is thought to cause clinical symptoms called Meltzer's triad. This triad is represented by purpura, arthralgia and weakness. One third of patients suffering from HCV-associated mixed cryoglobulinemia are developing typical symptoms during their course of disease.

The striking association between HCV infection and MC has conducted to the hypothesis that HCV is of major importance in the production of MC with followed vasculitis.

Both hepatrophism and lymphotrophism have been reported for the hepatitis C virus. Infection of B-cells by HCV could probably lead to a *bcl-2* translocation and immunoglobulin gene rearrangement which results in clonal lymphoproliferation and in synthesis of monoclonal IgM with rheumatoid factor activity. These IgM form immunocomplexes with IgG in the cold, which are finally responsible for the described vasculitis.

Histopathological changes of the liver are dominated by chronic HCV infection. The majority of times mild activity of hepatitis or mild fibrosis could be found. Nevertheless, cirrhosis is more often found in HCV-infected patients suffering from MC compared to patients without MC.

Conventional treatment of MC is aimed to reduce circulating immune complexes by immunosuppression and plasmapheresis. With the emerging concept of a viral pathogenesis the therapeutic approach has changed during the last decade. Interferon treatment of MC, particularly of HCV-associated MC is well established nowadays.

**Key words:** Hepatitis C virus infection, HCV, Mixed cryoglobulinemia, MC, Interferon treatment, Histopathology

### The syndrome of cryoglobulinemia, a historical review

As early as 1929 the phenomenon of cryoprecipitation during formation of immune complexes was described by Heidelberger and Kendall (1929). Cold-induced precipitation of serum proteins was observed in a patient suffering from multiple myeloma in 1933 for the first time (Wintrobe and Buell, 1933). In 1947 the term cryoglobulinemia was established for the syndrome of precipitating immunoglobulins in the cold (Lerner and Watson, 1947). Typical clinical symptoms associated with cryoglobulinemia, particularly the triad of arthralgia, purpura and weakness were described by Meltzer and Franklin (1966). The clinical manifestation of the syndrome is thought to be caused by deposits of circulating immune complexes in small vessels via complement activation (Meltzer and Franklin, 1966; Brouet et al., 1974; Invernizzi et al., 1979; Gross, 1994; Gumber and Chopra, 1995). In 1974 Brouet et al. (1974) described the composition of cryoglobulins and proposed a classification of cryoglobulinemia into type I, II and III based on the type of immunoglobulin that constitutes the cryoprecipitate.

Offprint requests to: Prof. G. Ramadori, Medizinische Universitätsklinik, Abteilung Gastroenterologie, Robert-Koch-Straße 40, 37075 Goettingen, Germany. Fax: 551-398596. e-mail: gramado@med.uni-goettingen.de

According to this classification type I consists of only one monoclonal immunoglobulin subtype, most frequently IgM, occasionally IgG, and quite rarely IgA.

Type I cryoglobulinemia is most frequently found in patients suffering from lymphoproliferative disorders, e.g. multiple myeloma, Waldenström's disease, chronic lymphocytic leukemia (Brouet et al., 1974).

Type II includes cryoglobulins composed of a mixture of different immunoglobulin isotypes. One of these isotypes is monoclonal. In general the later one is an IgM with rheumatoid factor activity bound to polyclonal IgG.

Type III is represented by a mixture of at least two different immunoglobulins without monoclonality. In practice, the association of polyclonal immunoglobulins is the most frequent.

Type II and type III are called mixed cryoglobulinemias due to their composition of at least two different immunoglobulin isotypes. The frequency of cryoglobulinemia subtypes according to Brouet et al. (1974) is given in Table 1.

This classification created a common language for several years, but did not consider the cause of cryoglobulinemia and the prognosis, which seems to be dominated by the associated disease. Based on two-dimensional polyacrylamide gel electrophoresis analysis Tissot et al. (1994) demonstrated that further subtypes of

cryoglobulins exist. Besides monoclonal and polyclonal IgM, as described by Brouet et al. (1974), oligoclonal IgM were detected by Tissot et al. The authors proposed an extension of the type I, II and III cryoglobulinemia by type II-III with a oligoclonal component (Fig. 1). A shift from type III (polyclonal) via type II-III (oligoclonal) to type II (monoclonal) during a longer duration of disease was hypothesized by the authors.

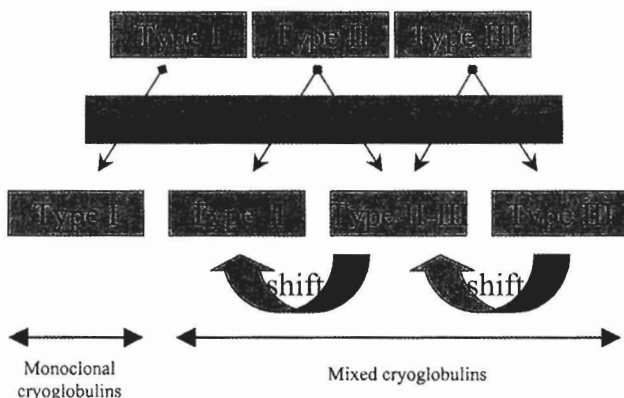
### Essential mixed cryoglobulinemia or viral-associated cryoglobulinemia?

A variety of diseases have been reported to be linked to cryoglobulinemia. Particularly, type I cryoglobulinemia is closely associated to lymphoproliferative disorders (Brouet et al., 1974), while mixed cryoglobulinemias are more often found in acute and chronic viral infections. Nevertheless, mixed cryoglobulinemias were often observed without any other disease. These mixed cryoglobulinemias were called essential mixed cryoglobulinemia (EMC). In the seventies a correlation of chronic HBV infection to EMC has been discussed (Levo et al., 1977; Gocke et al., 1979) but could not be confirmed by following studies (Galli et al., 1980; Popp et al., 1980). In 1990 3 cases of HCV-associated mixed cryoglobulinemia were described after the development of diagnostic procedures for detection of HCV infection (Pascual et al., 1990). This observation could be confirmed by a study of Ferri et al. (1991). The authors found markers of HCV infection in 91% of 41 patients suffering from so-called EMC. In the following years data of several authors supported the association of HCV and so-called EMC (Agnello et al., 1992; Dammaco and Sansonno, 1992; Galli et al., 1992; Misiani et al., 1992; Pechere-Bertschi et al., 1992; Lunel et al., 1994; Hartmann et al., 1995). Nowadays so-called EMC seems to be strongly correlated to chronic HCV infection.

### Prevalence and demographic data of HCV-associated mixed cryoglobulinemia

Up to 50% of chronic HCV-infected patients are going to develop mixed cryoglobulinemia during their course of disease (Lunel et al., 1994; Hartmann et al., 1995; Cacoub et al., 2000). There is a female prevalence of about 60-70 %, particularly in patients with renal involvement (Gorevic et al., 1980). Patients suffering from HCV-associated mixed cryoglobulinemia are significantly older compared to HCV-infected patients

### Classification according to Brouet et al. (1974)



**Fig. 1.** Relation between the different cryoglobulin classifications according to Brouet et al. (1974) and Tissot et al. (1993). A shift from type III via type II-III to type II could be observed during long lasting duration of disease. 2D-PAGE: two-dimensional sodium dodecylsulfate polyacrylamide gel electrophoresis. Figure according to Tissot et al. (1993).

**Table 1.** Frequency of type I-III in cryoglobulinemia according to published data.

AUTHOR	Brouet et al. (1974)	Gorevic et al. (1980)	Tarantino et al. (1981)	Hartmann et al. (1995)
classified patients	29	40	96	28
Type I	17%	0%	5%	0%
Type II	7%	32.5%	42%	33.3%
Type III	76%	67.5%	53%	66.6%

without mixed cryoglobulinemia and show a longer lasting duration of HCV infection (Lunel et al., 1994; Hartmann et al., 1995). The average age at the diagnosis of the disease is about 50 years and the apparent duration of HCV infection is about 10-11 years (Hartmann et al., 1995). The interval between the diagnosis of cryoglobulinemia and the appearance of typical symptoms is variable. It varies from 0 to 10 years, but in isolated patients, it has even been as long as 37 years (Tarantino et al., 1981). Table 2 gives an overview about demographic and clinical data in HCV-associated mixed cryoglobulinemia. Almost two thirds of patients with HCV-associated cryoglobulinemia are classified as type III according to Brouet et al. (1974), while only one third have monoclonal immunoglobulins of the subtype M and are classified as type II. Type I mixed cryoglobulinemia seems to be quite rare in chronic HCV infection (Lunel et al., 1994; Hartmann et al., 1995).

### Clinical symptoms of cryoglobulinemia

#### Cutaneous symptoms

The most frequent manifestation of cryoglobulinemia is purpura of the lower extremities. Involvement of upper extremities and abdomen or buttocks have been reported as well. Petechiae and papulae as well as livedo and even ulceration can be observed. Skin biopsies reveal a leukocytoclastic dermal vasculitis, which is thought to be caused by deposits of the cryoglobulin immunocomplexes in small vessels (Gross et al., 1994). Vascular purpura tends to be more often frequent in type II and III than in type I cryoglobulinemia (Montagnino, 1988). Skin necrosis are rare compared to purpura. The overall incidence varies from 11% up to 30% and is more often linked to type I cryoglobulinemia (Invernizzi et al., 1979; Gorevic et al., 1980).

Figure 2 shows skin lesions of a female patient suffering from HCV-associated MC type II and the course under interferon- $\alpha$  treatment.

As an early cutaneous symptom of cryoglobulinemia Raynaud's phenomenon could be observed in about 25-50% of cryoglobulinemic patients.

#### Arthralgias

About 10-91% of cryoglobulinemic patients suffer from arthralgia (Popp et al., 1980; Tarantino et al., 1981; Montagnino, 1988; Lunel et al., 1994; Hartmann et al., 1995; Cacoub et al., 2000). They seem to be more frequent in type II and III compared to type I. Patients show polyarthralgias with a symmetrical and not migratory pattern. All joints could be involved, but proximal interphalangeal joints, metacarpophalangeal joints and knees are most often involved. In some cases pain and joint stiffness appeared after cold exposure. Weinberger et al. (1985) performed x-rays of cryoglobulinemic patients and found cyst-like deformation of proximal and distal interphalangeal joints in 5 out of 11 patients.

#### Weakness

The majority of patients with HCV-associated mixed cryoglobulinemia suffer from weakness (Lunel et al., 1994; Hartmann et al., 1995). Whether this is a cause of mixed cryoglobulinemia or caused by chronic HCV infection remains unclear.

#### Renal involvement

The incidence of renal disease in mixed cryoglobulinemia varies from 8% to 58% (Jori and Buonano, 1972; Brouet et al., 1974; Levo et al., 1977; Bombardieri et al., 1979; Invernizzi et al., 1979; Popp et al., 1980; Lunel et al., 1994; Monti et al., 1995; Adinolfi et al., 1996). Adinolfi et al. (1996) observed haematuria in 37%, proteinuria in 29% and even renal failure in 14% of patients with cryoglobulinemia associated to chronic HCV infection. In further studies severe renal involvement was observed less frequently in HCV-associated mixed cryoglobulinemia (Lunel et al., 1994; Hartmann et al., 1995; Polzien et al., 1997). Almost all the kidneys of patients with EMC or HCV-associated nephritis show endocapillary proliferation, varying from focal to diffuse. In 60% to 80% of cases the main feature is a membranoproliferative glomerulonephritis (Montagnino, 1988). One of the most specific findings is

**Table 2.** Demographic and clinical data of 55 patients with chronic HCV infection according to data of Hartmann et al. (1995).

	TOTAL (n=55)	PATIENTS WITH CRYOGLOBULINEMIA (n=28)	PATIENTS WITHOUT CRYOGLOBULINEMIA (n=27)	p
Age (yr)	47.5±13.1	51.3±12.3	41.9±14.2	< 0.02*
Sex ratio (M/F)	27/28	10/18	17/10	< 0.02***
Apparent duration of disease (yr)	7.6±6.3	10.7±7.2	4.7±5.0	< 0.05**
Purpura (%)	9.0	18.2	0	< 0.02***
Arthralgias (%)	4.3	9.1	0	NS
Sicca Syndrome (%)	3.6	3.6	3.6	NS
Clinically advanced liver diseases (%) <sup>a</sup>	14.5	28.6	0	< 0.02 ***

Data are means±SD. <sup>a</sup>: presence of esophageal varices and/or ascites(encephalopathy); NS: not significant; \*: two-tailed unpaired t-test; \*\*: one-tailed unpaired t-test; \*\*\*:  $\chi^2$ -test.

the presence of numerous large amorphous thrombi lying on the endothelial side of the glomerular basement membrane and occluding the capillary loop lumina. These deposits indicate the presence of monoclonal immunoglobulins in the cryoprecipitate. Furthermore vasculitis could be observed in one third of the cases.

#### *Rare symptoms*

Besides the described clinical manifestations neurological involvement, in general peripheral neuropathy, gastrointestinal involvement, lung involvement and Sjögren's syndrome could be observed in a minority of patients (Montagnino et al., 1988).

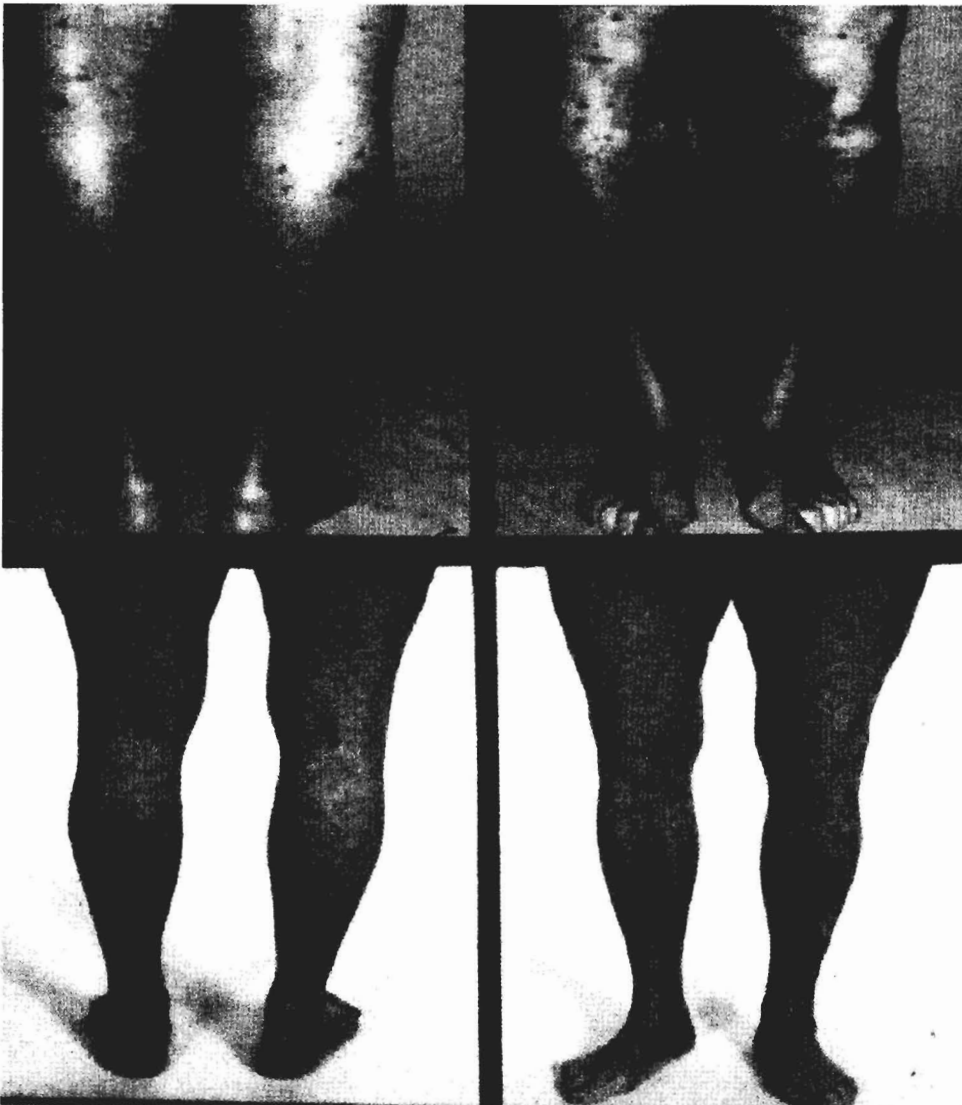#### **Laboratory features of HCV-associated mixed cryoglobulinemia**

Laboratory patterns of HCV-associated MC can be

divided into HCV-caused and MC-associated biochemical changes. Patterns like elevated transaminases or even biochemical constellation of liver cirrhosis are caused by the chronic HCV infection in these patients. Due to the existence of cryoglobulins the following biochemical abnormalities can be observed:

#### *Detection of cryoglobulins in serum*

There is no standard method described for detection of cryoglobulins, so far. The most common used method was described in 1970 (Schuboth and Westerhausen, 1970). Cryoglobulins are detected after incubation of serum at 4 °C by a visual precipitate. The precipitates are quantified in vol% of 1 ml serum. The so-called cryocrit levels range from 0.1% up to over 30% in chronic HCV-infected patients (Lunel et al., 1994; Pingel et al., 1994; Hartmann et al., 1995) and seem to be higher in patients suffering from MC type II compared to



**Fig. 2.** Course of skin lesions and purpura under interferon- $\alpha$  treatment of a female patient with HCV-associated MC type II and high levels of cryocrit (30 Vol %). After initiation of interferon- $\alpha$  therapy a continuously improvement of the skin lesions could be observed.

type III. Different methods of cryoglobulin detection (incubation at 4 °C for 24 up to 72 hours etc.) may have resulted in discrepancies according to frequency and

amount of cryoprecipitates. Taken together, the published data of precipitate level and frequency suggest strong regional differences with a possible south-north gradient (Weiner et al., 1998).

Figure 3 shows a cryoprecipitate after serum incubation at 4 °C.

#### *High level of rheumatoid factor activity*

Patients suffering from mixed cryoglobulinemia show high levels of IgM rheumatoid factor activity. In a collective of chronic HCV-infected patients rheumatoid factor activity was found in all patients with MC, while none of the HCV-infected patients without MC had rheumatoid factor activity in sera (Hartmann et al., 1995). This rheumatoid factor activity is caused by the IgM fraction of the cryoprecipitates, which bounds IgG and forms immunocomplexes.

#### *Activation of the complement system*

Due to circulating immunocomplexes (Cacoub et al., 1994) and immunocomplex deposits in small vessels activation of the complement system in MC is observed. This leads to low levels of C4, C3 and CH50 (Ferri et al., 1991; Cacoub et al., 1994; Lunel et al., 1994) in sera of MC patients. Cacoub et al. (1994) even found significantly lower levels of C4 and CH50 in HCV-associated MC compared to EMC.

#### *Increase of serum immunoglobulin level and markers of cellular immune response*

Pathological serum concentrations of IgM were found by Hartman et al. (1995) in patients suffering from HCV-associated MC. Compared to patients infected by HCV without MC the IgM serum concentration was significantly higher in MC patients.

Besides markers of humoral immune response, an increase in cellular immune response markers as sIL2r, sICAM-1 and sCD30 could be observed, as well as an increase of sICAM-I which is a marker for endothelial damage (Lamprecht et al., 2001).

Table 3 gives an overview about typical HCV-associated MC-caused laboratory data.

#### **Histopathological changes**

Histological patterns of MC-caused vasculitis and of renal involvement have already been mentioned above.

Histopathology of the liver is dominated by chronic HCV infection. Most of the patients show mild activity of hepatitis, or mild fibrosis. As is typical for HCV infection, lymphocytic aggregates, bile duct damage, steatosis, and intracellular acidophilic bodies could be found in patients with and without MC. Fayyazi et al. (1997) observed an increased activity of chronic hepatitis ( $p=0.005$ ) and a higher grade of liver fibrosis with architectural distortion up to cirrhosis ( $p<0.05$ ) in



**Fig. 3.** Serum with a cryoprecipitate (cryocrit about 21 Vol%) after incubation at 4 °C for 48 hours.

patients suffering from HCV-associated MC compared to HCV-infected patients without MC. A higher rate of cirrhosis in patients with cryoglobulinemia has been

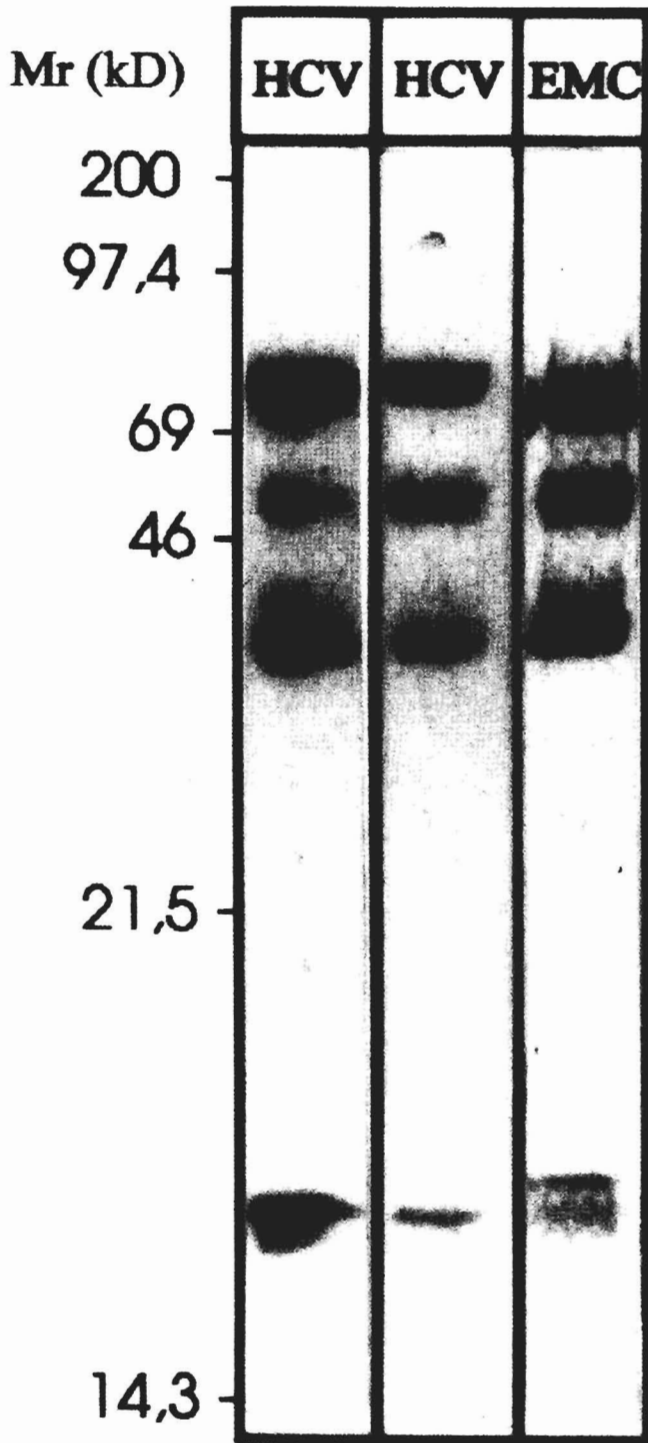


Fig. 4. SDS-PAGE analysis of different cryoprecipitates. Typical patterns are shown from two patients with chronic HCV infection and one patient with EMC. Molecular weight markers in kilo Daltons (kD).

observed in previous studies as well (Lunel et al., 1994, Hartmann et al., 1995). Sansonno et al. (1998) demonstrated that in chronic HCV infection intrahepatic monoclonal B cells could be found more often in patients with MC compared to patients without MC. Table 4 shows the histological data of 62 patients suffering from chronic HCV infection.

#### Composition of cryoprecipitates

In general, HCV-associated cryoprecipitates are composed of immunoglobulins. As described above, type I-III could be observed. Analysis by SDS-PAGE revealed the presence of at least four different proteins of apparent molecular mass of about 70, 50, 25 and 15 kDa respectively. Based on immunoblotting the 70 kDa protein was identified as corresponding to  $\mu$ -chains of IgM, the 50 kDa protein representing  $\gamma$ -chain of IgG and the 25 kDa protein corresponding to immunoglobulin light chains (kappa and lambda). The 15 kDa protein most likely represents IgM-joining peptides (Hartmann et al., 1995). There was no different protein pattern observed for patients with EMC compared to patients with HCV-associated MC (Hartmann et al., 1995). Figure 4 shows SDS-Page analysis of cryoprecipitates. In MC type II, polyclonal immunoglobulins were without exception of the IgG subtype and monoclonal antibodies were only of the IgM subtype, most times with kappa light chains in this study. Figure 5 shows immunofixation of MC type II for detection of monoclonality.

Besides immunoglobulins, HCV core particles and HCV RNA have been detected in the precipitates (Lunel et al., 1994). In 1992 even a 10- to 1000-fold enrichment of HCV RNA in cryoprecipitates compared to the serum of patients with MC type II has been described (Agnello et al., 1992). Data of Hartmann et al. (1995) could not confirm this enrichment of HCV RNA, while HCV RNA was detected in the precipitates as well.

#### Reactivity of cryoglobulins

##### Reactivity of cryoglobulin IgG to HCV-encoded proteins

As previously reported, we studied the reactivity of HCV-associated cryoglobulins and demonstrated the following data: cryoglobulins of the IgG subtype are reactive against HCV-encoded antigens. By using EIA and immunoblot techniques each of the analyzed precipitates (n=8) had anti-HCV IgG reactivity. This reactivity was directed to structural (nucleocapsid antigen C22) as well as to non-structural antigens (C 33c, NS 5, 5-1-1) of HCV. When comparing IgG reactivity to individual HCV-encoded proteins, the highest titer was noted against the nucleocapsid antigen C22. There was no enrichment of anti-HCV activity found in cryoprecipitates compared to cryoglobulin-free sera of these patients (Schott et al., 1998).

## HCV-associated mixed cryoglobulinemia

## Reactivity of cryoglobulin IgM to HCV-encoded proteins

By using EIA and immunoblot reactivity of cryoglobulin IgM against HCV-encoded proteins, particularly against the nucleocapsid antigen, has been

described (Hartmann et al., 1995), while others have not observed IgM reactivity against HCV antigens (Agnello et al., 1995) by analyzing complete precipitates. After separation of cryoglobulin IgG and cryoglobulin IgM fractions of HCV-associated cryoprecipitates no

**Table 3.** Laboratory features of 55 patients with chronic hepatitis C virus infection with or without mixed cryoglobulinemia as published by Hartmann et al. (1995).


	WITH CRYOBLOBULINEMIA (n=28)	WITHOUT CRYOGLOBULINEMIA (n=27)	p
AST (<17 U/l)	47.2±20.1	60.7±46.2	NS
γ-globuline-level (8.8-17%)	20.9±7.6	18.6±3.6	NS
Serum IgM (0.6-3.7 g/l)	3.7±2.2	2.2±1.5	< 0.05
C4 (20-50 mg/100ml)	18.9±10.0	23.8±6.4	< 0.05
Rheumatoid factor (<40 IU/l)	195.5±315.5	20.5±1.4	< 0.05

Data are means ± standard deviation, normal values in parenthesis.

**Table 4.** Grading, staging, and the prevalence of typical histological features in 62 patients with chronic HCV infection with or without MC (Fayyazi et al., 1997).

	PATIENTS WITH CRYOGLOBULINEMIA (n=30)	PATIENTS WITH CRYOGLOBULINEMIA (n=32)
<i>Hepatitis activity (HA)<sup>a</sup></i>		
Absent/nonspecific (0 ≤ HA <sup>a</sup> ≤ 3)	1	4
Mild (4 ≤ HA <sup>a</sup> ≤ 8)	13	23
Moderate (9 ≤ HA <sup>a</sup> ≤ 12)	13	4
Severe (13 ≤ HA <sup>a</sup> ≤ 18)	3	1
<i>Fibrosis (HA)<sup>b</sup></i>		
Absent (HA <sup>b</sup> =0)	3	8
Mild (HA <sup>b</sup> =1)	18	21
Severe (HA <sup>b</sup> =3)	4	2
Cirrhosis (HA <sup>b</sup> =4)	5	1
<i>Portal lymphocytic aggregates</i>	14	11
<i>Bile duct damage</i>	12	12
<i>Steatosis</i>		
Absent	14	19
Mild	6	4
Moderate	8	3
Severe	2	3
<i>Intracellular acidophilic bodies</i>	10	8

A significant association of cryoglobulinemia with increased activity of hepatitis (p=0.005) and with a higher grade of fibrosis (p<0.05) was observed. HA<sup>a</sup>: Histology activity changes containing the necroinflammatory changes. HA<sup>b</sup>: Histology activity changes containing the architectural alterations.



**Fig. 5.** Immunofixation of a purified cryoprecipitate type II. A polyclonal IgG and a monoclonal IgM of κ-light chain type could be detected. TSF: total serum fixation; κ: kappa-light chain; λ: lambda light chain.

reactivity for IgM fraction against HCV-encoded antigens was observed (Schott et al., 1998). After adding the isolated IgG fraction with reactivity against HCV antigens to the isolated IgM fraction, false positive IgM reactivity was detected due to rheumatoid factor activity of IgM (Schott et al., 1998). So cryoprecipitate IgM does not recognize HCV antigens.

#### Interaction of cryoglobulin IgG and IgM

Rheumatoid factor activity of the cryoprecipitate IgM has been well described (Brouet et al., 1974; Ferri et al., 1991; Lunel et al., 1994; Hartmann et al., 1995). The monoclonal IgM rheumatoid factor in MC type II bear in about 80% a cross-idiotype (Xid) designated WA. This type of monoclonal rheumatoid factor appears to occur predominantly in MC type II, and in polyclonal rheumatoid factors of patients with Sjögren's syndrome.

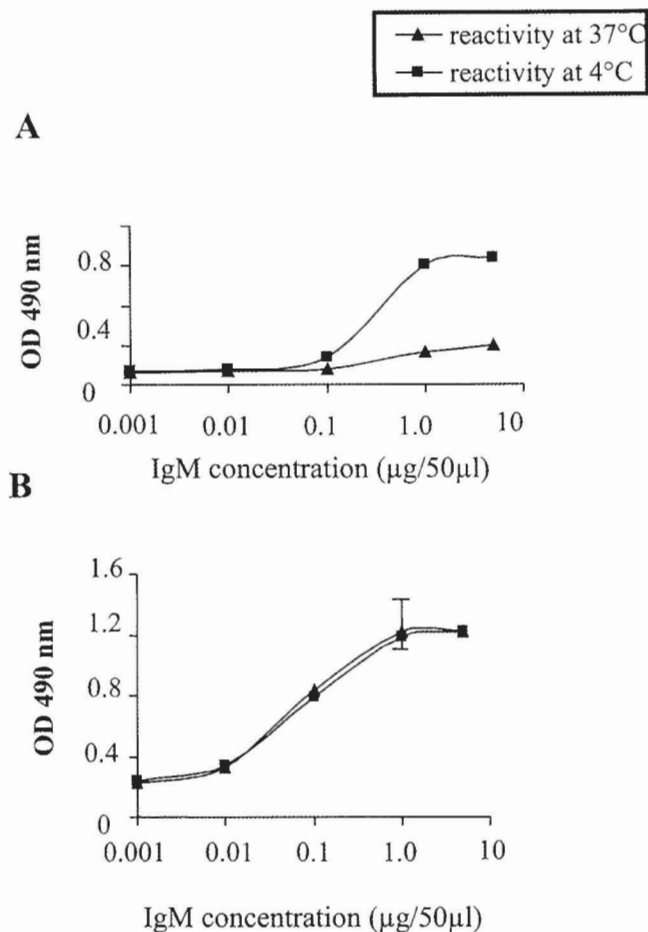
It has been detected only in small amounts of patients with rheumatoid arthritis or systemic lupus erythematoses (Abel et al., 1993). By using competitive inhibition assays Schott et al. (1998) demonstrated binding activity of cryoglobulin IgM to complete IgG, Fc fragments as well as against F(ab')<sub>2</sub> fragments. Maximum binding activity was observed to complete IgG. Furthermore, binding activity of cryoglobulin IgM to unspecific non-cryoglobulin-non-HCV IgG was demonstrated. In view of these data the authors postulated that more than one single linear epitope on IgG may be responsible for the binding of cryoglobulin IgM. At least one conformational epitope on a three-dimensional structure motif of IgG near the hinge region might serve as the antigen for the cryoglobulin IgM. Binding activity of monoclonal cryoglobulin IgM to complete IgG was significantly higher than that of polyclonal cryoglobulin IgM in this study. By analyzing cryoglobulin IgG reactivity against IgM no binding activity was described (Schott et al., 1998).

So cryoglobulin IgM, particularly monoclonal cryoglobulin IgM, acts as the antibody during formation of cryoglobulin immunocomplexes, while a conformational epitope on IgG serves as the antigen.

The binding activity of cryoglobulin IgM is induced by low temperature. Binding assays showed a higher binding activity of cryoglobulin IgM at low temperature (4 °C) compared to body temperature (37 °C). The enhancement of cryoglobulin IgM binding activity to IgG at 4 °C was higher for type III (polyclonal IgM) than for type II (monoclonal IgM). This indicates a more saturated IgG binding capacity of cryoglobulin IgM in type II MC at 37 °C and could be a possible explanation for the higher frequency of MC-associated symptoms in type II MC compared to type III MC. Interestingly binding activity of IgM with rheumatoid factor activity of control patients suffering from rheumatoid arthritis without MC was not induced by low temperature (Schott et al., 1998). Figure 6 shows temperature-dependent binding activity of cryoglobulin IgM and control-IgM.

#### Therapeutic options

Conventional treatment of mixed cryoglobulinemia aimed to reduce circulating immune complexes by immunosuppression with steroids, cytostatic drugs and plasmapheresis. Most times these efforts were only marginally effective and induction of long-term remission was not observed. With the emerging concept of a viral pathogenesis of mixed cryoglobulinemia the therapeutic approach has changed. Interferon treatment of MC was found to be effective in seven patients which were not responsive to immunosuppressive therapy even before association of MC and HCV had been described. With the discovery of the association of MC and HCV there was further rationale for the use of interferon- $\alpha$  with its antiviral effects. The efficacy of interferon- $\alpha$  treatment was evaluated in several studies (Casato et al., 1991; Ferri et al., 1993a,b; Misiani et al, 1994; Polzien et



**Fig. 6.** Reactivity of cryoglobulin IgM to non-cryoglobulinemic IgG at 4 °C and 37 °C analyzed by EIA. **Panel A** shows temperature dependent reactivity of one HCV-associated cryoglobulin IgM against IgG, while **Panel B** shows control sera of patients with rheumatoid factor activity without cryoglobulinemia and without HCV infection (n=8). Cryoglobulin IgM shows a high affinity at low temperature (4 °C) to IgG, while rheumatoid factor IgM affinity is not induced by low temperature.



al., 1997). Although heterogeneous treatment schedules were used and definition of response was not in common in these studies, the following conclusions can be drawn: (i) during interferon treatment the clinical, biochemical and virological parameters improve in a majority of patients; (ii) treatment is effective in controlling purpura (see Figure 2), but its benefit is small with regard to renal involvement; (iii) response to treatment is associated with the disappearance of HCV RNA in most cases, (iv) relapse is frequent after discontinuation of treatment subsequent to reappearance of HCV RNA; and (v) the presence of HCV genotype 2a, the absence of cirrhosis, low cryocrit and low viral load seem to be positive predictive factors to response of treatment. Patients with symptomatic MC are more often non-responders to interferon- $\alpha$  treatment (Misiani et al., 1994), while asymptomatic MC does not influence the outcome of interferon- $\alpha$  treatment according to HCV elimination (Polzien et al., 1997).

Data about the course of MC under combination therapy with ribavirin and interferon- $\alpha$  are scarce nowadays.

In severe cases of MC, immunosuppressive therapy and/or plasmapheresis in combination with antiviral treatment could be a valuable option.

#### **Hypothesis on the aetiology of HCV-associated mixed cryoglobulinemia**

Cryoprecipitation can be regarded as the result of the temperature-dependent association and dissociation of immunoglobulins. Low temperature may favor formation of cryoglobulin IgM/IgG complexes, as multivalent cryoglobulin IgM may have functional affinity at a low temperature (Schott et al., 1998). Physicochemical characterization of purified monoclonal cryoglobulins revealed no evidence of cryoprecipitation. Rather, the anomalous behavior in solution of monoclonal cryoimmunoglobulins was considered to be a direct result of the individual solubility properties of these proteins (Middaugh et al., 1978). Similar investigations of the hydrodynamic and spectroscopic properties of mixed cryoglobulins of HCV-infected patients have not been yet reported.

When reactions of cryoprecipitates and supernatants were compared, cryoglobulin IgM was not reactive to HCV-encoded proteins and precipitated predominantly non-specific IgG (Schott et al., 1998). Neither the presence of viral particles (proteins, HCV RNA), nor of HCV-specific IgG antibodies was necessary for cryoprecipitation in this study. The essential component for cryoprecipitation was the isolated cryoglobulin IgM with rheumatoid factor activity. Monoclonal and polyclonal cryoglobulin IgM (type II and type III MC) were able to precipitate non-specific IgG, while low temperature dependence was higher in type III MC (polyclonal IgM). An enrichment of anti-HCV IgG antibodies or HCV RNA in the cryoprecipitate compared to serum seems to be unlikely due to these data (Schott

et al., 1998). However, it has to be considered that an enrichment of HCV RNA and IgG antibodies against HCV-encoded antigens has been reported in type II MC (Agnello et al., 1992). How HCV could be concentrated in cryoprecipitates remains unclear, because the cryoglobulin IgM shows no reactivity to any available recombinant HCV-encoded protein (Agnello et al., 1992, Schott et al., 1998). Due to the data of Schott et al. (1998) a capturing of HCV-IgG complexes, which could lead to a concentration of HCV in cryoprecipitates, seems to be unlikely. Nevertheless, it should be kept in mind that an important pathogenetic role of HCV infection in MC, due to clinical data, including the response to successful anti-viral treatment with interferon- $\alpha$ , is out of doubt.

Since the participation of neither HCV viral particles nor anti-HCV-directed immunoglobulins appeared crucial for precipitate formation, an alternative explanation has to be sought. HCV-IgG complexes and HCV-lipoprotein complexes have been found in sera of HCV-infected patients (Thomssen et al., 1993). Such a complex might serve as a B-cell superantigen, inducing the synthesis of non-HCV-reactive IgM with rheumatoid-factor-like activity, and thus leading to formation of cryoprecipitates. Those immunocomplexes lead to an activation of the complement system and serve as a physiological component of the immune system in controlling infectious diseases (Chen et al., 1988).

Furthermore, infection of peripheral blood mononuclear cells (PBMC) by HCV has been reported (Müller et al., 1993) and a high level of HCV-infected PBMCs in MC patients has been observed (Ferri et al., 1993a,b). Additionally, monoclonal B-cell expansions, even of intrahepatic lymphocytes, and frank lymphoma have been observed in patients with MC and chronic HCV infection (Mazzaro et al., 1996; Sansonno et al., 1998). Furthermore, it is known that B-cells from type II MC patients strongly express the antiapoptotic bcl-2 oncogene product. Recently, Kitay-Cohen et al. (2000) and Zuckerman et al. (2001) reported that in patients suffering from chronic HCV infection and MC a high incidence of the t(14;18) translocation (MBR bcl-2-JH) and of IgH rearrangement (FR3/JH) was observed, compared to patients suffering from HCV infection without MC. So a non-antigenic HCV-caused stimulation of B-cells, which leads to an clonal proliferation of B-cells and production of cryoglobulin IgM could be responsible for the pathogenesis of HCV-associated MC.

#### **Conclusion**

Mixed cryoglobulinemia is a frequent phenomenon in chronic HCV infection. MC type III and type II could be observed in association with HCV infection. Occasionally, this may result in the syndrome of MC with purpura, arthralgias and weakness which could be complicated by severe organ involvement like peripheral

neuropathy and membranoproliferative glomerulonephritis. These manifestations are caused by immunocomplex-deposits in small vessels leading to complement activation. Liver involvement is dominated by the pathology of chronic HCV infection. However, cirrhosis is more often found in patients suffering from MC compared to patients without MC.

First-line treatment for HCV-associated MC is the antiviral therapy with interferon- $\alpha$ . Response of MC to treatment seems to be strikingly associated to the elimination of HCV RNA. Interferon- $\alpha$  treatment is effective in controlling skin disease, whereas the benefit in severe organ involvement is small. So immunosuppressive therapy and plasmapheresis in combination with interferon- $\alpha$  treatment could be necessary in some cases. HCV genotype 2a, the absence of cirrhosis, low viral load and low cryocrit are positive predictive factors of response.

The pathogenesis of HCV-associated MC remains unclear so far. The striking association of chronic HCV infection to the appearance of cryoprecipitates in sera is nowadays out of doubt. An antigenic stimulation by HCV-encoded proteins, which leads to the production of cryoglobulin IgM, seems to be unlikely. Probably a proliferation of B-cells with monoclonal expansion in MC type II, caused by viral infection of these cells, leads to the production of polyclonal and/or monoclonal cryoglobulin IgM with rheumatoid-factor activity. This multivalent IgM has high functional activity at low temperatures to at least two different epitopes on IgG and captures these IgGs. Formation of immunocomplexes with *in vitro* precipitation at low temperature follows.

## References

- Abel G., Zhang Q. and Agnello V. (1993). Hepatitis C Virus infection in type II mixed cryoglobulinaemia. *Arthritis Rheum.* 36, 1341-1349.
- Adinolfi L.E., Utilli R., Attanasio V., Zampino R., Ragone E., Tripodi M.-F. and Ruggiero G. (1996). Epidemiology, clinical spectrum and prognostic value of mixed cryoglobulinemia in hepatitis C virus patients: a prospective study. *Ital. J. Gastroenterol.* 28, 1-9.
- Agnello V. (1995). The aetiology of mixed cryoglobulinaemia associated with hepatitis C virus infection. *Scand. J. Immunol.* 42, 179-184.
- Agnello V., Chung R.T. and Kaplan L.M. (1992). A role for hepatitis C virus infection in type II cryoglobulinemia. *N. Engl. J. Med.* 327, 1490-1495.
- Bombardieri S., Ferri C., Di Munno O. and Pasero G. (1979). Liver involvement in essential mixed cryoglobulinemia. *Ric. Clin. Lab.* 9, 361-368.
- Brouet J.C., Clauvel J.P. and Danon F. (1974). Biological and clinical significance of cryoglobulins. *Am. J. Med.* 57, 775-788.
- Cacoub P., Lunel F., Musset L., Perrin M., Frangeul L., Leger J.M., Hureau J.M., Piette J.C. and Godeau P. (1994). Mixed cryoglobulinemia and hepatitis C virus. *Am. J. Med.* 96, 124-132.
- Cacoub P., Renou C., Rosenthal E., Cohen P., Lorry I., Loustad-Ratti V., Yamamoto A.M., Camproux A.C., Hausfater P., Musset L., Veyssier P., Raguin G. and Piette J.C. (2000). Extrahepatic manifestations associated with hepatitis C virus infection. A prospective multicenter study of 321 patients. The GERMIVIC. Groupe d'Etude et de Recherche en Medecine Interne et Maladies Infectieuses sur le Virus de l'Hepatitis C. *Medicine* 79, 47-56.
- Casato M., Lagana B., Antonielli G., Dianzani F. and Bonomo L. (1991). Long-term results of therapy with interferon-alpha for type II essential mixed cryoglobulinemia. *Blood* 78, 3142-3147.
- Chen P.P., Fong S., Goni F., Silverman G.J., Fox R.I. and Liu M.F. (1988). Cross-reacting idiotypes on cryoprecipitating rheumatoid factor. *Springer. Semin. Immunopathol.* 10, 35-55.
- Dammaco F. and Sansonno D. (1992). Antibodies to hepatitis C in essential mixed cryoglobulinemia. *Clin. Exp. Immunol.* 87, 352-356.
- Fayyazi A., Schott P., Hartmann H., Mihm S., Middel P., Ramadori G. and Radzun H.J. (1997). Clinical, biochemical, and histological changes in hepatitis C virus infection-associated cryoglobulinemia. *Z. Gastroenterol.* 35, 921-928.
- Ferri C., Greco F., Longombardo G., Palla P., Moretti A., Marzo E., Fosella P.V., Pasero G. and Bombardieri S. (1991). Antibodies against hepatitis C virus in mixed cryoglobulinemia patients. *Infection* 6, 417-420.
- Ferri C., Marzo W., Longombardo G., Lombardini F. and La Civita L. (1993a). Interferon- $\alpha$  in mixed cryoglobulinaemia patients: a randomized, crossover-controlled trial. *Blood* 81, 1132-1136.
- Ferri C., Monti M., La Civita L., Longombardo G., Greco F. and Pasero G. (1993b). Infection of peripheral blood mononuclear cells by hepatitis C virus in mixed cryoglobulinemia. *Blood* 82, 3701-3704.
- Ferri C., Caracciolo F., Zignego A.L., La Civita L., Monti M. and Longombardo G. (1994). Hepatitis C virus infection in patients with non-Hodgkin's lymphoma. *Br. J. Haematol.* 88, 392-394.
- Galli M., Careddu F., D'Armino A., Monti G., Messiani K. and Invernizzi F. (1980). Hepatitis B virus and essential mixed cryoglobulinemia. *Lancet* 1, 1093.
- Galli M., Monti G. and Monteverde A. (1992). Hepatitis C virus and mixed cryoglobulinemias. *Lancet* 339, 989.
- Gocke D.J., Hsu K., Morgan C., Bombardieri S., Lockstein M.D. and Christian C.L. (1979). Association between polyarthritis and Australia antigen. *Lancet* II, 1149.
- Gorevic P.D., Kassab H.J., Levo Y., Kohn R., Meltzer M., Prose P. and Franklin E.C. (1980). Mixed cryoglobulinemia: clinical aspects and long-term follow-up of 40 patients. *Am. J. Med.* 69, 287-308.
- Gross W.L. (1994). New developments in the treatment of systemic vasculitis. *Curr. Opin. Rheumatol.* 9, 11-19.
- Gumber S.C. and Chopra S. (1995). Hepatitis C: A multifaceted disease. Review of extrahepatic manifestations. *Ann. Intern. Med.* 123, 615-620.
- Hartmann H., Schott P., Polzien F., Mihm S., Uy A., Kaboth U., Pardowitz I. and Ramadori G. (1995). Cryoglobulinemia in chronic hepatitis C virus infection: prevalence, clinical manifestations, response to interferon treatment and analysis of cryoprecipitates. *Z. Gastroenterol.* 33, 643-650.
- Heidelberger M. and Kendall F. (1929). A quantitative study of the precipitin reaction between type III pneumococcus polysaccharide and purified homologous antibody. *J. Exp. Med.* 50, 809-823.
- Invernizzi F., Pioltelli P., Cattaneo R., Gavazzeni V., Borzini P., Monti G. and Zanussi C. (1979). A long-term follow-up study in essential cryoglobulinemia. *Acta Haematol.* 61, 93-99.
- Jori G.P. and Buananno G. (1972). Chronic hepatitis and cirrhosis of the liver in cryoglobulinemia. *Gut* 13, 610-614.
- Kitay-Cohen Y., Amiel A., Hilzenrat N., Buskila D., Ashur Y., Fejgin M., Gaber E., Safadi R., Tur-Kaspa R. and Lishner M. (2000). Bcl-2

## HCV-associated mixed cryoglobulinemia

- rearrangement in patients with chronic hepatitis C associated with essential mixed cryoglobulinemia type II. *Blood* 96, 2910-2912.
- Lampecht P., Moosig F., Gause A., Herlyn K., Csernok E., Hansen H. and Gross W.L. (2001). Immunological and clinical follow up of hepatitis C virus associated cryoglobulinaemic vasculitis. *Ann. Rheum. Dis.* 60, 385-390.
- Lerner A.B. and Watson C.J. (1947). Studies of cryoglobulins. Unusual purpura associated with the presence of a high concentration of cryoglobulin (cold precipitable serum globulin). *Am. J. Med. Sci.* 214, 410.
- Levo Y., Gorevic P.D., Hanna M.D., Kassab J., Tobias H. and Franklin E.C. (1977). Liver involvement in the syndrome of mixed cryoglobulinemia. *Ann. Intern. Med.* 87, 287-292.
- Lunel F., Musset L., Cacoub P., Franguel L., Cresta P., Perrin M., Grippon P., Hoang C., Piette J.C., Hureau J.M. and Opolon P. (1994). Cryoglobulinemia in chronic liver disease: role of hepatitis C virus and liver damage. *Gastroenterology* 106, 1291-1300.
- Mazzaro C., Franzin F., Tulissi P., Bussini E., Crovatto M. and Carniello G.S. (1996). Regression of monoclonal B-cell expansion in patients affected by mixed cryoglobulinemia responsive to  $\alpha$ -interferon therapy. *Cancer* 77, 2604-2613.
- Meltzer M. and Franklin E.C. (1966). Cryoglobulinaemia. A study of twenty-nine patients. *Am. J. Med.* 40, 828-835.
- Middaugh C.R., Kehoe J.M., Prystowsky M.B., Gerber-Jenson B. and Jnson C. (1978). Molecular basis for the temperature-dependent insolubility of cryoglobulins. IV. Structural studies of the IgM monoclonal cryoglobulin McE. *Immunochemistry* 15, 171-187.
- Misiani R., Bellavita P., Fenili D., Borelli G., Marchesi D., Massazza M., Vendramin G., Comotti B., Tanzi E., Scudeller G. and Zanetti A. (1992). Hepatitis C virus infection in patients with essential mixed cryoglobulinemia. *Ann. Intern. Med.* 117, 573-577.
- Misiani R., Bellavita P., Fenili D., Vicari O., Marchesi D. and Sironi P.L. (1994). Interferon-alpha 2a therapy in cryoglobulinaemia associated with hepatitis C virus. *N. Engl. J. Med.* 330, 751-756.
- Montagnino G. (1988). Reappraisal of the clinical expression of mixed cryoglobulinemia. *Springer Semin. Immunopathol.* 10, 1-19.
- Monti G., Galli M., Invernizzi F., Pioletti P., Saccardo F., Monteverde A., Pietrogande M., Renoldi P., Bombardieri S., Bordin G., Candela M., Ferri C., Gabrielli A., Mazzaro C., Migliaresi S., Musini C., Ossi E., Quintiliani L., Tirri G. and Vacca A. (1995). Cryoglobulinemias: a multi-centre study of the early clinical and laboratory manifestations of primary and secondary disease. *Q. J. Med.* 88, 115-126.
- Müller H.M., Pfaff E., Goeser T., Kallinowski B., Solbach C. and Theilmann L. (1993). Peripheral blood mononuclear leukocytes serve as a possible extrahepatic site for hepatitis C virus replication. *J. Gen. Virol* 74, 669-676.
- Pascual M., Perrin L., Giostra E. and Schifferli J.A. (1990). Hepatitis C virus in patients with cryoglobulinemia type II. *J. Infect. Dis.* 162, 569-570.
- Pechere-Bertschi A., Perrin L., de Saussure P., Widmann J.J., Giostra E. and Schifferli J.A. (1992). Hepatitis C: a possible etiology for cryoglobulinemia type II. *Clin. Exp. Immunol.* 89, 419-422.
- Pingel S., Hartmann H. and Ramadori G. (1994). Essential mixed cryoglobulinemia (EMC) in a case of chronic hepatitis C – successful treatment with interferon alpha. *Z. Gastroenterol.* 32, 584-588.
- Polzien F., Schott P., Mihm S., Ramadori G. and Hartmann H. (1997). Interferon- $\alpha$  treatment of hepatitis C virus-associated mixed cryoglobulinemia. *J. Hepatol.* 27, 63-71.
- Popp J.W., Dienstag J.L., Wands J.R. and Bloch U.J. (1980). Essential mixed cryoglobulinemia without evidence for hepatitis B virus infection. *Ann. Intern. Med.* 92, 379-383.
- Sansonno D., De Vita S., Iacobelli A.R., Cornacchiulo V., Boiocchi M. and Dammaco F. (1998). Clonal analysis of intrahepatic C cells from HCV-infected patients with and without mixed cryoglobulinemia. *J. Immunol.* 160, 3594-3601.
- Schhubothe H. and Westerhausen M. (1970). Nachweismethoden und Vorkommen von Kryoglobulinen. *Dtsch. Med. Wschr.* 35, 1786-1788.
- Schott P., Polzien F., Müller-Issberner A., Ramadori G. and Hartmann H. (1998). In vitro reactivity of cryoglobulin IgM and IgG in hepatitis C virus-associated mixed cryoglobulinemia. *J. Hepatol.* 28, 17-26.
- Tarantino A., De Vecchi A., Montagnino G., Imbasciati E., Mihatsch M.G., Zollinger H.U., Barbiano di Belgiojoso G., Busnach G. and Ponticelli C. (1981). Renal disease in essential mixed cryoglobulinemia. Long-term follow-up of 44 patients. *Q. J. Med.* 50, 1-7.
- Thomssen R., Bonk S. and Thiele A. (1993). Density heterogeneities of hepatitis C virus in human sera due to the binding of  $\beta$ -lipoproteins and immunoglobulins. *Med. Microbiol. Immunol.* 182, 329-334.
- Tissot J.D., Schneider P. and Hohlfeld P. (1993). Two-dimensional electrophoresis as an aid in the analysis of the clonality of immunoglobulins. *Electrophoresis* 14, 1366-1371.
- Weinberger A., Berliner S., Russo I., Pinkhas J. and Pick I.A. (1985). X-ray findings of peripheral joints in essential mixed cryoglobulinemia. *Isr. J. Med. Sci.* 21, 529-534.
- Weiner S.M., Berg T., Berthold H., Weber S., Peters T., Blum H.E., Hopf U. and Peter H.H. (1998). A clinical and virological study of hepatitis C virus-related cryoglobulinemia in Germany. *J. Hepatol.* 29, 375-384.
- Wintrobe M.M. and Buell M.V. (1933). Hyperproteinemia associated with multiple myeloma. *Bull. Johns Hopkins Hosp.* 52, 133.
- Zuckerman R., Zuckerman T., Sahar D., Streichmann S., Altias D., Szabo E., Yeshurun D. and Rowe J. (2001). Bcl-2 and immunoglobulin gene rearrangement in patients with hepatitis C virus infection. *Br. J. Haematol.* 112, 364-369.

Accepted July 16, 2001