

Chronic inhibition of NO synthesis produces myocardial fibrosis and arterial media hyperplasia

P. Babál^{1,3}, O. Pechánová², I. Bernátová² and S. Štvrtina³

¹Department of Pathology, University of South Alabama, Mobile AL, USA, ²Institute of Normal and Pathological Physiology, Slovak Academy of Sciences and ³Department of Pathology, Comenius University, Bratislava, Slovakia

Summary. Pathophysiological effects of nitric oxide (NO)-deficient hypertension are much better known than are the potential morphological changes. Hearts and main arteries were studied in 15 week old male Wistar rats administered N^G-nitro-L-arginine methyl ester (L-NAME) for 4 weeks. A dose of 40 mg/kg/day increased systolic arterial pressure by 30%, while heart rate decreased by 20%. Heart/body weight ratios were not significantly changed. Total cardiac RNA and DNA content and [¹⁴C]leucine incorporation into myocardial protein were, however, increased by 15%, 228% and 97%, respectively. Light microscopy of hearts showed subendocardial areas of necrosis along with different stages of healing. Morphometric evaluation demonstrated significant increase in myocardial fibrosis. Serum lactate dehydrogenase increased by 91%. Proliferation cell nuclear antigen (PCNA) immunohistochemistry indicated positive cells in areas of postischemic repair. Chronic inhibition of NO synthase (NOS) resulted in periarterial fibrosis and hyperplasia of the media in coronary arteries and aorta. RNA and DNA content, and [¹⁴C]leucine incorporation into protein of aorta increased by 255%, 95% and 49%, respectively. PCNA staining showed numerous positive nuclei in the media of coronary arteries and the aorta. It is concluded that inhibition of NOS leads to systemic hypertension with focal myocardial fibrosis reflecting reparative responses associated to ischemic injury. This sequence of alterations involves impaired arterial relaxation, and uncontrolled vascular medial proliferation attributed to the absence of smooth muscle cell proliferation inhibition by NO.

Key words: Nitric oxide (NO), L-NAME, Myocardial fibrosis, Ischemia, Arterial hyperplasia, Proliferation cell nuclear antigen (PCNA), Smooth muscle cells

Introduction

Vascular endothelial cells synthesize and release nitric oxide (NO) which plays an important role in the regulation of vascular tone (Arnal et al., 1993), platelet aggregation, leukocyte adhesion (Fukuda et al., 1995; Kanvar and Kubes, 1995) and vascular smooth muscle cell proliferation (Kolpakov et al., 1995). Nitric oxide synthase (NOS) activity can be inhibited by L-arginine analogues such as N^G-nitro-L-arginine methyl ester (L-NAME) or N^G-monomethyl-L-arginine (L-NMMA) (Palmer et al., 1988; Johns et al., 1990; Gardiner et al., 1990).

Much attention has been devoted to the acute physiological effects of NO. Less information is available on morphological changes in the cardiovascular system related to long-term NOS blockade. Myocardial hypertrophy as a result of systemic NO-deficient hypertension is well documented (Shudo et al., 1992; Kristek et al., 1995; Numaguchi et al., 1995). Recently, myocardial fibrosis (Numaguchi et al., 1995; Pechánová et al., 1995) and coronary vascular remodeling have been described (Kristek et al., 1995; Numaguchi et al., 1995). The aim of this work was to examine the morphological changes of rat myocardium, coronary arteries and aorta resulting from the chronic inhibition of NOS by L-NAME. Morphological correlates for biochemical parameters of increased RNA and DNA content and protein synthesis in myocardium and aorta in L-NAME-treated animals (Bernátová et al., 1995) are provided.

Materials and methods

Animal model of chronic NOS inhibition

Male, 15 week old Wistar rats were divided into 2 groups (n=8). One group served as control and the second group was given L-NAME (Sigma Chemie GmbH, Germany) in a daily dose of 40 mg/kg in drinking water. Systolic heart pressure and heart rate were measured daily by tail cuff pletysmography. After 4

Offprint requests to: Dr. Pavel Babál, M.D., Department of Pathology, University of South Alabama, 2451 Fillingim Street, Mobile, AL 36617, USA

Cardiovascular changes in NO deficiency

weeks the animals were sacrificed by decapitation.

Determination of nucleic acids content

Total myocardial RNA content was assessed by single-step isolation with guanidinium thiocyanate-phenol-chloroform extraction (Chomczynski and Sacchi, 1987). The DNA content was analyzed by the method of Sambrook et al. (1989).

Protein synthesis determination by [¹⁴C]leucine incorporation

The procedure described in detail elsewhere (Gerová et al., 1996) was used for [¹⁴C]leucine incorporation into 0.2-0.3 mm thick slices of myocardium and aorta. After a 10 minute incubation in oxygenated Krebs-Ringer solution at 37°C, samples were placed for 30 minutes in medium containing 0.25 mM [¹⁴C]leucine with 320 kBq/mM specific activity (Institute for Research, Production and Application of Radioisotopes, Prague, Czech Republic). The specimens were homogenized in ice cold 1M perchloric acid for denaturation of proteins and extraction of unincorporated leucine. After two repeated precipitations, the sediment was dissolved in 1M NaOH and the solution was assayed for protein content and for [¹⁴C]leucine incorporation by liquid scintillation counting.

Lactate dehydrogenase assay

Commercially available Diagnostic kit for lactate dehydrogenase (Sigma) was used to determine LDH activity in rat sera at the end of the experiment.

Histology

Hearts were cut perpendicularly to the long axis in midway between the apex and sulcus coronarius. The apical half of the heart, a 3 mm long segments of ascending and of descending aorta were dissected from the experimental animals. The samples of aorta were put in an upright position on cellulosic filter membranes (Micron Separations, Inc., Westboro, MA) to maintain round shape. The tissues were fixed for 24 hours in 10% phosphate buffered formalin, then routinely processed in paraffin and serial 5 µm thick sections were stained with hematoxylin and eosin, phosphotungstic acid hematoxylin and by Van Gieson's staining.

Immunohistochemistry

Deparaffinized slides were treated 10 minutes in methanol containing 0.5% H₂O₂ and incubated in antigen-retrieving solution (Innovex Biosciences, Richmond, CA) in boiling water bath for 10 minutes. Primary antibodies against PCNA and smooth muscle alpha actin (DAKO Corp., Carpinteria, CA) were applied diluted 1:200 in phosphate buffered saline pH 7.3 (PBS)

for 60 minutes. The immune reaction was performed with DAKO LSAB 2 Peroxidase Kit: 20 minute incubation with biotinylated anti-mouse IgG antibodies followed by 10 minute incubation with avidin-horseradish peroxidase complex. The peroxidase reaction was developed with Diaminobenzidine Chromogen Kit (Biomedica Corp., Foster City, CA). All washes were done in PBS for 10 minutes, incubations at room temperature. Slides were counterstained with hematoxylin or 1% methyl green water solution. For better resolution PCNA immunoreaction was developed in diaminobenzidine with 0.5% CoCl₂. In each slide of aorta a segment with 250 nuclei was counted. The frequency of PCNA positivity was expressed as percentage of the number of all counted nuclei in the aorta segment.

Morphometry

Morphometric evaluation was performed on Reichert light microscope equipped with two dimensional image analyzer Telemet II (Tesla, Piestany, Slovakia). Van Gieson's staining was applied to enhance the red color contrast of collagen. Myocardial fibrosis was expressed as ratio of fibrosis/muscle areas on the heart slice. The wall thickness and the inner diameter of aorta were measured on the descending segment at the magnification scale 1:40.

Data were expressed as mean±SEM. For analysis ANOVA-Bonferroni test was used. Values were considered statistically significant at p<0.05.

Results

Blood pressure and heart rate

Systolic blood pressure and heart rate were monitored daily. Oral administration of L-NAME in the dose 40 mg/kg/day increased systolic blood pressure by 34, 30, 30 and 26%; heart rate decreased by 25, 23, 19 and 20% after the first, second, third and fourth week, as compared with control group (p<0.05).

Heart weight, nucleic acids content and protein synthesis

The heart/body weight ratio showed a rising trend in the experimental group (Table 1). No change was observed in body weight of L-NAME treated rats compared to the control group. Although the heart/body weight ratio was not significantly elevated in the treated animals, total RNA content increased by 15%, DNA content increased by 228%, and [¹⁴C]leucine incorporation increased by 97%. In aorta, RNA and DNA content, and [¹⁴C]leucine incorporation increased by 255%, 93% and 49%, respectively (Table 1).

Lactate dehydrogenase activity

Activity of LDH in serum of L-NAME treated rats

was increased after 4 weeks by 91% as compared with the control group (Table 1).

Histology with morphometric analysis and histochemistry

Hematoxylin and eosin sections revealed large areas of fibrosis in the myocardium of rats treated with L-NAME. These changes were accentuated with Van Gieson's staining of collagen (Fig. 1). Maximum changes were subendocardial in the left ventricle, in the

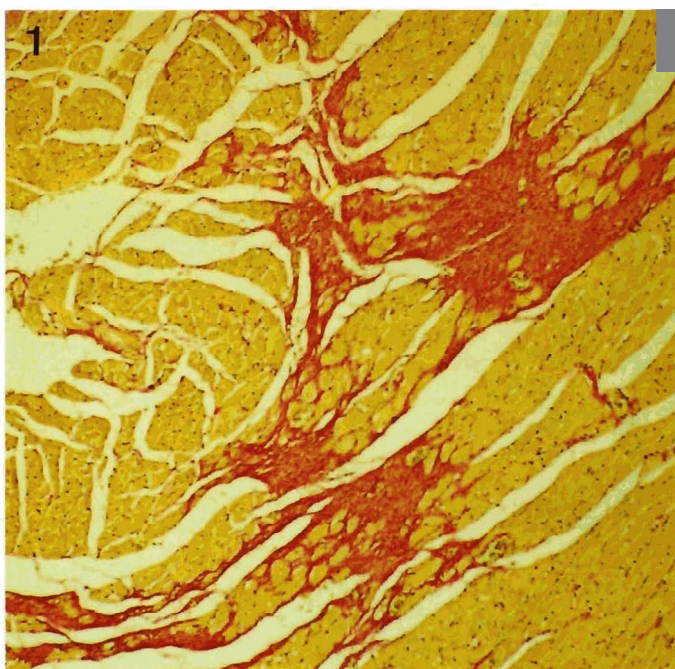


Fig. 1. Left ventricle of the rat treated with L-NAME for 4 weeks with large areas of focal fibrosis prevalently in the subendocardial region. Van Gieson. x 100

Table 1. Morphological and biochemical changes of myocardium and aorta.

	CONTROL	L-NAME
<i>Myocardium</i>		
Heart/body weight ratio	2.64±0.04	2.98±0.21
Fibrosis/muscle ratio	0.055±0.038	1.491±0.148*
LDH (microcatal/L)	16.2±1.92	30.9±1.52*
RNA (mg/g protein)	3.3±0.2	3.8±0.08*
DNA (mg/g protein)	0.7±0.1	2.3±0.3*
[¹⁴ C]leucine incorp. (DPM/g protein)	102.8±18.4	202.3±21.1*
<i>Aorta</i>		
Inner diameter (mm)	1.49±0.15	2.02±0.15*
Wall thickness (mm)	0.13±0.02	0.24±0.03*
Diameter/wall ratio	9.36±1.28	11.99±1.34
PCNA-positive nuclei (%)	~	6.3±2.24
RNA (mg/g protein)	2.71±0.35	9.61±0.84*
DNA (mg/g protein)	1.66±0.2	3.2±0.31*
[¹⁴ C]leucine incorp. (DPM/g protein)	432.0±42.2	645.8±71.3*

*: p<0.05.

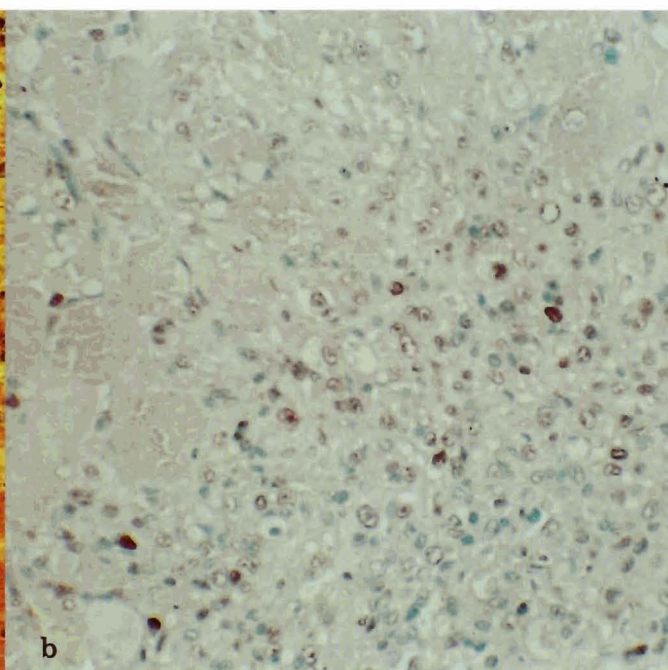
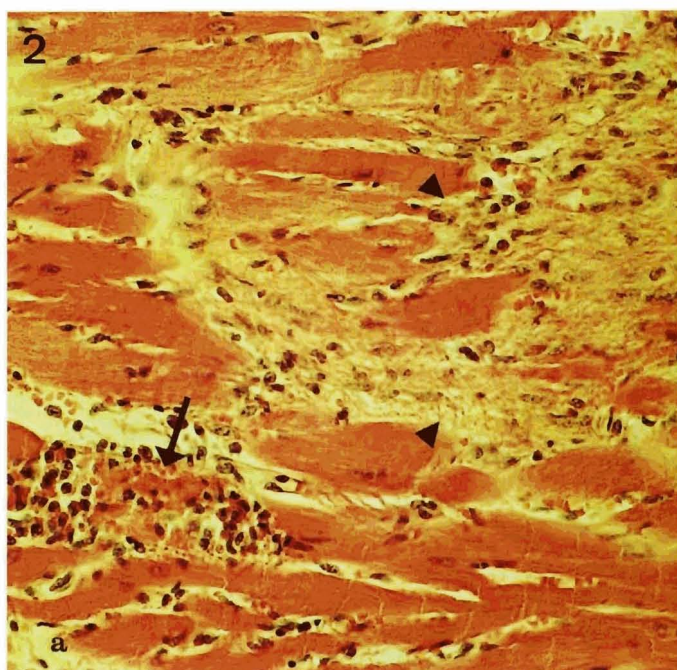


Fig. 2. Recent myocardial necrosis with inflammatory cell accumulation (arrow) next to the postischemic lesion healed by fibrous scar (arrowhead) a. PCNA immunohistochemistry uncovering numerous positive nuclei of cells in the granulation tissue replacing necrotic myocardium b. Avidin-biotin-peroxidase complex (ABC-Px), counterstained with methyl green. x 400

Cardiovascular changes in NO deficiency

papillary muscles, and in the interventricular septum. Similar changes were occasionally seen in the right ventricle. Fibrous tissue/muscle ratio was $0.055 \pm 0.038\%$ in the control group and increased to $1.491 \pm 0.148\%$ in the experimental group, thus demonstrating myocardial healing after 4 week L-NAME administration. Areas of acute necrosis with inflammatory cell accumulation next to foci of fibrosis (Fig. 2a) documented the dynamics of ischemic changes development in the myocardium.

PCNA immunohistochemistry in these areas depicted accumulation of positive nuclei in fibroblasts and endothelial cells (Fig. 2b). Only vascular walls stained with α -actin antibodies.

Remarkable thickening of the perivascular fibrous tissue was evident with Van Gieson's technique. Proliferation of the media in arteries of all sizes was recognized by increased blue cytoplasmic staining of smooth muscle cells exposed to phosphotungstic acid

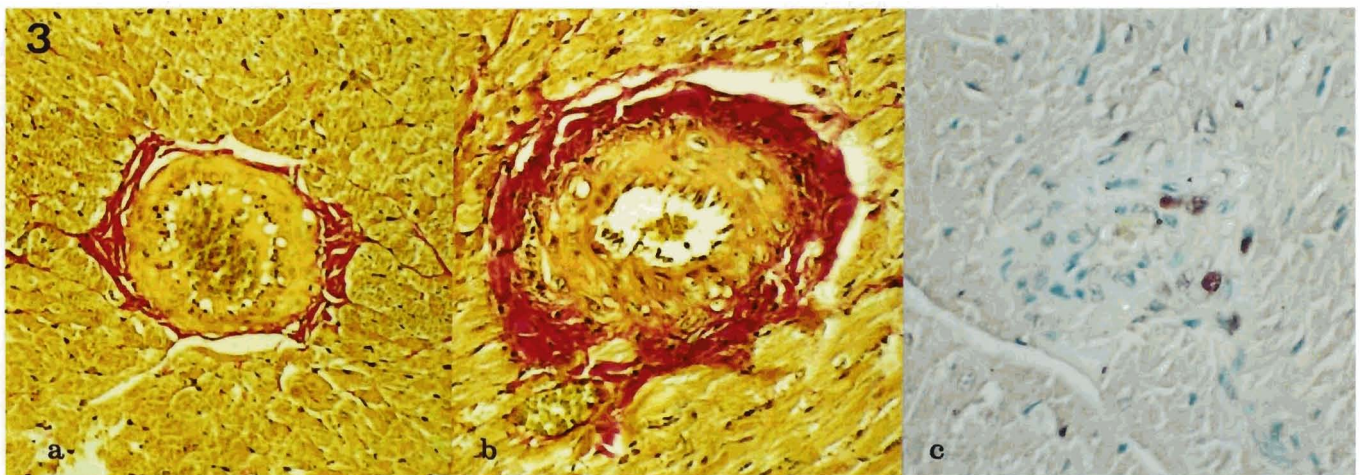


Fig. 3. Medium-sized artery in the interventricular septum. a. Heart of control animal. Van Gieson. b. Striking perivascular fibrosis stained pink with Van Gieson's method, and enlargement of the media with narrowed lumen. c. The presence of PCNA-positive nuclei (dark) document proliferative activity of vascular smooth muscle cells at NO deficiency. ABC-Px, counterstained with methyl green. x 400

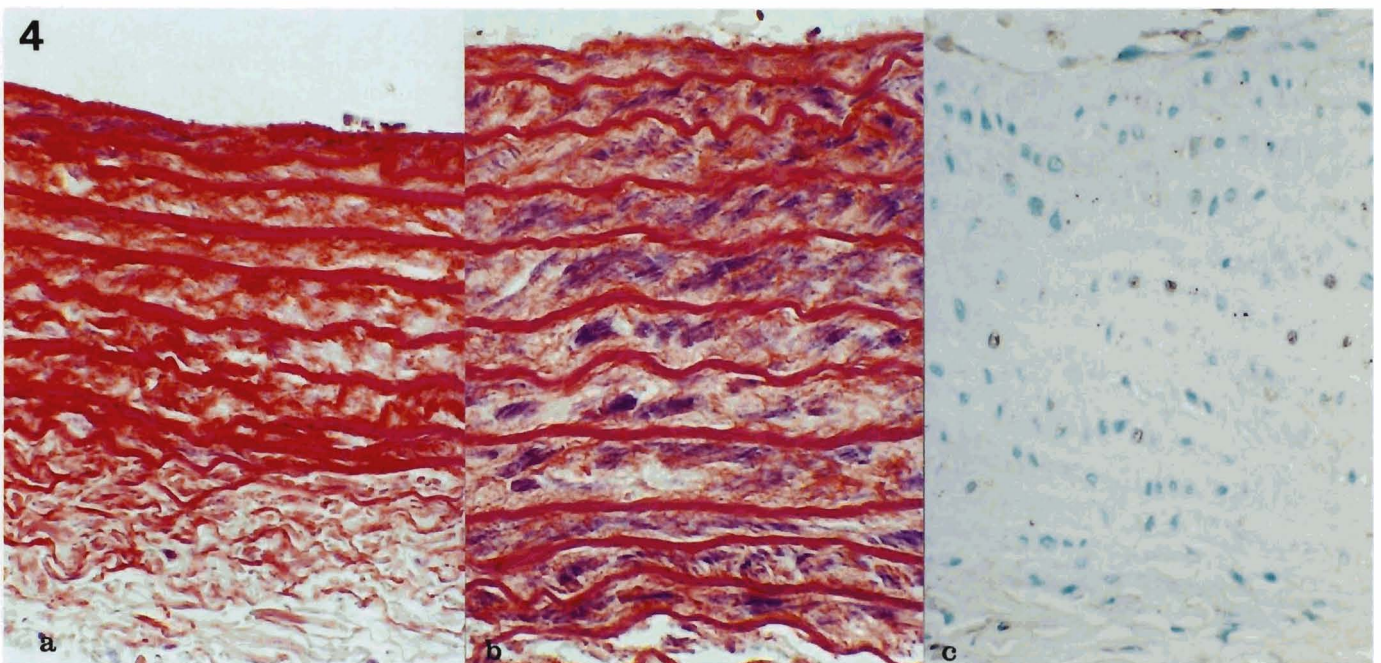


Fig. 4. Rat aorta of the control group (a), and of an animal after 4 week L-NAME treatment with doubled thickness of the wall and blue staining of smooth muscle cells cytoplasm (b). Numerous PCNA-positive nuclei of smooth muscle cells proving high proliferation activity of cells in the wall of aorta (c). a,b: phosphotungstic acid hematoxylin; c: PCNA, ABC-Px, counterstained with methyl green. x 400

hematoxylin. The thickened walls (approximately doubled) narrowed the lumen to one half of that in hearts from control animals (Fig. 3a,b). The cells of thickened arterial walls in L-NAME treated animals showed cytoplasmic positivity of α -actin (not shown), and numerous PCNA-positive nuclei (Fig. 3c).

The inner diameter of control rat aortas was considerably smaller than that in L-NAME treated animals (Table 1). The thickness of the wall of control aortas was less compared to wall size in chronically NO-deficient rats (Fig. 4). The aorta diameter/wall ratio in the NO-deficient experimental animals did not differ significantly from the values in controls (Table 1). Cells in the enlarged aortic wall displayed strong cytoplasmic α -actin positivity and blue staining with phosphotungstic acid hematoxylin, confirming their smooth muscle origin (Fig. 4a,b). PCNA histochemistry (Fig. 4c) documented the high proliferation rate of smooth muscle cells in the aortic media (Table 1).

None of the described histological abnormalities were observed in rats of the control group. In hearts of both, control and the treated animals, there were scattered PCNA-positive nuclei of capillary endothelial cells and occasionally (0-2 per section) in cardiomyocytes. There were no noticeable changes in the valves.

Discussion

The increase of blood pressure along with decreased heart rate in animals chronically administered with L-NAME have been described in numerous studies (Gardiner et al., 1990; Ribeiro et al., 1992; Shudo et al., 1992) and serve as reliable indicators of NO synthesis inhibition. The increase in heart/body weight ratio in our experimental animals was not statistically significant after four weeks of L-NAME treatment. Similar results were published by Arnal et al. (1993). A six- (Delacretaz et al., 1994) and eight-week long treatment (Kristek et al., 1995; Numaguchi et al., 1995; Moreno et al., 1996) resulted in significant heart weight changes, thus the period of NO-synthase inhibition may play a critical role in the development of myocardial hypertrophy. As shown in rats with L-NAME and hydralasine co-treatment (Numaguchi et al., 1995), it is not hypertension per se but the inhibition of NOS that is critical for myocardial hypertrophy (Matsuoka et al., 1996).

In order to analyze the alterations in macromolecular synthesis in myocardium of L-NAME treated rats, total RNA and DNA content and [14 C]leucine incorporation into proteins were determined. Four-week L-NAME administration resulted in significant elevation of all these parameters. NO inhibits proliferation of vascular smooth muscle cells (VSMC) in part by a cGMP-dependent mechanism (Garg and Hassid, 1989; Scott-Burden et al., 1992), although other factors may also be involved (Gupta et al., 1994). It has been generally accepted that generation of NO also inhibits protein synthesis in VSMC. Data concerning myocardium and myocytes are ambiguous with some

showing a decrease of myocardium proteosynthesis by NO donors or NO synthesis stimulation (McDonald et al., 1992; Harding et al., 1995), other by NOS inhibition (Arnal et al., 1993). We assume that the remarkable increase in nucleic acids content and protein synthesis in the myocardium of L-NAME treated rats in part might be the result of stimulated myocyte hypertrophy reflecting decreased cGMP (Matsuoka et al., 1996). Although proliferation of adult ventricular myocytes can result from ischemic injury (Anversa et al., 1995), PCNA immunohistochemical negativity in myocytes did not confirm such activity. Thus, the increased bio-chemical parameters could be related to fibroblast and endothelial cell proliferation in areas of postischemic reparative processes. The overall high proliferative activity of SMC in thickened vascular walls also might contribute significantly to the elevated biochemical indicators in the heart tissue.

Light microscopy and morphometric evaluation documented the significant fibrosis in the myocardium of rats treated with L-NAME. Van Gieson's stain highlights mature fibrous tissue; areas with acute necrosis and proliferating granulation tissue were not recognized by the morphometric system, thus the actual size of myocardial ischemic damage would be much greater. The pattern of fibrotic changes in the heart was segmental corresponding to healed myocardial infarction (Anversa et al., 1995). The focal character of these lesions most likely resulted from L-NAME impaired vascular relaxation leading to local myocardial ischemia (Avontuur and Ince, 1995), potentiated by the development of systemic hypertension requiring higher cardiac load. NOS inhibition also may increase mitochondrial respiration (Cobb et al., 1992; Hoshida et al., 1995; Shen et al., 1995) but it has not been shown how this affects the myocardium. Our results are in agreement with findings of increased post-ischemic reperfusion injuries in isolated rat hearts treated with L-NAME in which during ischemia the cytosolic enzymes lactate dehydrogenase and creatine kinase were increased in the venous effluent (Hropot et al., 1994). In the later phase of the L-NAME treatment experiment, when vascular wall proliferation took place, the narrowing of lumen could contribute to further ischemia of the heart muscle. Large infarct-like areas of necrosis with connective tissue deposition in the healing phase were described in connection with fibromuscular intimal proliferation triggered by some pharmacological substances (Van Vleet et al., 1991). NO limits endothelial activation, including expression of adhesion molecules (De Caterina et al., 1995; Fukuda et al., 1995; Kanvar and Kubes, 1995). NO deficiency may thus result in increased monocyte and platelet adhesion, and accompanying release of growth factors which would contribute to the thickening of the vascular wall. The proliferation was limited to the media, which is in agreement with the findings of others (Kristek et al., 1995; Numaguchi et al., 1995; Sventek et al., 1996).

Since cardiac fibrosis is quite frequent in rats over 1

year old (Fairweather, 1967; Van Vleet et al., 1991), young animals were used in the experiment. The lesions characterized by necrosis, inflammatory changes, reparative fibrosis and increased serum lactate dehydrogenase were found only in rats administered with L-NAME. As we and others described previously (Numaguchi et al., 1995; Pechánová et al., 1995; Moreno et al., 1996), maximum pathologic changes were observed in the subendocardial zone, papillary muscles and in the interventricular septum. These lesions were similar to those resulting from ischemia produced by coronary vascular disease in old rats (Greaves and Faccini, 1984). Subendocardial zone of the left ventricle predisposes for ischemic injury due to capillary pressure decreases through the thick wall of the left ventricle and is the lowest in the subendocardial zone (Balasz, 1981). The distribution of fibrosis was focal which corresponded to postnecrotic reparative replacement process (Anversa et al., 1995). Diffuse cardiac fibrosis described in ventricular hypertrophy (Frohlich, 1989) in other experimental hypertension models in rats (Philips et al., 1994; Robert et al., 1995) imply activation of cardiac myocytes, not found in our animals with NO deficient hypertension.

The capacity of NO to inhibit VSMC proliferation has been extensively documented in vitro and in vivo (Garg and Hassid, 1989; McNamara et al., 1993; Kolpakov et al., 1995). The finding of $6.3 \pm 2.24\%$ PCNA-positive nuclei in the wall of aorta and their presence in the coronary arteries is likely related to the lack of the antiproliferative action of NO on SMC, which results in vascular wall remodeling. These proliferative changes were similar to those described by others (Kristek et al., 1995; Numaguchi et al., 1995) and were accompanied by significant increase of nucleic acids content and protein synthesis detected in aortic wall. Doubling of the wall thickness and lumen widening in aortas of our experimental animals were analogous to findings in the carotid artery (Kristek et al., 1995), however, as it was also described in the coronary arteries (Numaguchi et al., 1995) we did not observe significant changes in the wall/diameter ratio. The contrasting finding of only slight proliferation of aortic smooth muscle cells by Shudo et al. (1992) or absence of accentuation of cardiac arteries medial hypertrophy in spontaneously hypertensive rats (Sventek et al., 1996) might be explained by the short, two respectively three, week duration of L-NAME administration.

We conclude that the inhibition of NO-synthase leads to hypertension and cardiac ischemia with necrosis accompanied by increased serum LDH activity followed by reparative processes resulting in focal myocardial fibrosis. These alterations may represent consequences of impaired arterial relaxation and arterial media thickening due to decreased availability of NO. The latter is supported also by the finding of numerous PCNA-positive SMC nuclei documenting uncontrolled vascular wall cell proliferation after L-NAME administration.

Acknowledgements. Supported by PECO grant No BMH1-CT-92-1893; Slovak Grant Agency for Science No 2/1147/95; South Alabama Medical Sciences Foundation.

References

- Anversa P., Kajstura J., Reiss K., Quaini F., Baldini A., Olivetti G. and Sonnenblick E.H. (1995). Ischemic cardiomyopathy: Myocyte cell loss, myocyte cellular hypertrophy, and myocyte cellular hyperplasia. *Ann. NY Acad. Sci.* 752,47-64.
- Arnal J.F., El Amrani A.I., Chatellier G., Menard J. and Michel J.B. (1993). Cardiac weight in hypertension induced by nitric oxide synthase blockade. *Hypertension* 22, 380-387.
- Avontuur J.A.M. and Ince B.C. (1995). Inhibition of nitric oxide synthesis causes myocardial ischemia in endotoxemic rats. *Circ. Res.* 76, 418-425.
- Balazs T. (1981). Cardiotoxicity of adrenergic bronchodilator and vasodilating antihypertensive drugs. In: *Cardiac toxicology*. Vol. 2. Balazs T. (ed). CRC Press. Boca Raton, FL. pp 61-73.
- Bernátová I., Pechánová O. and Babál P. (1995). Nitric oxide synthase inhibition enhances proteosynthesis in rat tissues. *Endothelium* 3(Suppl.), 38.
- Chomczynski P. and Sacchi N. (1987). Single-step method of RNA isolation by Acid guanidium thiocyanate-phenol-chloroform extraction. *Anal. Biochem.* 162, 156-159.
- Cobb J.P., Natanson C., Hoffman W.D., Lodato R.F., Banks S., Koev C.A., Solomon M.A., Elin R.J., Hosseini J.M. and Danner R.L. (1992). N-amino-L-arginine, an inhibitor of nitric oxide synthase, raises vascular resistance but increases mortality rates in awake canines challenged with endotoxin. *J. Exp. Med.* 176, 1175-1182.
- De Caterina R., Libby P., Peng H., Thannickal V.J., Rajavashisth T.B., Gimbrone Jr. M.A., Shin W.S. and Liao J.K. (1995). Nitric oxide decreases cytokine induced endothelial activation. *J. Clin. Invest.* 96, 60-68.
- Delacretaz E., Hayoz D., Osterheld M.C., Genton C.Y., Brunner H.R. and Waeber B. (1994). Long-term nitric oxide synthase inhibition and distensibility of carotid artery in intact rats. *Hypertension* 23 (part 2), 967-970.
- Fairweather F.A. (1967). Cardiovascular disease in rats. In: *Pathology of laboratory rats and mice*. Cotchin E. (ed). Blackwell Sci. Publications. Oxford. pp 213-228.
- Frohlich E.D. (1989). Overview of hemodynamic and non-hemodynamic factors associated with left ventricular hypertrophy. *J. Mol. Cell. Cardiol.* 21(suppl. V), 3-10.
- Fukuda H., Sawa Y., Kadoba K., Taniguchi K., Shimazaki Y. and Matsuda H. (1995). Supplement of nitric oxide attenuates neutrophil-mediated reperfusion injury. *Circulation* 92(suppl. II), 413-416.
- Gardiner S.M., Compton A.M., Bennett T., Palmer R.M.J. and Moncada S. (1990). Regional haemodynamic changes during oral ingestion of NG-monomethyl-L-arginine or NG-nitro-L-arginine methyl ester in conscious Brattleboro rats. *Br. J. Pharmacol.* 101, 10-12.
- Garg U.C. and Hassid A. (1989). Nitric oxide generating vasodilators and 8-bromo-cyclic guanosine monophosphate inhibit mitogenesis and proliferation of cultured rat vascular smooth muscle cells. *J. Clin. Invest.* 83, 1774-1777.
- Gerová M., Pechánová O., Stoev V., Kittová M., Bernátová I. and Bárta E. (1996). Early changes in protein synthesis in epicardial coronary

Cardiovascular changes in NO deficiency

- artery of pressure-overloaded heart. *Am. J. Physiol. (Heart. Circ. Physiol.)* 39, H685-H691.
- Greaves P. and Faccini J.M: Cardiovascular system. In: *Rat histopathology*. Greaves P. (ed). Elsevier. Amsterdam. pp 74-81.
- Gupta S., McArthur C., Grady C. and Ruderman N.B. (1994). Stimulation of vascular Na-K-ATPase activity by nitric oxide: a cGMP-independent effect. *Am. J. Physiol.* 266 (Heart. Circ. Physiol. 35), H2146-H2151.
- Harding P., Carretero O.A. and LaPointe M.C. (1995). Effects of interleukin-1beta nitric oxide on cardiac myocytes. *Hypertension* 25, 421-430.
- Hoshida S., Yamasita N., Igarashi J., Nishida M., Hori M., Kamada T., Kuzuya T. and Tada M. (1995). Nitric oxide synthase protects the heart against ischemia-reperfusion injury in rabbits. *J. Pharmacol. Exp. Ther.* 274, 413-418.
- Hropot M., Grötsch H., Klause E., Langer K.H., Linz W., Wiemer G. and Schölkens B.A. (1994). Ramipril prevents the detrimental sequels of chronic NO synthase inhibition in rats: hypertension, cardiac hypertrophy and renal insufficiency. *Naunyn-Schmiedebergers Arch. Pharmacol.* 350, 646-652.
- Johns R.A., Peach M.J., Linden J. and Tichotsky A. (1990). NG-monomethyl L-arginine inhibits endothelium-derived relaxing factor-stimulated cyclic GMP accumulation in cocultures of endothelial and vascular smooth muscle cells by an action specific to the endothelial cell. *Circ. Res.* 67, 979-985.
- Kanvar S. and Kubes P. (1995). Nitric oxide is an antiadhesive molecule for leukocytes. *New Horiz.* 3, 93-104.
- Kolpakov V., Gordon D. and Kulik T.J. (1995). Nitric oxide-generating compounds inhibit total protein and collagen synthesis in cultured vascular smooth muscle cells. *Circ. Res.* 76, 305-309.
- Kristek F., Gerová M., Devát L. and Varga I. (1995). Cardiac hypertrophy and vascular remodeling in nitric oxide-deficient hypertension. *Endothelium* 3(Suppl.), 94.
- Matsuoka H., Nakata M., Kohomo K., Koga Y., Nomura G., Toshima H. and Imaizumi T. (1996). Chronic L-arginine administration attenuates cardiac hypertrophy in spontaneously hypertensive rats. *Hypertension* 27, 14-18.
- McDonald K.M., Francis G.S., Carlyle P.F., Hauer K., Matthews J., Hunter D.W. and Cohn J.N. (1992). Hemodynamic, left ventricular structural and hormonal changes after discrete myocardial damage in the dog. *J. Am. Coll. Cardiol.* 19, 460-467.
- McNamara D.B., Bedi B., Aurora H., Tena L., Ignarro L.J., Kadowitz P.J. and Akers D.J. (1993). L-arginine inhibits balloon catheter-induced intimal hyperplasia. *Biophys. Res. Commun.* 193, 291-296.
- Moreno H. Jr., Metzke K., Bento A.C., Antunes E., Zatz R., de Nucci G. (1996). Chronic nitric oxide inhibition as a model of hypertensive heart muscle disease. *Basic Res. Cardiol.* 91, 248-255.
- Numaguchi K., Egashira K., Takemoto M., Kadokami T., Shimokawa H., Sueishi K. and Takeshita A. (1995). Chronic inhibition of nitric oxide synthesis caused coronary microvascular remodeling in rats. *Hypertension* 26 (part 1), 957-962.
- Palmer R.M.J., Rees D.D., Ashton D.S. and Moncada S. (1988) L-Arginine is the physiological precursor for the formation of nitric oxide in endothelium-dependent relaxation. *Biochem. Biophys. Res. Commun.* 153, 1251-1256.
- Pechánová O., Babál P. and Bernátová I. (1995). Pathologic changes in rat heart after long-term nitric oxide synthase inhibition. *Endothelium* 3 (Suppl.), 93.
- Philips N., Bashey R.I. and Jimenez S.A. (1994). Collagen and fibronectin expression in cardiac fibroblasts from hypertensive rats. *Cardiovasc. Res.* 28, 1342-1347.
- Ribeiro N.O., Antunes E., de Nucci G., Lovisolio S.M. and Zatz R. (1992). Chronic inhibition of Nitric Oxide Synthesis. A new model of arterial hypertension. *Hypertension* 20, 298-303.
- Robert V., Silvestre J.S., Charlemagne D., Sabri A., Trouve P., Wassef M., Swynghedauw B. and Delcayre C. (1995). Biological determinants of aldosterone-induced cardiac fibrosis in rats. *Hypertension* 26 (part 1), 971-978.
- Sambrook J., Fritsch E.F. and Maniatis T. (1989). Isolation of DNA from mammalian cells. In: *Molecular cloning. A laboratory manual*. Second edition. Ford N. (ed). Gold Spring Harbor Laboratory Press. New York. pp 9.16-9.19.
- Scott-Burden T., Schini V.B., Elizondo E., Junquero D.C. and Vanhoutte P.M. (1992) Platelet-derived growth factor suppresses and fibroblast growth factor enhances cytokine-induced production of nitric oxide by cultured smooth muscle cells. *Circ. Res.* 71, 1088-1100.
- Shen W., Hintze T.H. and Wolin M.S. (1995). Nitric oxide. An important signaling mechanism between vascular endothelium and parenchymal cells in the regulation of oxygen consumption. *Circulation* 92, 3505-3512.
- Shudo H., Sakuma I., Yoshioka M., Togashi H., Saito I., Saito H. and Levi R. (1992). A chronic model of mild low-renin hypertension in the rat by inhibition of the L-arginine to nitric oxide pathway. *Circulation* 86 (Suppl. I), I-560.
- Sventek P., Li J.S., Grove K., Deschepper C.F. and Schiffrin E.L. (1996). Vascular structure and expression of endothelin-1 gene in L-NAME-treated spontaneously hypertensive rats. *Hypertension* 27, 49-55.
- Van Vleet J.F., Ferrans V.J. and Herman E. (1991). Cardiovascular and skeletal systems. In: *Handbook of toxicologic pathology*. Haschek W. (ed) Academic Press Inc. Rousseau CG. San Diego. pp 539-604.

Accepted November 29, 1996