

Electron microscopic perspectives of gill pathology induced by 1-naphthyl-N- methylcarbamate in the goldfish (*Carassius auratus* Linnaeus)

C.J. Pfeiffer¹, B. Qiu¹ and C.H. Cho²

¹Department of Biomedical Sciences and Pathobiology, Virginia-Maryland Regional College of Veterinary Medicine, Virginia Tech, Blacksburg, Virginia, USA and ²Department of Pharmacology, Faculty of Medicine, University of Hong Kong, Hong Kong

Summary. This experiment has clarified the ultra-structural pathology, by scanning (SEM) and transmission electron microscopy (TEM), induced by 1-naphthyl-N- methylcarbamate (carbaryl) in the gills of juvenile goldfish (*Carassius auratus* Linnaeus). Carbaryl is a low toxicity pesticide commonly used in forestry and agriculture and for controlling aquatic weeds and crustacean predators of shellfish, and has been known to cause gill damage in fish and clams. A variety of cellular changes were observed after exposure of goldfish for 96 h to a sublethal dose of 10 mg carbaryl/l of water. SEM revealed secondary lamellar fusion, distortion, thinning, and mucus release. TEM responses included enlargement of subepithelial lymphatic spaces and mitochondrial disruption and distortion of the lamellar covering epithelium. Pillar cells became detached and chloride cells were vacuolated. Fish were able to withstand these changes in subacute experiments due to redundancy in gill surface area.

Key words: Carbamate, Fish, Gill, Ultrastructure, Pesticide

Introduction

The insecticide, 1-naphthyl-N-methylcarbamate, commonly known as carbaryl or sevin, has been used for many years as a low toxicity biocide both for the control of pests in forestry and agriculture and also for the control of crustacean predators of shellfish and aquatic weeds in bays and estuaries. Not surprisingly, its toxicity and that of one of its hydrolytic metabolites, 1-naphthol, has inadvertently spread to desirable species of edible fish, clams, etc. (Lowe, 1967; Butler et al., 1968; Armstrong and Millemann, 1974a,b; Basha et al., 1983). This pesticide is a cholinesterase inhibitor, and it has

been associated with increased mortality (Lowe, 1967; Basha et al., 1983), behavioral changes (Weis and Weis, 1974; Lingaraja and Venugopalan, 1978) induction of liver, kidney, and gill damage in estuarine and freshwater species of fish (Gill et al., 1988), and altering *in vitro* cell division (Söderpalm-Berndes and Önfelt, 1988).

The gills of bony fish serve not only as the principal respiratory organ, but also participate in acid-base regulatory, osmoregulatory, and excretory functions. They are often a sensitive and critical site of pathology and respond readily to bacterial, viral, waterborne chemical toxicant and salinity factors. Although an early, preliminary study has revealed that carbaryl and 1-naphthol were toxic to goldfish (Shea and Berry, 1983), and that carbaryl exposure caused damage to gills as studied by light microscopy of another freshwater fish species (Gill et al., 1988), information is lacking on the fine structural responses of gill tissue to this important pesticide. In our laboratory we have been using goldfish (*Carassius auratus* Linnaeus) as an assay model for toxicology testing of fish because this readily available and inexpensive species has a significant published database with respect to hematologic, anatomic, biochemical, and pathologic background factors (Bailey, 1957; Yamamoto, 1965, 1966; Aubin and Johansen, 1969; Grant and Mehrle, 1970; Young et al., 1971; Minick and Chavin, 1972; Burton and Murray, 1979; Ostland et al., 1989). The present communication reports our current findings on the effects of carbaryl exposure on goldfish gill ultrastructure, as investigated by transmission (TEM) and scanning electron microscopy (SEM).

Materials and methods

The fish utilized for this investigation were juvenile goldfish (*Carassius auratus* Linnaeus) obtained from a local commercial supplier. Fish of both sexes at a weight range of 1.3-3.3 g were randomly placed, 20 fish per aquarium, in 36 l of clean, aerated tap water for the initial equilibration and subsequent chemical testing

periods. The water was chemically dechlorinated and aerated with an air bubbler for 24 hours prior to use, and fish were subsequently allowed to equilibrate for 48 hours in the aquaria prior to administration of any test chemicals. The water was maintained at a temperature of 22-23°C and aquaria were in a light controlled laboratory with a 10 h light and 14 h dark cycle per day.

Accumulative 96 hour mortality rates were assessed for goldfish exposed to a range of doses of technical grade (99.7%, Union Carbide Corp., Wilmington, DE) carbaryl which was dissolved in their aquaria. The doses studied included 40, 30, 20, 17.5, 15, 12.5, 10, 5, 1, and 0.25 mg carbaryl/l final concentration in order to obtain the median lethal concentration (LC_{50}). Mortality was assessed at 3, 6, 9, 12, 24, 48, 72, and 96 h after carbaryl administration. Gill samples were acquired from healthy-appearing and moribund fish, which were sacrificed by decapitation at the 96 h interval, which has been recommended as a standard assay time for aquatic animal toxicity screening (Murty, 1986).

Tissue samples were taken of gill arches and placed immediately in cold 5% glutaraldehyde/3% formaldehyde in 0.1M Na-cacodylate buffer at pH 7.4 for fixation. Fixed samples were washed with 0.1M cacodylate buffer (pH 7.4), postfixed in 1% osmium tetroxide in 0.1M cacodylate buffer for 1 h, washed in buffer again and dehydrated in a series of alcohols. For orientation of specimens and preliminary study by light microscopy, semithin sections (1 μ m) were cut from specimens embedded in Poly/Bel 812 (Polysciences) using standard methods we have used (Pfeiffer and Rowntree, 1996). The sections were stained with 1% toluidine blue in 1% sodium borate for 30 sec followed by 0.5% safranin in 0.5% sodium borate for 10 sec. The sections were subsequently cut and doubly stained with

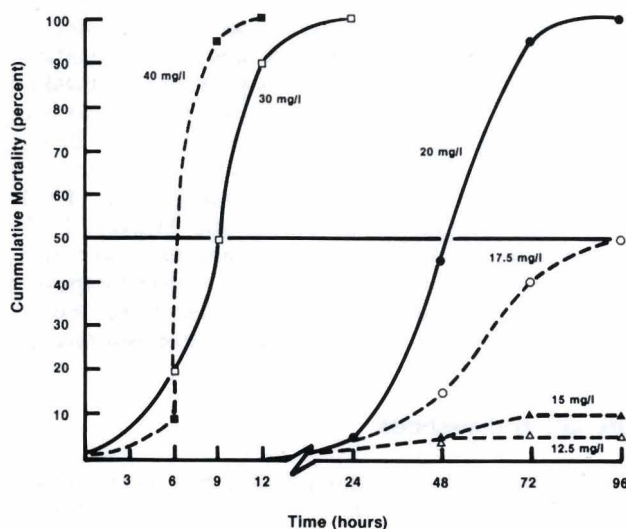


Fig. 1. Cumulative mortality of goldfish exposed to graded doses of carbaryl. Note that the 48 h median lethal concentration (LC_{50}) is about 20 mg/l resulting in about 50 percent mortality at this time. At a dose of 17.5 mg/l about 50 percent of fish are dead at 96 h.

lead citrate and uranyl acetate and were studied with a JEOL 100 CX-II transmission electron microscope operating at 80 KV. Multiple sections from multiple tissue blocks prepared from each gill were examined. Large tissue specimens (3 x 2 x 2 mm) were similarly fixed for examination by scanning electron microscopy. These specimens were critical point dried, mounted, and coated with gold (approximately 1500 Å) in a SPI sputter coater for 5 min and examined in a JEOL JSM 35C scanning electron microscope operating at 10 KV.

Results

The screening for subacute toxicity of carbaryl, as evaluated by cumulative mortality, is summarized in Figure 1 for many of the doses, which reveals the LC_{50} dose to be approximately 20 mg/l at 48 h. This dose resulted, however, in 100% mortality by 96 h. Therefore, on the basis of these findings and the observation that little mortality was observed at 96 h at the 12.5 mg/l dose (Fig. 1), we selected a dose of 10 mg/l to evaluate the sublethal effects of carbaryl on gills. Further, preliminary morphologic examination of gills from goldfish exposed to this low dose had indicated some pathologic changes were to be anticipated.

Low power SEM provided a good overview of the




Fig. 2. Low magnification SEM of secondary lamellae (arrow) of normal control fish. x 220

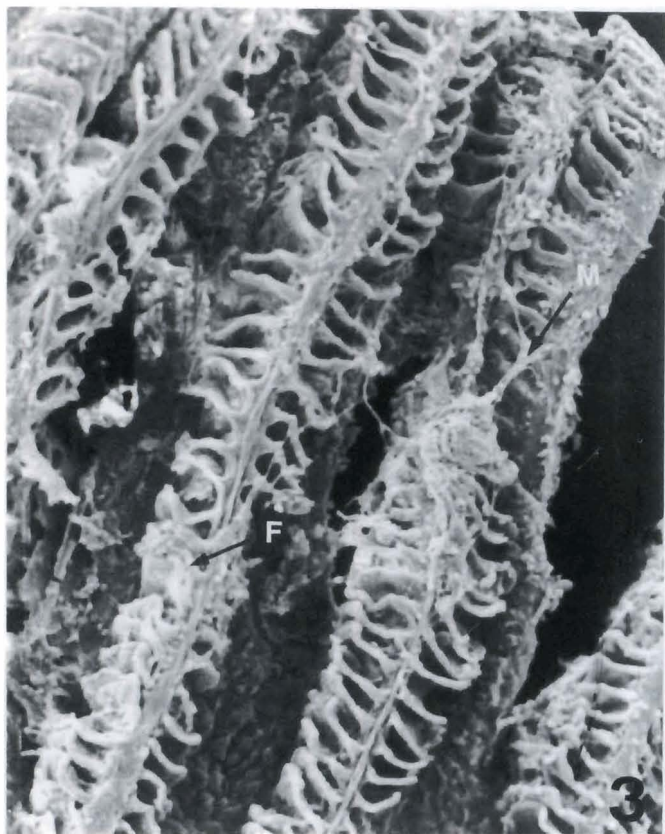


Fig. 3. Low magnification SEM of gills of fish exposed to 10 mg carbaryl/l and sacrificed at 96 h revealed marked distortion of the secondary gill lamellae, sloughing of the epithelium, fusion (F) of the lamellae, and strands of secreted mucus (M). x 210

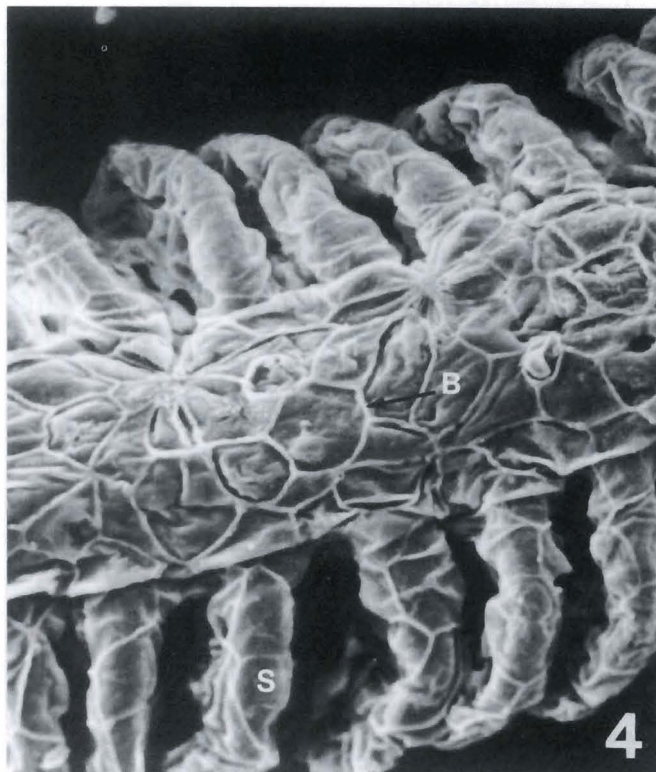

Fig. 4. Higher magnification SEM of normal control goldfish gill. Note prominent cell boundaries (B) on primary filament. The cell boundaries of these epithelial pavement cells are also discernible on the secondary lamellae (S). x 870

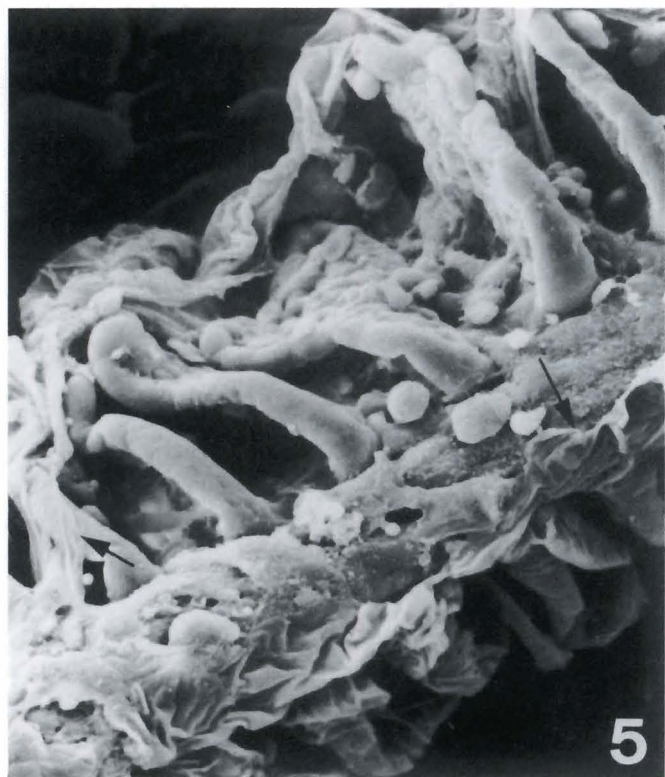

Fig. 5. Higher magnification SEM of carbaryl-treated fish (10 mg/l, 96 h) showing marked sloughing (arrows) of pavement epithelium. x 800

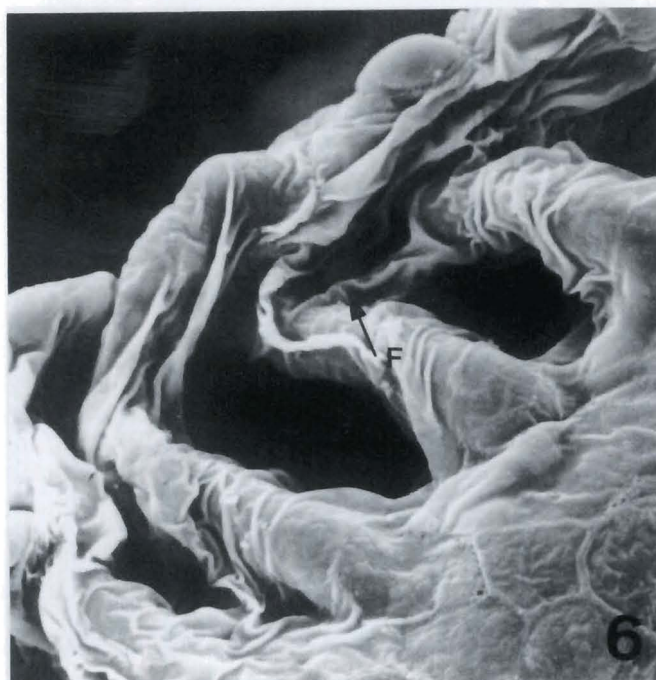


Fig. 6. SEM of gill of carbaryl-treated fish (10 mg/l, 96 h) showing fusion (F) between two secondary lamellae. In this sample, the surface, pavement epithelium is wrinkled but not yet sloughed. x 1,480

secondary (or respiratory) gill lamellae. In gills of control fish these secondary lamellae constituted evenly-spaced parallel plates (Fig. 2). In goldfish exposed to 10 mg carbaryl/l and sacrificed at 96 h, the secondary lamellae were distorted, evidence of lamellae fusion was observed, and some sloughing of surface epithelium was evident (Fig. 3). The lamellae of treated fish were also thinner than in control fish. Strands of mucus were seen on the gill surface of carbaryl-treated fish (Fig. 3) but not in control fish (Figs. 2, 4). At higher magnification by SEM cell boundaries of surface epithelial cells (pavement cells) on both primary gill filaments and secondary lamellae of normal, control fish could be discerned (Fig. 4). At this same magnification of carbaryl-treated (10 mg/l, 96 h) fish gills however, the denuding of the lamellae was particularly evident, as shown in a severe case (Fig. 5). At still higher magnification of a gill from a carbaryl-treated fish (10 mg/l, 96 h) surface wrinkling prior to denudation of the epithelium, and fusion of the secondary lamellae was observed (Fig. 6). High resolution SEM of individual cells comprising the surface epithelium of the lamellae of normal control fish shows both distinct boundaries between cells and short, surface ridges (Fig. 7). These ridges are believed to be remnants of the intercellular junctions which were formerly connected to overlying epithelial cells which have sloughed off by normal cell replacement processes. The apical openings to mucus-secreting cells were also observed on the lamellae surface. These structures were evident either filled with

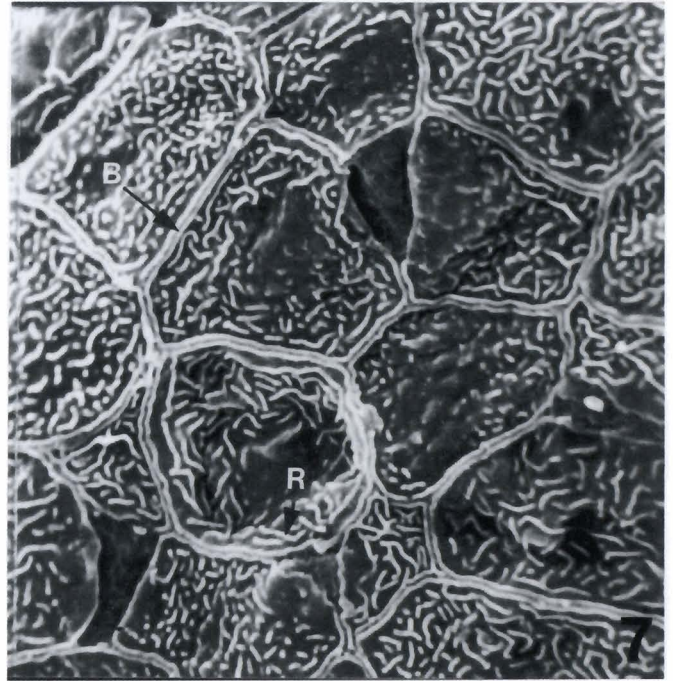


Fig. 7. At high SEM resolution, the apical surface of pavement epithelial cells shows multiple, short surface ridges (R) and distinct cell boundaries (B). The ridges are likely the remnants of intercellular interdigitations from previously overlying cells. Normal control fish. x 3,300

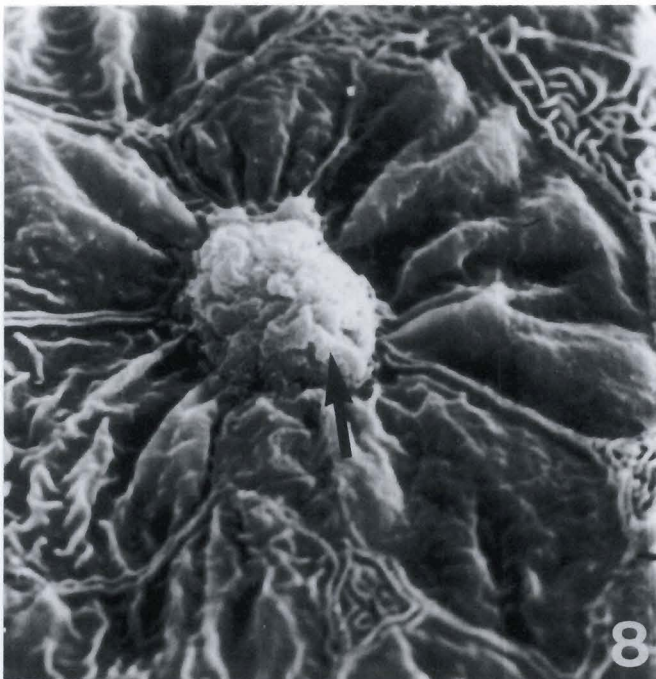


Fig. 8. This figure illustrates the apical opening (arrow) of a mucous cell. An aggregate of mucus is seen in the process of expulsion to the outer surface of the gill secondary lamella of a normal control fish. x 4,500

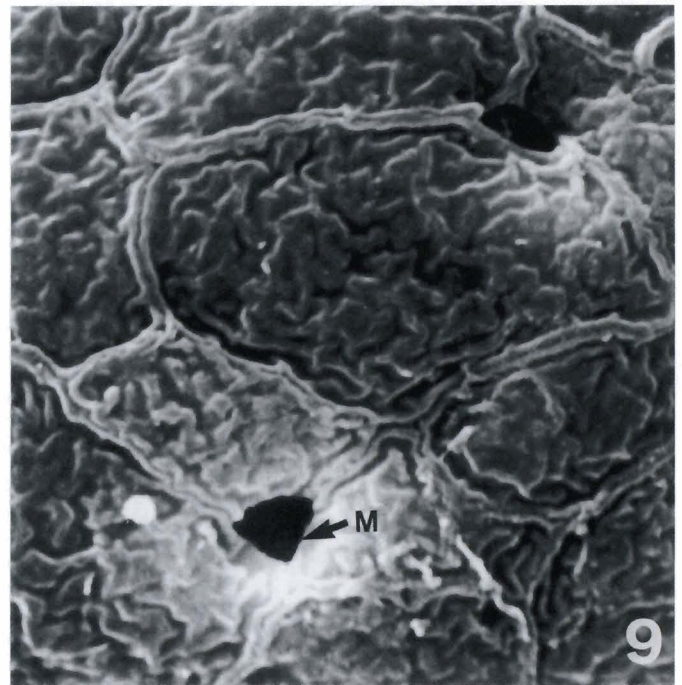


Fig. 9. Openings (M) to mucus secreting cells were sometimes observed free of mucus. This sample was from a carbaryl-treated fish (10 mg/l, 96 h), and the stored mucus may have already been depleted. x 5,300

EM of carbaryl pathology in fish gills

mucus (Fig. 8) or devoid of mucus (Fig. 9).

Cyto-pathologic changes induced by carbaryl in secondary gill lamellae, deeper than the surface changes observed by SEM, were elucidated by TEM. Cross-section of the normal goldfish lamella from a control fish is illustrated in Figure 10. Surface epithelial cells were flattened and contained scattered, rough and smooth endoplasmic reticula, small ovoid mitochondria, and other typical cytoplasmic organelles. Pillar cells supporting the central blood spaces were typical of bony fish (Fig. 10). Marked ultrastructural changes were induced by carbaryl exposure (10 mg/l, 96 h). These included enlargement of the subepithelial lymphatic spaces and cytoplasmic, distortion of the covering epithelial cells with disruption of their mitochondria (Fig. 11). In addition, pillar cells rounded up and partially detached, resulting in coalescence of central vascular spaces (Fig. 12). Chloride cells of the secondary gill lamellae also displayed cytoplasmic changes, including the presence of significant numbers of large

(1.15 μ m) cytoplasmic vacuoles (Figs. 12, 13). The majority of mitochondria and the intracellular tubular system which is characteristic of chloride cells, however, were not effected by carbaryl at this dose and time (Fig. 14). Mucous cells of the secondary lamellae were unaffected by carbaryl exposure.

Discussion

Carbaryl remains a widely used insecticide and herbicide, generally considered of low toxicity (Katz, 1961), but because of its diverse and massive use it has long been associated with pathologic changes in aquatic animals. This agent and other carbamates can accumulate in the aquatic environment either from direct use in water or as runoff from soil or aerial contamination. Early studies have evaluated the persistence of carbaryl in water and its rate of hydrolysis, photolysis, and biolysis, indicating its delayed breakdown in acidified water (Aly and El-Dib, 1971; Wolfe et al., 1978).

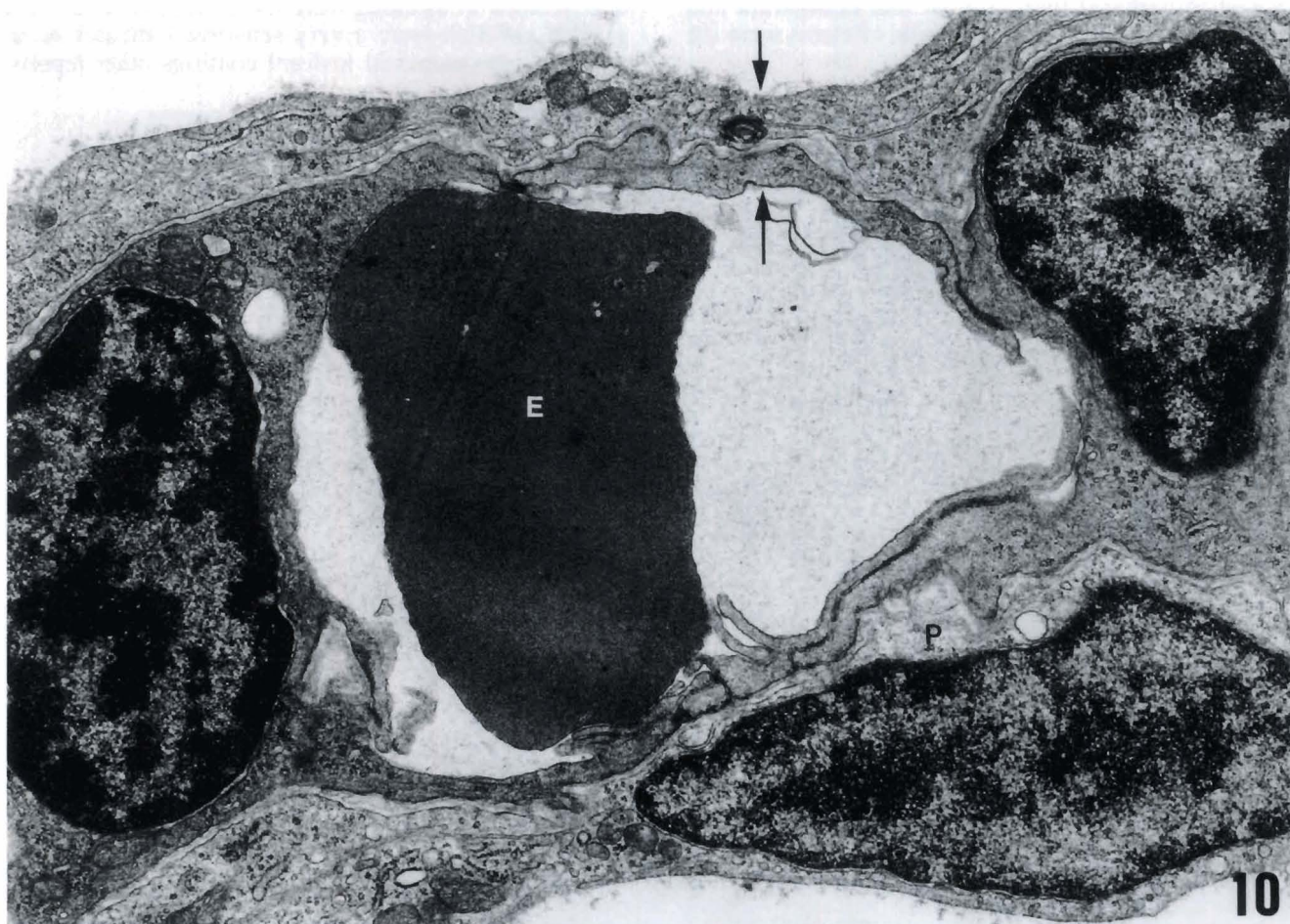


Fig. 10. Transverse section through gill secondary lamella, shown by TEM of normal control goldfish. An erythrocyte (E) is shown in the lumen of the central blood space and prominent nuclei of pillar cells are illustrated on either side. A pavement epithelial cell (P) with large nucleus is shown at the bottom. Note the thin area (between arrows) across which respiratory transport occurs, which includes the outer flanges of the pillar cells. Normal control fish. x 16,600

EM of carbaryl pathology in fish gills

However, the half-life of carbaryl in seawater is measured in days rather than years as with other types of pesticides (Karinen et al., 1967). In the present experiment in which 96 h was selected as an optimal and standard subacute toxicity screening period, considerable carbaryl would have remained intact in the water throughout the test duration. It must also be considered in the present experiment that carbaryl would exert not only direct effects on the goldfish gills by local transport at the site of gills, but would also be absorbed in the gastrointestinal tract after ingestion (Pekas, 1971; Shah and Guthrie, 1973), resulting in gill and other systemic effects as has been shown by early workers.

The ultrastructural changes observed in the goldfish gills after 96 h of exposure to carbaryl were marked, although the fish remained alive in apparent good health. This suggested that there must be considerable redundancy in transport area in the gill architectural morphology to allow for critical respiratory transport in spite of significant pathology. It should be noted that the fish, *Therapon jarbua* consumed more oxygen when exposed to carbaryl than control fish (Lingaraja and Venugopalan, 1978). Further, the gills of clams were the

most severely affected organ after exposure to carbaryl (Armstrong and Millemann, 1974a,b), and the histopathologic response consisted mainly of necrosis of gill epithelial tissue, corresponding to the epithelial sloughing we observed by SEM of goldfish gills. Gill and associates (Gill et al., 1988) also reported that carbaryl induced in bony fish (*Puntius conchonius* Ham.) light microscopic evidence of gill epithelial separation and secondary lamellar fusion. The evidence we found by SEM of strands of secreted mucus on the gill surface of carbaryl-treated goldfish parallels our finding in gills of hybrid striped bass, in which a pathologic sequela of overcrowding stress was a marked increase in mucous cell numbers (Smith et al., unpublished results). Other functions of gills, such as osmotic regulation, may have been impaired in the present experiment, as we also observed abnormal cytoplasmic inclusions in the chloride cell. It might be argued that the large, vacuolar structures observed in the chloride cells were remnants of swollen mitochondria. This point remains uncertain, however, as intermediate stages of mitochondrial degeneration or swelling were not evident. The fact that gills in goldfish were a very sensitive indicator of an aqueous, environmental toxicant confirms other reports,

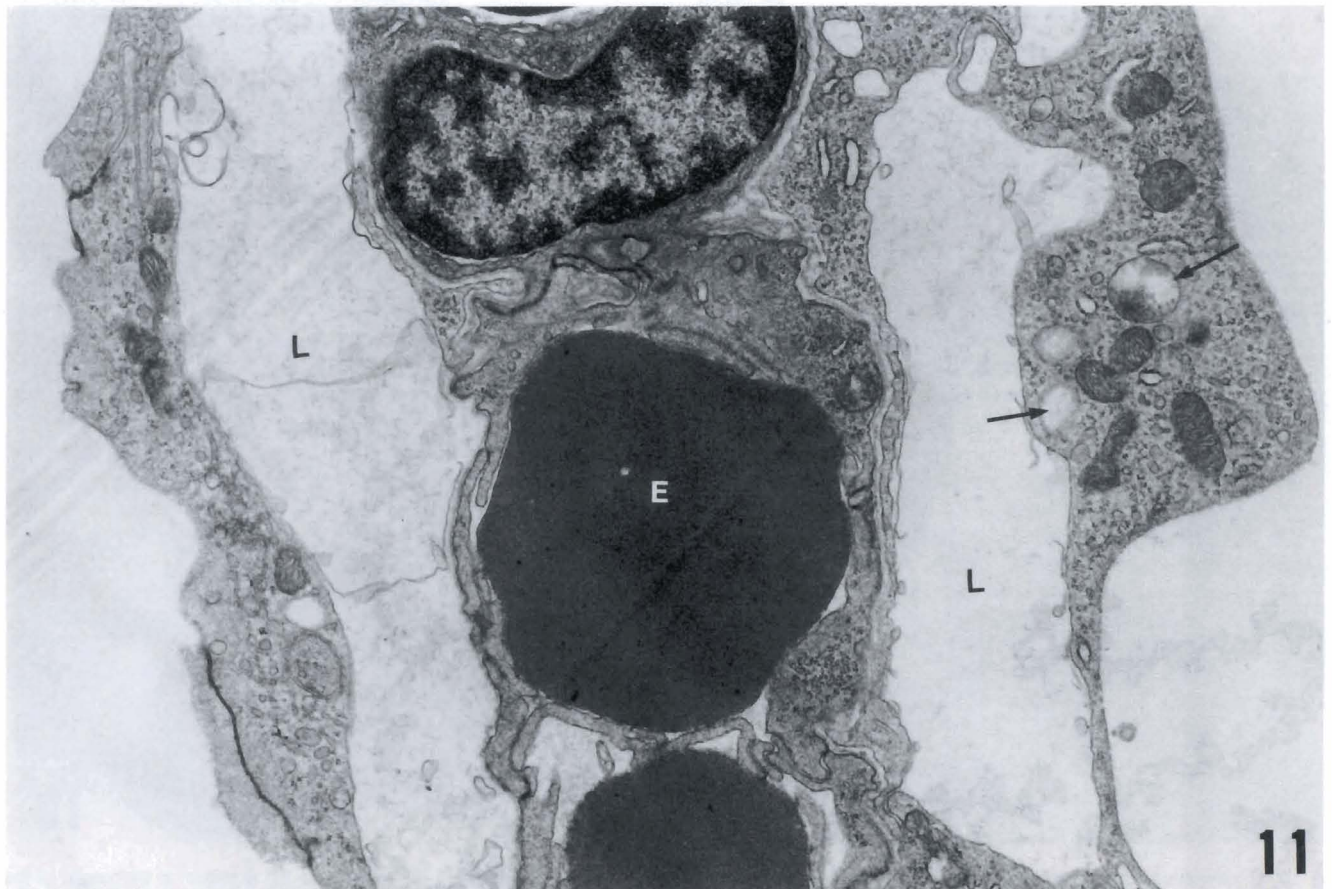


Fig. 11. Carbaryl induced great enlargement of the subepithelial lymphatic spaces (L), and mitochondrial disruption (arrows) and distortion of the pavement epithelial cells on secondary lamellae. Erythrocytes (E) fill the central blood spaces. x 14,700

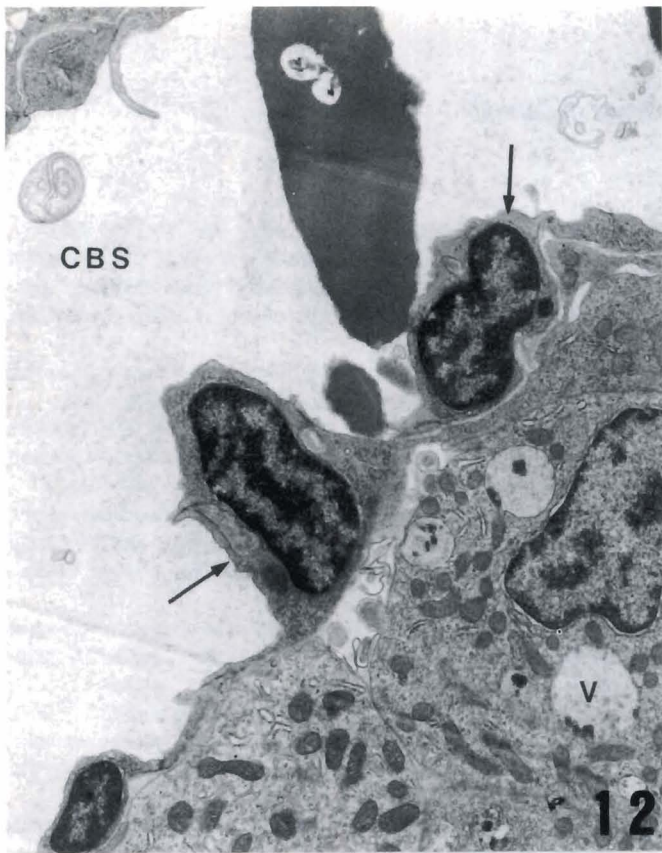


Fig. 12. This TEM illustrates carbaryl-induced (10 mg/l, 96 h) breakdown and coalescence of the central blood spaces (CBS) due to atrophy of the pillar cells (arrows). Note also the appearance of abnormal cytoplasmic vacuoles (V) in the chloride cells, where the numerous mitochondria nonetheless remain normal. x 7,500

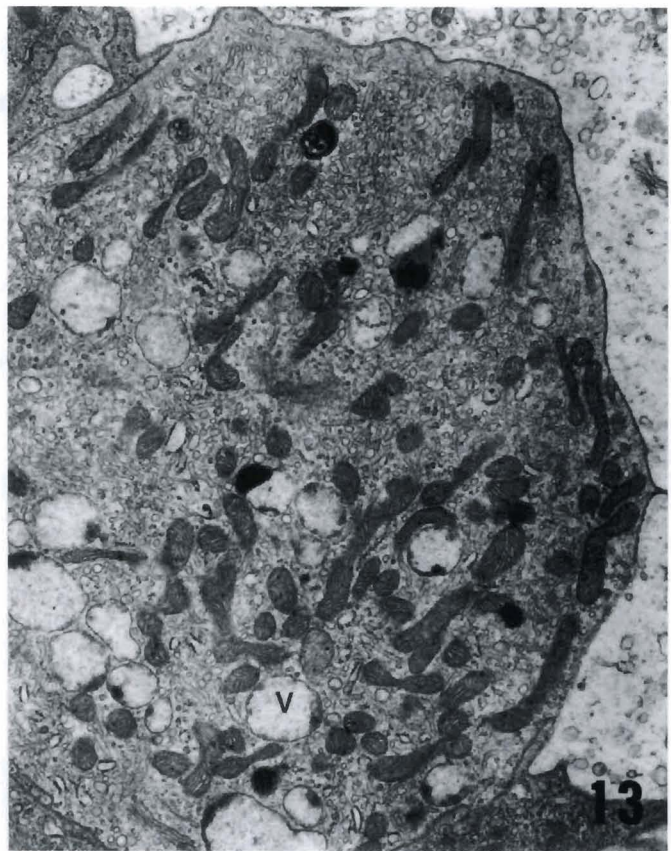


Fig. 13. Apical aspect of chloride cell in carbaryl-treated fish (10 mg/l, 96 h), showing abnormal cytoplasmic vacuoles (V), but normal mitochondria (M). x 11,300

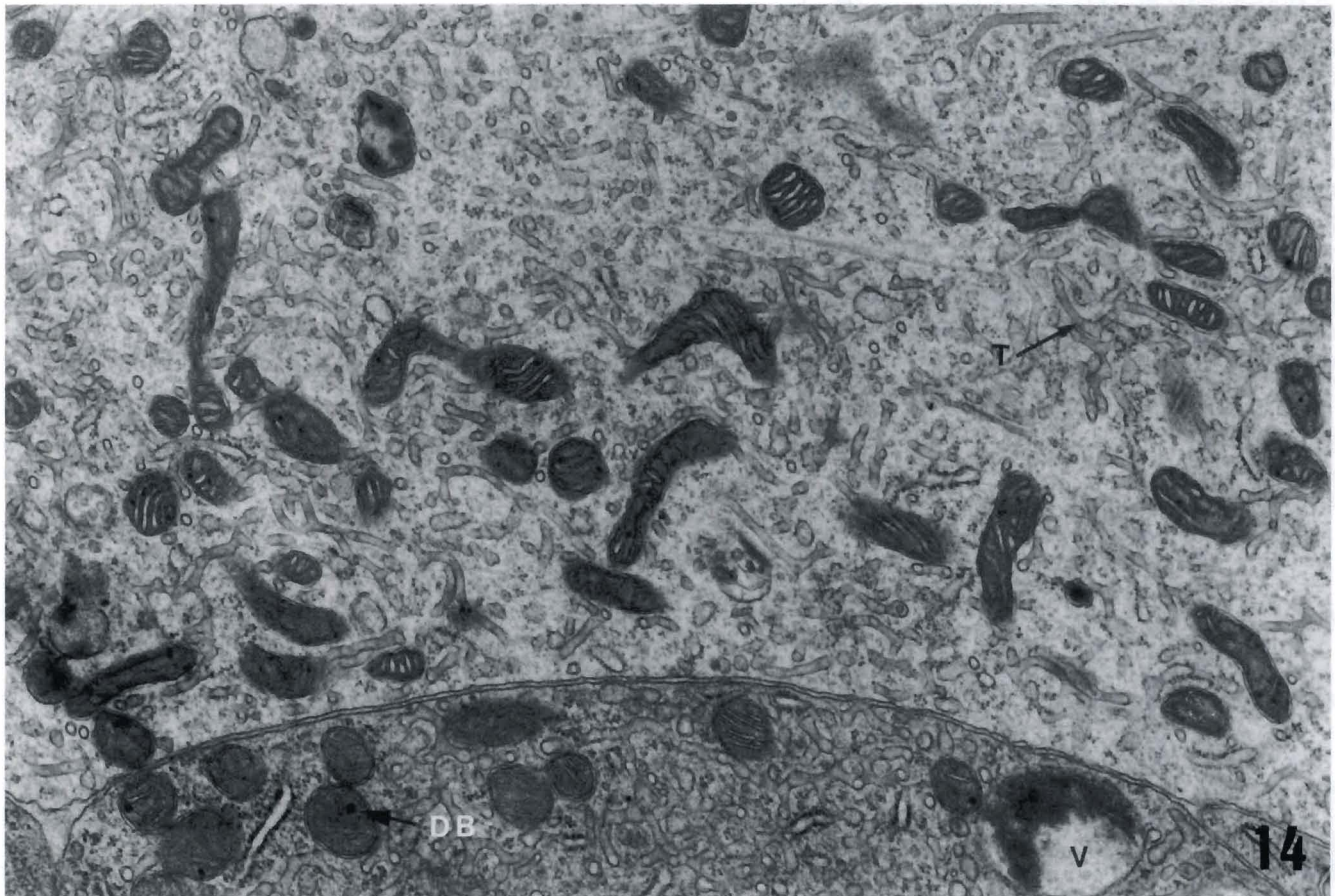


Fig. 14. At high TEM magnification, the fine structure of normal-appearing mitochondria, with their dense bodies (DB), and normal intracellular tubular system (T) is shown. An abnormal vacuole (V) is shown in the cell below. Fish was exposed to carbaryl (10 mg/l, 96 h). x 22,000

attesting to gill sensitivity to other xenobiotic chemical contaminants (Kumaragura et al., 1982). The nature of gill cytomorphologic pathology observed after carbaryl exposure also was relatively non-specific, since pillar cell damage, fused secondary lamellae, and swollen, subepithelial lymphatic channels have also been seen in response to crowding stress in another species (Smith et al., unpublished results). The lamellar edema, and ultrastructural and distal thickening of gill lamellae that we have reported for hybrid striped bass subjected to environmental crowding (Smith et al., unpublished results) has also been seen after pesticide exposure (Murty, 1986). Although we did not examine ultrastructural pathology in other tissue types in this experiment, it can be anticipated that gills would not be the sole tissue to react adversely to carbaryl (Van Leeuwen et al., 1986; Gill et al., 1988). Indeed, histopathologic damage in the fish liver has been reported after low doses of carbaryl (Gill et al., 1988).

The mechanisms by which carbaryl damages the goldfish gill will await further clarification. However, we have shown in unpublished, preliminary experiments that concurrent administration of tungstic acid (dose range 1.0-100 mg/l) in aquarium water reduces up to 50 percent of the mortality of goldfish at 96 h which is induced by 20 mg carbaryl/l. Since carbaryl is a cholinesterase inhibitor, its toxicity is attributable at least in part to acetylcholine accumulation. Tungstic acid has been reported to precipitate rapidly the acetylcholine or choline in cholinergic nerve terminals (Tsuji, 1984; Tsuji and Anglade, 1989), so it is likely protective by reacting directly with the excess acetylcholine. Data are not yet available with respect to specific effects of tungstic acid on the histopathology of gill tissue, although we have reported that it reduces stress-induced mammalian gastric pathology (Qiu et al., 1996).

Acknowledgments. The authors are most grateful to Prof. Hara Misra for his encouragement and admirable departmental organization of carbaryl research, and to V. Viers and K. Lowe for their excellent technical assistance.

References

- Aly O.M. and El-Dib M.A. (1971). Studies on the persistence of some carbamate insecticides in the aquatic environment. I. Hydrolysis of sevin, baygon, pyrolan and dimetilan in waters. *Water Res.* 5, 1191-1205.
- Armstrong D.A. and Millemann R.E. (1974a). Effects of the insecticide Carbaryl on clams and some other intertidal mud flat animals. *J. Fish. Res. Bd. Canada* 31, 466-470.
- Armstrong D.A. and Millemann R.E. (1974b). Pathology of acute poisoning with the insecticide Sevin in the bent-nosed clam, *Macoma masuta*. *J. Invert. Pathol.* 24, 201-212.
- Aubin A.E. and Johansen P.H. (1969). The effects of an acute DDT exposure on the spontaneous electrical activity of goldfish cerebellum. *Can. J. Zool.* 47, 163-166.
- Bailey R.E. (1957). The effect of estradiol on serum calcium, phosphorus, and protein of goldfish. *J. Exp. Zool.* 136, 455-469.
- Basha S.M., Rao K.S.P., Rao K.R.S. and Rao K.V.R. (1983). Differential toxicity of malathion, BHC, and carbaryl to the freshwater fish, *Tilapia mossambica* (Peters). *Bull. Environ. Contam. Toxicol.* 31, 543-546.
- Burton C.B. and Murray S.A. (1979). Effects of density on goldfish blood. I. Hematology. *Comp. Biochem. Physiol.* 62A, 555-558.
- Butler J.A., Millemann R.E. and Stewart N.E. (1968). Effects of the insecticide Sevin on survival and growth of the cockle clam *Clinocardium nuttalli*. *J. Fish. Res. Bd. Canada* 25, 1621-1635.
- Gill T.S., Pant J.C. and Pant J. (1988). Gill, liver, and kidney lesions associated with experimental exposures to carbaryl and dimethoate in fish (*Puntius conchonus* Ham.). *Bull. Environ. Contam. Toxicol.* 41, 71-78.
- Grant B.F. and Mehrle P.M. (1970). Chronic endrin poisoning in goldfish, *Carassius auratus*. *J. Fish. Res. Bd. Canada* 27, 2225-2232.
- Karinen J.F., Lamberton J.G., Stewart N.E. and Terriere L.C. (1967). Persistence of carbaryl in the marine estuarine environment. Chemical and biological stability in aquarium systems. *J. Agric. Fd. Chem.* 15, 148-156.
- Katz M. (1961). Acute toxicity of some organic insecticides to three species of salmonids and to the threespine stickleback. *Trans. Amer. Fish. Soc.* 90, 264-268.
- Kumaragura A.K., Beamish F.W.H. and Ferguson H.W. (1982). Direct and circulatory paths of permethrin (NRDC-143) causing histopathological changes in the gills of rainbow trout, *Salmo gairdneri* Richardson. *J. Fish. Biol.* 20, 87-91.
- Lingaraja T. and Venugopalan V.K. (1978). Pesticide-induced physiological and behavioural changes in an estuarine teleost *Therapon jarbua* (Forsk). *Fish. Technol.* 15, 115-119.
- Lowe J.I. (1967). Effects of prolonged exposures to Sevin on an estuarine fish, *Leiostomus xanthurus* Lacépède. *Bull. Environ. Contamin. Toxicol.* 2, 147-155.
- Minick M.C. and Chavin W. (1972). Effects of vertebrate insulins upon serum FFA and phospholipid levels in the goldfish, *Carassius auratus* Linnaeus. *Comp. Biochem. Physiol.* 41A, 791-804.
- Murty A.S. (1986). Toxicity of pesticides to fish. Vol. 1, Chapter 4. Toxicity tests and test methodology. CRC Press. Boca Raton. pp. 117-154.
- Ostland V.E., Ferguson H.W. and Stevenson R.M.W. (1989). Case report: bacterial gill disease in goldfish *Carassius auratus*. *Dis Aquat. Org.* 6, 179-184.
- Pekas J.C. (1971). Uptake and transport of pesticidal carbamates by everted sacs of rat small intestine. *Can. J. Physiol. Pharmacol.* 49, 14-21.
- Pfeiffer C.J. and Rowntree V.J. (1996). Epidermal ultrastructure of the southern right whale calf (*Eubalana australis*). *J. Submicrosc. Cytol. Pathol.* 28, 277-286.
- Qiu B.S., Pfeiffer C.J., Wu W. and Cho C.H. (1997). Tungstic acid reduction of cold-restraint stress-induced ulceration in rats. *J. Gastroenterol. Hepatol.* 12, 19-23.
- Shah P.V. and Guthrie F.E. (1973). Penetration of insecticides through isolated sections of the mouse digestive system: Effects of age and region of intestine. *Toxicol. Appl. Pharmacol.* 25, 621-624.
- Shea T.B. and Berry E.S. (1983). Toxicity of carbaryl and 1-naphthol to goldfish (*Carassius auratus*) and killifish (*Fundulus heteroclitus*). *Bull. Environ. Contam. Toxicol.* 31, 526-529.
- Söderpalm-Berndes C. and Önfelt A. (1988). The action of carbaryl and

EM of carbaryl pathology in fish gills

- its metabolite -naphthol on mitosis in V79 Chinese hamster fibroblasts. Indications of the involvement of some cholinester in cell division. *Mutat. Res.* 201, 349-363.
- Tsuji S. (1984). Electron microscopical autoradiography of [³H] choline fixed by phosphomolybdic acid in the motor nerve terminal. *Neurosci. Lett.* 45, 151-156.
- Tsuji S. and Anglade P. (1989). Acetylcholine in neurons and paraneurons: a histochemical study. *Arch. Histol. Cytol.* 52, 75-83.
- Van Leeuwen C.J., Helder T. and Seinen W. (1986). Aquatic toxicological aspects of dithiocarbamates and related compounds. IV. Teratogenicity and histopathology in rainbow trout (*Salmo gairdneri*). *Aquatic Toxicol.* 9, 147-159.
- Weis P. and Weis J.S. (1974). Schooling behavior of *Menidia menidia* in the presence of the insecticide Sevin (carbaryl). *Mar. Biol.* 28, 261-263.
- Wolfe N.L., Zepp R.G. and Paris D.F. (1978). Carbaryl, prothion and chlorprothion. A comparison of the rates of hydrolysis and photolysis with the rate of biolysis. *Water Res.* 12, 565-571.
- Yamamoto T. (1965). Some observations on the fine structure of the intrahepatic biliary passages in goldfish (*Carassius auratus*). *Z. Zellforsch.* 65, 319-330.
- Yamamoto T. (1966). An electron microscopic study of the columnar epithelial cell in the intestine of fresh water teleosts: goldfish (*Carassius auratus*) and rainbow trout (*Salmo irideus*). *Z. Zellforsch.* 72, 66-87.
- Young R.G., St. John L. and Lisk D.J. (1971). Degradation of DDT by goldfish. *Bull. Environ. Contam. Toxicol.* 6, 351-354.

Accepted December 13, 1996