

Vitamin E prevents neutrophil accumulation and attenuates tissue damage in ischemic-reperfused human skeletal muscle

L. Formigli¹, L. Ibba Manneschi¹, A. Tani¹, E. Gandini², C. Adembri², C. Pratesi³, G.P. Novelli² and S. Zecchi Orlandini¹

¹Department of Human Anatomy and Histology, ²Institute of Anaesthesiology and Intensive Care and

³Institute of Vascular Surgery, University of Florence, Italy

Summary. Neutrophil accumulation and the consequent production of oxygen-derived free radicals are involved in the pathogenesis of Ischemia-Reperfusion syndrome. In this study we investigated whether a treatment with Vitamin E, which has antioxidant properties, could attenuate the tissue damage by interfering with the influx of neutrophils within the ischemic and reperfused human skeletal muscle.

To this purpose, patients undergoing aortic cross-clamping during the surgical repair of aortic abdominal aneurysm were studied as a model of ischemia-reperfusion of the lower limb muscles. Muscle biopsies from the right femoral quadriceps of patients not receiving and receiving Vitamin E pretreatment before surgery were taken: a) after the induction of anaesthesia, as control samples, and b) after a period of ischemia followed by 30 min of reperfusion. The tissue samples were either routinely processed for morphological study and immunohistochemical analysis to detect an altered expression of specific endothelial adhesion proteins, such as E-selectin and ICAM-1. The results obtained showed that Vitamin E administration was able to prevent the accumulation of neutrophils within the ischemic and reperfused muscle. This beneficial effect of Vitamin E was due to its ability to hinder the expression of E-selectin and ICAM-1, molecules known to increase the adhesiveness of endothelium to circulating neutrophils. After treatment with Vitamin E a marked attenuation of the reperfusion injury was also evident. In conclusion, Vitamin E treatment may be considered a valuable tool for protection against the ischemia-reperfusion damage of human skeletal muscle.

Key words: Endothelial adhesive proteins, Neutrophils, Vitamin E, Skeletal muscle

Introduction

The role of neutrophils in ischemia-reperfusion injury has been well established (Horgan et al., 1990; Walden et al., 1990; Zimmeran et al., 1990; Formigli et al., 1992; Siminiak and Ozawa, 1993; Albertine et al., 1994). Indeed, neutrophils accumulate within the ischemic and reperfused (I-R) tissue and contribute to exacerbate the tissue damage by actively producing radical O₂ metabolites (ROM) via the membrane-associated enzyme NADPH oxidase. There is increasing evidence that the microvascular endothelium plays an important role in initiating the events associated with the ischemia-reperfusion syndrome (Granger et al., 1993; Kubes, 1993; Lefler et al., 1993; Grace, 1994) by releasing chemotactic factors (Crawford et al., 1988; Montrucchio et al., 1989; Formigli et al., 1992) and expressing adhesion proteins specific for circulating neutrophils (Lewis et al., 1988; Kubes et al., 1990a,b; Palluy et al., 1992; Granger et al., 1993). In particular, cytokine-activated endothelial cells express E-selectin and the intercellular adhesion molecule (ICAM-1), which have been postulated to be responsible for the initial rolling event and the further adhesion strengthening of neutrophils to the endothelium (Bevilacqua et al., 1989; Luscinskas et al., 1991; Bevilacqua, 1993; Kukielka et al., 1993; Shen and Verrier, 1994). There is now a growing interest in the endogenous substances capable of inhibiting the emigration of neutrophils into the ischemic and reperfused tissues and, consequently, the neutrophil-induced injuries. Vitamin E, a lipophilic antioxidant capable of protecting cellular and subcellular membranes from oxygen radical injury (Massey and Burton, 1989; Farris, 1990), may represent one of these factors. In fact, it has been suggested that Vitamin E may interfere with neutrophil accumulation in the I-R rat myocardium (Campo et al., 1994). Accordingly, after treatment with Vitamin E, a significant reduction in the myeloperoxidase (MPO) activity has been shown in the

ischemic and reperfused rat myocardium (Campo et al., 1994). However, the precise mechanisms of action of Vitamin E upon tissue neutrophil infiltration remain to be elucidated.

The present study was undertaken to evaluate whether a treatment with Vitamin E before the induction of ischemia was able to reduce the recruitment of neutrophils within the ischemic and reperfused human skeletal muscle and hamper the expression of specific endothelial adhesion proteins responsible for neutrophil-endothelial interactions.

Materials and methods

Muscle biopsies from twenty male patients, (mean age 65 ± 4 years), bearing an abdominal aortic aneurysm and undergoing aortic reconstructive surgery, were studied. None of the patients was diabetic or showed evidence of peripheral vascular, renal insufficiency or muscle disease. The patients were divided into two groups of 10 patients each. Group 1 did not receive any drug before surgery; Group 2 received 600 mg (600 UI) of vitamin E (d,1- α -tocopheryl-acetate, Roche) administered orally for 8 days prior to the surgery. All the patients gave a written declaration of informed consent to the study according to the human subjects institutional review committee guidelines. They were premedicated with atropine (0.01 mg/kg) and morphine (0.1 mg/kg) 1 h before induction of general anaesthesia which was induced with thiopentone (3 mg/kg) and atracurium besylate (0.6 mg/kg) and maintained with isoflurane in O₂-air (FiO₂ 30%). The patients were connected to a volume controlled ventilator (Draeger, Werck AV1, Germany) in order to maintain an end-tidal CO₂ (ETCO₂) (Capnolog, Draeger, Werck) between 35 and 40 mmHg. Muscle relaxation was obtained with a continuous infusion of atracurium besylate (0.45 mg/kg/h). ETCO₂, invasive arterial blood pressure (CM 120 Philips, Holland) and haemoglobin saturation (SaO₂) (Nellcor 1000, Hayward, California, USA) were continuously monitored during the surgical procedures. The mean duration of the surgery was 280 min (range 210-480) with an average duration of the ischemic period of 75 min (range 55-170). Fluidotherapy consisted in polysaline solutions and colloids.

Cross-clamping and subsequent declamping of the aorta during surgery of abdominal aortic grafting is known to be a suitable model of I-R of human skeletal muscle of the lower limbs (Novelli et al., 1990). In this study, muscle biopsies from the vastus medialis of the right femoral quadriceps were obtained from Vitamin E-treated and untreated patients and in particular: 1) immediately after the induction of anaesthesia, as non-ischemic control samples, and 2) 30 min after reperfusion.

The tissue samples were processed for light and electron microscopic examinations and for the immunohistochemical analysis.

Electron microscopy

Small fragments of muscle tissue were fixed in cold 4% glutaraldehyde in 0.1M cacodylate buffer, pH 7.4, at room temperature for 4 hours and postfixed in 1% osmium tetroxide in 0.1 M phosphate buffer, pH 7.4, at 4 °C for 1 hour. The samples were dehydrated in a graded acetone series, passed through propylene oxide and embedded in Epon 812. The tissue fragments were embedded with the muscle fiber running parallel to the plane of the sections. Semithin sections, 1-2 μ m thick, were cut and stained with toluidine blue Na-tetraborate and observed under a light microscope. Thin sections were also obtained from the same specimens, stained with uranyl acetate and alkaline bismuth subnitrate and examined under a Siemens Elmiskop at 80 KW.

Immunohistochemistry

The muscle samples were frozen in liquid nitrogen and stored at -80 °C until sectioning. Cryostat serial sections, 6 μ m thick, were obtained and then fixed in cold acetone for 10 min. After washes in PBS, some sections were incubated overnight with anti-E-selectin murine monoclonal Ab (MoAb) (Bender MedSystem) diluted 1:100 in TBS in a moist chamber at 4 °C. Other sections were incubated with ICAM-1 MoAb (Bender MedSystem) diluted 1:500. The immunoreactivity was revealed using the streptavidin-biotin alkaline phosphatase staining technique (DAKO, LSAB Kit). The immunostained sections were then counterstained in Mayer's haemalum and mounted in an aqueous medium. Negative controls were obtained by substituting the primary MoAb with non-immune mouse serum.

For each group of patients, almost 200 slices were cut from biopsies obtained after the induction of anaesthesia as well as at the end of reperfusion. In addition, for each slice 5 random microscopic fields were examined and the number of the vessels staining positively for E-selectin and ICAM-1 was counted at a magnification of 25X.

Results

Control muscle tissue

After the induction of anaesthesia, the non ischemic muscle tissue coming from Vitamin E-untreated and Vitamin E-treated patients showed all the morphological and ultrastructural features of normal skeletal muscle. The microvascular endothelium showed no staining for E-selectin and sometimes only a weak reactivity for ICAM-1. In particular, 5% of the small blood vessels examined stained positively for ICAM-1 (see Table 1).

Vitamin E untreated I-R muscle

By light microscopy the dominant features of the muscle tissue were an increased adherence of neutro-

Table 1. Molecular and morphological alterations of the ischemic and reperfused human skeletal muscle.

	NEUTROPHIL ACCUMULATION	E-SELECTIN	ICAM-1	TISSUE DAMAGE
Control skeletal muscle	-	-	+	-
Vit. E untreated I-R skeletal muscle	+++	+++	+++	+++
Vit. E-treated I-R skeletal muscle	+	+	+	+

phils to the vessel wall and emigration of these cells from the blood compartment into the surrounding tissue (Fig. 1a). This increase in neutrophil adhesion in response to ischemia and reperfusion, was accompanied by the expression of the endothelial adhesive molecules for circulating neutrophils (see Table 1). In fact, most of the endothelial lining of capillaries and postcapillary venules stained positively for both E-selectin and ICAM-1 (Figs. 2, 3). In particular, 80% of the small blood vessels examined were positive for E-selectin while 60% revealed a strong ICAM-1 staining.

The ultrastructural analysis showed that in many, if

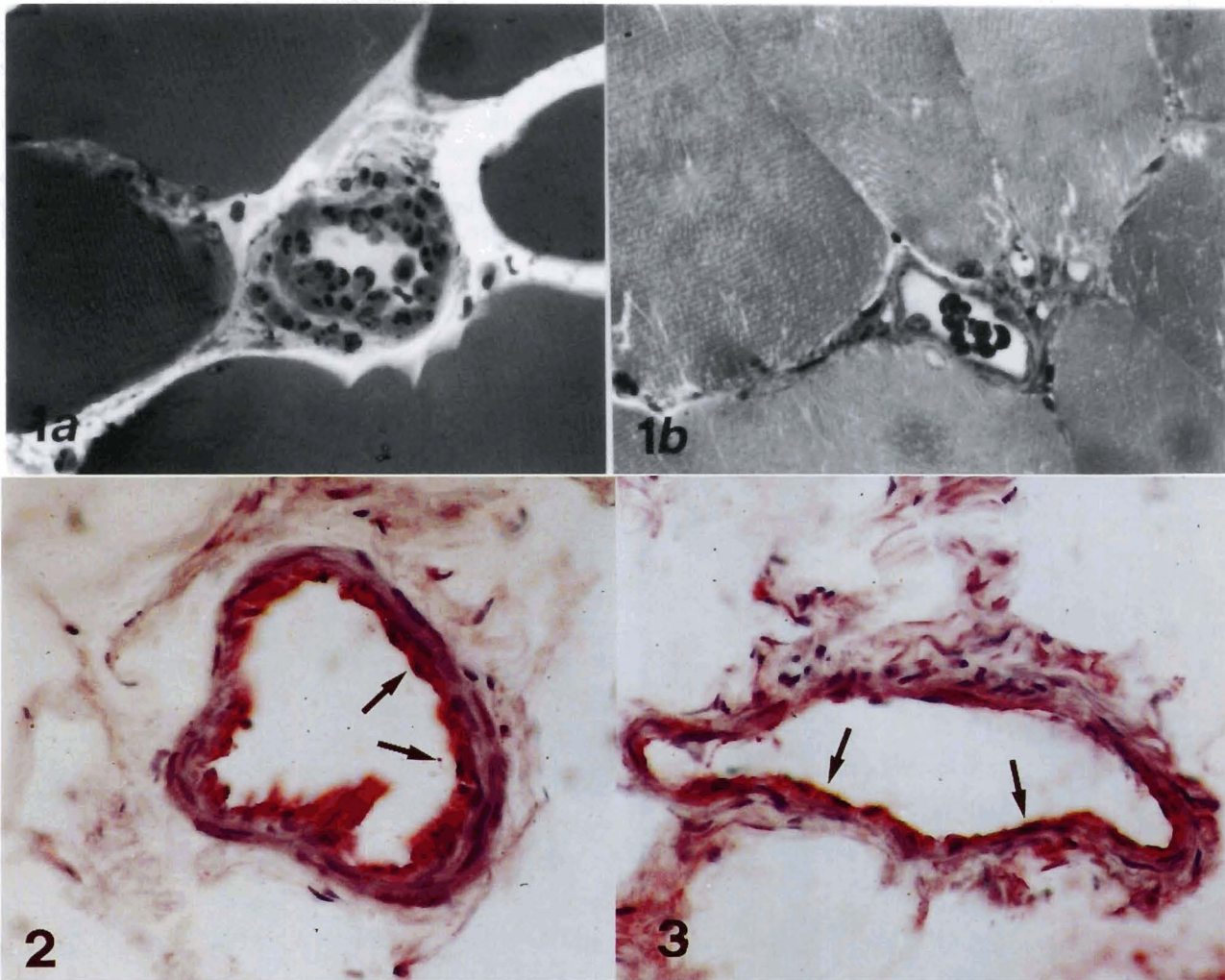


Fig. 1. a. Ischemic and reperfused human skeletal muscle. Numerous neutrophils are visible inside a postcapillary venule and in the surrounding tissue. Semithin section stained with toluidine blue-Na tetraborate. x 130. **b.** Vitamin E-treated ischemic and reperfused human skeletal muscle. No neutrophils are seen in the vicinities of the vascular lining or in the extravascular spaces. Semithin section stained with toluidine blue-Na tetraborate. x 150

Fig. 2. Ischemic and reperfused human skeletal muscle. Immunoalkaline phosphatase staining: a strong positive reaction for E-selectin is visible at the inner vascular wall of a postcapillary venule (arrows). x 250

Fig. 3. Ischemic and reperfused human skeletal muscle. Immunoalkaline phosphatase staining: a marked positivity for ICAM-1 is seen on the endothelial lining of postcapillary venules (arrows). x 750

not all, the muscle fibers there were several signs of damage including intermyofibrillar oedema, loss of glycogen particles, swollen mitochondria with dissolved matrix and disrupted cristae (Fig. 4a). Sometimes mitochondria contained electron-dense amorphous bodies within their matrix (Fig. 6).

Occasionally, severe fiber alterations could also be seen. In fact, in some areas, myofibrils appeared either interspersed with small patches of Z-disc material (Fig. 5a) or disarranged with loss of Z-discs (Fig. 6).

Vitamin E treated-I-R muscle

Light microscopy showed a marked reduction in the neutrophil accumulation in the muscle tissue (see Table 1). Only a few neutrophils were seen either to marginate the venular endothelium or to migrate deeply into the connective stroma among the muscle fibers (Fig. 1b). The endothelium of capillaries and postcapillary venules showed only a little staining for E-selectin or ICAM-1, 20% of the vessels being positive for E-selectin and 10% reactive for ICAM-1.

The ultrastructural investigation showed that most of

the fibers retained a quite normal appearance. In fact, the intermyofibrillar oedema was virtually absent, mitochondria exhibited a normal morphology, apart from localized areas of low amplitude swellings (Fig. 4b). Myofibrils always appeared properly arranged (Fig. 5b) and disruption of Z-discs was never seen.

Discussion

Adhesion of neutrophils to the endothelium is the first step in the localization of circulating leukocytes at the sites of tissue inflammation.

This process requires many different signals or proinflammatory molecules, including activated complement (C5a), leukotriene B4 (LTB4), platelet activator factor (PAF), histamine and oxygen radicals, that direct neutrophils to the inflamed tissue (Kubes, 1993; Ikeda et al., 1994). These molecules, in turn, induce the expression of specific endothelial adhesion proteins (Poher and Cotran, 1991; Bevilacqua, 1993; Smith, 1993; Ikeda et al., 1994) that favour the adhesion of circulating leukocytes to the endothelium and their emigration into the tissue (Luscinskas et al., 1991).

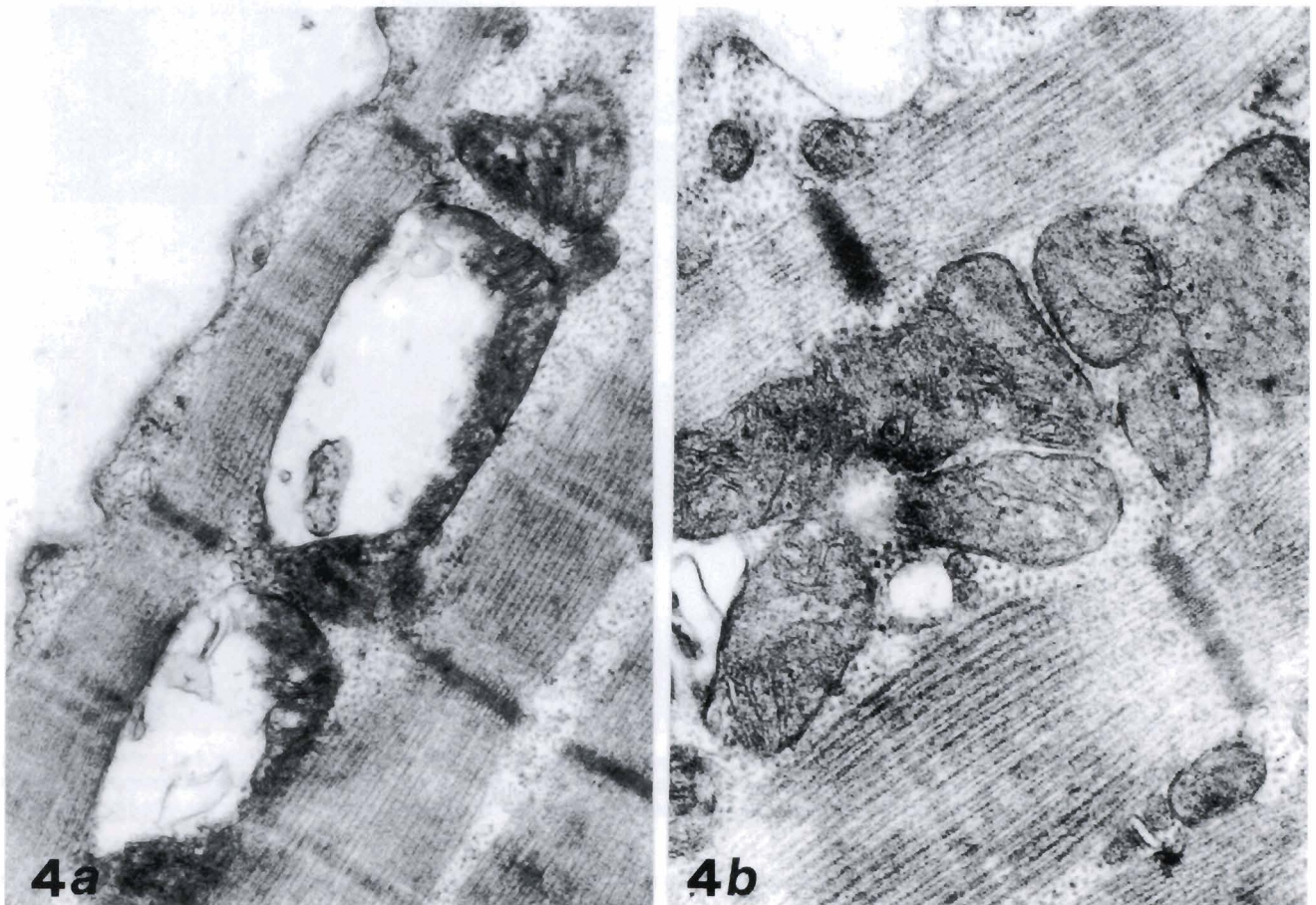


Fig. 4. a. Ischemic and reperfused human skeletal muscle. Swollen mitochondria are seen in the subsarcolemmal region. x 26,000. b. Vitamin E-treated ischemic and reperfused human skeletal muscle. Well preserved mitochondria within the fiber are shown. x 44,000

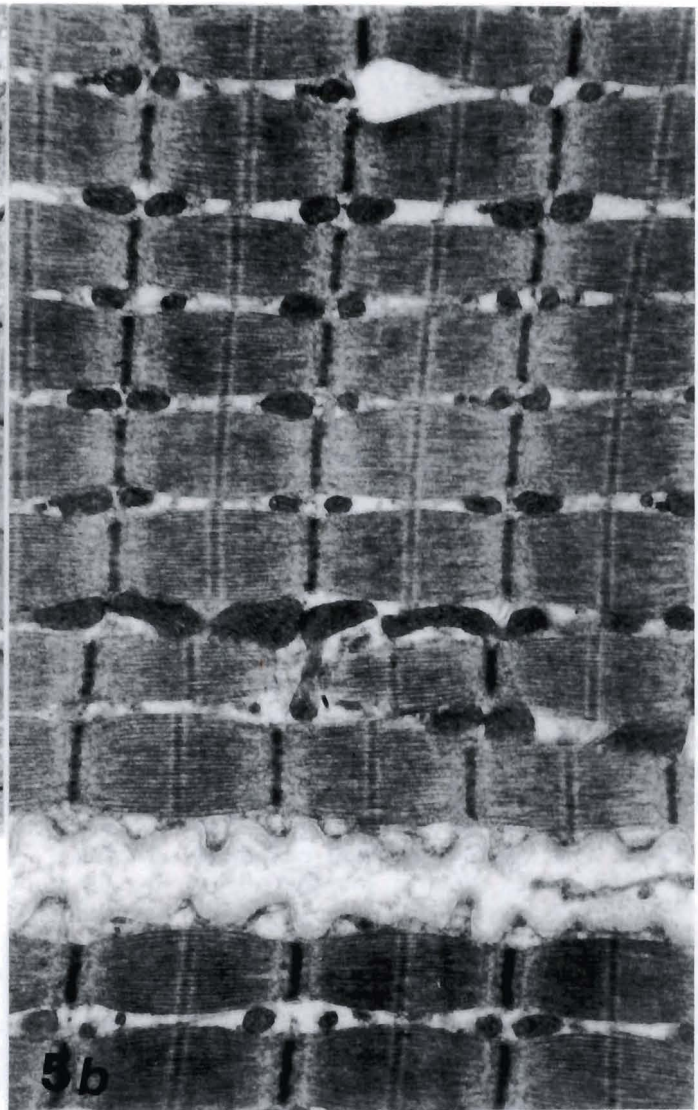



Fig. 5. a. Ischemic and reperfused human skeletal muscle. Patches of Z-disc material (arrows) are visible among the myofibrils which still largely retain their proper orientation. x 9,000. **b.** Vitamin E-treated ischemic and reperfused human skeletal muscle. The muscle tissue shows a quite normal appearance: the myofibrils are properly arranged and no sign of fiber oedema is evident. x 10,000

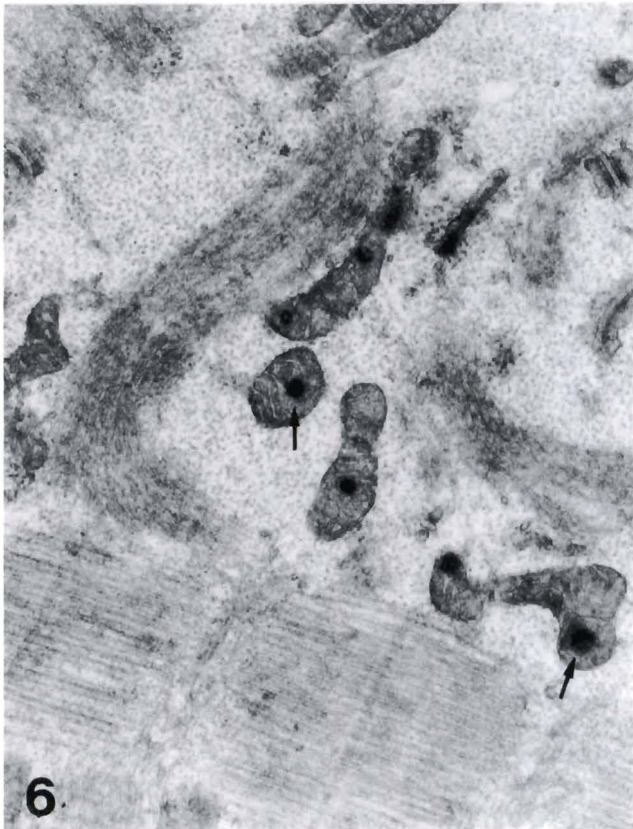


Fig. 6. Ischemic and reperfused human skeletal muscle. Marked degenerative changes consisting of focal disarrangement of the myofibrillar pattern are shown. Note that mitochondria contain abnormal electron-dense amorphous bodies within their matrix (arrows). x 22,000

Events occurring at the interface between circulating neutrophils and the microvascular endothelium are also critical in the pathogenesis of the I-R injury. In fact, there is increasing evidence suggesting that reperfusion of ischemic tissues may be considered as an acute form of inflammation, characterized by activation, adherence and diapedesis of neutrophils and by an increased microvascular permeability (Crawford et al., 1988; Montrucchio et al., 1989; Formigli et al., 1992, 1995; Nose, 1993; Bulkley, 1994). Consistent with this idea, the present findings suggest that the enhanced neutrophil intravascular margination, their diapedesis across the postcapillary venular endothelium and infiltration in the connective tissue surrounding skeletal muscle fibers in response to I-R, are mediated by the expression and/or upregulation of endothelial adhesive molecules, such as E-selectin and ICAM-I. These results extend our previous observations that neutrophil adhesion to the microvasculature is dependent upon E-selectin expression (Formigli et al., 1995) and suggest that multiple endothelial-dependent mechanisms are required for the effective neutrophil extravasation and, therefore, for the occurrence of tissue damage. It should be pointed out that the effect of ischemia and reperfusion on skeletal muscle mitochondria were strictly dependent upon the duration of the ischemic period, with drastic changes occurring only after a long period of ischemia, as previously reported (Bakker et al., 1995).

Most studies so far have stressed the effect of Vitamin E as a major lipophilic compound capable of protecting the cellular membranes against the peroxidative alterations (Massey and Burton, 1989; Farris, 1990; Kappus and Diplock, 1992). Accordingly, Vitamin E is depleted during ischemia and reperfusion (Murphy et al., 1992; Coghlan et al., 1993) and Vitamin E therapy has a preventive role against the free radical-mediated damage associated with ischemia-reperfusion (Petty et al., 1992; Shum-Tim et al., 1992; Abadie et al., 1993; Haramaki et al., 1993; Kotegawa et al., 1993; Mickle and Weisel, 1993; Campo et al., 1994). In particular, we recently showed that Vitamin E is able to decrease the tissue levels of malondialdehyde, a product of lipid peroxidation, in the ischemic and reperfused human skeletal muscle (Novelli et al., 1996). Besides interfering with the propagation of free radical chain reactions within the cell membrane, Vitamin E may also interfere with neutrophil accumulation within ischemic and reperfused tissues. In the present study, we have provided the first experimental evidence that Vitamin E is capable of inhibiting the infiltration of neutrophils in human skeletal muscle upon ischemia-reperfusion. This beneficial effect of Vitamin E appears to be related to the preservation of the endothelial functions, including a decreased expression of E-selectin and ICAM-I. Since ROM are involved in the endothelial-dependent adhesion of neutrophils (Palluy et al., 1992), it is conceivable that the reduced endothelial adhesiveness after treatment with Vitamin E may also be due to a direct antioxidant action of this molecule within the endothelial cell

membrane. It is also possible that Vitamin E, acting as membrane stabilizer, may prevent the accumulation of proinflammatory agents, such as PAF and LTB₄, which are known to be potent leukocyte chemoattractants (Lewis et al., 1988; Kubes et al., 1990a,b). In addition, an effect of Vitamin E on the migratory activity of neutrophils cannot be ruled out. Accordingly, a significant reduction in the neutrophil chemotaxis has been shown in the blood samples of healthy volunteers receiving a dietary supplementation with Vitamin E (Luostarinen et al., 1991). Taken together, the results of this study show that a well coordinated series of events promoting neutrophil/endothelial interactions plays a key role in the pathogenesis of the ischemia-reperfusion syndrome of the human skeletal muscle. Vitamin E seems to prevent reperfusion injury mostly by interfering with the release and expression of those factors responsible for the recruitment of neutrophils within the ischemic and reperfused tissue. Vitamin E treatment might, therefore, be considered a valuable and effective therapeutic tool for protecting skeletal muscle tissue from I-R injury.

Acknowledgements. This work was supported by the grant from CNR N° 94.02943.CT04.

References

- Abadie C., Baouali A.B., Maupoil V. and Rochette L. (1993). An α -tocopherol analogue with antioxidant activity improves myocardial function during ischemia reperfusion in isolated working rat hearts. *Free Rad. Biol. Med.* 15, 209-215.
- Albertine K.H., Weyrich A.S., Ma X.L., Lefer D.J., Becker L.C. and Lefer A.M. (1994). Quantification of neutrophils migration following ischemia and reperfusion in cats and dogs. *J. Leuk. Biol.* 55, 557-566.
- Bakker A., Goosens F., De Bie M., Bernaert I., Van Belle H. and Jacob W. (1995). The effect of ischemia and reperfusion on mitochondrial contact sites in isolated rat hearts. *Histol. Histopathol.* 10, 405-416.
- Bevilacqua M.P. (1993). Endothelial-leukocyte adhesion molecules. *Annu. Rev. Immunol.* 11, 767-804.
- Bevilacqua M.P., Stengelin S., Gimbrone M.A.Jr. and Seed B. (1989). Endothelial leukocyte adhesion molecule 1: an inducible receptor for neutrophils related to complement regulatory proteins and lectins. *Science* 243, 1160-1165.
- Bulkley G.B. (1994). Reactive oxygen metabolites and reperfusion injury: aberrant triggering of reticuloendothelial function. *Lancet* 344, 934-936.
- Campo G.M., Squadrito F. and Ioculano M. (1994). Reduction of myocardial infarct size in rat by IRRFI-048, a selective analogue of vitamin E. *Free Rad. Biol. Med.* 16, 427-435.
- Coghlan J.G., Flitter W.D., Clutton S.M., Ilesley C.D., Rees A. and Slater T.F. (1993). Lipid peroxidation and changes in Vitamin E levels during coronary artery bypass grafting. *J. Thorac. Cardiovasc. Surg.* 106, 268-274.
- Crawford M.H., Grover F.L., Kolb W.P., McMahan C.A. and O'Rourke R.A. (1988). Complement and neutrophil activation in the pathogenesis of ischemic myocardial injury. *Circulation* 78, 1449-1458.

Endothelial-neutrophil interactions in I-R

- Farris M.W. (1990). Oxygen toxicity: unique properties of Vitamin E succinate in hepatocytes. *Free Rad. Biol. Med.* 9, 333-343.
- Formigli L., Domenicini Lombardo L., Adembri C., Brunelleschi S., Ferrari E. and Novelli G.P. (1992). Neutrophils as mediators of human skeletal muscle ischemia-reperfusion syndrome. *Hum. Pathol.* 23, 627-634.
- Formigli L., Ibba Manneschi L., Adembri C., Zecchi Orlandini S., Pratesi C. and Novelli G.P. (1995). Expression of E-selectin in ischemic and reperfused human skeletal muscle. *Ultrastruct. Pathol.* 19, 193-200.
- Grace P.A. (1994). Ischemia-reperfusion injury. *Br. J. Surg.* 81, 637-647.
- Granger D.N., Kviety P. and Perry M.A. (1993). Leukocyte-endothelial cell adhesion induced by ischemia and reperfusion. *Can. J. Physiol. Pharmacol.* 71, 67-75.
- Haramaki N., Packer L., Assadnazar H. and Zimmer G. (1993). Cardiac recovery during post-ischemic reperfusion is improved by combination of vitamin E with dihydrolipic acid. *Biochem. Biophys. Res. Commun.* 196, 1101-1107.
- Horgan M.J., Wright S.D. and Malik A.B. (1990). Antibody against leukocyte integrin (CD18) prevents reperfusion-induced lung vascular injury. *Am. J. Physiol.* 259, L315-L319.
- Ikeda U., Ikeda M., Kano S. and Shimada K. (1994). Neutrophil adherence to rat cardiac myocyte by proinflammatory cytokines. *J. Cardiovasc. Pharmacol.* 23, 647-652.
- Kappus H. and Diplock A.T. (1992). Tolerance and safety of Vitamin E: a toxicological position report. *Free Rad. Biol. Med.* 13, 55-74.
- Kotegawa M., Sugiyama M., Shoji J., Harama K. and Ogura R. (1993). Effect of α -Tocopherol on high energy phosphate levels in rat heart by P-NMR using a langendorff perfusion technique. *J. Mol. Cell Cardiol.* 25, 1067-1074.
- Kubes P. (1993). Polymorphonuclear leukocyte-endothelium interaction: a role for pro-inflammatory and anti-inflammatory molecules. *Can. J. Physiol. Pharmacol.* 71, 88-97.
- Kubes P., Ibbotson G., Russell J., Wallace J.M. and Granger D.N. (1990a). Role of platelet-activating factor in ischemia/reperfusion-induced leukocyte adherence. *Am. J. Physiol.* 259, G300-G305.
- Kubes P., Suzuki M. and Granger D.N. (1990b). Modulation of PAF-induced leukocyte adherence and increased microvascular permeability. *Am. J. Physiol.* 259, G859-G864.
- Kukielka G.L., Hawkins K.H., Michael L., Manning A.M., Youker K., Lane C., Entman M.L., Smith C.V. and Anderson D.C. (1993). Regulation of intercellular adhesion molecule1 (ICAM-1) in ischemic and reperfused canine myocardium. *J. Clin. Invest.* 92, 1504-1516.
- Lefer A.M., Ma X.L., Weyrich A. and Lefer D.J. (1993). Endothelial dysfunction and neutrophil adherence as critical events in the development of reperfusion injury. *Agent. Action. Suppl.* 41P, 127-135.
- Lewis M.S., Whatley R.E., Cain P., Mc Intyre T.M., Prescott S.M. and Zimmerman G.A. (1988). Hydrogen peroxide stimulates the synthesis of platelet-activating factor by endothelium and induces endothelial cell-dependent neutrophil adhesion. *J. Clin. Invest.* 82, 2045-2055.
- Luostarinen R., Siegbahn A. and Saldeen T. (1991). Effects of dietary supplementation with vitamin E on human neutrophil chemotaxis and generation of LTB₄. *Ups. J. Med. Sci.* 96, 103-111.
- Luscinskas F.W., Cybulsky M.I., Kiely J.M., Peckins C.S., Davis U.M. and Gimbrone M.A. (1991). Cytokine-activated human endothelial monolayers support enhanced neutrophil transmigration via a mechanism involving both endothelial-leukocyte adhesion molecule-1 and intercellular adhesion molecule-1. *J. Immunol.* 146, 1617-1625.
- Massey K.D. and Burton K.P. (1989). α -Tocopherol attenuates myocardial membrane-related alterations resulting from ischemia and reperfusion. *Am. J. Physiol.* 256, H1192-H1199.
- Mickle D.A. and Weisel R.D. (1993). Future directions of Vitamin E and its analogues in minimizing myocardial ischemia-reperfusion injury. *Can. J. Cardiol.* 9, 89-93.
- Montrucchio G., Alloati G., Tetta C., Deluca R., Sanders R.N., Emanuelli G. and Camussi G. (1989). Release of platelet activator factor from ischemic-reperfused rabbit heart. *Am. J. Physiol.* 256, H1236-H1246.
- Murphy M.E., Kolvenbach R., Aleksis M., Hansen R. and Sies H. (1992). Antioxidant depletion in aortic crossclamping ischemia: increase of the plasma α -tocopherol quinone/ α -tocopherol ratio. *Free Rad. Biol. Med.* 13, 95-100.
- Nose P.S. (1993). Cytokines and reperfusion injury. *J. Card. Surg.* 8, 305-308.
- Novelli G.P., Adembri C., Brunelleschi S., Livi P., Rossi R. and Pratesi C. (1990). Oxygen radicals production during ischemia-reperfusion of the lower limbs in man: inhibitory effects of L-carnitine. *Curr. Therap. Res.* 48, 903-911.
- Novelli G.P., Adembri C., Gandini E., Zecchi Orlandini S., Papucci L., Formigli L., Ibba Manneschi L., Quattrone A., Patresi C. and Capaccioli S. (1996). Vitamin E protects human skeletal muscle from damage during surgical ischemia-reperfusion. *Am. J. Surg.* (in press).
- Palluy O., Morliere L., Gris J.C., Bonne C. and Modat G. (1992). Hypoxia/reoxygenation stimulates endothelium to promote neutrophil adhesion. *Free Rad. Biol. Med.* 13, 21-30.
- Petty M.A., Grisar G.M. and De Jong W. (1992). Protective effects of an alpha-tocopherol analogue against myocardial reperfusion injury in rats. *Eur. J. Pharmacol.* 210, 85-90.
- Pober J.S. and Cotran R.S. (1991). What can be learned from the expression of endothelial adhesion molecules in tissues? *Lab. Invest.* 64, 301-305.
- Shen L. and Verrier E.D. (1994). Expression of E-selectin on coronary endothelium after myocardial ischemia and reperfusion. *J. Card. Surg.* 9, 437-441.
- Shum-Tim D., Tchervenkov C.I. and Chiu R.C.J. (1992). Oral vitamin E prophylaxis in the protection of newborn myocardium from global ischemia. *Surgery* 112, 441-450.
- Siminiak T. and Ozawa T. (1993). Neutrophil-mediated myocardial injury. *Int. J. Biol.* 25, 147-156.
- Smith C.W. (1993). Endothelial adhesion molecules and their role in inflammation. *Can. J. Physiol. Pharmacol.* 71, 76-87.
- Walden D.L., McCutchan H.J., Enquist E.G., Schwappach J.R., Shanley P.F., Reiss O.K., Terada L.S., Leff J.A. and Repine J.E. (1990). Neutrophils accumulate and contribute to skeletal muscle dysfunction after ischemia-reperfusion. *Am. J. Physiol.* 258, H1809-H1812.
- Zimmerman B.J., Grisham M.B. and Granger D.N. (1990). Role of oxidants in ischemia/reperfusion-induced granulocyte infiltration. *Am. J. Physiol.* 258, G185-G190.