

Invited Review

Eosinophils and human cancer

M. Samoszuk

Pathology Department, University of California, Irvine, CA, USA

Summary. Eosinophils are rare granulocytes that are normally associated with allergic diseases or responses to various parasitic infections. Many types of human cancer, however, are also associated with extensive eosinophilia, either within the tumor itself, or in the peripheral blood, or in both locations. Special techniques such as autofluorescence or immunohistochemistry are sometimes needed to detect the presence of intact and degranulating eosinophils within the tumors. With the help of these techniques, extensive eosinophilia is most often seen in hematologic tumors such as Hodgkin's disease and certain lymphomas; however, many other types of cancer such as colon, cervix, lung, breast, and ovary also contain eosinophilia if diligently sought. Although the presence or absence of eosinophilia within these tumors does not appear to have a major influence on the prognosis of the patient, eosinophils may play an important role in the host interaction with the tumor, perhaps by promoting angiogenesis and connective tissue formation adjacent to the cancer. In addition, tumor-related eosinophilia provides some interesting clues into tumor biology, particularly with regard to production of cytokines by the tumor cells.

Key words: Eosinophils, Peroxidase, Carcinoma, Angiogenesis, Lymphoma

Introduction

Eosinophils are a rare type of granulocyte, comprising fewer than 1 in 300,000 blood cells in normal individuals. They are distinguished by their tinctorial properties (bright red staining with acid aniline dyes) and abundant cytoplasmic granules that contain potent compounds which are highly toxic *in vitro* to helminthic and protozoan parasites, bacteria, tumor cells, and host cells (Butterworth et al., 1979; Jong and Klebanoff, 1980; Jong et al., 1980, 1981; Noguiera et al., 1982; Gleich and Adolphson, 1986; Hamada and Greene, 1987; Weller, 1991; Makino and Fukuda, 1993).

Offprint requests to: Dr. Michael Samoszuk, M.D., Pathology Department, 440 Medical Sciences D-ZC4800, University of California, Irvine, CA 92697-4800, USA

Despite their rarity, eosinophils are involved in the pathogenesis of many important diseases, including allergies (hay fever, asthma), allograft rejections, parasitic infections, celiac disease, sclerosing cholangitis, Loeffler's syndrome, and retroperitoneal fibrosis (Spry, 1988). This review will focus on the many types of human cancers (Table 1) that are also associated with extensive eosinophilia, either in the tumor itself or in the peripheral blood.

Methods for detecting eosinophils in tumors

Intact eosinophils can usually be readily detected in tissue sections of tumors that are stained with hematoxylin and eosin or phloxine B (Fig. 1). It should be noted, however, that tissue eosinophils often assume an ameboid or "medusa" cell configuration, especially in fibrous tissue, thereby making their recognition in routinely stained sections very difficult (Hanker et al., 1980, 1981; Samoszuk et al., 1996a,b).

Giemsa staining usually makes the intensely red granules of eosinophils considerably easier to see within tumor tissue (Fig. 2). Another powerful tool for visualizing eosinophils in tumors exploits the natural autofluorescence of eosinophil granules (Samoszuk and Espinoza, 1987; Samoszuk and Ramzi, 1993). This technique is especially useful in decalcified bone marrow biopsies where there is likely to be extensive eosinophilic background material that makes it difficult to recognize eosinophils by conventional staining techniques. Using green light epifluorescence microscopy of deparaffinized bone marrow sections, we have previously demonstrated that there is occult eosinophil degranulation in a significant proportion of myeloproliferative disorders (Samoszuk and Espinoza, 1987).

Finally, immunohistochemistry with monoclonal antibodies can be used on cryostat sections to detect eosinophil granule substances such as eosinophil peroxidase deposited within Hodgkin's disease, breast cancer (Fig. 3), and ovarian cancer (Samoszuk et al., 1986, 1987, 1996a,b). This technique has the advantage that it can recognize intact eosinophils as well as the "footprints" of eosinophils that have previously undergone degranulation in blood vessels adjacent to the

tumor (Fig. 4). Because eosinophils contain abundant endogenous peroxidase, however, it is important to use an enzymatic label such as glucose oxidase for the immunohistochemical detection step instead of horseradish peroxidase.

Eosinophils in hematologic tumors

Hodgkin's disease of the nodular sclerosis or mixed cellularity subtypes is associated with eosinophilia in more than 80% of cases (Samoszuk et al., 1986, 1987;

Samoszuk and Ramzi, 1993). In addition, non-Hodgkin's lymphomas of T-cell origin are frequently accompanied by eosinophilia within the tumor and in the peripheral blood, perhaps due to the production of interleukin-5 (a potent stimulator of eosinophils) by the cells within the tumor (Samoszuk et al., 1993b). The presence of abundant EPO within these tumors has been successfully exploited as a target for radioimmunodetection of the tumors *in vivo*, by using an indium-111-labeled monoclonal antibody directed against EPO (Samoszuk et al., 1993a).

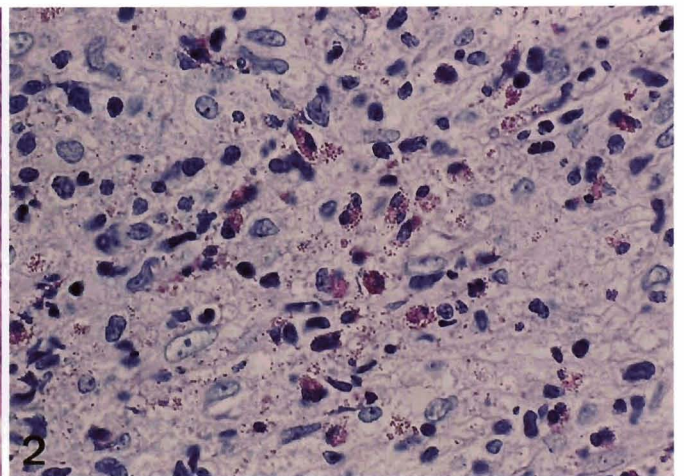
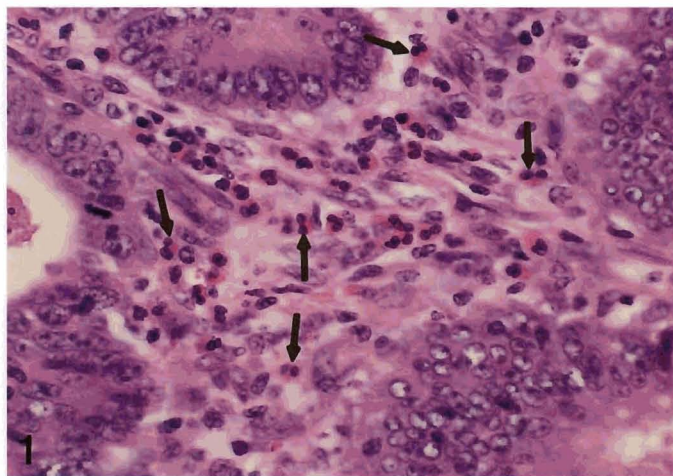


Fig. 1. Endometrial carcinoma with extensive eosinophilia in the fibrovascular tissue between tumor cells. The intact eosinophils (some of which are denoted by *arrows*) are readily visualized by their bright red cytoplasmic staining and characteristic bilobed nuclei. Hematoxylin and eosin stain. x 250

Fig. 2. Hodgkin's disease stained by Giemsa technique. Intact and degranulating eosinophils are especially easy to recognize, and free eosinophil granules are readily evident among the tumor cells. Giemsa stain. x 400

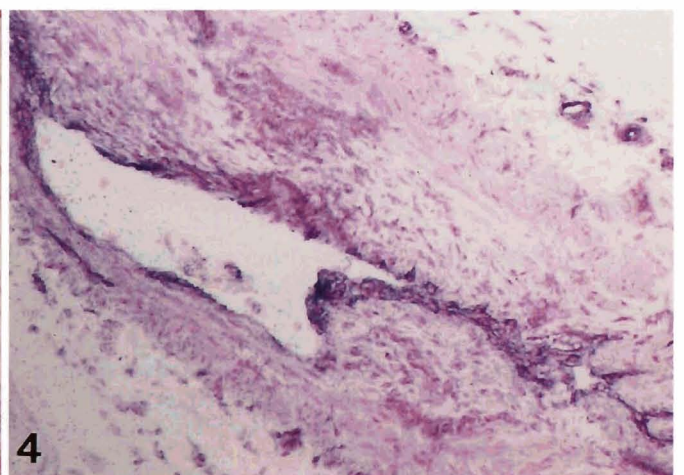
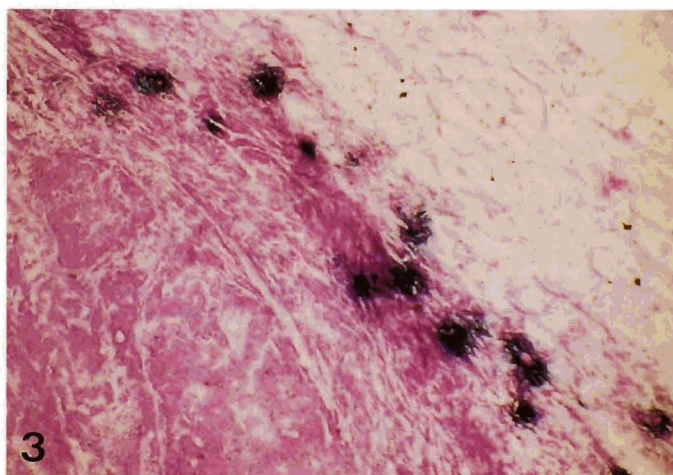


Fig. 3. Breast cancer section immunostained for eosinophil peroxidase (EPO) with EOS monoclonal antibody. The EPO (intensely blue staining) is concentrated primarily at the edge of the tumor, near the interface with fatty connective tissue. Vectastain ABC-Glucose Oxidase Kit (Vector Laboratories, Burlingame, CA) with nitroblue tetrazolium substrate and nuclear fast red counterstain. x 250

Fig. 4. EPO (blue stain) deposited on the lumen of a blood vessel adjacent to Hodgkin's disease. Immunohistochemistry with a monoclonal antibody (EOS) specific for human EPO can detect evidence of occult eosinophil degranulation even in the absence of intact eosinophils. Same conditions as in Fig. 3. x 250

Non-Hodgkin's lymphomas of B-cell lineage occasionally also have eosinophilia, but this occurs far less frequently than in T-cell lymphomas (Ramon et al., 1994). A case of diffuse large B-cell lymphoma with peripheral blood eosinophilia has been described, but the cause of the eosinophilia could not be determined (Watanabe et al., 1989). AIDS-related lymphomas of small non-cleaved cell type with extensive eosinophilia have also been described, and these tumors have been shown to contain Epstein-Barr virus DNA as well as mRNA coding for interleukin-5 (Samoszuk et al., 1992). Plasma cell myeloma is only rarely associated with eosinophilia. A case report has described the presence of interleukin-3 but not interleukin-5 in the pre-treatment serum of one such patient (Glantz et al., 1995).

Certain types of acute and chronic leukemia are also accompanied by substantial eosinophilia. The most important of these types to recognize clinically is acute myelomonocytic leukemia with abnormal eosinophils (M4Eo) by the French-American-British Cooperative Group) in which chromosomal inv(16) or t(16;16) portends a favorable prognosis (Larson et al., 1986). Adult T-cell leukemia/lymphoma is also associated with eosinophilia in up to 21% of cases, and the peripheral blood eosinophil counts in these patients closely parallel the course of the disease and the degree of lymphadenopathy (Vukelja et al., 1988; Murata et al., 1992). Hybrid eosinophilic-basophilic granulocytes have been identified in chronic granulocytic leukemia by using immunocytochemical staining for eosinophil-specific, cyanide-resistant peroxidase (Weil and Hrisinko, 1987).

Table 1. List of human tumors that have been associated with eosinophilia

Hematologic Tumors

- Acute myelogenous leukemia
- Chronic myelogenous leukemia
- Acute lymphoblastic leukemia, especially of T-cell types
- Acute myelomonocytic leukemia
- Hodgkin's disease
- B-cell lymphomas
- T-cell lymphomas
- Plasma cell myeloma
- AIDS-related B-cell lymphomas
- Mycosis fungoides
- Nodal angiolymphoid hyperplasia

Non-Hematologic Tumors

- Colon
- Stomach
- Pancreas
- Uterine cervix
- Lung
- Breast
- Ovary
- Endometrium
- Head and neck squamous cell carcinomas
- Thyroid
- Various tumors after treatment with interleukin-2

Eosinophils in carcinomas

In human colonic carcinomas, a relationship has been reported between the concentration and microanatomic location of eosinophils, the metastases of the tumors, and the survival of patients (Pretlow et al., 1984; McGinnis et al., 1989). Minute early gastric cancer has also been shown to contain significant eosinophilic infiltration in up to 40% of cases (Caruso et al., 1993). Although the degree of eosinophilia in the gastric tumors was not correlated to size, histologic type, or necrosis, some tumor cells in intimate contact with degranulating eosinophils were noted to show focal cytopathic changes.

In an interesting case report, Dvorak et al. (1990) described a patient with a solid papillary epithelial cancer of the pancreas in which the tumor cells contained Charcot-Leyden crystal protein (lysophospholipase), a material that has traditionally been associated with eosinophil-rich disorders. The tumor stroma of this patient was then found to contain numerous damaged and partially or completely degranulated eosinophils. Another case report has described a patient with a large cell carcinoma of the lung who developed eosinophilia that was attributed to production of a tumor-derived eosinophilopoietic factor with a molecular mass of 45 kD (Slungaard et al., 1983).

Our laboratory has recently been studying the involvement of eosinophils in various gynecologic cancers. In one report, we showed that up to 88% of the human breast cancers that we studied had immunohistochemical evidence of histologically occult eosinophil degranulation around or within the tumors (Samoszuk et al., 1996b). A subsequent study of ovarian and endometrial cancers showed that 12 out of 15 cases of ovarian cancer and 16 out of 16 endometrial cancers contained abundant EPO deposits on the vascular endothelial cells and connective tissue stroma within and around the tumors (Samoszuk et al., 1996a). These findings imply that eosinophil degranulation is a significant and previously unappreciated component of the interaction between these cancers and the host. Moreover, the abundant and highly specific nature of the EPO deposits near and within the microvessels of these cancers suggests that eosinophil degranulation is a new marker for tumor blood vessels that potentially could be exploited for therapeutic purposes.

Eosinophilia within various cancers of the head and neck has prompted numerous studies, beginning with a case report of blood hypereosinophilia in association with an anaplastic, giant cell carcinoma of the thyroid (Van Crombrugge et al., 1983). A study of biopsy specimens from 422 consecutive primary nasopharyngeal carcinomas revealed tumor-associated tissue eosinophilia in 26% of the tumors and in 38% of the metastatic tumors within lymph nodes (Looi, 1987). A subsequent study confirmed the incidence of eosinophilia in 32% of patients with nasopharyngeal cancer but failed to show any significant association between the

eosinophilia and local recurrence, distant metastases, or survival (Leighton et al., 1996). In advanced laryngeal squamous cell carcinoma, eosinophilia has been found in 22% of cases, but once again there was no detectable relationship between the tumor-associated eosinophilia and the overall or disease-free survival rates of the patients (Sassler et al., 1995).

At this time, it appears that most other histologic types of cancer only rarely have significant degrees of tumor infiltration by eosinophils. A notable exception, however, is in miscellaneous solid tumors in patients who have been treated with interleukin-2. There have been consistent reports that therapeutic interleukin-2 administration results in hypereosinophilia and tumor infiltration by eosinophils in patients with renal cell carcinoma, adenocarcinomas, bladder cancer, and melanomas (Cohen et al., 1987; Arinaga et al., 1992; Huland and Huland, 1992; Rivoltini et al., 1993; Bovo et al., 1995). The mechanism for this finding remains unclear but may be related to the induction of interleukin-5 production by the IL-2-activated cells.

Prognostic significance of eosinophils in cancer

As alluded to in the previous section of this review, the presence or absence of eosinophils within tumors generally does not appear to have a major or consistent influence on the prognosis of the patient. This conclusion was first reached by Pastrnak and Jansa (1983) after studying eosinophilia in oral, gastric, breast, and cervical carcinomas. In a subsequent confirmatory study, Ayhan et al. (1992) showed that eosinophilic reaction to stage I cancer of the uterine cervix was not a significant predictor of pelvic lymph node metastases or 5-year survival. Studies in mice bearing interleukin-5 gene-transfected tumors have also demonstrated that the presence of significant eosinophilia within tumors did not, by itself, induce a protective host immune response against the tumor (Kruger-Krasagakes et al., 1993).

There are, however, some studies that suggest that tumor associated tissue eosinophilia may indeed have a modest beneficial effect on the survival of some cancer patients. For example, Bethwaite et al. (1993) showed that tissue associated eosinophilia in 81 women with stage IB cervical carcinoma was associated with statistically improved survival. Dalal et al. (1992) demonstrated that local and systemic eosinophilia in 49 patients with carcinoma of the uterine cervix predicted a favorable response to radiation treatment, and Goldsmith et al. (1992) showed that eosinophilia was a favorable prognostic indicator in a study of 120 patients with head and neck cancers.

Biologic significance of eosinophils in cancer

The presence of eosinophils within a wide variety of human cancers immediately raises two questions: Why are they present and what are they doing to the tumor? With regard to the first question, a number of factors

have been shown to be potent eosinophil chemoattractants *in vitro* and *in vivo*, including platelet activating factor, C5a, RANTES, MCP-2, interleukin-5, eotaxin, and IgE. Of these factors, only IgE and interleukin-5 have to date been detected in lymphomas that are infiltrated by eosinophils (Samoszuk and Nansen, 1990; Samoszuk, 1992; Samoszuk et al., 1993b). Unidentified eosinophil colony-stimulating factors, however, have been detected in the blood and tumors of patients with medullary carcinoma of the thyroid (Balducci et al., 1989), melanoma, and adenocarcinoma of the biliary tree (Stefanini et al., 1991). It remains unclear if the tumor cells themselves or the host inflammatory cells are responsible for the production of these eosinophilotactic compounds.

There is also clinical and laboratory evidence that a type 2 helper T-cell response and interleukin-4 may account for hypereosinophilia in some conditions, including tumors (Cogan et al., 1994; Pericle et al., 1994). This raises the intriguing possibility that the host immune response to the tumor results in the recruitment of eosinophils to the site. Very little work has been done in this area, and it is clear that further investigation is needed.

The functional role of eosinophils in human cancers remains even more obscure than the nature of the eosinophilotactic compounds. There was a provocative earlier report that eosinophils are responsible for an anti-tumor effect in mice bearing tumors that were transfected to produce interleukin-4 (Tepper et al., 1992). As previously discussed in this review, however, the anti-tumor effect of eosinophils in humans is modest at best, particularly in view of the many examples of aggressive cancers that continue to proliferate and spread even though they are infiltrated by significant numbers of eosinophils. Thus, it appears somewhat unlikely that eosinophils play a significant role in the host defense against cancer.

A more likely possibility at this time is that eosinophils are part of the host connective tissue response to the tissue damage created by the growing tumor. The involvement of eosinophils in connective tissue remodeling and collagen formation was first proposed by Bassett in 1962 and then further detailed by the same investigator in subsequent papers (Bassett et al., 1977; Bassett, 1983). Since then, our laboratory has repeatedly noted the remarkable association between eosinophils, granulation tissue, and collagen fibrosis in human tumors (Samoszuk et al., 1987, 1996a,b).

Laboratory studies seem to provide a possible explanation for this association. In 1987, Pincus et al. demonstrated that eosinophils stimulate DNA synthesis in fibroblasts. Wong et al. (1991) then showed that eosinophils express transforming growth factor β 1, which is a multifunctional cytokine known to exert potent effects on the extracellular matrix, including collagen fibrosis. In a later paper, Ghiabi et al. (1992) showed that eosinophils infiltrating oral cancers in hamsters expressed transforming growth factor- α , a

multifunctional cytokine that can promote angiogenesis. In aggregate, these findings strongly suggest that eosinophils may be involved in the remodeling of the host connective tissue and blood vessels in response to the growing tumor. If this hypothesis is correct, then eosinophils and their granule compounds could some day become a target for therapies designed to restrict the growth of new blood vessels and connective tissue framework in some human cancers.

Acknowledgements. This publication was supported by grants #1R01CA 69079 and #1R41CA 68795 from the National Cancer Institute. Its contents are solely the responsibility of the authors and do not necessarily represent the official views of the National Cancer Institute

References

- Arinaga S., Karimine N., Takamuku K., Nanbara S., Inoue H., Abe R., Watanabe D., Matsuoka H., Ueo H. and Akiyoshi T. (1992). Correlation of eosinophilia with clinical response in patients with advanced carcinoma treated with low-dose recombinant interleukin-2 and mitomycin C. *Cancer Immunol. Immunother.* 35, 246-50.
- Ayhan A., Altintas A., Tuncer Z.S., Kucukali T., Yuca K. (1992). Prognostic value of mitotic activity, eosinophilic and inflammatory reaction in stage I cancer of the uterine cervix. *Eur. J. Surg. Oncol.* 18, 264-266.
- Balducci L., Chapman S.W., Little D.D. and Hardy C.L. (1989). Paraneoplastic eosinophilia: Report of a case with *in vitro* studies of hemopoiesis. *Cancer* 64, 2250-2253.
- Bassett E.G. (1962). Infiltration of eosinophils into the modified connective tissue of oestrous and pregnant animals. *Nature* 194, 1259-1261.
- Bassett E.G. (1983). Eosinophils and connective tissue catabolism. *Biochem. J. Lett.* 213, 769-770.
- Bassett E.G., Baker J.R. and de Souza P. (1977). A light microscopical study of healing incised dermal wounds in rats, with special reference to eosinophil leucocytes and to the collagenous fibres of the periwound areas. *Br. J. Exp. Pathol.* 58, 581-605.
- Bethwaite P.B., Holloway L.J., Yeong M.L. and Thornton A. (1993). Effect of tumour associated tissue eosinophilia on survival of women with stage IB carcinoma of the uterine cervix. *J. Clin. Pathol.* 46, 1016-1020.
- Bovo G., Brivio F., Brenna A., Fumagalli L., Perego P., Brivio O., Uggeri F., Lavorato F., Bratina G. (1995). Pre-operative interleukin-2 immunotherapy induces eosinophilic infiltration in colorectal neoplastic stroma. *Pathologica* 87, 135-138.
- Butterworth A.E., Wassom D.L., Gleich G.J., Loegering D.A. and David J.R. (1979). Damage to schistosomula of *Schistosoma mansoni* induced directly by eosinophil major basic protein. *J. Immunol.* 122, 221-229.
- Caruso R.A., Giuffre G. and Infrerera C. (1993). Minute and small early gastric carcinoma with special reference to eosinophil infiltration. *Histol. Histopathol.* 8, 155-166.
- Cogan E., Schandené L., Crusiaux A., Cochaux P., Velu T. and Goldman M. (1994). Brief report: Clonal proliferation of type 2 helper cells in a man with the hypereosinophilic syndrome. *N. Engl. J. Med.* 350, 535-538.
- Cohen P.J., Lotze M.T., Roberts J.R., Rosenberg S.A. and Jaffe E.S. (1987). The immunopathology of sequential tumor biopsies in patients treated with interleukin-2. *Am. J. Pathol.* 129, 208-216.
- Dalal B.I., Das K.C., Dutta T.K. and Malakar K. (1992). Local and systemic eosinophilia in patients with carcinoma of the uterine cervix undergoing therapy: correlation with radiation response. *Clin. Oncol.* 4, 18-21.
- Dvorak A.M., Letourneau L., Weller P.F. and Ackerman S.J. (1990). Ultrastructural localization of Charcot-Leyden crystal protein (lysophospholipase) to intracytoplasmic crystals in tumor cells of primary solid and papillary epithelial neoplasm of the pancreas. *Lab. Invest.* 62, 608-615.
- Ghiabi M., Gallagher G.T. and Wong D.T. (1992). Eosinophils, tissue eosinophilia, and eosinophil-derived transforming growth factor alpha in hamster oral carcinogenesis. *Cancer Res.* 52, 389-393.
- Glantz L., Rintels P., Samoszuk M. and Medeiros L.J. (1995). Plasma cell myeloma associated with eosinophilia. *Am. J. Clin. Pathol.* 103, 583-587.
- Gleich G.J. and Adolphson C.R. (1986). The eosinophilic leukocyte: structure and function. *Adv. Immunol.* 39, 117-253.
- Goldsmith M.M., Belchis D.A., Cresson D.H., Merritt W.D. 3d and Askin F.B. (1992). The importance of the eosinophil in head and neck cancer. *Otolaryngol. Head Neck Surg.* 106, 27-33.
- Hamada A. and Greene B.M. (1987). C1q enhancement of IgG-dependent eosinophil-mediated killing of schistosomula *in vitro*. *J. Immunol.* 138, 1240-1245.
- Hanker J.S., Chandross R.J. and Ottolenghi A. (1980). Medusa cells: the morphology and cytochemistry of common amoeboid variants of eosinophils. *Histochem. J.* 12, 701-715.
- Hanker J.S., Chandross R.J., Solic J.G., Weatherly N.F., Laszlo J., Moore J.O. and Ottolenghi A. (1981). Medusa cells: cytostructure and cytochemistry of amoeboid eosinophils with pseudopod-like processes. *Histochem. J.* 13, 905-919.
- Huland E. and Huland H. (1992). Tumor-associated eosinophilia in interleukin-2-treated patients: evidence of toxic eosinophil degranulation on bladder cancer cells. *J. Cancer Res. Clin. Oncol.* 118, 463-467.
- Jong E.C. and Klebanoff S.J. (1980). Eosinophil-mediated mammalian tumor cell cytotoxicity: role of the peroxidase system. *J. Immunol.* 124, 1945-1953.
- Jong E.C., Henderson W.R. and Klebanoff S.J. (1980). Bactericidal activity of eosinophil peroxidase. *J. Immunol.* 124, 1378-1382.
- Jong E.C., Mahmoud A.A.F. and Klebanoff S.J. (1981). Peroxidase-mediated toxicity to schistosomula of *Schistosoma mansoni*. *J. Immunol.* 126, 468-471.
- Krüger-Krasagakes S., Li W., Richter G., Diamantstein T. and Blankenstein T. (1993). Eosinophils infiltrating interleukin-5 gene-transfected tumors do not suppress tumor growth. *Eur. J. Immunol.* 23, 992-995.
- Larson R.A., Williams S.F., Le Beau M.M., Bitter M.A., Wardiman J.W. and Rowley J.D. (1986). Acute myelomonocytic leukemia with abnormal eosinophils and inv(16) or t(16;16) has a favorable prognosis. *Blood* 68, 1242-1249.
- Leighton S.E.J., Teo J.G.C., Leung S.F., Cheung A.Y., Lee J.C.K. and van Hasselt C.A. (1996). Prevalence and prognostic significance of tumor-associated tissue eosinophilia in nasopharyngeal carcinoma. *Cancer* 77, 436-440.
- Looi L. (1987). Tumor-associated tissue eosinophilia in nasopharyngeal carcinoma. *Cancer* 59, 466-470.

Eosinophils and cancer

- Makino S. and Fukuda T. (1993). Eosinophils: biological and clinical aspects. Boca Raton. CRC Press.
- McGinnis M.C., Bradley Jr. E.L., Pretlow T.P., Ortiz-Reyes R., Bowden C.J., Stellato T.A. and Pretlow II T.G. (1989). Correlation of stromal cells by morphometric analysis with metastatic behavior of human colonic carcinoma. *Cancer Res.* 49, 5989-5993.
- Murata K., Yamada Y., Kamihira S., Atogami S., Tsukasaki K., Momita S., Amagasaki T., Sadamori N., Tomonaga M., Kinoshita K. and Ichimaru M. (1992). Frequency of eosinophilia in adult T-cell leukemia/lymphoma. *Cancer* 69, 966-971.
- Nogueira N.M., Klebanoff S.J. and Cohn Z.A. (1982). *T. cruzi*: sensitization to macrophage killing by eosinophil peroxidase. *J. Immunol.* 128, 1705-1708.
- Pastrnak A. and Jansa P. (1983). Local eosinophilia in stroma of tumors related to prognosis. *Neoplasma* 31, 323-326.
- Pericle F., Giovarelli M., Colombo M.P., Ferrari G., Musiani P., Modesti A., Cavallo F., Di Pierro F., Novelli F. and Forni G. (1994). An efficient Th2-type memory follows CD8⁺ lymphocyte-driven and eosinophil-mediated rejection of a spontaneous mouse mammary adenocarcinoma engineered to release IL-4. *J. Immunol.* 153, 5659-5673.
- Pincus S.H., Ramesh K.S. and Wyler D.J. (1987). Eosinophils stimulate fibroblast DNA synthesis. *Blood* 70, 572-574.
- Pretlow T.P., Boohaker E.A., Pitts A.M., MacFadyen A.J., Bradley Jr. E.L. and Pretlow II T.G. (1984). Heterogeneity and sub-compartmentalization in the distribution of eosinophils in human colonic carcinomas. *Am. J. Pathol.* 116, 207-213.
- Ramon L.N., Medeiros J., Kingman D.W., Osorno-Zarate A., Nguyen V., Samoszuk M. and Jaffe E.S. (1994). Malignant lymphomas of B-cell lineage with marked tissue eosinophilia. A report of 5 cases. *Am. J. Surg. Pathol.* 18, 347-355.
- Rivoltini L., Viggiano V., Spinazze S., Santoro A., Colombo M.P., Takatsu K. and Parmiani G. (1993). In vitro anti-tumor activity of eosinophils from cancer patients treated with subcutaneous administration of interleukin 2. Role of interleukin 5. *Int. J. Cancer* 54, 8-15.
- Samoszuk M. (1992). Immunoglobulin E in Reed-Sternberg cells of Hodgkin's disease with eosinophilia. *Blood* 79, 1518-1522.
- Samoszuk M. and Espinoza F. (1987). Deposition of autofluorescent eosinophil granules in pathologic bone marrow biopsies. *Blood* 70, 597-599.
- Samoszuk M. and Nansen L. (1990). Detection of interleukin-5 mRNA in Reed-Sternberg cells of Hodgkin's disease with eosinophilia. *Blood* 75, 13-16.
- Samoszuk M.K. and Nguyen V. (1996). *In vitro* and *in vivo* interactions of D-penicillamine with tumors. *Anticancer Res.* 16, 1219-1224.
- Samoszuk M. and Ramzi E. (1993). IgE, Reed-Sternberg cells, and eosinophilia in Hodgkin's disease. *Leukemia and Lymphoma* 9, 315-319.
- Samoszuk M.K., Lukes R.J. and Nathwani B.N. (1986). Extensive deposition of eosinophil peroxidase in Hodgkin's and non-Hodgkin's lymphomas. *Am. J. Pathol.* 125, 426-429.
- Samoszuk M.K., Sholly S. and Epstein A.L. (1987). Eosinophil peroxidase is detectable with a monoclonal antibody in collagen bands of nodular sclerosis Hodgkin's disease. *Lab. Invest.* 56, 394-400.
- Samoszuk M., Ravel J. and Ramzi E. (1992). Epstein-Barr virus and interleukin-5 mRNA in AIDS-related lymphomas with eosinophilia. *Human Pathol.* 23, 1355-1359.
- Samoszuk M., Anderson A.L., Ramzi E., Wang F., Braunstein P., Majmundar H. and Slater L. (1993a). Radioimmuno-detection of Hodgkin's disease and non-Hodgkin's lymphomas with monoclonal antibody to eosinophil peroxidase. *J. Nuclear Med.* 34, 1246-1253.
- Samoszuk M., Ramzi E. and Cooper D.L. (1993b). Interleukin-5 mRNA in three T-cell lymphomas with eosinophilia. *Am. J. Hematol.* 42, 402-404.
- Samoszuk M., Lin F., Rim P. and Strathearn G. (1996a). A new marker for blood vessels in human ovarian and endometrial cancers. *Clin. Cancer Res.* 2, 1867-1871.
- Samoszuk M.K., Nguyen V., Gluzman I. and Pham J.H. (1996b). Occult deposition of eosinophil peroxidase in a subset of human breast carcinomas. *Am. J. Pathol.* 148, 701-706.
- Sassler A.M., McClatchey K.D., Wolf G.T. and Fisher S.G. (1995). Eosinophilic infiltration in advanced laryngeal squamous cell carcinoma. Veterans Administration laryngeal cooperative study group. *Laryngoscope* 105, 413-416.
- Slungaard A., Ascensao J., Zanjani E. and Jacob H.S. (1983). Pulmonary carcinoma with eosinophilia: Demonstration of a tumor-derived eosinophilopoietic factor. *New Engl. J. Med.* 309, 778-779.
- Spry J.F.C. (1988). Eosinophils: A comprehensive review, and guide to the scientific and medical literature. Oxford University Press. New York.
- Stefanini M., Claustro J.C., Motos R.A. and Bendigo L.L. (1991). Blood and bone marrow eosinophilia in malignant tumors: Role and nature of blood and tissue eosinophil colony-stimulating factor(s) in two patients. *Cancer* 68, 543-548.
- Tepper R.I., Coffman R.L. and Leder P. (1992). An eosinophil-dependent mechanism for the antitumor effect of interleukin-4. *Science* 257, 548-551.
- van Crombrugge P., Pauwels R. and van der Straeten M. (1983). Thyroid carcinoma and eosinophilia. *Ann. Clin. Res.* 15, 128-130.
- Vukelja S.J., Weiss R.B., Perry D.J. and Longo D.L. (1988). Eosinophilia associated with adult T-cell leukemia/lymphoma. *Cancer* 62, 1527-1530.
- Watanabe K., Shinbo T., Kojima M., Naito M., Tanahashi N. and Nara M. (1989). B-cell lymphoma associated with eosinophilia. *Cancer* 64, 1682-1685.
- Weil S.C. and Hrisinko M.A. (1987). A hybrid eosinophilic-basophilic granulocyte in chronic granulocytic leukemia. *Am. J. Clin. Pathol.* 87, 66-70.
- Weller P.F. (1991). The immunology of eosinophils. *N. Engl. J. Med.* 324, 1110-1118.
- Wong D.T.W., Elovic A., Matossian K., Nagura N., McBride J., Chou M.Y., Gordon J.R., Rand T.H., Galli S.J. and Weller P.F. (1991). Eosinophils from patients with blood eosinophilia express transforming growth factor β -1. *Blood* 78, 2702-2707.