Histol Histopathol (1997) 12: 319-336

Histology and Histopathology

The alveolar type II cell is a pluripotential stem cell in the genesis of human adenocarcinomas and squamous cell carcinomas

A.A.W. Ten Have-Opbroek[1,2], J.R. Benfield[2], J.H.J.H. van Krieken[3] and J.H. Dijkman[1]

[1]Departments of Pneumology, Leiden University, Leiden, The Netherlands,

[2]Cardiothoracic Surgery, University of California Davis, Davis, CA, USA and [3]Pathology, Leiden University, Leiden, The Netherlands

Summary. Studies in a canine bronchogenic carcinoma model indicate that alveolar type II cells may differentiate from carcinogen-exposed epithelium of larger bronchi and generate adenocarcinomas with bronchioloalveolar and other growth patterns. In this study, we investigated whether type II cells are one of the major proliferating cells (=stem cells) in the genesis of two major subsets of bronchogenic carcinoma in humans. Adenocarcinomas (17 bronchioloalveolar; 3 papillary; and 10 other) and squamous cell carcinomas (n=27) as well as (pre)neoplastic lesions in adjacent bronchi and bronchioles were examined for the presence of type II cell markers and cellular proliferation markers (PCNA; Ki-67) using light and electron microscopy and immunohistochemistry. Distinctive features of type II cells, which do not depend upon the degree of cell maturity, are the approximately cuboid shape, large and roundish nucleus, cytoplasmic staining for surfactant protein A (SP-A), and presence of multilamellar bodies or their precursory forms. Cells with this phenotype were found in early progressive (i.e., dysplastic, in situ, microinvasive) lesions in conducting airways and in all the carcinomas investigated, although with a much greater abundance among glandular lesions compared to squamous lesions. The most consistent sites of type II cells were the basal and adjacent epithelial layers. Nuclear PCNA (Ki-67) expression usually predominated in the same region. None of the lesions displayed specific Clara cell features. Our findings strongly suggest that the type II cell is a pluripotential stem cell in human lung carcinogenesis. Based on our findings in humans and dogs, we postulate that type II tumor stem cells may originate from one of two sources: (1) normal bronchial epithelium (by an oncofetal mechanism of differentiation); and (2) normal alveolar type II cells.

Offprint requests to: Dr. Ank A.W. Ten Have-Opbroek, M.D., Ph.D., Professor, Respiratory Biology Group, Department of Anatomy and Embryology, Leiden University, P.O. Box 9602, NL-2300 RC Leiden, The Netherlands

Key words: Alveolar type II cells, Human lung carcinogenesis, Lung adenocarcinomas, Lung squamous cell carcinomas, Non-small cell lung cancer

Introduction

Information about the tumor progenitor cells implicated in the genesis of two major subsets of bronchogenic carcinoma in humans, notably adenocarcinomas and squamous cell carcinomas, is important for insight into the pathogenesis of the disease and the design of methods for early detection and treatment. To date, however, such knowledge has remained inconclusive. Postulated progenitor cells are the bronchial epithelial cells that are capable of division, notably mucous and basal cells and possibly neuroendocrine cells (McDowell, 1987; Nasiell et al., 1987) and also the alveolar type II cell (Ten Have-Opbroek et al., 1990a; Linnoila et al., 1992a). Type II cells are identifiable based upon a set of highly distinctive features which do not depend upon the degree of cell maturity, including the approximately cuboid shape, large and roundish nucleus, cytoplasmic staining for surfactant protein A (SP-A), and presence of multilamellar bodies or their precursory forms (Ten Have-Opbroek, 1981, 1991; Ten Have-Opbroek et al., 1991; Ten Have-Opbroek and Plopper, 1992). Immunohistochemical and ultrastructural studies performed in humans and animal species report on the presence of type II cells and their secretory product SP-A in adenocarcinomas, especially the bronchioloalveolar and papillary subtypes (McDowell et al., 1978; Ten Have-Opbroek et al., 1990a, 1993a,b, 1994a,b, 1996; Linnoila et al., 1992a; Tsutahara et al., 1993). Type II cells are also detectable in human squamous cell carcinomas, although less frequently (McDowell et al., 1978; Linnoila et al., 1992a; Ten Have-Opbroek et al., 1993a, 1994b). However, despite these data, it is not known yet whether type II cells play a role in the genesis of these two major subsets of bronchogenic carcinoma in

humans. Preliminary studies have suggested that this may be the case (Ten Have-Opbroek et al., 1993a, 1994a).

In the normal mammalian lung, type II cells are present in the epithelial lining of the pulmonary acinus, notably in the alveolar septa and in particular regions of respiratory bronchioles, but they do not occur in the epithelium of the more proximal bronchioles and bronchi (Ten Have-Opbroek et al., 1990a, 1991, 1993b, 1994b, 1996; Plopper and Ten Have-Opbroek, 1994). However, evidence that type II tumor cells may originate from major bronchi has been provided by studies in a canine bronchogenic carcinoma model in which subcutaneous bronchial autografts are exposed to 3-methylcholanthrene (Ten Have-Opbroek et al., 1990a, 1993b, 1994b, 1996). After carcinogen exposure type II tumor cells occur in intra-epithelial bronchial lesions with all degrees of atypia and in invasive lesions with different (bronchioloalveolar and other) glandular growth patterns. Immunohistochemistry for cellular proliferation markers (PCNA; Ki-67) has demonstrated that the type II cells are the predominant proliferating cells in these lesions. This strongly suggests that these cells are pluripotential stem cells (see Definitions, below) in canine bronchial carcinogenesis (Ten Have-Opbroek et al., 1996). As reported, the type II tumor stem cells must originate from undifferentiated primordial-like cells of origin that derive from bronchial epithelial cells present in major bronchi or their divisions by retrodifferentiation (Ten Have-Opbroek et al., 1994b, 1996). Very likely, therefore, bronchial carcinogenesis is subject to an oncofetal mechanism of differentiation: bronchial epithelial retro-differentiation followed by novel differentiation of particular (here: alveolar) tumor stem cells (Ten Have-Opbroek et al., 1994b, 1996).

The present study reports on the expression of the afore-mentioned set of type II cell markers and cellular proliferation markers (PCNA; Ki-67) in two subsets of human bronchogenic carcinoma, i.e., adenocarcinomas and squamous cell carcinomas, and in (pre)neoplastic lesions in adjacent conducting airways using light microscopy and immunohistochemistry in adjacent serial 6 µm sections and transmission electron microscopy. We used antibodies to human Clara cell 10kD protein (CC10) (gift of Dr. G. Singh, Pittsburg PA) as one of the immunohistochemical controls. Our findings support the view that the alveolar type II cell is a pluripotential stem cell in the genesis of the human lung carcinomas investigated. However, as will be discussed, further evidence is required to prove this conclusion incontrovertibly. Based on our findings in humans (present study; Ten Have-Opbroek et al., 1993a, 1994a) and our work in the canine model (Ten Have-Opbroek et al., 1990a, 1993b, 1996), we postulate that type II tumor stem cells may originate from one of two sources: (1) the originally existing bronchial epithelium of conducting airways by an oncofetal mechanism of differentiation (see above); and (2) normal alveolar type II cells existing in the lung parenchyma.

Definitions

The terms stem cell and cell of origin are frequently used as synonyms. In this study, as in our earlier reports (Ten Have-Opbroek et al., 1990a, 1993b, 1994b, 1996), the term "*cell of origin*" refers to the very first undifferentiated (primordial-like) tumor progenitor cell that appears during transformation (via metaplasia) of normal bronchial epithelium to bronchogenic carcinoma. We use the term "*stem cell*" to indicate the predominant proliferating cell type that occupies the dividing layers of the preneoplastic and neoplastic lesions.

Materials and methods

Tumor and control specimens

Specimens from lung carcinomas and (pre)neoplastic lesions in adjacent airways were obtained from patients requiring surgical resection of the tumors. Normal lung tissue was taken from apparently normal areas in the resected lungs or lung lobes that were remote from the tumor. Permission for the use of the human specimens was given by the Committee for Medical Ethics of the School of Medicine at the University of Leiden and the Human Subjects Use Committee of the University of California at Davis. The specimens were derived from a broad population of patients including women and racial/ethnic minorities and were procured according to approved protocols. The lung carcinoma specimens were classified in hematoxylin and eosin (H&E) stained sections according to the international standards for human lung tumors (WHO, 1982) as either adenocarcinomas (n=30; 17 bronchioloalveolar; 3 papillary; and 10 other) or squamous cell carcinomas (n=27).

Light microscopy; Immunohistochemistry

Formalin-fixed serial sections were cut at 6 µm and placed on poly-L-lysine coated slides. Adjacent sections were used for immunohistochemistry and H&E staining, which allowed for light microscopic characterization of immunoreactive cells in lesions and control tissues. We used antibodies to: (1) Proliferating Cell Nuclear Antigen (PCNA), clone PC10 (Signet Laboratories, Dedham, MA) and Ki-67 proliferating cell antigen, clone MIB-1 (DAKO Corp., Carpenteria, CA; AMAC Inc., Westbrook, ME), mouse anti-human; and (2) natural and recombinant human SP-A, rabbit or mouse anti-human, including the antibodies SALS-Hu (Otto-Verberne et al., 1988, 1990); BGP, a polyclonal antibody to purified recombinant human SP-A provided by BYK Gulden Pharmaceuticals, Konstanz, Germany (Voss et al., 1988); and gifts from other investigators. SALS-Hu was prepared in rabbits using a surfactant enriched fraction of bronchoalveolar lavage fluid from adult human lung; the SP-A specificity was assessed by immunohistochemistry, Western blotting, and in vitro

translation of mRNA from human lungs and immunoprecipitation (Otto-Verberne et al., 1988, 1990). The PCNA and Ki-67 antibodies were applied to tissue sections according to the ABC-peroxidase method using biotinylated horse anti-mouse secondary antibodies (Vector Laboratories, Burlingame, CA), streptavidin peroxidase (Dako Corp., Carpinteria, CA), and 3,3'-diaminobenzidine as the chromogen as reported (Ten Have-Opbroek et al., 1991, 1996). Prior to incubation, endogenous peroxidase activity was quenched with a freshly prepared 3% hydrogen peroxide solution in methanol. Sections of each specimen were processed for antigen retrieval by microwave exposure in 10mM citrate buffer, pH 6.0 (Shi et al., 1991; Yu et al., 1992); for PCNA detection, adjacent untreated sections were used as well. The optimal antibody dilution in phosphate-buffered saline (PBS), pH 7.6 (Sigma Chemical, St. Louis, Mo) was assessed using positive normal tissue controls (lung; colon; lymph nodes). The Ki-67 antibodies were used at a 1:50 dilution, and the PCNA antibodies at a dilution of 1:1000 for microwave treated sections and of 1:200 for untreated sections. The antibodies to SP-A were applied either according to the indirect immunofluorescence technique using fluorescein isothiocyanate (FITC)-conjugated swine anti-rabbit IgG (DAKO, Glostrup, Denmark; absorbed with human IgG) or goat anti-mouse IgG (Nordic Immunological Laboratories, Tilburg, The Netherlands) as secondary antibody (Ten Have-Opbroek et al., 1990a, 1993a,b, 1994b), or according to the avidin/biotin complex (ABC) method as above using swine anti-rabbit or horse anti-mouse secondary antibodies (Vector Laboratories, Burlingame, CA) (Ten Have-Opbroek et al., 1991, 1996). The sections were counterstained with Mayer's hematoxylin. The percentage of type II cell positive glandular or squamous elements (=lesions) per lung carcinoma specimen was estimated in SP-A stained step sections (approximately seven 6 µm sections removed) of the tumor (incidence scores: 0%; 1-10%; 11-49%; and 50-100%). The glandular or squamous lesions were considered type II cell positive when they contained cells with the light microscopic type II phenotype (i.e., approximately cuboid shape, large and roundish nucleus, cytoplasmic staining for SP-A), irrespective of the grade of SP-A staining (i.e., weak, moderate or strong).

Immunohistochemical controls were performed on the same tumor material (adjacent sections) using antibodies to Clara Cell 10kD protein (CC10) (rabbit anti-human, optimal dilution: 1:5000; gift of Dr. G. Singh, Pittsburg, PA), preimmunization serum (PS) or normal mouse serum as the primary antibody or omission of one of the incubation steps, and on normal lung tissues.

Transmission electron microscopy

Specimens from human adenocarcinomas and squamous cell carcinomas were fixed by immersion in 1.25% glutaraldehyde and 2% paraformaldehyde in 0.1M cacodylate buffer (pH 7.4) and embedded in Epon as reported (Ten Have-Opbroek et al., 1988). We obtained 5 to 10 blocks per tumor specimen. Semi-thin sections (1 µm) of these blocks were stained with toluidine blue and used to select blocks with similar lesions as studied by light microscopy and immunohistochemistry. For this selection, H&E-stained 6 µm sections of the corresponding tumors were used as reference slides. The selected blocks were sectioned at approximately 90 nm. The ultrathin sections were mounted on copper grids, stained with aqueous 7% uranyl acetate for 20 min and alkaline lead citrate for 10 min, and examined with a Philips 200 electron microscope at 80 kV. For type II cell identification, use was made of published data on immature and mature type II cells in fetal and adult lungs (Otto-Verberne et al., 1988; Ten Have-Opbroek et al., 1988, 1990b, 1991; Ten Have-Opbroek, 1991; Brandsma et al., 1993; Ten Have-Opbroek and De Vries, 1993).

Molecular characterization of reactive proteins recognized by anti SP-A in human tumor material

To characterize the reactive protein recognized by SALS-Hu in the tumor sections, samples from human adenocarcinoma homogenates (each prepared with an equal volume of PBS, pH 7.3), and SP-A positive (recombinant human SP-A, BYK Gulden Pharmaceuticals, Konstanz, Germany; human bronchoalveolar lavage fluid from alveolar proteinosis patients) and negative (human serum) controls were subjected to sodium dodecyl sulphate-polyacrylamide gel electrophoresis (SDS-PAGE) according to Laemmli and Favre (1973) using 1 mm thick gels containing 15% polyacrylamide. For immunoblotting procedures, the proteins were transferred electrophoretically from the gels to nitrocellulose paper (Immobilon-P, pore size 0.45 µm; Millipore, Bedford, MA) and immunostained using SALS-Hu or a control serum (preimmunization serum) and horseradish peroxidase-conjugated swine anti-rabbit IgG (DAKO, Glostrup, Denmark; absorbed with human IgG) as previously described (Van Hemert et al., 1986; Otto-Verberne et al., 1988).

Results

Type II cells in normal human lung as shown by light microscopy, immunohistochemistry, and electron microscopy

In the present as in earlier studies of normal human lungs, epithelial cells with the light microscopic features of alveolar type II cells (i.e., cuboid shape; large roundish nucleus; cytoplasmic staining for SP-A; see Introduction) were found to occur in the alveolar septa and in particular zones of respiratory bronchioles (Fig. 7E). The type II cells showed a moderate or strong cytoplasmic staining for SP-A with the SP-A antibodies used, including SALS-Hu and BGP. Alveolar type I cells

Table 1. The incidence of type II cell positive lesions in two major subsets of bronchogenic carcinoma[1].

TUMOR HISTOLOGY	TUMOR No.	TYPE II CELL POSITIVE LESIONS (%)			
		0%	1-10%	11-49%	50-100%
Adenocarcinoma	30				
Bronchioloalveolar	17				17 (approx. 100%)
Papillary	3				3 (approx. 100%)
Other	10		7	2	1
Squamous cell carcinoma	27		24	3	

[1]: as estimated in SP-A stained step sections per tumor specimen (Type II cell criteria (see text): cuboidal cell shape; large, roundish nucleus; and cytoplasmic staining for SP-A).

and bronchial epithelium consisting of columnar ciliated cells, columnar Clara or mucous cells and basal cells did not stain. Alveolar macrophages showed variable SP-A immunoreactivity. The type II cells present in alveolar septa and distal bronchiolar areas also displayed the ultrastructural characteristics of type II cell differentiation, namely multilamellar bodies and/or their precursory forms.

Type II cells in adenocarcinomas and squamous cell carcinomas as shown by light microscopy, immunohistochemistry, and electron microscopy

Cells that manifested the type II phenotype light and electron microscopically were observed in all the lung carcinomas investigated in this study. The type II cells predominated at specific sites of the glandular and squamous lesions, i.e., the basal and adjacent epithelial layers (for details, see below). All the SP-A antibodies used provided a similar (= either positive or negative) staining result in the tumor sections. However, the staining was often weaker and also more focal when antibodies to recombinant human SP-A (BGP) were used. As found in SALS-Hu stained step sections, there were differences in the abundance of type II cell positive lesions among the tumor types investigated (Table 1). Type II cell positive lesions prevailed in adenocarcinomas of the bronchioloalveolar and papillary subtypes (incidence score: approximately 100%) and were less frequent in other subtypes of adenocarcinoma and in squamous cell carcinoma. None of the latter tumors, however, was completely devoid of type II cell positive lesions, although their incidence was sometimes extremely low. In such cases, the few positive lesions present were often found in proximity to hyperplastic type II cell configurations or apparently normal alveolar spaces (see Figs. 4A, 5D).

Figure 1 illustrates our light and electron microscopic findings in adenocarcinomas with bronchioloalveolar and papillary features. The lesions (Fig. 1A) consisted of cuboid epithelial cells showing moderate to strong pleomorphism. The nuclei were usually large and clear with one or two prominent nucleoli. The tumor cells had ample eosinophilic cytoplasm; there were no signs of squamous metaplasia. The cells were arranged in a single layer or a two-three cell thick multilayer on a delicate stroma and sometimes also in sheets. After incubation with SP-A antibodies and FITC conjugate, the epithelial cells displayed a strong cytoplasmic fluorescence, whereas the stroma remained unstained (Fig. 1B). Immunohistochemical controls were negative. At the ultrastructural level (Fig. 1C), the epithelial cells constituting the lesions had a large, roundish or ovoid nucleus, sometimes with indentations, but bizarre nuclei were also observed. Epithelial cells surrounding the lumen were studded with rather long microvilli at their luminal surface; they were connected by distinct junctional complexes at their apical borders and some lateral desmosomes. Furthermore, adjacent epithelial cells exhibited a striking pattern of interdigitations of cell extensions. The basal surface of cells that adjoined connective tissue sometimes displayed distinct foot processes. Closer examination (Fig. 1D) revealed that the cytoplasm contained a variety of inclusion bodies (IB). Primitive lamellar IB (Fig. 1D) had a few electron dense lamellae around a granular or more homogeneous core of light to moderate density. Mature multilamellar IB (not shown) were also observed, although infrequently. Dense IB sometimes displayed a (para)centric core or peripheral rim of lighter density. They varied considerably in size and in shape (round; oblong; rod- or crescent-shaped). Multivesicular bodies were usually osmiophilic and lightly to moderately electron dense. Finally, there were also cytoplasmic IB of various sizes (not shown), which presumably are primary structures in multilamellar body formation (Ten Have-Opbroek, 1991). The cytoplasm also contained a well-developed Golgi apparatus, numerous mitochondria, free ribosomes, profiles of variably distended rough and smooth endoplasmic reticulum (ER), and sometimes also bundles of filaments. The epithelial cells in the lesions often looked different due to variations in their IB content (predominant types; abundance of IB). Some epithelial cells were mainly stuffed with whorls of ER profiles or with dilated ER cisternae.

Figure 2 A,B gives an example of our findings in a moderately differentiated squamous cell carcinoma. Light microscopically, this tumor consisted of irregular fields formed by cuboid epithelial cells with large, hyperchromatic and often polymorphous nuclei. There

was dyskeratosis and locally also formation of keratin pearls. Ultrastructural examination (Fig. 2A) showed that epithelial cells with the type II phenotype were immediately contiguous to epithelial areas with varying degrees of cellular keratinization. They were most consistently found at the lesions' borders, which could be adjacent to alveolar spaces (Fig. 2A) or the surrounding connective tissue (not shown). The type II cells (Fig. 2B) and epithelial cells with little keratinization in the adjacent fields (not illustrated) resembled those present in adenocarcinomas and contained similar types of IB and organelles in their cytoplasm, see Figure 1D. Light microscopic immunohistochemistry demonstrated that the squamous lesions stained for SP-A. The SP-A-positive cuboid cells had a similar preferential localization as the type II cells identified by ultrastructure (see above), namely the border of the lesions, which could be adjacent to alveolar spaces (see Fig. 5D) or to surrounding connective tissue (see Figs. 5D and 6C). Tumor cells with the morphologic features of type II cells were also found in lymph node metastases of squamous cell carcinomas (Figs. 2C). All the cells (Fig. 2D) displayed a strong cytoplasmic fluorescence after exposure to SP-A antibodies and FITC conjugate, whereas the stroma remained unstained. Immunohistochemical controls were negative. The fluoresence in the tumor type II cells was delicate and included the peripheral cytoplasm as also seen in embryonic lungs.

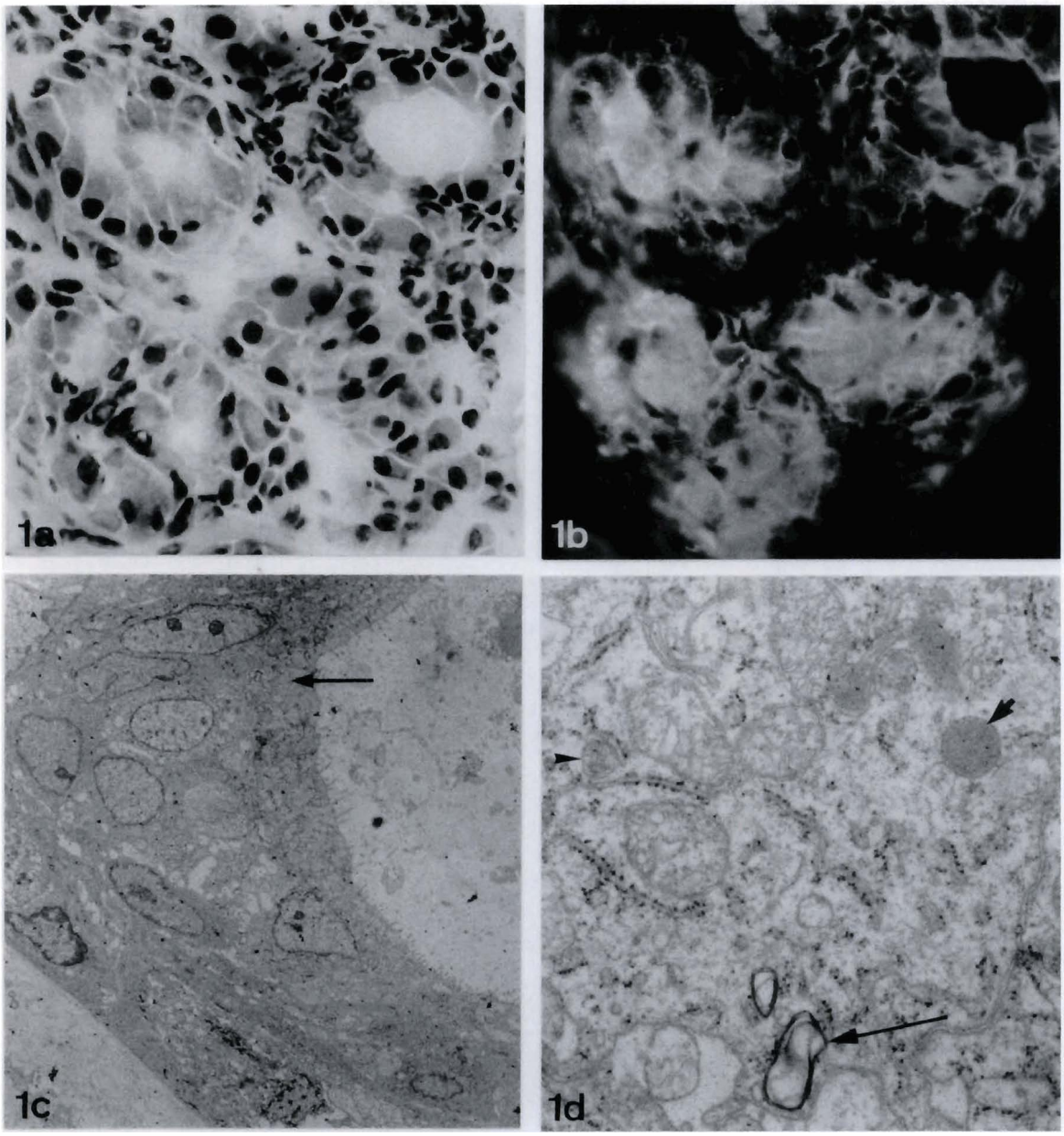

Fig. 1. Human adenocarcinoma. A. Glandular lesions situated in a delicate fibrous stroma and composed of cuboid cells with large roundish or sometimes bizarre nuclei. H&E. x 300. B. All the cuboid cells exhibit cytoplasmic fluorescence for SP-A, indicating (see Figure 7E) that they are alveolar type II cells. Anti SP-A, indirect immunofluorescence. x 300. C. Electron micrograph of same tumor. Arrow indicates area shown enlarged in D. Uranyl acetate/lead citrate. x 2,400. D. Note that the type II cells contain osmiophilic multivesicular (arrowhead), dense (short arrow), and lamellar (arrow) inclusions in their cytoplasm. Uranyl acetate/lead citrate. x 32,000

This phenomenon was also observed in primary squamous cell carcinomas and adenocarcinomas (see below).

Distribution of proliferation markers and type II cell markers in adenocarcinomas and squamous cell carcinomas as shown by light microscopy and immunohistochemistry

Figure 3A-D illustrates the distribution of proliferation markers (PCNA; Ki-67) and type II cell markers in adenocarcinomas with bronchioloalveolar and papillary features. The lesions (Fig. 3A) consisted of cuboid or low-columnar tumor cells showing mild to moderate pleomorphism with large and occasionally vesicular nuclei, prominent nucleoli, and abundant eosinophilic cytoplasm. Immunohistochemistry revealed abundant nuclear staining for PCNA in all the lesions (Fig. 3B). This staining pattern was not influenced by the methods used (antigen retrieval vs. no antigen retrieval). A similar distribution pattern was found for Ki-67. The lesions did not show immunoreactivity when antibodies to CC10 (Fig. 3C) or other immunohistochemical controls were used. In contrast, however, they all showed a positive staining for SP-A (Fig. 3D). The SP-A staining, which was cytoplasmic and sometimes also nucleolar, was found in all the epithelial cells (as in Fig. 1B). The stroma was negative except for some

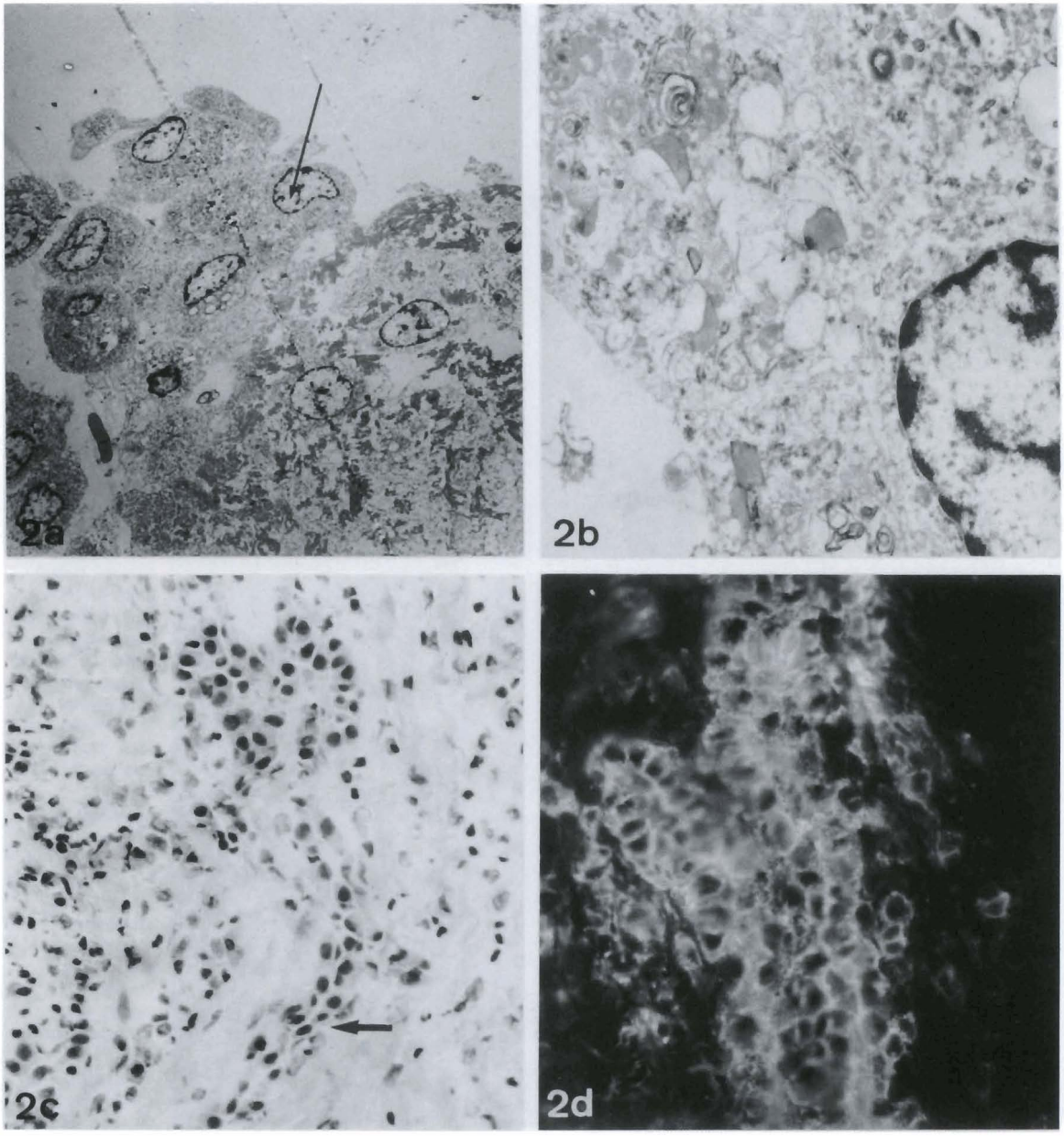

Fig. 2. Human squamous cell carcinoma. **A.** Epithelial cells with the type II phenotype (arrow; shown enlarged in B) are immediately contiguous to areas with cellular keratinization. Uranyl acetate/lead citrate. x 1,600. **B.** Note the presence of multiple dense bodies and (multi)lamellar bodies in the cytoplasm of type II cells. Uranyl acetate/lead citrate.x 16,000. **C.** Lymph node metastasis. The cuboid epithelial cells (arrow) are arranged in tubular or cord-like structures. H&E. x 125. **D.** All the cuboid cells stain for SP-A. Anti SP-A, indirect immuno-fluorescence. x 300

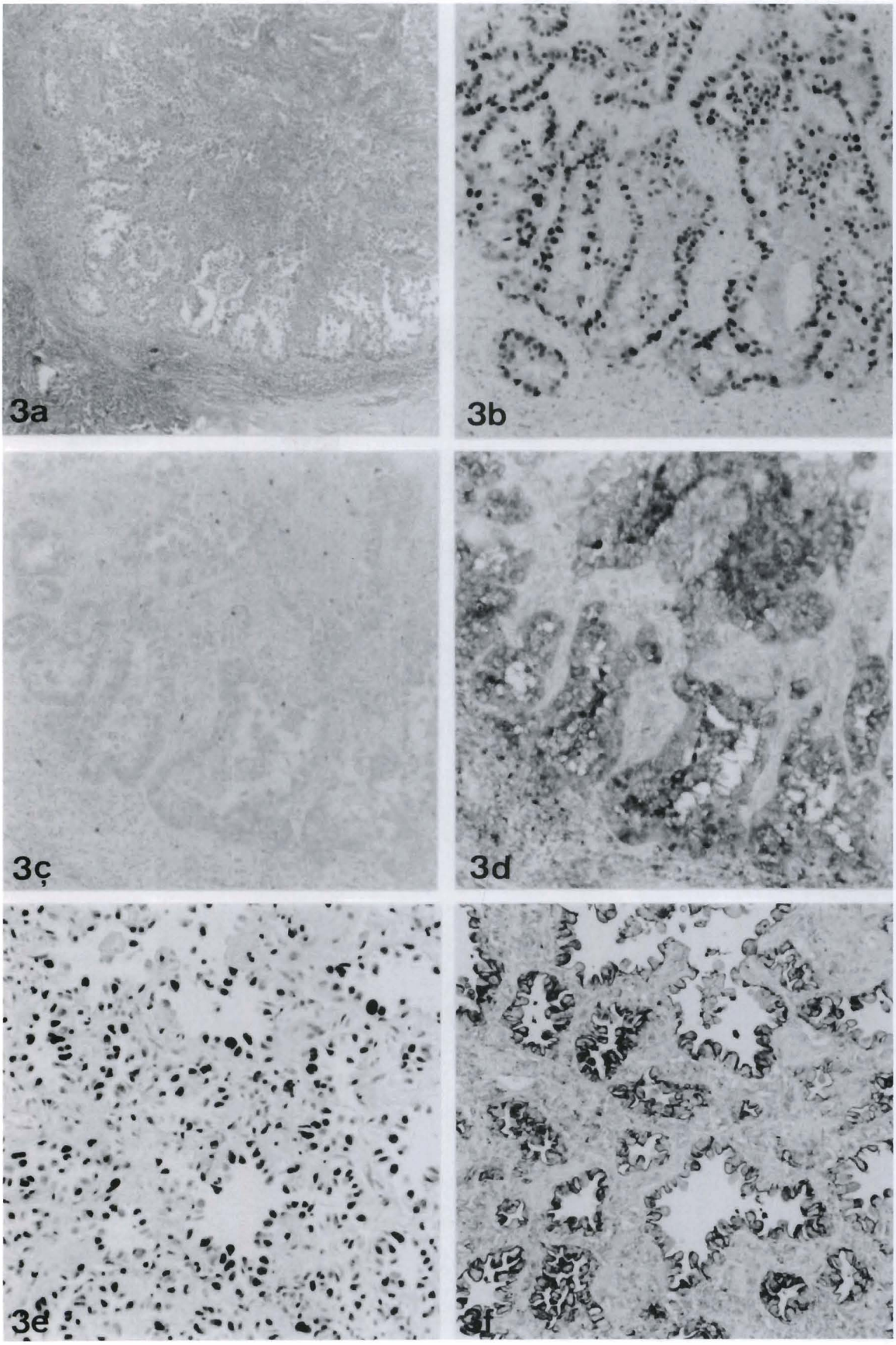

Fig. 3. Co-localization of the alveolar type II phenotype and proliferation markers in adenocarcinomas with bronchioloalveolar and papillary features as shown by ABC immunohisto-chemistry in adjacent sections. **A.** Morphology of lesions. H&E. x 52. **B.** All the lesions display a prominent nuclear staining for PCNA. Anti PCNA, clone PC10. x 130. **C.** There is no staining for CC10. Anti CC10. x 130. **D.** All the cells of the lesions show a cytoplasmic staining for SP-A. Anti SP-A. x 130. **E.** True bronchiolo-alveolar lesions also have a high incidence of nuclear PCNA staining. Anti PCNA, clone PC10. x 130. **F.** The cuboid epithelial cells are almost all SP-A positive. Anti SP-A. x 130

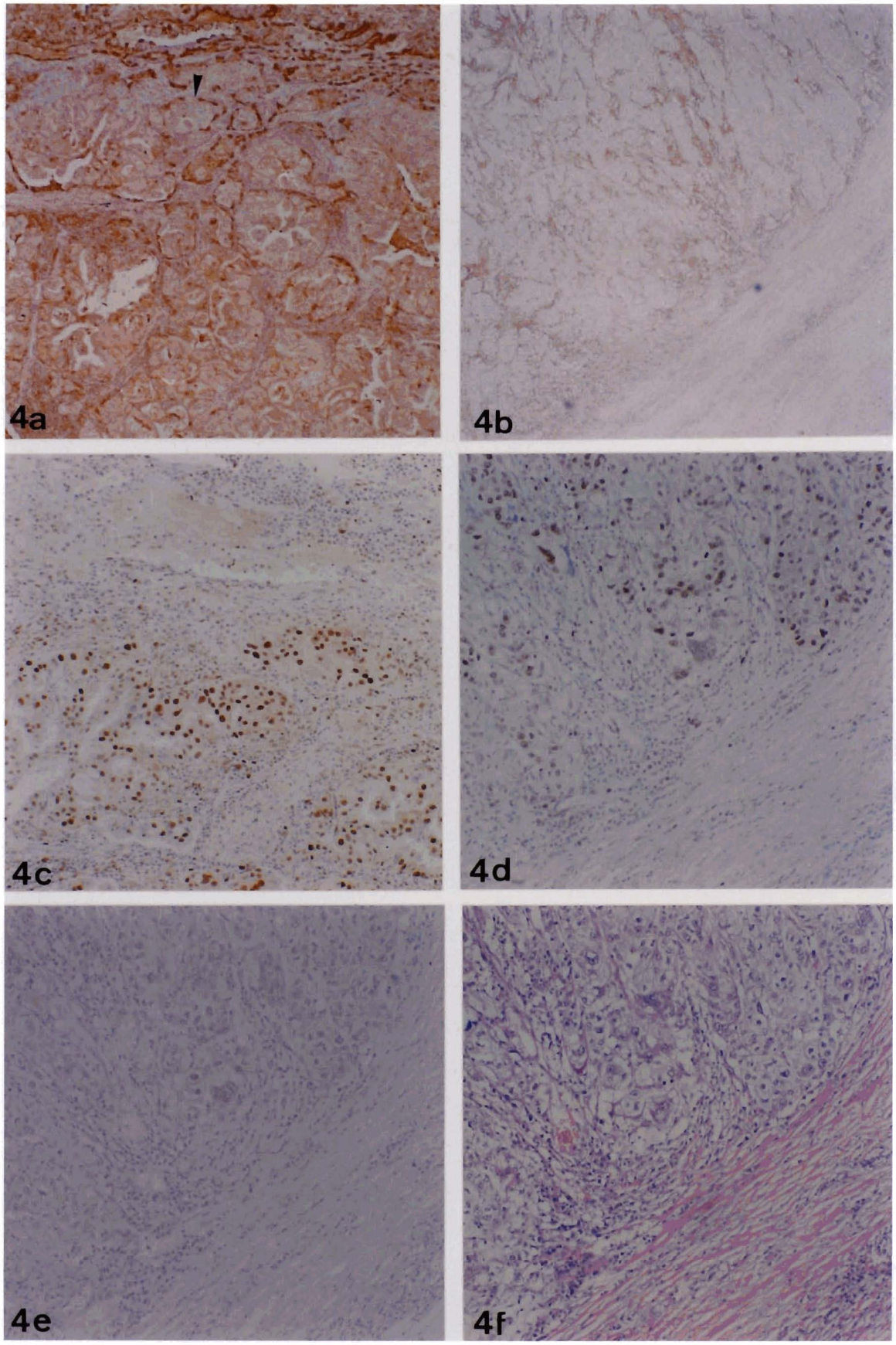

Fig. 4. Co-localization of the alveolar type II phenotype and proliferation markers in other subtypes of adenocarcinomas as shown by ABC immunohisto-chemistry in adjacent sections. Peroxidase (=brown) labeling; nuclear counterstaining: hematoxylin. **A.** SP-A positive cuboid cells localize to the basal epithelial layer of the tubular lesions and are sometimes also found in more inner layers, which are otherwise almost not stained. Note the hyperplastic SP-A positive type II cell configurations (top panel). Arrowhead indicates area shown enlarged in C. Anti SP-A. x 80. **B.** There are also areas with SP-A negative lesions. Positive staining in the stroma must be due to SP-A secreted/lost by type II tumor cells. Note that the tumor capsule is not stained. Anti SP-A. x 52. **C, D.** The lesions shown in A and B display proliferation activity. Anti PCNA, clone PC10. x 130. **E.** Immunohisto-chemical controls are completely negative. Preimmunization serum. x 130. **F.** Morphology of the lesions. H&E. x 130

staining in areas with chronic inflammation and in macrophages. The findings indicated that the SP-A-positive cuboid cells were the proliferating cells of the lesions. Similar pictures were found in true bronchiolo-alveolar carcinomas. The cuboid or low-columnar epithelial cells with large nuclei, which lined the alveolar spaces, displayed a high incidence of nuclear PCNA staining (Fig. 3E) and were almost all SP-A-positive (Fig. 3F). The SP-A staining was delicate but strong and included especially the peripheral cytoplasm, which suggests cellular immaturity (see above).

Figure 4 illustrates the distribution of proliferation markers and type II cell markers in other subtypes of adenocarcinomas. As shown below, the tumors showed

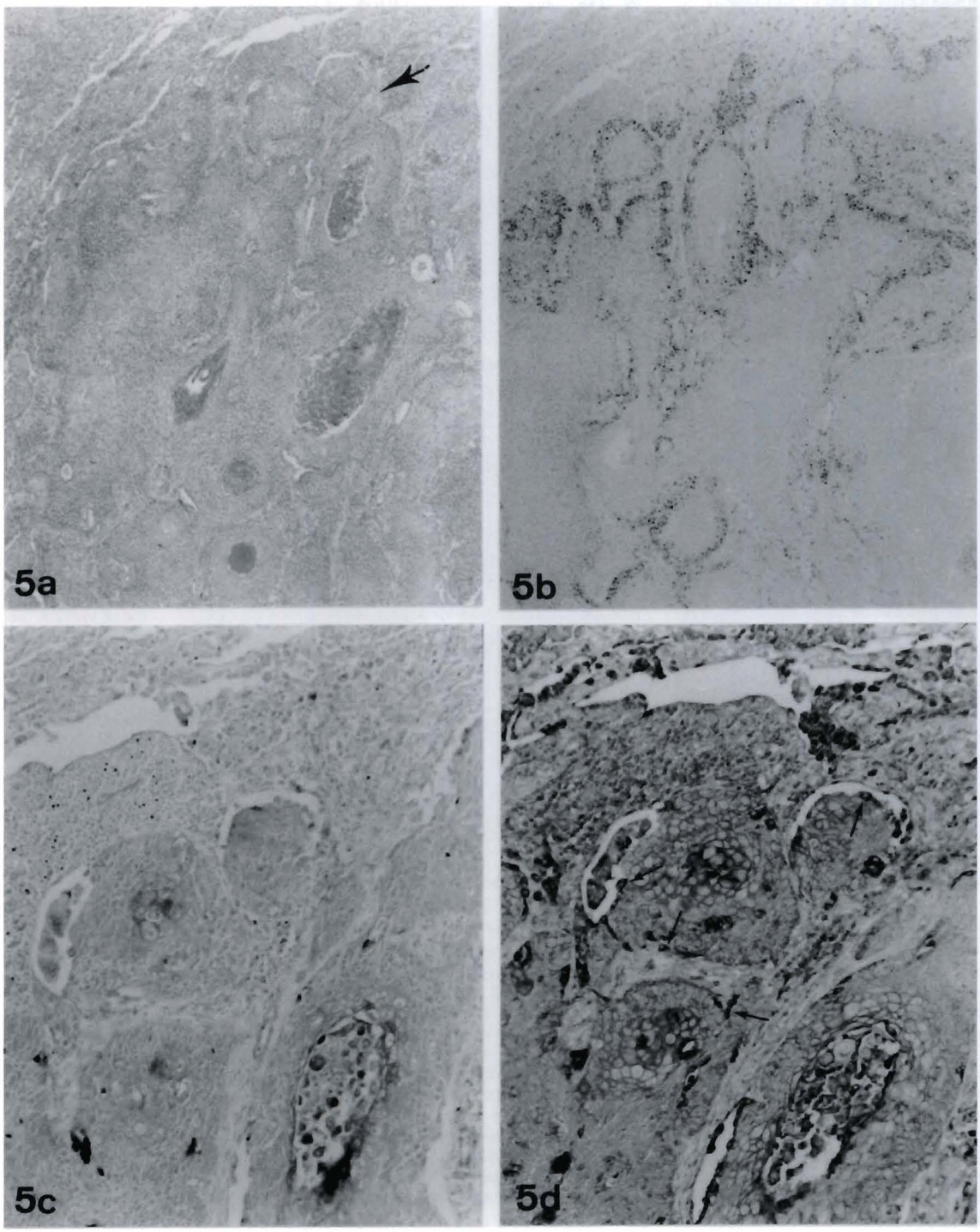

Fig. 5. Co-localization of the alveolar type II phenotype and proliferation markers in moderately differentiated squamous cell carcinomas as shown by ABC immunohisto-chemistry in adjacent sections. **A.** Lesions showing central keratinization and situated near alveolar spaces, see top of Figure. Arrow indicates area shown enlarged in C and D. H&E. x 52. **B.** PCNA expressing cuboid cells show a striking preferential localization, i.e., the basal and adjacent epithelial layers of the lesions. Anti PCNA, clone PC10. x 52. **C.** The lesions do not stain for CC10. Anti CC10. x 130. **D.** SP-A positive cuboid cells occur, singly or in rows, in the basal layers of the lesions near stroma and alveolar spaces (arrows) and sometimes also in more inner layers of the lesions, which are otherwise slightly stained. Anti SP-A. x 130

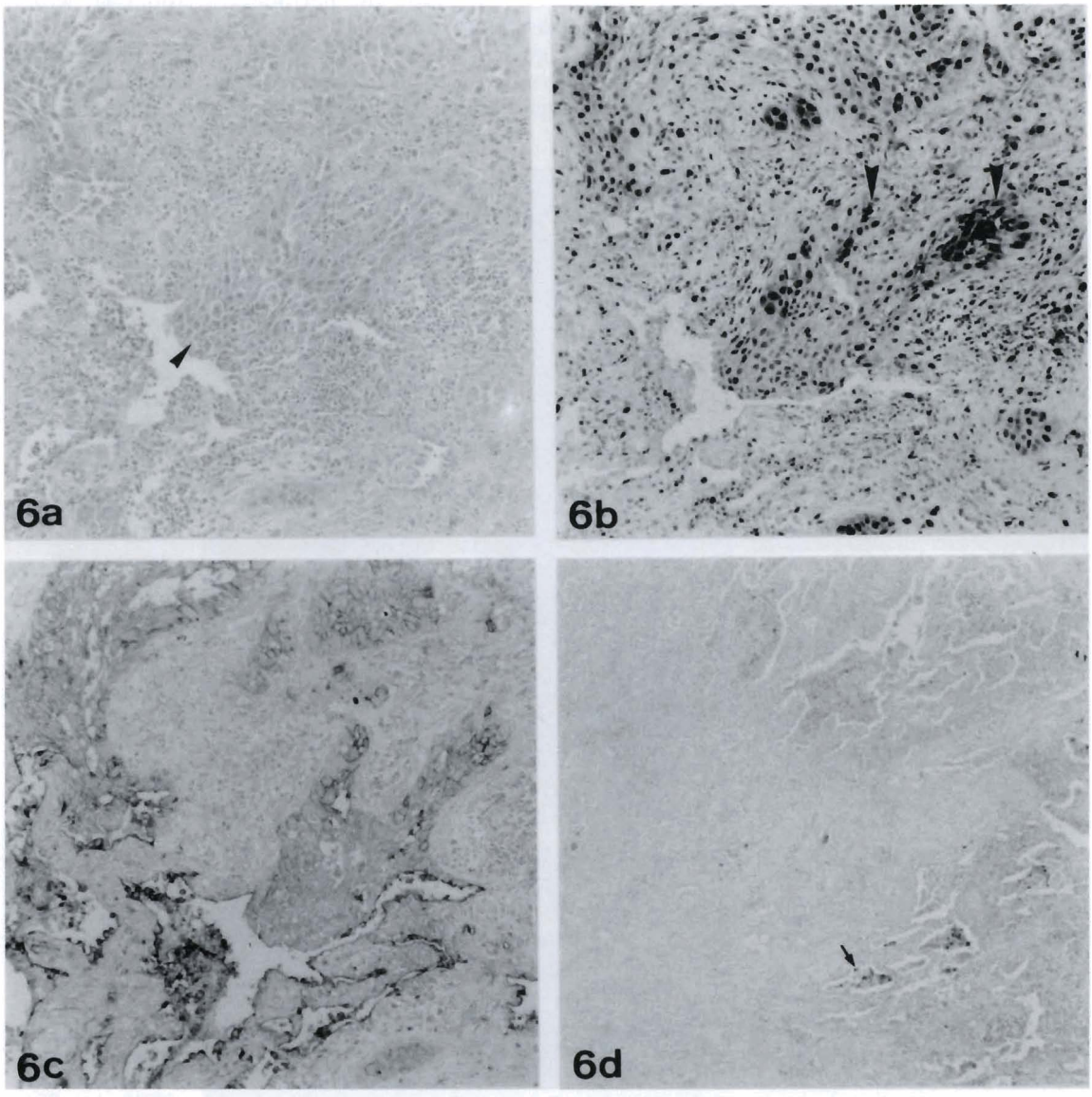

Fig. 6. Co-localization of the alveolar type II phenotype and proliferation markers in poorly differentiated squamous cell carcinomas as shown by ABC immunohisto-chemistry in adjacent sections. **A.** Lesions (arrowhead) arising from alveolar spaces. H&E. x130. **B.** PCNA positive nuclei are most abundant in the basal and adjacent epithelial layers, especially in epithelial projections into the stroma (arrowheads). Anti PCNA, clone PC10. x 130. **C.** SP-A expressing cuboid cells show a similar (predominately basal) localization as found for PCNA. Note the SP-A positive type II cells along the alveolar spaces. Anti SP-A. x 130. **D.** Immunohisto-chemical controls of the tumor area (on the left) are completely negative. Some staining in adjacent alveolar spaces (arrow) is caused by the presence of macrophages. Preimmunization serum. x 52

Fig. 7. Co-localization of the alveolar type II phenotype and proliferation markers in (pre)neoplastic lesions arising from a tumor-associated bronchiole as shown by ABC immunohistochemistry (peroxidase (=brown) labeling; nuclear counterstaining: hematoxylin) in adjacent sections. **A.** The upper bronchiolar wall is lined with apparently normal bronchial epithelium. The lower wall displays a dysplastic focus (on the right) and in situ/invasive carcinoma (on the left). The latter area contains some normal bronchial epithelial inclusions (arrow). H&E x 130. **B.** Nuclear staining for PCNA predominates in the lower bronchiolar wall, where it is present in the basal layer of the lesions. Anti PCNA, PC10. x 130. **C.** Strong staining for CC10 is seen where Clara cells occur in normal bronchial epithelium, i.e., in the upper and left part of the lower bronchiolar wall. The intra-epithelial and invasive lesions of the lower wall are not stained. Anti CC10. x130. **D.** SP-A positive cuboid cells are present in the intraepithelial lesions in the lower wall, also in the basal regions (arrows), and occupy the invasive lesions (arrowheads). Normal bronchial epithelium is not stained for SP-A; linear staining along luminal borders is due to SP-A or conjugate retained among cilia or in epithelial ruffles. There is some staining of cellular infiltrate, notably macrophages, in adjacent connective tissue. Anti SP-A. x130. **E.** Normal terminal and respiratory bronchiole with parenchyma (Ten Have-Opbroek et al., Anat. Rec. 1991; 229:339-354). SP-A staining is highlighted here by alkaline phosphatase (=blue) labeling. Normal bronchial epithelium (columnar ciliated cells, columnar nonciliated (=Clara) cells and basal cells) is always SP-A negative, whereas cuboid type II cells lining distal bronchiolar areas and alveoli are SP-A positive (blue). Macrophages (arrowhead) show nonspecific (=brown) staining and sometimes also blue (=SP-A) staining. Nuclear fast red; anti SP-A. x75

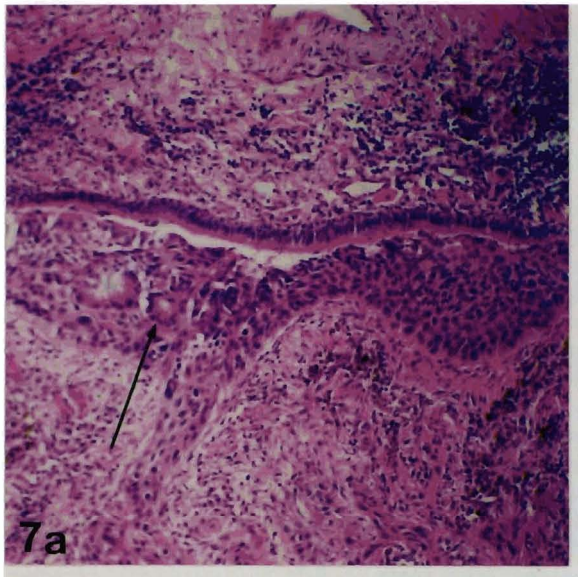
7a

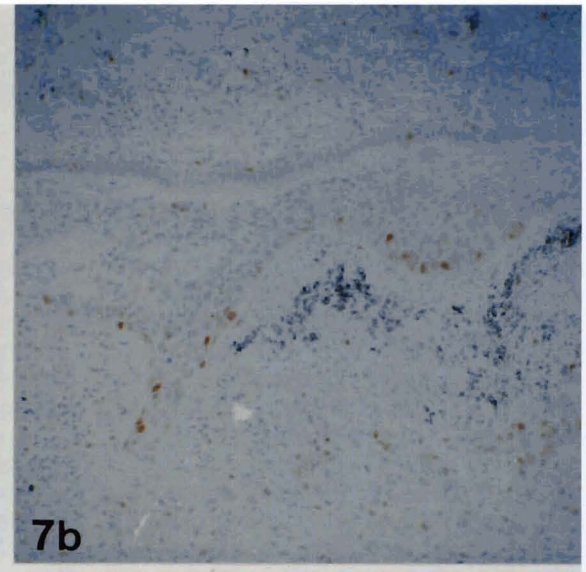
7b

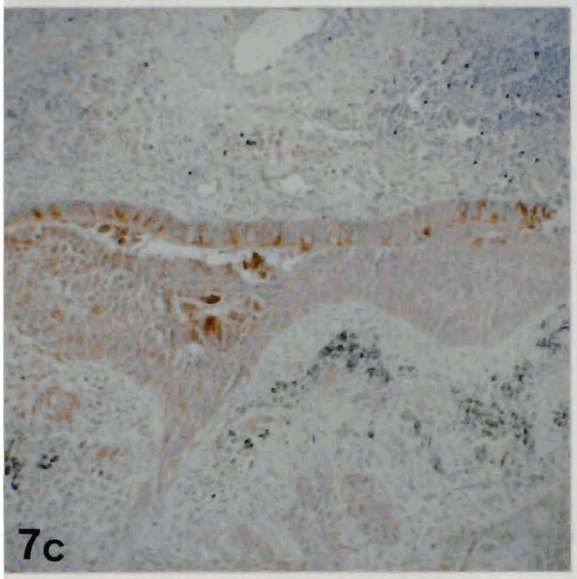
7c

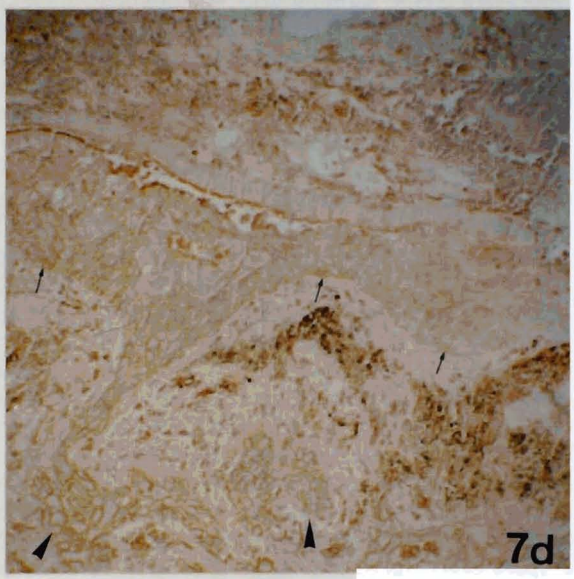
7d

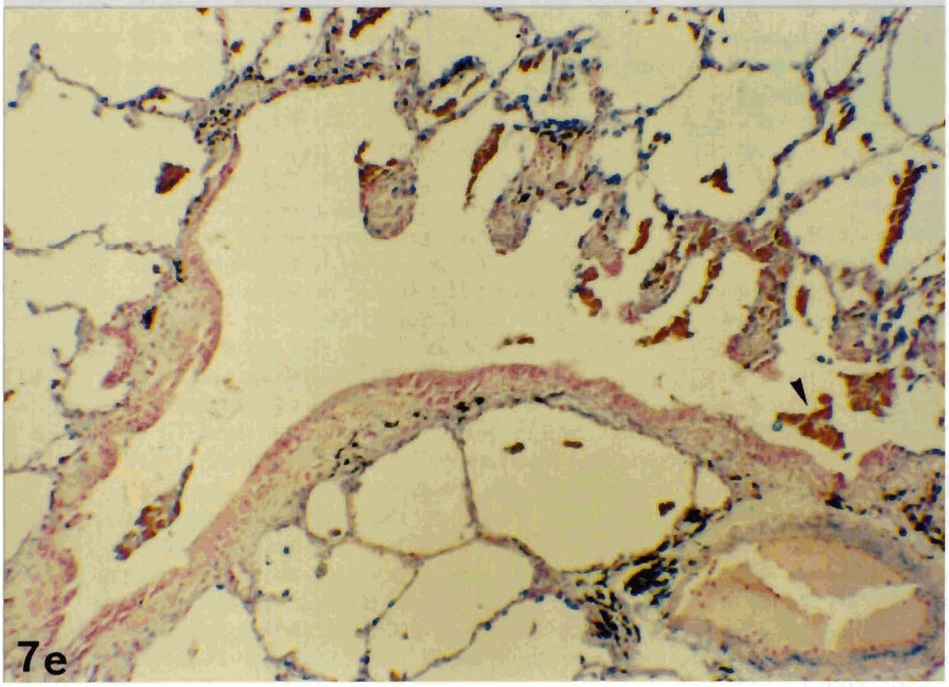
7e

distinct SP-A reactivity, although with site-specific variations (proximity vs. no proximity to bronchi/ bronchioles and/or hyperplastic type II cells). The lesions of the tumor shown (see Fig. 4F) consisted of cuboid to ovoid cells showing eosinophilic cytoplasm and large, strongly polymorphous nuclei with prominent nucleoli. In tumor areas situated in proximity to SP-A positive hyperplastic type II cell configurations (and a normal bronchiole; not shown), SP-A staining was found in all the lesions whereas the stroma was not stained. The SP-A staining predominated in the basal epithelial layer of the lesions and was sometimes also found in more inner layers. However, in tumor areas near the fibrous capsule (Fig. 4B), SP-A staining was no longer observed within the lesions but in the stroma among the lesions. Remarkably, the tumor capsule was not stained. Both the SP-A positive and the SP-A negative tumor areas displayed distinct PCNA activity (Fig. 4C, D). Taken together, the findings shown in Figures 4 A-D suggested that the epithelial cells of the lesions were viable type II cells which seemed to lose SP-A expression during proliferation and to finally secrete or lose their SP-A content to the surrounding stroma. This would mean that originally SP-A-positive cuboid cells were one of the major proliferating cells of the lesions. Immunohistochemical controls did not show any immunoreactivity (Fig. 4E).

Figures 5 and 6 provide the distribution of proliferation markers and type II cell markers in moderately and poorly differentiated squamous cell carcinomas. The lesions of moderately differentiated tumors (Fig. 5A) consisted of cuboid tumor cells displaying a moderate degree of pleomorphism with occasional tumor giant cells, large and hyperchromatic nuclei, relatively abundant cytoplasm which varied from clear to dark pink, prominent intercellular bridges, and focal areas of keratinization. PCNA-expressing cells (Fig. 5B) had a distinctive preferential localization, i.e., the basal and adjacent epithelial layers of the lesions. In a number of lesions, such cells were present in more inner layers as well. Adjacent H&E sections showed that such variant staining patterns were probably caused by a tangential cut of the lesions. The lesions (Fig. 5C) did not stain for CC10; the slight staining found in areas with keratinization was also seen in controls with pre-immunization serum and was thus nonspecific. In contrast, however, the lesions did show immunoreactivity for SP-A (Fig. 5D), whereas the stroma was not reactive. The cuboid SP-A positive cells were most consistently found at the border of the lesions, which could be adjacent to alveolar spaces or to the surrounding connective tissue. The similar (=basal) localization of SP-A and PCNA expression suggested that the SP-A positive cuboid cells were one of the major proliferating cells of the lesions. In addition, SP-A positive cells were seen in more inner layers of the lesions, which were otherwise slightly stained. Most of the SP-A positive lesions were found in tumor areas which were near hyperplastic type II cell configurations or apparently normal alveolar spaces with SP-A positive type II cells in their lining (Fig. 5D). The lesions of poorly differentiated squamous cell carcinomas (Fig. 6A) consisted of cuboid cells showing pleomorphism, enlarged and variably sized hyperchromatic nuclei with prominent nucleoli, variable amounts of eosinophilic cytoplasm, and intercellular bridges. PCNA positive nuclei (Fig. 6B) were most abundant in the basal and adjacent epithelial layers of the lesions adjacent to the stroma, especially in epithelial projections that seemed to invade the stroma. SP-A positive cuboid cells (Fig. 6C) showed a similar (basal) localization; the more inner and adluminal epithelial layers were almost unstained. The lesions arose from alveolar spaces that were lined by SP-A positive type II cells. The tumor area was not stained in immunohistochemical controls; occasional staining seen in the adjacent parenchyma was caused by the presence of macrophages in alveolar spaces (Fig. 6D).

Figure 7 illustrates the distribution of proliferation markers and type II cell markers in preneoplastic and neoplastic lesions as found in tumor-associated bronchi and their bronchiolar divisions. Similar (=predominately basal) staining patterns were observed in all the lesions, irrespective as to whether the lesions were of bronchial or bronchiolar origin. As shown below, bronchiolar lesions did not contain Clara cells, although these cells did occur in adjacent normal bronchiolar epithelial areas. The affected bronchiole shown (Fig. 7A) was located near the squamous cell carcinoma depicted in Figure 5A-D. One wall was lined with apparently normal bronchial epithelium consisting of columnar ciliated cells, columnar Clara cells and basal cells. The epithelium of the opposite wall was abnormal and had two different areas: one area, which is designated here by the term 'dysplastic focus', had basal hyperplasia and squamous metaplasia with mild to moderate atypia (on the right), whereas the other area had in situ and invasive carcinoma (on the left). The latter area also contained some apparently normal bronchial epithelial inclusions. The connective tissue surrounding the bronchiole displayed some inflammatory infiltrates and dust deposition. Immunohistochemistry revealed (Fig. 7B) that most PCNA reactivity was present in the abnormal epithelium of the lower bronchiolar wall, where it localized to the basal epithelial layer. PCNA reactivity was also seen in the connective tissue. After staining for CC10 (Fig. 7C), the columnar Clara cells present in the normal bronchial epithelium of the upper bronchiolar wall and in the lower wall (on the left) displayed a positive staining. The intra-epithelial and invasive lesions of the lower wall did not stain for CC10. By contrast, however, the intra-epithelial and invasive lesions of the lower wall did stain for SP-A (Fig. 7D). Both the dysplastic focus (on the right) and the in situ/ invasive carcinomatous area (on the left) contained SP-A positive cuboid cells. In both areas, the most consistent sites of their localization were the basal and adjacent epithelial layers, where also most PCNA reactivity was

found (cf. Fig. 7B). This suggested that the SP-A positive cuboid cells were (one of the) major proliferating cells of the lesions. The normal bronchial epithelium of the upper bronchiolar wall and the bronchial epithelial inclusions in the lower wall (on the left) were not stained. Linear staining found along the luminal surface was probably caused by retention of SP-A (secreted by the SP-A positive lesions into the bronchiolar lumen) among cilia or in epithelial ruffles. In addition, some staining was seen in cellular infiltrate (notably macrophages) in the adjacent connective tissue; otherwise, the connective tissue was not stained. Immunohistochemical controls were not stained except for macrophages. Figure 7E, which is derived from detailed light/ electron microscopic cell characterization studies in normal human lung (Ten Have-Opbroek et al., 1991; Plopper and Ten Have-Opbroek, 1994), illustrates the cellular localization of SP-A in the normal human pulmonary acinus. SP-A is highlighted here by alkaline phosphatase (=blue) labeling. As shown, normal bronchial epithelium consisting of columnar ciliated and columnar Clara cells and basal cells does not stain for SP-A, whereas cuboid type II cells lining distal bronchiolar areas and alveoli are SP-A positive (=blue). Macrophages may also show some SP-A (blue) staining.

Molecular characterization of reactive proteins recognized by anti SP-A in human tumor material

We characterized the antigenic determinants recognized by SALS-Hu in adenocarcinoma sections by Western blotting. As shown (Fig. 8), SALS-Hu recognized human SP-A (31 to 36 kD) and its dimeric form (62 to 72 kD) in bronchoalveolar lavage fluid (BALF) from patients with alveolar proteinosis (lane 1). The antiserum also identified the 29 kD SP-A precursor protein and 31 to 36 kD proteins of recombinant human SP-A (lane 2). SALS-Hu did not react to proteins in normal human serum (lane 4). SALS-Hu labeled proteins within the SP-A size classes in adenocarcinomas (lanes 3 and 5). Minor bands of lower sizes sometimes seen in BALF (lane 1; approx. 50 kD) and adenocarcinomas (lane 5) were probably caused by degradation products of SP-A in such pathologic material. In addition (lanes 3 and 5), the adenocarcinoma blots presented some protein bands below the 21 kD marker, which were also seen when preimmunization serum was used instead of SALS-Hu (lanes 7 and 9). SALS-Hu and preimmunization serum detected these nonspecific bands only in tumor homogenates but not in BALF (lane 6), recombinant human SP-A (lane 8) and normal human serum (lane 10). This suggested that such nonspecific bands were caused by blood cell proteins like hemoglobin.

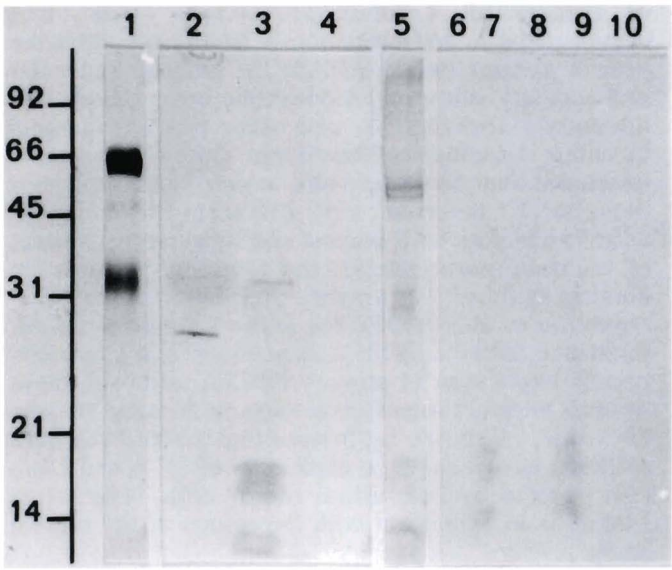

Fig. 8. Molecular characterization of SALS-Hu reactive proteins in human adenocarcinoma by Western blotting. The proteins were transferred electrophoretically to nitrocellulose paper and then incubated with SALS-Hu (rabbit anti-human SP-A serum 1:300, lanes 1-5) or preimmunization serum (normal rabbit serum 1:300, lanes 6-10) followed by horseradish peroxidase-conjugated swine anti-rabbit IgG (1:400; absorbed with human IgG). Lanes 1 and 6: bronchoalveolar lavage fluid (BALF) from alveolar proteinosis patients; lanes 2 and 8: recombinant human SP-A; lanes 3 and 7: adenocarcinoma (same tumor as in Figure 1); lanes 4 and 10: normal human serum; lanes 5 and 9: adenocarcinoma (same tumor as in Figure 4). Note that SALS-Hu labels human SP-A (31 to 36 kD) and its dimeric form (62 to 72 kD) in BALF (lane 1) and the 29 kD and 31 to 36 kD proteins of recombinant human SP-A (lane 2). SALS-Hu labels proteins within the SP-A size classes in adenocarcinomas (lanes 3 and 5). The bands seen below 21 kD are also found when preimmunization serum is used (lanes 7 and 9), and are thus nonspecific.

Discussion

Type II cells in human adenocarcinomas and squamous cell carcinomas

The present study has used a set of highly distinctive cell markers to detect alveolar type II cells in human adenocarcinomas and squamous cell carcinomas and in (pre)neoplastic lesions in bronchi and bronchioles, notably the approximately cuboid shape of the type II cell, its relatively large and roundish nucleus, its cytoplasmic staining for SP-A, and the presence of precursory or mature forms of multilamellar bodies in its cytoplasm (Ten Have-Opbroek, 1981, 1991; Ten Have-Opbroek et al., 1991; Ten Have-Opbroek and Plopper, 1992; Plopper and Ten Have-Opbroek, 1994). This set of phenotypic cell markers enables recognition of all mature and immature type II cells in foetal and adult mammalian lungs and in (pre)neoplastic lesions from human and canine bronchogenic carcinomas (reviewed in Ten Have-Opbroek et al., 1991, 1994b; Ten Have-Opbroek and Plopper, 1992). Some SP-A mRNA and protein studies of developing and adult lungs have assigned positive SP-A reactivity in bronchiolar epithelium to "Clara cells" without considering that this epithelium contains two categories of secretory cells,

namely columnar Clara cells (Clara, 1937) and cuboid alveolar type II cells (Ten Have-Opbroek et al., 1991; Plopper and Ten Have-Opbroek, 1994). These type II cells maintain the bronchiolar type II cell population in fetal and adult lungs and give rise to bronchiolar alveolar type I cells. Use of the afore-mentioned set of type II cell markers allows for an unequivocal distinction between type II cells and Clara cells (Ten Have-Opbroek et al., 1991). It is evident that SP-A is an excellent type II cell marker and more appropriate than, e.g., surfactant protein C because the expression of the latter protein is restricted to relatively mature type II cell populations in fetal and adult lungs (Ten Have-Opbroek and De Vries, 1993).

The light microscopic, ultrastructural and immunohistochemical data in this study demonstrate that cells with the type II phenotype are regular constituents of two major subsets of human bronchogenic carcinoma, namely adenocarcinomas and squamous cell carcinomas. Their abundance is often greater in the adenocarcinoma subset. The tumor type II cells lack any similarity to the other epithelial cells present in normal proximal and distal conducting airways, including ciliated, mucous and basal cells and the columnar cell type described by Clara (1937). Often, however, the cells look somewhat immature at the ultrastructural level. In this respect, they resemble type II cells present in fetal lungs (Otto-Verberne et al., 1988; Ten Have-Opbroek et al., 1988, 1990; Brandsma et al., 1993) and in distal bronchioles of adult lungs (Ten Have-Opbroek et al., 1991). That tumor type II cells may be immature is also suggested by the frequent finding of a peripheral instead of overall cytoplasmic staining for SP-A, a pattern seen in early fetal lungs (Ten Have-Opbroek and Plopper, 1992) and also reported for canine adenocarcinoma (Ten Have-Opbroek et al., 1993b, 1994b, 1996). However, this phenomenon may also be explained by abnormal secretory routes for SP-A in type II tumor cells. That type II cells in human adenocarcinomas actually contain SP-A protein and mRNA has been confirmed by Western blotting (present study; Tsutahara et al., 1993) and in situ hybridization (Broers et al., 1992).

Adenocarcinomas of the bronchioloalveolar and papillary subtypes display the highest incidence of type II tumor cells: these cells usually are the only or almost only epithelial cell type to occupy all the lesions. In other subtypes of adenocarcinoma and in squamous cell carcinoma, type II tumor cells are most consistently found in the basal epithelial layer of the lesions, where they occur singly or in rows, but they may be present in more central layers as well. That they would represent entrapped non-neoplastic type II cells is not very likely, in view of their consistent distribution pattern within the lesions. The presence of type II tumor cells may be restricted to a smaller (i.e., <50%) percentage of the lesions. In cases of a low incidence, type II cell positive neoplastic lesions seem to prevail near the tumor/normal bronchial and alveolar tissue interface where hyperplastic type II cell configurations are found. The type II phenotype is already detectable in early progressive lesions (i.e., dysplastic; in situ; microinvasive) which had arisen from tumor-associated bronchi and their bronchiolar divisions. Such newly differentiated type II cells show a predominately basal distribution in the lesions, irrespective as to whether the lesions are of bronchial or bronchiolar origin. As presently shown, Clara cells are not implicated in the genesis of bronchiolar lesions. All these findings suggest that type II tumor cells are involved in the genesis of human lung carcinoma and may come from both bronchial and alveolar sources (see further below and Fig. 9).

Our present finding that type II cells are regular constituents of two major subsets of human bronchogenic carcinoma, namely adenocarcinoma and squamous cell carcinoma, is in agreement with observations in humans and animal species (McDowell et al., 1978; Ten Have-Opbroek et al., 1990a, 1993b, 1994b, 1996; Linnoila et al., 1992a; Tsutahara et al., 1993). However, the SP-A immunoreactivity in the tumor sections found by other investigators was often mostly focal. In our study, a similar (more or less focal) SP-A staining was obtained in the tumor sections when use was made of anti-human recombinant SP-A (BGP), whereas application of SALS-Hu or other SP-A antibodies resulted in staining of almost all morphologically identifiable type II cells in the sections. As reported, SALS-Hu is far more sensitive than BGP (Ten Have-Opbroek et al., 1993b) and is highly suitable for detecting all morphologically identifiable but immature type II cells in fetal and adult lungs (Otto-Verberne et al., 1988; Ten Have-Opbroek et al., 1991; Ten Have-Opbroek and Plopper, 1992) and in adenocarcinomas (Ten Have-Opbroek et al., 1990a, 1993a,b, 1994a,b, 1996). In a study of 126 non-small cell lung carcinomas (NSCLC) in humans (Linnoila et al., 1992a), the highest incidence of (focal) SP-A immunoreactivity (50%) was demonstrated in adenocarcinomas having papillolepidic growth patterns (which include the bronchioloalveolar and papillary subtypes), followed by other subtypes of adenocarcinoma (31%) and other NSCLC subsets including squamous cell carcinoma (14%). The authors concluded that the finding of a marker characteristic of peripheral, alveolar cell differentiation in all adenocarcinomas is of interest and supports the concept of common pathogenesis for adenocarcinomas. In another study of 247 primary and metastatic NSCLC (Linnoila et al., 1992b), the authors found a similar incidence for (focal) SP-A expression and Clara cell protein expression in primary NSCLC, although these markers were not usually expressed by the same tumors. However, as shown by tumors that stained for both markers, there was no co-expression of SP-A and Clara cell protein by individual tumor cells. The latter finding is in agreement with the results of the present study.

Type II cells as pluripotential stem cells in the genesis of human adenocarcinomas and squamous cell carcinomas

Our data strongly suggest that the type II phenotype is a pluripotential stem cell (see Definitions) in the genesis of two major subsets of human bronchogenic carcinoma. Type II cells are the only or most predominant proliferating cells of invasive lesions with particular glandular (i.e., bronchioloalveolar; papillary) growth patterns and are at least one of the proliferating cell types of invasive lesions with other glandular or squamous growth patterns. Type II cells are already detectable in (pre)neoplastic lesions found in tumor-associated airways (see above). In both early and more advanced lesions, type II tumor stem cells usually predominate in the basal region near the connective tissue, which is compatible with cellular invasive potentials. In multilayered glandular and squamous lesions, type II progeny may occur in upper (more central) regions of the lesions as well. These observations suggest that type II cell proliferation takes place in both peripheral and central directions. However, as can be seen in multilayered glandular and squamous lesions, type II cells may also differentiate to apparently viable larger cells with more abundant cytoplasm that is (almost) devoid of reactivity to SP-A and may display other features (e.g., keratin deposits). Such larger cells occur exclusively in upper (more central) layers of the lesions. Our view that type II cells have the potentials to follow such variant differential pathways is supported by observations in the literature. Normal type II cells are capable of phenotypic squamous differentiation as has been demonstrated in in vitro studies (Oomen et al., 1990), studies of embryonic lung development in primates including humans (Otto-Verberne et al., 1988; Ten Have and Plopper, 1992) and other species (Adamson and Bowden, 1975; Ten Have-Opbroek, 1979, 1981, 1991; Ten Have-Opbroek and Plopper, 1992) and studies of alveolar epithelial regeneration in the adult lung (Evans et al., 1975). Evidence that type II cells are able to accumulate keratin comes from time studies in fetal monkey lungs (Chi et al., 1985). According to the latter studies, which have made use of electron microscopy and cytokeratin immunocytochemistry, differentiation and maturation of type II cells are related to intermediate filament expression. In older type II cells, the filaments may even form bundles or aggregates. Our present conclusion that the type II phenotype is a pluripotential stem cell in the genesis of human adenocarcinoma is fully supported by our studies in a canine bronchogenic carcinoma model (sub-cutaneous bronchial autografts exposed to carcinogen) (Ten Have-Opbroek et al., 1990a, 1993b, 1994b, 1996) and with our finding of type II tumor cell populations in serial canine adenocarcinoma transplants in nude mice (Ten Have-Opbroek et al., 1990a, 1993b).

Bronchial and alveolar origin of type II stem cells implicated in the genesis of human adenocarcinomas and squamous cell carcinomas; oncofetal mechanism of differentiation

The question regarding the cellular origin of type II tumor stem cells is interesting and important. A potential source for such cells is of course the normal type II cell population existing in the lung parenchyma. However, as suggested by our present findings, carcinogen-exposed epithelium of conducting airways may represent another source. Our studies of canine bronchial carcinogenesis (Ten Have-Opbroek et al., 1990a, 1993b, 1994b, 1996) provide strong support for the latter option. These studies show that potential type II tumor stem cells, which may give rise to intra-epithelial and invasive type II cell lesions (Ten Have-Opbroek et al., 1996), can be induced in normal epithelium of major bronchi by exposure to 3-methylcholanthrene (Hammond et al., 1986; Derrick et al., 1988). Tobacco smoke, a major agent in human bronchial carcinogenesis, contains numerous carcinogens including polycyclic aromatic hydrocarbon compounds of which 3-methylcholanthrene is an example. In both humans (present study) and dogs (Ten Have-Opbroek et al., 1996), proliferating type II cells are detectable in transformed bronchial epithelium as soon as it is slightly abnormal (i.e., basal hyperplasia and squamous metaplasia with mild or moderate atypia). In the embryo, type II cells originate from undifferentiated primordial epithelium but never from earmarked bronchial epithelium (Ten Have-Opbroek 1979, 1981). Evidence that undifferentiated primordial cells exist in the epithelium of larger airways after birth is not available (Ten Have-Opbroek, 1981). In view of these data and present insights into embryonic lung differentiation (Ten Have-Opbroek, 1981, 1991; Ten Have-Opbroek and Plopper, 1992), we have postulated that neoplastic progression for adenocarcinoma development in conducting airways (Ten Have-Opbroek et al., 1994b, 1996) may start with local retro-differentiation of existing normal bronchial epithelial cells such as mucous or basal cells, which results in the appearance of more or less undifferentiated (primordial-like) cells of origin. Differentiation of type II tumor stem cells from such cells of origin may occur by activation of genes that regulate type II cell expression but were repressed in utero in earmarked bronchial cells, a phenomenon not unlike the appearance of alpha fetoprotein in liver cancer. In view of their way of induction (i.e., by carcinogen exposure) and depending on other (growth, genetic, environmental) factors, type II tumor stem cells very probably give rise to type II cell clones that display significant variations in growth and differentiation potentials.

A diagram illustrating the bronchial and alveolar origin of type II tumor stem cells and depicting a common developmental pathway for adenocarcinoma and squamous cell carcinoma (see below) is provided in Figure 9.

Common developmental pathway for human adenocarcinomas and squamous cell carcinomas

Bronchioloalveolar and papillary adenocarcinomas are sometimes considered (Linnoila et al., 1992a) as a separate group of bronchogenic carcinoma. They are thought to arise from peripheral airways and to be the result of so-called lepidic growth, i.e, growth of tumor cells along existing air spaces. The present study provides some evidence that bronchioloalveolar and papillary adenocarcinomas may originate from (peripherally or centrally induced) type II tumor stem cells but that they share this stem cell with other adenocarcinomas and squamous cell carcinomas. Based upon this new knowledge of a common (=type II) stem cell and embryologic insight into type II cell behaviour (Ten Have-Opbroek, 1979, 1981, 1991; Ten Have-Opbroek and Plopper, 1992) and differential potentials (see above), it seems very likely that there is a common oncofetal pathway for the genesis of all adenocarcinomas and squamous cell carcinomas. In normal mammalian lung morphogenesis, type II cells have an enormous growth and morphogenetic potential. They protrude into the mesenchyme of the developing lung, design the architecture of the pulmonary acinus with its tubular and alveolar components, generate squamous type I cells, and also maintain the parenchyma in adulthood (Ten Have-Opbroek, 1979, 1981, 1991; Ten Have-Opbroek and Plopper, 1992). In canine bronchial carcinogenesis type II tumor stem cells give rise to an active yet stable progeny with an apparently high and diverse growth and morphogenetic potential (Ten Have-Opbroek et al., 1996). Based upon these findings in dogs and our present observations in humans, we postulate

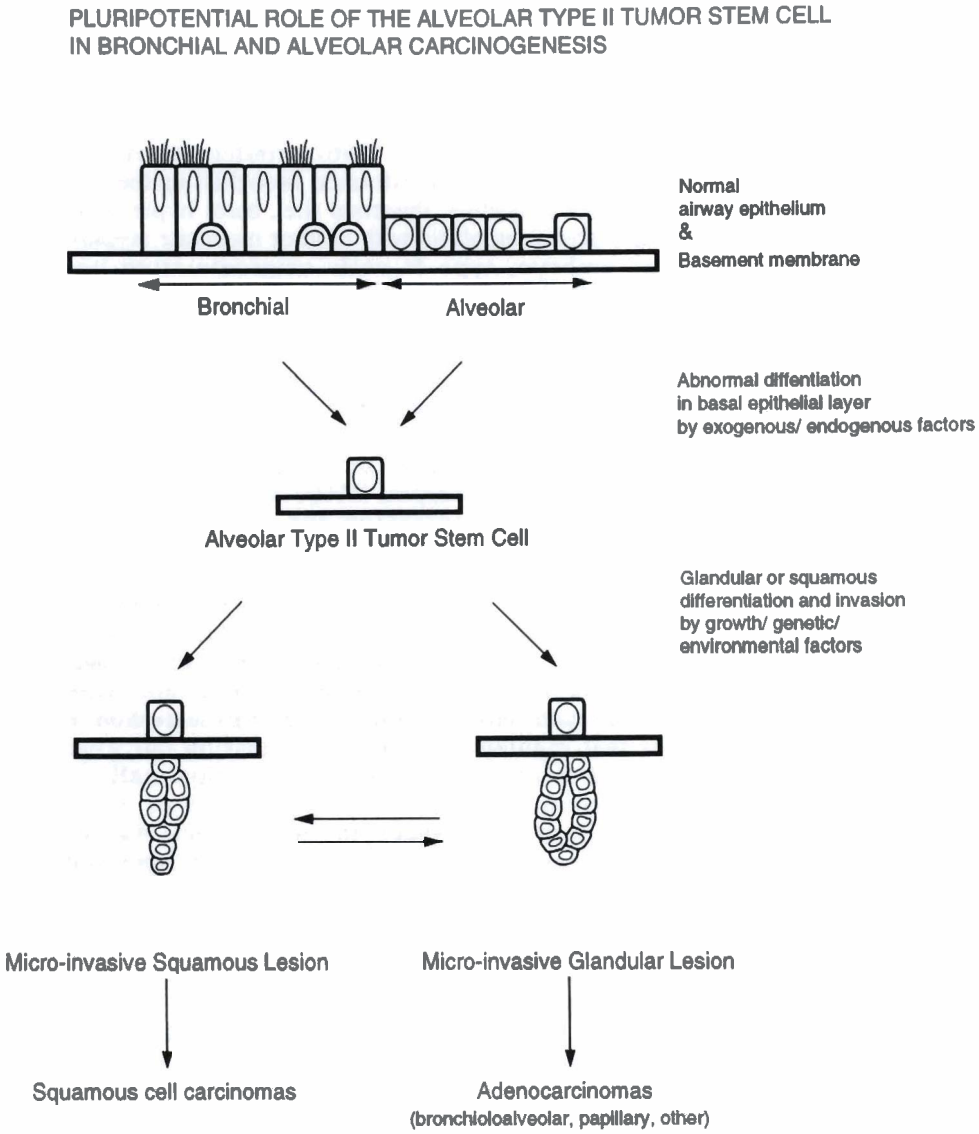

Fig. 9. Diagram illustrating the pluripotential role of the alveolar type II tumor stem cell in bronchial and alveolar carcinogenesis. The postulated developmental pathway for two major subsets of bronchogenic carcinoma is based upon our findings in humans and in a canine model (see text).

(Fig. 9) that type II tumor stem cells, irrespective of their alveolar or bronchial origin, may invade the surrounding connective tissue and attempt to form new structures in an embryonic fashion. As illustrated (Fig. 9), the primary structure formed may in principle be a micro-invasive glandular lesion or a micro-invasive squamous lesion. The architecture of the mature lesions suggests that the efforts of type II cells to mimick embryonic lung development are most succesful in adenocarcinomas of the bronchioloalveolar subtype. In other subtypes and in squamous cell carcinoma, the cells apparently do not succeed in producing structures other than tubules, cords, and/or fields.

Very likely, the rates of proliferation, differentiation, and slough of type II tumor stem cells and their descendants are responsible for the final appearance of the glandular and squamous lesions. That type II tumor stem cells probably belong to different clones (see above) may contribute to the histologic complexity and diversity of the tumors. The present study certainly does not exclude that also unrelated clones - e.g., those produced by potential tumor stem cells like mucous and basal cells and possibly also by neuroendocrine cells (McDowell, 1987; Nasiell et al., 1987) or spontaneously differentiated novel cell types (Doherty et al., 1995) - could contribute to such pattern formation. This would result in the occurrence of a mixed type of tumor. If in the latter case the tumor progenitor cells involved also display mixed cell properties, there may even be a broad mix of partially differentiated epithelial cells within a single tumor. Further characterization of the cells of origin and stem cell clones implicated in human bronchial and alveolar carcinogenesis is needed to answer these questions. Xenograft models of proximal airways, which are highly suitable for such studies, are available (Benfield and Hammond, 1992; Zepeda et al., 1995).

We speculate that the influence of non-specific factors (e.g., aging; change of nutrients by poor vascularization) on type II tumor stem cells and their cell lineages may contribute to the development of (predominately) squamous cell carcinoma instead of adenocarcinoma, a phenomenon not unlike the appearance of squamous cells in type II cell cultures (Oomen et al., 1990). Studies in a lung-tumor transplantation system in the mouse (Williams and Nettesheim, 1973) show that squamous cell carcinomas may transform to tumors composed of large, undifferentiated cells with little or no evidence of keratinization (=retrodifferentiation to primordial-like cells of origin? See above). At 3 weeks and beyond, the center of these tumors may differentiate to "acinar" structures (=composed of type II tumor cells?), many of which show squamous cell differentiation and signs of keratinization. Although we fully recognize that much more evidence is required, these as well as other findings discussed in the sections above support our view that there is such a common cell-biological pathway for adenocarcinoma and squamous cell carcinoma development as shown in Figure 9.

In summary, our findings strongly suggest that the alveolar type II phenotype is a pluripotential stem cell type in the genesis of two major subsets of human bronchogenic carcinoma, namely adenocarcinoma and squamous cell carcinoma. However, further investigation of type II (and possibly other) stem cell clones involved is required to prove this conclusion incontrovertibly. Based upon our present study in humans and previous studies in a canine model (Ten Have-Opbroek et al., 1990a, 1993b, 1994b, 1996), we postulate that the type II tumor stem cells may originate from one of two sources: (1) the originally existing epithelium of conducting airways by an oncofetal mechanism (i.e., bronchial epithelial retrodifferentiation followed by novel type II cell differentiation) (Ten Have-Opbroek et al., 1994b, 1996); and (2) normal alveolar type II cells present in the lung parenchyma.

Acknowledgements. The authors thank Joost Boex (Dept. of Pneumology, Leiden University, The Netherlands) and Jeremy Johnson (Dept. of Surgery, Univ. of California Davis, USA) for their excellent technical assistance.

References

Adamson I.Y.R. and Bowden D.H. (1975). Derivation of type I epithelium from type 2 cells in the developing rat lung. Lab. Invest. 32, 736-745.

Benfield J.R. and Hammond W.G. (1992). Bronchial and pulmonary carcinogenesis at focal sites in dogs and hamsters. Cancer Res. (suppl) 52, 2687s-2693s.

Brandsma A.E., Tibboel D., Vulto I.M., Egberts J. and Ten Have-Opbroek A.A.W. (1993). Ultrastructural features of alveolar epithelial cells in the late fetal pulmonary acinus. A comparison between normal and hypoplastic lungs, using a rat model of pulmonary hypoplasia and congenital diaphragmatic hernia. Microsc. Res. Techn. 26, 389-399.

Broers J.L.V., Jensen S.M., Travis W.D., Pass H., Whitsett J.A., Singh G., Katyal S.L., Gazdar A.F., Minna J.D. and Linnoila R.I. (1992). Expression of surfactant associated protein-A and Clara cell 10 kilodalton mRNA in neoplastic and non-neoplastic human lung tissue as detected by in situ hybridization. Lab. Invest. 66, 337-346.

Chi E.Y., Gown A.M., Vogel A.M. and Teh E.C. (1985). Intermediate filaments in the developing type II cell of fetal monkey lung. J. Histochem. Cytochem. 33, 161-168.

Clara M. (1937). Zur Histobiologie des Bronchalepithels. Z. Mikrosk. Anat. Forsch. 41, 321-347.

Derrick M.J., Hammond W.G., Pak H.Y., Azumi N., Smith S.S. and Benfield J.R. (1988). Non-small cell lung cancer in autogenous subcutaneous bronchial grafts in dogs. J. Thorac. Cardiovasc. Surg. 95, 562-571.

Doherty M.M., Liu J., Randell S.H., Carter C.A., Davis C.W., Nettesheim P. and Ferriola P.C. (1995). Phenotype and differentiation potential of a novel rat tracheal epithelial line. Am. J. Respir. Cell Mol. Biol. 12, 385-395.

Evans M.J., Cabral L.J., Stephens R.J. and Freeman G. (1975). Transformation of alveolar type 2 cells to type I cells following exposure to NO_2. Exp. Mol. Pathol. 22, 142-150.

Hammond W.G., Benfield J.R., Paladugu R.R., Azumi N., Pak H.Y. and Teplitz R.L. (1986). Carcinogenesis in heterotopic respiratory epithelium in canine subcutaneous bronchial autografts. Cancer Res. 46, 2995-2999.

Laemmli N.K. and Favre M. (1973). Maturation of the head of bacteriophage T4. I. DNA packaging events. J. Mol. Biol. 80, 575-590.

Linnoila R.I., Mulshine J.L., Steinberg S.M. and Gazdar A.F. (1992a). Expression of surfactant-associated protein in non-small-cell lung cancer: A discriminant between biologic subsets. J. Natl. Cancer Inst. Monogr. 13, 61-66.

Linnoila R.I., Jensen S.M., Steinberg S.M., Mulshine J.L., Eggleston J.C. and Gazdar A.F. (1992b). Peripheral airway cell marker expression in non-small cell lung carcinoma. Association with distinct clinicopathologic features. Am. J. Clin. Pathol. 97, 233-243.

McDowell E.M. (1987). Bronchogenic carcinomas. In: Lung carcinomas. McDowell E.M. (ed). Churchill Livingstone. Edinburgh, London, Melbourne, New York. pp 255-285.

McDowell E.M., McLaughlin J.S., Merenyl D.K., Kieffer R.F., Harris C.C. and Trump B.F. (1978). The respiratory epithelium. V. Histogenesis of lung carcinomas in the human. J. Natl. Cancer Inst. 61, 587-606.

Nasiell M., Auer G. and Kato H. (1987). Cytological studies in man and animals on development of bronchogenic carcinoma. In: Lung carcinomas. McDowell E.M. (ed). Churchill Livingstone. Edinburgh, London, Melbourne, New York. pp 207-242.

Oomen L.C.J.M., Ten Have-Opbroek A.A.W., Hageman Ph.C., Oudshoorn-Snoek M., Egberts J., Van der Valk M.A., Calafat J. and Demant P. (1990). Fetal mouse alveolar type II cells in culture express several type II cell characteristics found in vivo, together with major histocompatibility antigens. Am. J. Respir. Cell Mol. Biol. 3, 325-339.

Otto-Verberne C.J.M., Ten Have-Opbroek A.A.W., Balkema J.J. and Franken C. (1988). Detection of the type II cell or its precursor before week 20 of human gestation, using antibodies against surfactant-associated proteins. Anat. Embryol. 178, 29-39.

Otto-Verberne C.J.M., Ten Have-Opbroek A.A.W. and De Vries E.C.P. (1990). Expression of the major surfactant-associated protein, SP-A, in type II cells of human lung before 20 weeks of gestation. Eur. J. Cell Biol. 53, 13-19.

Plopper C.G. and Ten Have-Opbroek A.A.W. (1994). Anatomical and histological classification of bronchioles. In: Diseases of the bronchioles. Epler G.R. (ed). Raven Press. New York. pp 15-25.

Shi S.R., Key M.E. and Kalra K.L. (1991). Antigen retrieval in formalin-fixed, paraffin-embedded tissues: An enhancement method for immunohistochemical staining based on microwave oven heating of tissue sections. J. Histochem. Cytochem. 39, 741-748.

Ten Have-Opbroek A.A.W. (1979). Immunological study of lung development in the mouse embryo. II. First appearance of the great alveolar cell, as shown by immunofluorescence microscopy. Dev. Biol. 69, 408-423.

Ten Have-Opbroek A.A.W. (1981). The development of the lung in mammals: An analysis of concepts and findings. Am. J. Anat. 162, 201-219.

Ten Have-Opbroek A.A.W. (1991). Invited review. Lung development in the mouse embryo. Exp. Lung Res. 17, 111-130.

Ten Have-Opbroek A.A.W. and De Vries ECP (1993). Clara cell differentiation in the mouse: Ultrastructural morphology and cytochemistry for surfactant protein A and Clara cell 10 kD protein. Microsc. Res. Techn. 26, 400-411.

Ten Have-Opbroek A.A.W. and Plopper C.G. (1992). Morphogenetic and functional activity of type II cells in early fetal Rhesus monkey lungs. A comparison between primates and rodents. Anat. Rec. 234, 93-104.

Ten Have-Opbroek A.A.W., Dubbeldam J.A. and Otto-Verberne C.J.M. (1988). Ultrastructural features of type II alveolar epithelial cells in early embryonic mouse lung. Anat. Rec. 221, 846-853.

Ten Have-Opbroek A.A.W., Hammond W.G. and Benfield J.R. (1990a). Bronchiolo-alveolar regions in adenocarcinoma arising from canine segmental bronchus. Cancer Lett. 55, 177-182.

Ten Have-Opbroek A.A.W., Otto-Verberne C.J.M. and Dubbeldam J.A. (1990b). Ultrastructural characteristics of inclusion bodies of type II cells in late embryonic mouse lung. Anat. Embryol. 181, 317-323.

Ten Have-Opbroek A.A.W., Otto-Verberne C.J.M., Dubbeldam J.A. and Dijkman J.H. (1991). The proximal border of the human respiratory unit, as shown by scanning and transmission electron microscopy and light microscopical cytochemistry. Anat. Rec. 229, 339-354.

Ten Have-Opbroek A.A.W., Dijkman J.H., Van Krieken J.H.J.H., Boex J.J.M., Hammond W.G. and Benfield J.R. (1993a). The presence of alveolar type II cells in human bronchogenic carcinoma. Am. Rev. Respir. Dis. 147 (suppl), A158.

Ten Have-Opbroek A.A.W., Hammond W.G., Benfield J.R., Teplitz R.L. and Dijkman J.H. (1993b). Expression of alveolar type II cell markers in acinar adenocarcinomas and adenoid-cystic carcinomas arising from segmental bronchi. A study in a heterotopic bronchogenic carcinoma model in dogs. Am. J. Pathol. 142, 1251-1264.

Ten Have-Opbroek A.A.W., Hammond W.G., Benfield J.R., Teplitz R.L. and Dijkman J.H. (1994a). Localization of the tumor stem cell area in developing and overt bronchogenic carcinomas (dogs, humans). Am. J. Respir. Crit. Care Med. 149 (suppl), A713.

Ten Have-Opbroek A.A.W., Benfield J.R., Hammond W.G., Teplitz R.L. and Dijkman J.H. (1994b). In favour of an oncofoetal concept of bronchogenic carcinoma development. Histol. Histopathol. 9, 375-384 (Review).

Ten Have-Opbroek A.A.W., Benfield J.R., Hammond W.G. and Dijkman J.H. (1996). Alveolar stem cells in canine bronchial carcinogenesis. Cancer Lett. 101, 211-217.

The World Health Organization histological typing of lung tumours (1982). 2nd ed. Am. J. Clin. Pathol. 77, 123-136.

Tsutahara S., Shijubo N., Hirasawa M., Honda Y., Satoh M., Kuroki Y. and Akino T. (1993). Lung adenocarcinoma with type II pneumocyte characteristics. Eur. Respir. J. 6, 135-137.

Van Hemert F.J., Ten Have-Opbroek A.A.W. and Otto-Verberne C.J.M. (1986). Histochemical characterization of an antigen specific for the great alveolar cell in the mouse lung. Histochemistry 85, 497-504.

Voss T., Eistetter H., Schäfer K.P. and Engel J. (1988). Macromolecular organization of natural and recombinant lung surfactant protein SP 28-36. J. Mol. Biol. 201, 219-227.

Williams M.L. and Nettesheim P. (1973). Lung colony assay with a squamous cell carcinoma derived from the respiratory tract of mice. J. Natl. Cancer Inst. 51, 1513-1520.

Yu C.C.W., Woods A.L. and Levison D.A. (1992). The assessment of cellular proliferation by immunohistochemistry: a review of currently available methods and their applications. Histochem. J. 24, 121-131.

Zepeda M.L., Chinoy M.R. and Wilson J.M, (1995). Characterization of stem cells in human airway capable of reconstituting a fully differentiated bronchial epithelium. Somat. Cell Mol. Genet. 21, 61-73.

Accepted September 23, 1996