

Endotheliitis-like changes in chronic hepatitis C

J. Lory and A. Zimmermann

Institute of Pathology of the University, Berne, Switzerland

Summary. Liver biopsies in hepatitis C frequently show bile duct damage, lymphoid follicles, large and small droplet fat, hepatocyte multinucleation, Mallory body-like material, and activation of sinusoidal inflammatory cells. Even though these lesions are useful parameters in the diagnosis of hepatitis C, their specificity remains uncertain.

Endotheliitis-like changes of small portal veins have been described for various liver diseases, including viral hepatitis. The aim of the present study was to investigate the prevalence and severity of endotheliitis-like changes in chronic hepatitis C in comparison with chronic hepatitis B. For this purpose, liver biopsies of 50 patients with chronic hepatitis C and 48 patients with chronic hepatitis B were systematically analyzed for the presence of endotheliitis-like changes. Endotheliitis-like changes were defined as lymphocytic infiltration of venous walls, subendothelial lymphocyte accumulation, adherence of lymphocytes to the endothelium, and endothelial cell damage. Endotheliitis-like change severity was graded (borderline/questionable; slight to moderate; severe), and endotheliitis-like changes were analyzed in small portal veins and in central veins. Endotheliitis-like changes were significantly more frequent in chronic hepatitis C than in chronic hepatitis B (41.5% vs. 6.9%; $p < 0.05$).

In chronic hepatitis C, endotheliitis-like changes predominated in small portal veins, but 27% of small hepatic veins were involved as well. The findings indicate that endotheliitis-like changes may represent a useful histological parameter in the diagnosis of chronic hepatitis C.

Key words: Endotheliitis, Chronic hepatitis, HCV infection

Introduction

The histopathology of chronic hepatitis (CH) due to hepatitis C viral infection (CH-C) has been described repeatedly in the last years. Its morphological features

range from mild lobular inflammation, e.g. as seen in asymptomatic hepatitis C virus (HCV)-positive blood donors, to cirrhosis (Dienes et al., 1982; Bianchi et al., 1987; Lefkowitz and Apfelbaum, 1989; Bach et al., 1992; Gerber et al., 1992; Scheuer et al., 1992; Lefkowitz et al., 1993; McMahon et al., 1994). Hepatic changes described in HCV infection include bile duct damage, lymphoid follicles in portal tracts, large- and small-droplet fatty change, Mallory body-like material in hepatocytes, multinucleation and dysplasia of liver cells, and activation of the littoral cell compartment. It has recently been demonstrated that small bile duct anomalies and lymphoid aggregates/follicles in portal tracts, particularly in combination, strongly suggest the diagnosis of CH-C (Gerber et al., 1992; Hino et al., 1992; Mosnier et al., 1993) and, in a multicenter study comparing CH-C and CH-B, four histological lesions (bile duct damage; lymphoid follicles and/or aggregates; large-droplet fat; Mallory body-like material) were found to be useful pathological parameters in the diagnosis of liver disease caused by HCV. Therefore, the histomorphology of the liver in CH-C is different from CH due to other causes to a degree allowing for its diagnosis in biopsies with considerable probability. However, more histological criteria may be needed to further condense differential diagnosis in a given case, in addition to the detection of HCV-associated antigens and/or HCV-RNA in liver tissue.

Endothelialitis (or endotheliitis; EN) has been considered to be a hallmark of acute liver transplant rejection and graft-versus-host disease (Ludwig et al., 1989). However, it has been reported that EN can occur in a variety of liver diseases with a varying incidence and activity, including acute hepatitis, chronic hepatitis, liver cirrhosis, primary biliary cirrhosis, and infectious mononucleosis (Nomomura et al., 1991). Based on these observations we were prompted to systematically analyze the prevalence of endotheliitis-like changes (ELC) in a comparative retrospective study on liver biopsies of patients with CH-C or CH-B.

Materials and methods

Patients

Liver biopsies were obtained from 70 patients with

Offprint requests to: Dr. Arthur Zimmermann, M.D., Professor of Pathology, Institute of Pathology of the University, Murtenstrasse 31, CH-3010 Berne, Switzerland

either CH-C (N=50) or CH-B (N=20) during the period from 1987 to 1993. Patients were clinically well-defined and participated in interferon trials. Those with CH-C were all positive for the new generation of HCV antibody tests and part of them were tested and positive for HCV-RNA. Biopsies analyzed in the present study were taken before any treatment was given.

Biopsy preparation for light microscopy

For light microscopy, tissue was fixed in 4% neutral-buffered formalin, embedded in paraffin, and processed for 5 μ m sections. Staining was effected with hematoxylin-eosin, Van Gieson's, reticulin, PAS, and iron stains.

Histopathological evaluation and grading of lesions

Fatty change was evaluated for the macrovesicular type only, and graded on the basis of parenchymal surface involved: Grade 0, fatty change lacking or questionable; grade 1, about 10% of surface involved; grade 2, about 10-30% surface involved; grade 3, more than about a third of surface involved.

Portal tract inflammation was graded in accordance with a system previously reported (Schmid et al., 1994): Grade 0, none; grade 1, mild, sprinkling of inflammatory cells in less than 1/3 of portal tracts; grade 2, moderate, numerous inflammatory cells in 1/3 to 2/3 of portal tracts; grade 3, severe, dense inflammatory infiltrate in more than 2/3 of portal tracts.

Lymphoid aggregates/follicles in portal tracts, were evaluated with respect to their frequency and their estimated size: Grade 0, no aggregates/follicles; grade 1, small aggregates/follicles involving less than 50% of the portal tract surface; grade 2, large follicles involving more than 50% of the portal tract surface; grade 3, as 1 or 2, but with germinal center formation.

For the assessment of piecemeal necrosis (PMN; interface lesions) grading was accomplished based on the fraction of portal tract circumference involved, on the involvement of septa in addition to portal tracts, and on the presence or absence of bridging: Grade 0, none; grade 1, minimal, one or few tongues in single portal tracts; grade 2, moderate, PMN involving less than 50% of portal tract circumference of most portal tracts; grade 3, marked, PMN involving more than 50% of circumference of most portal tracts; grade 4, severe, as in grade 3 plus septal PMN; grade 5, portal-portal bridging by PMN.

The evaluation of bile duct lesions (Poulsen and Christoffersen, 1969; Portmann and McSween, 1987; Vyberg, 1993) was based on the presence of easily detectable epithelial changes: Grade 0, no bile duct lesions; grade 1, vacuolization of epithelial cells and/or irregular arrangement of biliary nuclei in a minority of interlobular bile ducts; grade 2, focal necrosis of bile duct epithelia; grade 3, focal complete destruction of bile

ducts.

The amount of small bile duct proliferation (ductular proliferations, usually occurring together with fibrosis) was assessed based on a previously published proposal (Zhao et al., 1993): Grade 0, none or questionable; grade 1, a few proliferations in less than 50% of portal tracts; grade 2, proliferations easily recognizable in most portal tracts; grade 3, as grade 2 plus involvement of peripheral parts of lobules; grade 4, numerous proliferations involving portal tracts and lobules and extending along fibrous septa.

For grading hepatic fibrosis and cirrhosis, the scoring system as proposed by Knodell et al. (1981) was employed, with some modifications. Grades were defined as follows: 0, no fibrosis; 1, mild, portal tracts only; 2, portal tract fibrosis plus incomplete septa; 3, complete septa bridging portal-portal; 4, complete septa bridging portal-central, or focal incomplete cirrhosis; 5, diffuse incomplete or focal complete cirrhosis; 6, diffuse complete cirrhosis. Non-cirrhotic stage of liver disease therefore includes grades 0 to 3, incomplete cirrhosis 4 and 5, and complete cirrhosis grade 6 exclusively.

In acute hepatic allograft rejection, endotheliitis (EN; synonym: endothelialitis; SNOMED T 4803 in T 56-M 156, M 4-F 4411) is defined as adherence of immunocytes to the allogeneic endothelium or portal or hepatic vein branches. The immunocytes may also be found underneath the damaged endothelium or throughout the entire thickness of the wall (Ludwig, 1992). As a working formulation, we used the term, endotheliitis-like changes (ELC) and submitted ELC to grading in order to cover the whole morphological spectrum of questionable, incipient, and fully developed ELC, as follows: Grade 0, none; grade 1, borderline, i.e. spilling over of a few lymphocytes into venous walls and/or accumulation of occasional lymphocytes in the subendothelial space; grade 2, slight to moderate ELC, i.e. infiltration of venous walls and accumulation of lymphocytes in the subendothelial space are easily recognized, and round cells adhering to the endothelium are regularly found; in addition, endothelium may be visibly damaged; grade 3, as with grade 2, but wall infiltration is heavy, associated with heaping up of cells and sloughing of endothelial cells. ELC were separately analyzed in small portal vein radicles and in central and sublobular veins. For estimating the frequency of ELC, events (X) of ELC of a given grade per number of vein (Y) represented in the biopsy were calculated (X/Y), and involvement expressed as percent.

Statistics

Comparison between the two groups analyzed (CH-C vs. CH-B) was performed using a nonparametric Kruskal test. $P < 0.05$ was accepted as the level of statistical significance.

Endotheliitis in chronic hepatitis C

Table 1. Hepatic histopathology in CH-C and CH-B.

	NCL	IC	CC	MFC*	PTI*	PMN*
A) CH-C N=50	78%	20%	2%	0: 48% 1: 46% 2: 6% 3: 0%	0: 0% 1: 0% 2: 6% 3: 94%	0: 0% 1: 14% 2: 44% 3: 16% 4: 26% 5: 0%
B) CH-B N=48	91.7%	8.3%	0%	0: 54.2% 1: 41.7% 2: 2.1% 3: 2.1%	0: 0% 1: 6.2% 2: 29.2% 3: 64.6%	0: 4.2% 1: 41.7% 2: 27.1% 3: 10.4% 4: 16.7% 5: 0%

*: percentages given per grade (grades 0-3 or 0-5, respectively). For the criteria of grading, see Materials and methods. NCL: non-cirrhotic liver; IC: incomplete cirrhosis; CC: complete cirrhosis; MFC: macrovesicular fatty change; PTI: portal tract inflammation; PMN: piecemeal necrosis.

Results

General histological characterization of biopsies

Histological stage (non-cirrhotic liver, incomplete cirrhosis, complete cirrhosis) and the prevalence of macrovesicular fatty change, portal tract inflammation, piecemeal necrosis, bile duct changes and lymphoid follicles are listed in Tables 1-3 for CH-C and CH-B, respectively. It is seen that septal fibrosis associated with nodular change was more frequent in the group with CH-C, incomplete cirrhosis being observed more than twice as frequently in CH-C as in CH-B, and complete cirrhosis was found in CH-C only, albeit at a low frequency (2%). Low-degree macrovesicular fatty change of hepatocytes (grade 1) was encountered almost as frequently in CH-B as in CH-C; grade 2 was a little more frequent in CH-C, whereas a severe fatty change was seen in very few cases of CH-B only (2%). Even in

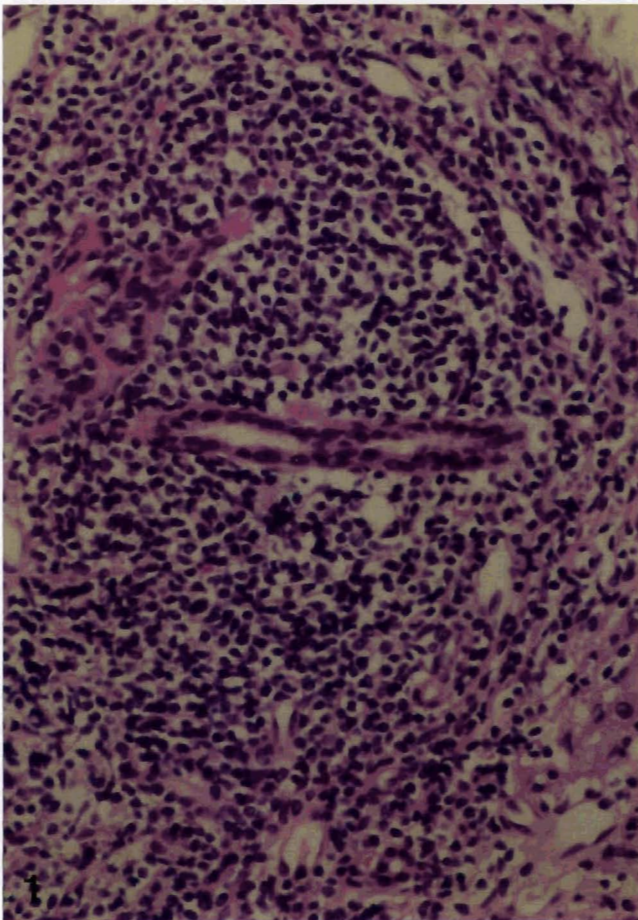


Fig. 1. Example of a typical lymphoid follicle located in a portal tract in chronic hepatitis C. Small lymphocytes forming the follicular structure are centered around a small bile duct. H&E stain, x 180

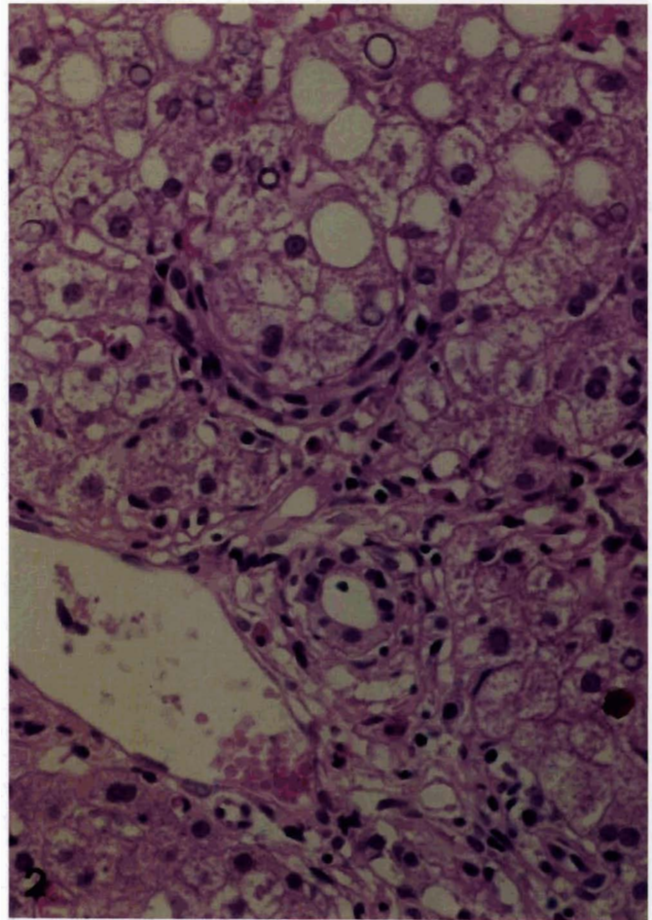


Fig. 2. Control situation. Portal tract of a liver biopsy with signs of a slight chronic hepatitis (HCV infection). Note that the small portal vein branch is morphologically normal, with thin endothelium and lack of cellular infiltration. H&E, x 240

Endotheliitis in chronic hepatitis C

biopsies exhibiting more advanced fatty change, no ballooning of hepatocytes, or perisinusoidal, lattice-like fibrosis were observed, suggesting that grade 2 and grade 3 fatty change is probably not due to florid alcoholic liver damage in this material. As seen in table 1, the majority of CH-C and CH-B biopsies exhibited advanced inflammatory changes in portal tracts. Moderate to marked piecemeal necrosis (grades 3 and 4) showed a similar frequency of distribution in CH-C and CH-B, whereas minimal PMN was much more frequently encountered in the cases with CH-B. No portal-portal bridges by PMN were seen in this material. The higher overall activity of hepatitis, based on the severity of both the extent of inflammatory change and of PMN in CH-C, appears to parallel the higher prevalence of incomplete and complete cirrhotic change, and the more advanced fibrosis in this group. Minor alterations of small bile duct epithelia (grade 1), which, in conventional tissue sections may be subject to interpretation bias due to artifacts, showed almost the

same prevalence for CH-C and CH-B. In contrast, bona fide bile duct damage was significantly more frequent in CH-C, bile duct destruction being observed in CH-C only, albeit at low frequency (4%; Table 2).

Lymphoid aggregates/follicles were significantly more frequently encountered in CH-C biopsies (Fig. 1; Table 3). Small lymphocytic aggregates occurred in 20.8% of cases with CH-B, but larger

Table 2. Bile duct lesions.

GRADE	0	1	2	3
CH-C	7 (14%)	29 (58%)	12 (24%)	2 (4%)
CH-B	19 (39.6%)	28 (58.3%)	1 (2.1%)	0

Grade 0: no bile duct lesions; grade 1: vacuolization and/or irregular arrangement of duct cells; grade 2: focal and slight loss of duct cells; grade 3: severe loss or necrosis of duct cells.

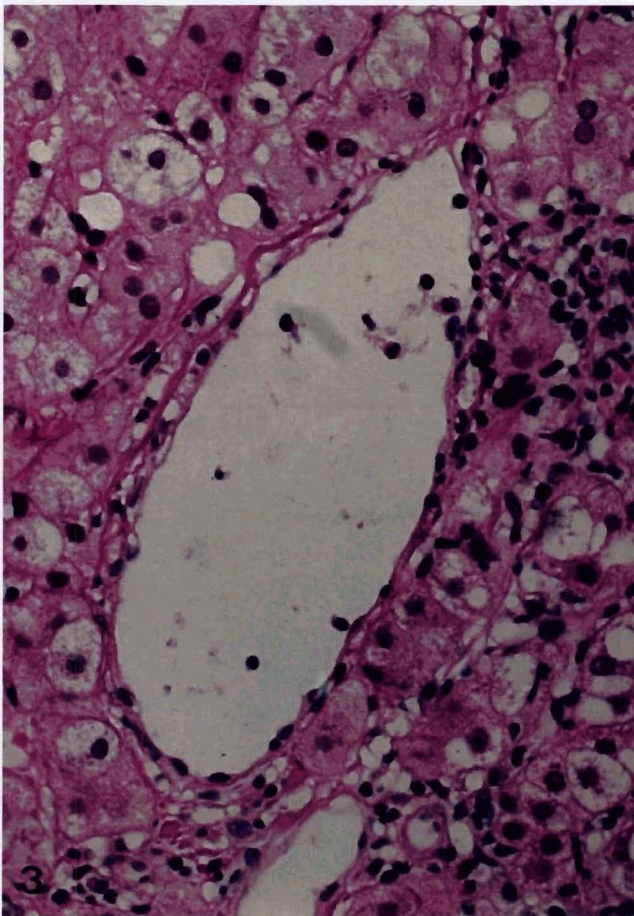


Fig. 3. Borderline endotheliitis-like change (grade 1). There is focal spilling over of a few lymphocytes into the venous wall, and there are a few lymphocytes in the subendothelial space. H&E. x 180

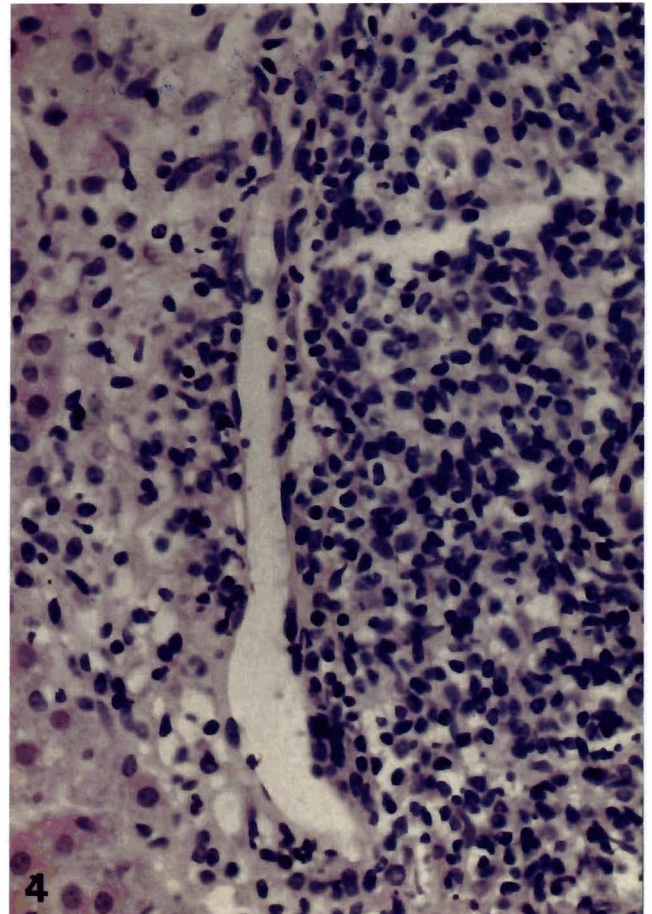


Fig. 4. Endotheliitis-like change, grade 2. The wall of the small portal vein branch shows focal infiltration by lymphocytes in the subendothelial space and, in addition, there is focal damage of endothelium with activation and heaping up of endothelial cells. Note that a lymphoid follicle is bulging into the vein. H&E. x 240

Endotheliitis in chronic hepatitis C

aggregates or follicles sometimes bulging into small portal vein branches, were exceedingly rare in CH-B (2.1%), but amounted to 34% in CH-C biopsies, 8% of them showing follicles with germinal centers.

Endotheliitis-like changes (ELC)

A normal portal vein branch and the three grades of ELC registered in the present study are illustrated in

Table 3. Lymphoid aggregates/follicles in portal tracts.

GRADE	0	1	2	3
CH-C	15 (30%)	18 (36%)	13 (26%)	4 (8%)
CH-B	37 (77.1%)	10 (20.8%)	1 (2.1%)	0

Grade 0: no aggregates/follicles; grade 1: small aggregates/follicles; grade 2: large aggregates/follicles; grade 3: score 1 or 2 with germinal centers.

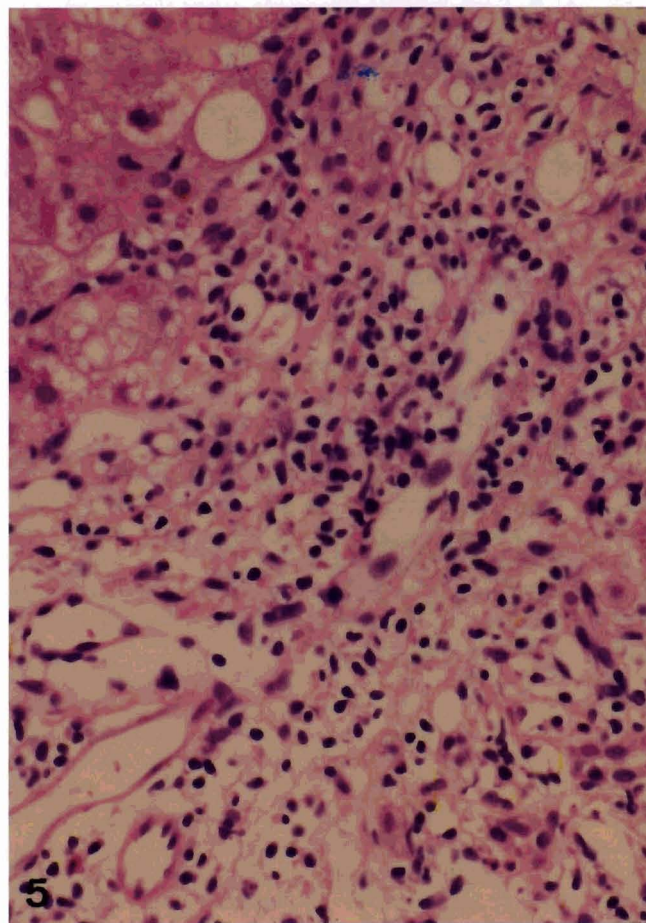


Fig. 5. Endotheliitis-like change, grade 3. In this situation, focal venous damage is advanced, with infiltration of inner segments of the vessel wall by lymphocytes, with partial interruption of the endothelial lining (center). H&E. x 180

Figs. 2-6. It is notable that most advanced ELC tended to predominate at sites where lymphocytic portal tract infiltrates were strongly expressed, or where lymphatic follicles were in close contact with small portal vein radicles, or were bulging into them (Fig. 4). However, ELC were also visualized in central veins, where adjacent liver parenchyma was not, or only very poorly, infiltrated. When taking all three grades of ELC together, they were observed significantly more

Table 4. Types of endotheliitis-like lesions.

GRADE	0	1	2	3
CH-C	10 (20%)	20 (40%)	16 (31.2%)	4 (9.7%)
CH-B	26 (54.2%)	20 (41.6%)	1 (2.1%)	1 (2.1%)

Grade 0: no endotheliitis-like lesions; grade 1: "borderline", i.e. spilling over of a few lymphocytes into venous wall and/or accumulation of a few lymphocytes in the subendothelial space; grade 2: slight/moderate endotheliitis-like lesions; grade 3: severe endotheliitis-like lesions.

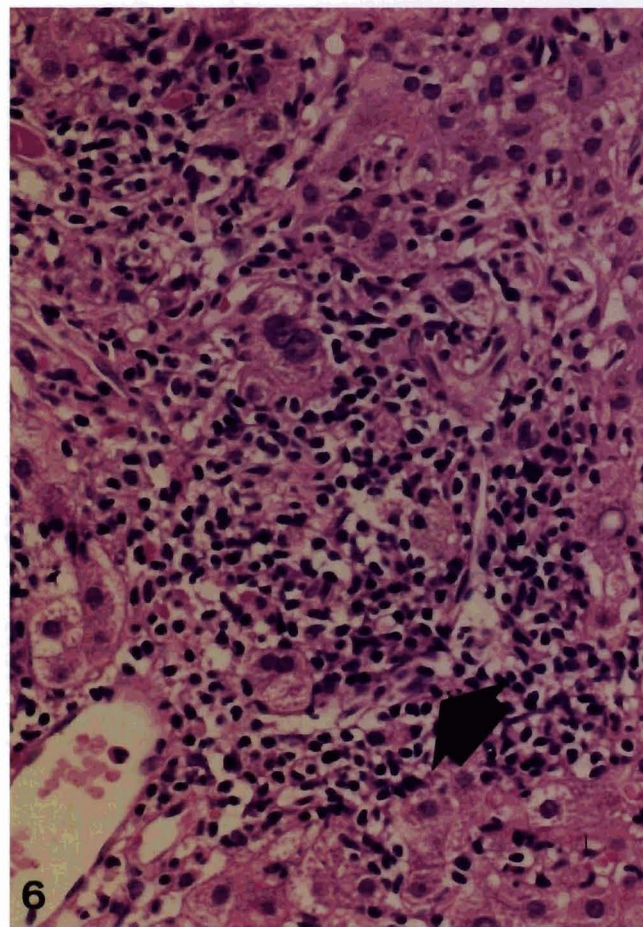


Fig. 6. Chronic hepatitis C of a high activity, with important piecemeal necrosis. A small venous branch shows a grade 3 endotheliitis-like alteration (arrow) H&E. x 180

frequently in CH-C than in CH-B (41.5% vs. 6.9%; $p < 0.05$). In the CH-C group, the majority of biopsies showing ELC exhibited this lesion in small portal vein radicles, but in 27.5% of cases central veins were involved as well. In contrast, ELC occurring in CH-B biopsies were located to small portal vein branches exclusively.

The distribution of ELC grades for CH-C and CH-B biopsies is presented in Table 4. It is seen that borderline lesions, i.e. alterations questionable with respect to ELC (grade 1) were encountered in CH-C and CH-B with a similar frequency (40% and 41.6% respectively), indicating that a low degree of lymphocyte spilling over into portal vein walls may occur in both situations. Conversely, grade 2 and grade 3 lesions, representing changes fulfilling the criteria of bona fide ELC, were significantly more frequent in CH-C, amounting to a total of 41% in CH-C vs 4.1% in CH-B. It is notable, however, that a few situations of severe ELC, characterized by heavy transmural lymphocyte infiltration and visible endothelial damage, also occurred in CH-B.

Discussion

Chronic hepatitis (Ishak, 1994) caused by HCV infection (CH-C) has been shown to be associated with a distinct set of histopathological changes to the liver, in particular comprising striking anomalies of small bile ducts and a high prevalence of lymphoid aggregates or follicles in portal tracts. Recent systematic studies have witnessed the diagnostic significance of these changes, and it surfaced that bile duct lesions in combination with lymphoid follicles strongly suggest the diagnosis of CH-C (Gerber et al., 1992). There is, therefore, increasing evidence indicating that the histomorphology of the liver in CH-C is different from CH due to other causes (in particular HBV infection) to a degree allowing its diagnosis in biopsies with a rather high probability (Lefkowitz et al., 1993). Overall, the histopathological findings obtained in the present investigation support previous results, in that significant damage to small bile ducts and lymphoid follicles were clearly more frequently registered in CH-C than in CH-B. However, both types of alterations exhibited considerable overlap between the two groups, particularly with respect to the lesion grade. Thus, minor anomalies of small bile duct epithelia showed almost the same prevalence in CH-C and CH-B; in fact, it has been reported that mild bile duct damage is common in viral hepatitis, usually seen as minor irregularity of shape, size and arrangement of epithelial nuclei (Scheuer, 1987). Only more advanced duct alterations of the type previously described (Poulsen and Christoffersen, 1969; Christoffersen et al., 1972) clearly discriminated between CH-C and CH-B in the present study, amounting to 28% of the cases in CH-C in comparison with 2% in CH-B. Taking all three grades of visible alterations of small bile ducts together, an overall prevalence of 86% was noted in CH-C, which

is somewhat higher than a figure recently reported (76%; Gerber et al., 1992), whereas the prevalence of 28% for more advanced duct lesions is very close to that observed in another study (30%; Lefkowitz and Apfelbaum, 1989). Similarly, very small lymphoid aggregates occurred in about 20% of CH-B biopsies, whereas larger aggregates or true follicles were rare in CH-B (2.1%), but amounted to 34% in CH-C, this prevalence being lower than that of previous studies (Lefkowitz and Apfelbaum, 1989: 52%; Gerber et al., 1992: 45%; Gordon et al., 1993: 20-74%; Lefkowitz et al., 1993: 49.4%; McMahon et al., 1994: 58%). Taking small and large aggregates together for CH-B, the prevalence of 22.9% is not far from the 27.2% reported in a multicenter study (Lefkowitz et al., 1993).

Here we show that 41% of pretreatment liver biopsies with CH-C exhibited ELC, whereas only 4.1% of CH-B biopsies disclosed this feature. A significant difference between the two CH groups with respect to ELC was seen for grade 2 and 3 lesions only, whereas borderline or questionable changes occurred in CH-C and CH-B with almost the same frequency. For this material of non-grafted livers we propose the descriptive term, ELC, in order to distinguish it from endothelialitis (or endotheliitis; EN; Ludwig et al., 1989; Ludwig, 1992) occurring in acute liver allograft rejection and in graft-versus-host disease. Ludwig coined the label, «immunoendotheliitis», to distinguish EN in rejection of allogeneic livers from the non-specific leucocyte adherence in other types of hepatitis (Ludwig et al., 1989). ELC, as described here, however, does not only comprise lymphocyte adherence to endothelia of small portal and hepatic veins, but also visible signs of endothelial damage. In fact, grade 2 and 3 lesions accepted as fully developed ELC closely meet the criteria described by Ludwig et al. (1989), in that our borderline lesions correspond to his minimal or diagnostically equivocal alterations, whereas grade 2 and 3 ELC appear to correspond to the spectrum of mild to severe lesions of Ludwig's classification (Ludwig et al., 1989), with the notable exception that we never observed blast-like transformation of effector cells. This is most probably due to the fact that blast formation occurs in rejecting allografts, but probably does not, or does to a much lesser degree, in CH.

In addition to liver allograft rejection, EN has previously been noted in various liver diseases (Nonomura et al., 1991). In the latter study, portal vein EN was defined as lymphocyte attachment to endothelial cells and was significantly more frequent in acute hepatitis, liver cirrhosis, primary biliary cirrhosis and infectious mononucleosis than in normal liver. The authors considered EN to be an intimate lymphocyte-endothelial cell interaction universally associated with active hepatic inflammation because, in active CH, the percentage of EN increased as a function of the degree of disease activity (Nonomura et al., 1991). Our findings indicate that the prevalence of ELC not only depends on CH activity, but also on the etiology of CH.

Endotheliitis in chronic hepatitis C

The pathogenesis of ELC in CH-C is not known so far, but several mechanisms may be taken into consideration. Firstly, ELC may represent a reaction not related to HCV as such, but to the inflammatory response induced by HCV. Small portal veins showing ELC are frequently embedded in areas of dense lymphocyte infiltration with lymphoid follicle formation. In this situation, lymphocyte traffic across the endothelial barrier may ensue, even though the exchange of recruited immunocytes between the intravascular and the extravascular compartments has not been studied in detail for the liver. However, this view is hampered by the observation that, in CH-C, ELC does also occur in small hepatic veins, where neither dense infiltrates nor follicles in adjacent tissue are usually found. Furthermore, simple lymphocyte traffic should not result in endothelial cell damage. Secondly, ELC may be due to immune-mediated mechanisms taking place in close vicinity. There are now several lines of evidence which suggest that immune mechanisms play a decisive role in the pathogenesis of cellular damage in CH-C (Gonzales-Peralta et al., 1994). It appears that the hepatitis seen in HCV infection is not dependent on the humoral immune response (Kumar et al., 1994), but rather on the action of cytotoxic T lymphocytes (Yang et al., 1988; Autschbach et al., 1991; Lau et al., 1991; Koziel et al., 1992; Botarelli et al., 1993; Gonzales-Peralta et al., 1994), even though the T cell zone enveloping the B cell aggregates in lymphoid follicles has been shown to contain more CD4-positive helper T than CD8-positive cytotoxic T lymphocytes (Mosnier et al., 1993). As immuno-competent cells associated with piecemeal necroses seemed to emerge from follicular areas (Mosnier et al., 1993), one might assume that a similar phenomenon can occur with respect to venous walls situated in close vicinity to lymphoid follicles. Thirdly, endothelia of small portal and hepatic veins may be the site of direct immune-mediated damage, because endothelial cells have previously been shown to stimulate lymphocytes in mixed culture (Hirschberg et al., 1975), to carry HLA-DR antigens (Burger and Vetto, 1982; Prober et al., 1986), and to act as antigen-presenting cells (Hirschberg et al., 1981; Groenewegen et al., 1986).

In conclusion, the present findings demonstrate that ELC occur significantly more frequent in CH-C than in CH-B, and may thus be a useful morphological feature in the differential diagnosis of these two hepatic diseases on biopsies. Their significance and pathogenesis have, however, to be further elucidated.

Acknowledgements. The technical help of M. Economou and the secretarial work of E. Müller are gratefully acknowledged.

References

Autschbach F., Meuer S.C., Moebius U., Manns M., Hess G., Meyer zum Büschenfee, de K.H., Thoernes W. and Diens H.P. (1991).

- Hepatocellular expression of lymphocyte function-associated antigen 3 in chronic hepatitis. *Hepatology* 14, 223-230.
- Bach N., Thung S. and Schaffner F. (1992). The histological features of chronic hepatitis C and autoimmune chronic hepatitis: a comparative analysis. *Hepatology* 15, 572-577.
- Bianchi L., Desmet V.J., Popper H., Scheuer P.J., Aledort L.M. and Berk P.D. (1987). Histological patterns of liver disease in hemophiliacs with special reference to morphological characteristics of non-A, non-B hepatitis. *Semin. Liver Dis.* 7, 203-209.
- Botarelli P., Brunetto M.R., Minutello M.A., Calvo P., Unutmaz D., Weiner A.J., Choo Q.-L., Shuster J.R., Kuo G., Bonino F., Houghton M., Abrignani S. (1993). T-lymphocyte response to hepatitis C virus in different clinical courses of infection. *Gastroenterology* 104, 580-587.
- Burger D.R. and Vetto R.M. (1982). Vascular endothelium as a major participant in T-lymphocyte immunity. *Cell Immunol.* 70, 357-361.
- Christoffersen P., Dietrichson O. and Faber V. (1972). The occurrence and significance of abnormal bile duct epithelium in chronic aggressive hepatitis. *Acta Pathol. Microbiol. Scand.* 80, 294-302.
- Dienes H.P., Popper H., Arndt W. and Lobeck H. (1982). Histologic observations in human hepatitis non-A, non-B. *Hepatology* 2, 562-571.
- Gerber M.A., Krawczynsky K., Alter M.J., Sampliner R.E., Margolis H.S. and the Sentinel Counties Chronic Non-A, Non-B Hepatitis Study Team. (1992). Histopathology of community acquired chronic hepatitis C. *Modern Pathol.* 5, 483-486.
- Gordon S.C., Elloway R.S., Long J.C. and Dmuchowski (1993). The pathology of hepatitis C as a function of mode of transmission: blood transfusion vs intravenous drug use. *Hepatology* 18, 1338-1343.
- Gonzales-Peralta R.P., Davis G.L. and Lau J.Y.N. (1994). Pathogenetic mechanisms of hepatocellular damage in chronic hepatitis C virus infection. *J. Hepatol.* 21, 255-259.
- Groenewegen G., Buurmann W.A. and Jeunhomme G.M.A.A. (1986). Alloantigen presentation by canine endothelial cells. *Transplantation* 41, 751-758.
- Hirschberg H., Evensen S.A., Hemriksen T. and Thorsby E. (1975). The human mixed lymphocyte-endothelium culture interaction. *Transplantation* 19, 495-504.
- Hirschberg H., Scott H. and Thorsby E. (1981). Human endothelial cells can present antigen to sensitized T lymphocytes in vitro. *Transplant. Proc.* 13, 100-102.
- Hino K., Okuda M., Konishi T., Yamashita A., Kayano K., Kubota M., Yasunaga M., Fukumoto Y. and Okita K. (1992). Analysis of lymphoid follicles in liver of patients with chronic hepatitis C. *Liver* 12, 387-391.
- Ishak K.G. (1994). Chronic hepatitis: morphology and nomenclature. *Modern Pathol.* 17, 690-713.
- Knodell R.G., Ishak K.G., Black W.C., Chen T.S., Craig R., Kaplowitz N., Kiernan T.W. and Wollmann J. (1981). Formulation and application of a numerical scoring system for assessing histological activity in asymptomatic chronic active hepatitis. *Hepatology* 1, 431-435.
- Koziel M.J., Dudley D., Wong J.T., Dienstag J., Houghton M., Ralston R. and Walker B.D. (1992). Intrahepatic cytotoxic T lymphocytes specific for hepatitis C virus in persons with chronic hepatitis. *J. Immunol.* 149, 3339-3344.
- Kumar U., Monjardino J. and Thomas H.C. (1994). Hypervariable region of hepatitis C virus envelope glycoprotein (E2/NS1) in an agammaglobulinemic patient. *Gastroenterology* 106, 1072-1075.

Endotheliitis in chronic hepatitis C

- Lau J.Y.N., Alexander G.J.M. and Alberti A. (1991). Viral hepatitis. *Gut* 32, S47-S62.
- Lefkowitz J.H. and Apfelbaum T. (1989). Non-A, non-B hepatitis: characterization of liver biopsy pathology. *J. Clin. Gastroenterol.* 11, 225-232.
- Lefkowitz J.H., Schiff E.R., Davis G.L., Perillo R.P., Lindsay K., Bodenheimer H.C., Balart L.A., Ortego T.J., Payne J., Dienstag J.L., Gibas A., Jacobson I.M., Tamburro C.H., Carey W., O'Brien C., Sampliner R., van Thiel D.H., Feit D., Albrecht J., Meschievitz C., Sanghvi B., Vaughan R.D. and the Hepatitis Interventional Therapy Group. (1993). Pathological diagnosis of chronic hepatitis C: A multi-center comparative study with chronic hepatitis B. *Gastroenterology* 104, 595-603.
- Ludwig J. (1992). Terminology of hepatic allograft rejection (glossary). *Semin. Liver Dis.* 12, 89-92.
- Ludwig J., Batts K.P., Ploch M., Rakela J., Perkins J.D. and Wiesner R.H. (1989). Endotheliitis in hepatic allografts. *Mayo Clin. Proc.* 64, 545-554.
- McMahon R.F.T., Yates A.J., McLindon J., Babbs C., Love E.M., and Warnes T.W.W. (1994). The histopathological features of asymptomatic hepatitis C virus-antibody positive blood donors. *Histopathology* 24, 517-524.
- Mosnier J.-F., Degott C., Marcellin P., Hénin D., Erlinger S. and Benhamou J.-P. (1993). The intraportal lymphoid nodule and its environment in chronic active hepatitis C: an immunohistochemical study. *Hepatology* 17, 366-371.
- Nonomura A., Mizukami Y., Matsubara F. and Kobayashi K. (1991). Clinicopathological study of lymphocyte attachment to endothelial cells (endothelialitis) in various liver diseases. *Liver* 11, 78-88.
- Portmann B.C. and MacSween R.N.M. (1987). Diseases of the intrahepatic bile ducts. In: *Pathology of the liver*. MacSween R.N.M., Anthony P.P. and Scheuer P.J. (eds). London. Churchill Livingstone. pp 424-453.
- Poulsen H. and Christoffersen P. (1969). Abnormal bile duct epithelium in liver biopsies with histological signs of viral hepatitis. *Acta Pathol. Microbiol. Scand.* 76, 383-390.
- Prober J.S., Collins T., Gimbrone M.A., Libby P. and Reiss C.S. (1986). Inducible expression of class II major histocompatibility complex antigens and the immunogenicity of vascular endothelium. *Transplantation* 41, 141-146.
- Scheuer P.J. (1987). *Liver biopsy interpretation*. 4th ed. Bailliere Tindall. London.
- Scheuer P.J., Ashrafzadeh R., Sherlock S., Brown D. and Dusheiko G. (1992). The pathology of hepatitis C. *Hepatology* 14, 567-571.
- Schmid M., FLury R., Bühler H., Havelka J.H., Grob P.J. and Heitz P.U. (1994). Chronic viral hepatitis B and C: an argument against the conventional classification of chronic hepatitis. *Virchows Arch.* 425, 221-228.
- Vyberg M. (1993). The hepatitis-associated bile duct lesion. *Liver* 13, 289-301.
- Yang P.M., Su I.J., Lai M.Y., Huang G.T., Hsu H.C., Chen D.S. and Sung J.L. (1988). Immunohistochemical studies on intrahepatic lymphocyte infiltrates in chronic type B hepatitis with special emphasis on the activation status of lymphocytes. *Am. J. Gastroenterol.* 83, 948-953.
- Zhao D., Zimmermann A. and Wheatley A.W. (1993). Morphometry of the liver after liver transplantation in the rat. Significance of an intact arterial supply. *Hepatology* 17, 310-317.

Accepted October 14, 1996