

Apoptosis and autophagy in nigral neurons of patients with Parkinson's disease

P. Anglade, S. Vyas, F. Javoy-Agid, M.T. Herrero, P.P. Michel, J. Marquez, A. Mouatt-Prigent, M. Ruberg, E.C. Hirsch and Y. Agid

INSERM U289, Hôpital de la Salpêtrière, Paris, France

Summary. Parkinson's disease (PD) is a neurodegenerative disorder characterized by progressive cell loss confined mostly to dopaminergic neurons of the substantia nigra. Several factors, including oxidative stress, and decreased activity of complex I mitochondrial respiratory chain, are involved in the degenerative process. Yet, the underlying mechanisms leading to dopaminergic cell loss remain elusive. Morphological assessment for different modes of cell death: apoptosis, necrosis or autophagic degeneration, can contribute significantly to the understanding of this neuronal loss. Ultrastructural examination revealed characteristics of apoptosis and autophagic degeneration in melanized neurons of the substantia nigra in PD patients. The results suggest that even at the final stage of the disease, the dopaminergic neurons are undergoing active process of cell death.

Key words: Parkinson's disease, Dopaminergic neurons, Apoptosis, Ultrastructural analysis

Introduction

In neurodegenerative diseases, the loss of specific neurons is slow, but more rapid than normal aging. In most patients, the initial cause and mechanisms leading to cell death remain an enigma. In Parkinson's disease (PD), cell loss is essentially confined to dopaminergic neurons in the pars compacta of the substantia nigra (Bernheimer et al., 1973). Biochemical abnormalities suggesting oxidative stress, decreased activity of the mitochondrial respiratory chain and decreased capacity to buffer intracellular calcium have been described in the substantia nigra, but their role in the death of dopaminergic neurons is not known (Agid et al., 1993). Morphological signs of cell suffering, such as Lewy bodies (Forno, 1986) and dendritic atrophy (Patt et al., 1991) have also been uninformative as to the cause of

the degenerative process.

Cell death during embryonic development or in adult cell populations with rapid turnover (Kerr et al., 1972) occurs principally by apoptosis or programmed cell death (PCD), which may be regarded as a regulated series of biochemical events that lead to autodestruction of the cell (Oltvai and Korsmeyer, 1994). Apoptosis can be triggered by diverse signals. For example, deprivation of a growth factor, inappropriate expression of dominant proto-oncogenes and stimulation by cytokines such as TNF- α (Raff et al., 1993). Some of the genes implicated in the mechanisms of apoptosis have been identified: the protooncogene *bcl-2*, which inhibits the process (Ellis et al., 1991), is a mammalian homologue of the nematode *Caenorhabditis elegans* cell death gene, *ced-9*, whereas the gene coding for interleukin-1 β -converting enzyme (ICE) (Yuan et al., 1993) is a mammalian counterpart of *C. elegans ced-3* gene required for PCD. The cells which undergo apoptosis in physiological situations exhibit chromatin condensation, nuclear fragmentation, blebbing of the plasma membrane and cell shrinkage. Cytoplasmic organelles remain intact even after final engulfment in macrophages and there is no accompanying inflammatory reaction (Kerr et al., 1972; Clarke, 1990). This is in contrast with necrosis, occurring in response to toxic insult that results in cytoplasmic vacuolation and final cell bursting, whereas the nucleus remains intact. Autophagic cell death is another frequently observed autodegenerative process characterized by formation of numerous autophagic vacuoles, vacuolation of endoplasmic reticulum and moderate chromatin condensation (Clarke, 1990).

In this study, we hypothesized that apoptosis may represent an important mechanism through which dopaminergic neurons ultimately die during the course of PD. Unequivocal identification of the different types of cell death in situ is based on criteria defined at subcellular level (Kerr et al., 1972; Clarke, 1990). Ultrastructural analysis of dopaminergic neurons in the substantia nigra of patients with PD was undertaken to search for morphological characteristics of cell death.

Materials and methods

Patients

The brains of 3 patients suffering from PD were used in this study. The mean age and postmortem delay between death and tissue fixation were, respectively, 75 ± 7 years and 8.3 ± 2.3 hours (expressed as mean \pm SEM). Only brains with a postmortem delay of less than 12 hours were included to minimize artifacts from postmortem degradation of the tissues. All patients were under levodopa therapy (mean daily dose at death \pm SEM: 830 ± 120 mg). Parkinsonian motor disability corresponded to stage III to IV, according to the Hoehn and Yahr rating scale (Hoehn and Yahr, 1967). The diagnosis of PD was established on analysis of the clinical charts and confirmed postmortem by the presence of neuronal loss, extraneuronal neuromelanin and Lewy bodies in the substantia nigra and locus coeruleus.

Electron microscopy

After autopsy, the brains were removed from the skull and hemisected. Brainstems were cut in 0.5 cm-thick transverse slabs and small blocks of the rostral tier of the substantia nigra pars compacta ($0.5 \times 0.5 \times 0.5$ cm) were removed. They were fixed for 3 days at 4 °C in a

mixture of 4% paraformaldehyde and 2.5% glutaraldehyde in 0.1M Na phosphate buffer and stored in 0.2M Na phosphate buffer containing 0.1% Na azide at 4 °C. Sections, 200 μ m thick, were cut on a vibrating microtome. From the sections, small pieces of tissue which included melanized dopaminergic neurons were selected and removed under binocular lens. Tissue samples were immersed in 2% osmium tetroxide in 0.01M phosphate buffer saline for 30 min. After rinsing in distilled water, dehydration and counterstaining were performed in a graded series of alcohol solutions containing saturated phosphotungstic acid. Embedding of tissues was performed in Araldite resin. Semi-thin sections (0.5-1 μ m) were cut and stained by toluidine blue. Finally, 100 to 120 nm-thick ultrathin sections were cut at the level that included nuclei of melanized neurons. The grids containing the sections were observed under a JEOL 1200 EX electron microscope at 70 kV.

Results

Ultrastructural features of apoptosis and also autophagic degeneration were detected in 6% of the 169 melanized dopaminergic neurons analyzed in the substantia nigra of three Parkinsonian patients (Table 1). In apoptotic neurons, varying degrees of nuclear alterations, ranging from moderate to major chromatin

Table 1. Number of dopaminergic (DA) neurons with apoptosis and autophagic degeneration in three Parkinsonian Patients.

PARKINSONIAN PATIENTS	DISEASE DURATION (yrs)	AGE AT DEATH (yrs)	TOTAL NUMBER OF DA NEURONS ANALYZED	NUMBER OF APOPTOTIC DA NEURONS	NUMBER OF APOPTOTIC CELL FRAGMENTS	NUMBER OF DA NEURONS WITH AUTOPHAGIC DEGENERATION
1	15	64	109	3	3	1
2	13	73	45	-	2	-
3	3	87	15	3	2	3

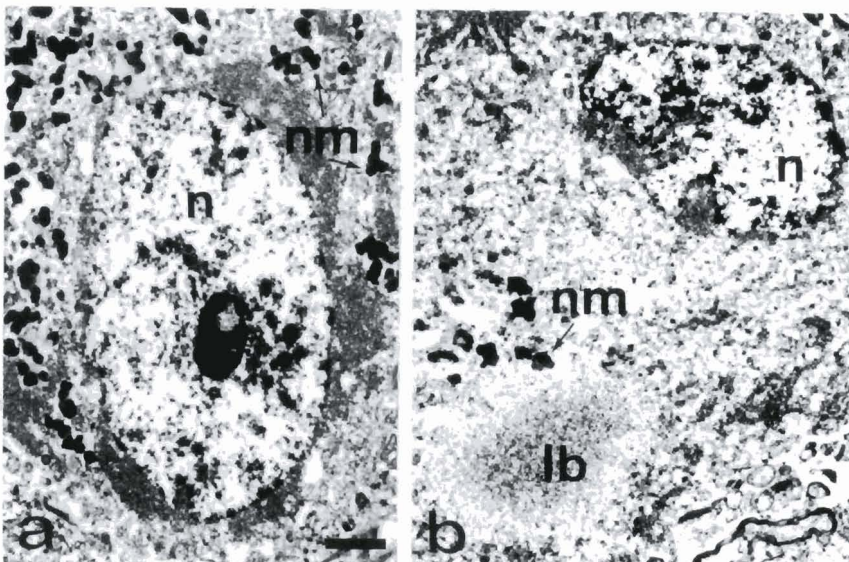


Fig. 1. Nigral DA neurons, characterized by cytoplasmic neuromelanin granules (nm), with normal morphological features (a,b). The nuclei (n) of the neurons display the same pattern of dispersed chromatin, forming a fine network in which a few small patches are visible, even in the presence of a Lewy body (lb) in the perikaryon (b). Bar: 2 μ m.

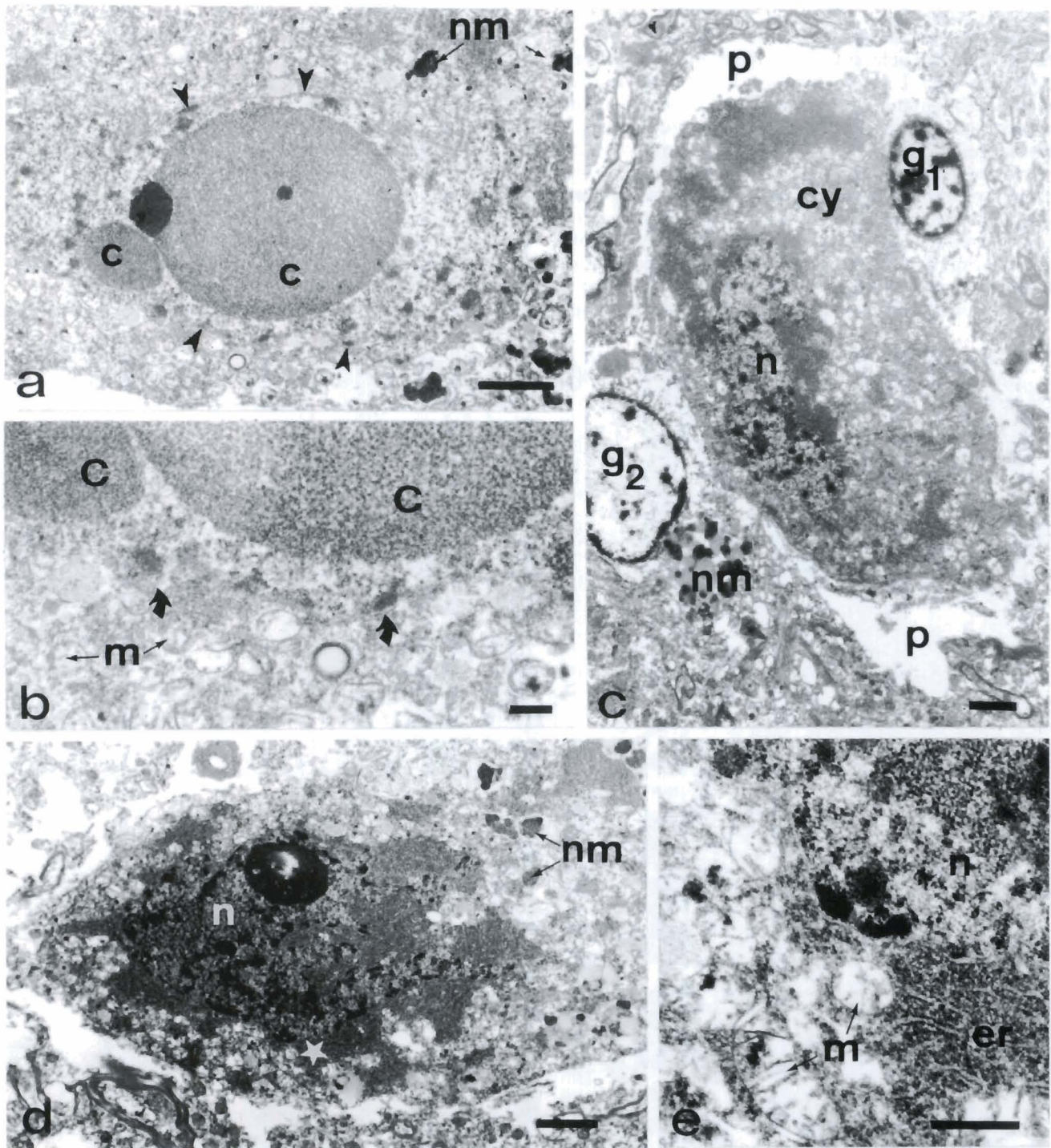


Fig. 2. Dopaminergic (DA) neurons, identified by neuromelanin granules (nm), with morphological features of apoptosis in the substantia nigra of Parkinsonian patients. **a.** The nucleus of this DA Neuron contains large masses of condensed chromatin (c). Small patches of chromatin are scattered close to the nuclear envelope outlined by arrowheads. Bar: 2 μ m. **b.** Detail of (a) at higher magnification. The masses of chromatin (c) are surrounded by the nuclear envelope (curved arrows). Mitochondria (m) are closely packed in the cytoplasm. Bar: 0.5 μ m. **c.** An apoptotic DA neuron, characterized by neuromelanin granules observed in adjacent sections (not shown), is engulfed in a glial cell (g₁ and p). Another glial cell (g₂) containing neuromelanin granules (nm) is observed close to the neuron. The nucleus (n) of the DA neuron displays middle condensation of the chromatin. The cytoplasm (cy) contains densely stacked organelles. Bar: 2 μ m. **d.** Apoptotic DA neuron with pronounced chromatin condensation in the nucleus (n) markedly convoluted. Bar: 2 μ m. **e.** Area dotted by a star in d at higher magnification. The endoplasmic reticulum (er) and densely packed mitochondria (m) retain a normal morphology. The nucleus (n) contains condensed chromatin. Bar: 0.5 μ m.

Apoptosis in Parkinson's disease

condensation and, in some of these neurons, disappearance of the nucleolus, were observed (Fig. 2). The absence of nucleolus was verified by screening the nuclei on serial semi-thin sections. The nuclear envelope, although in appearance intact, was convoluted. Outside the nucleus, the most striking change was shrinkage of cell bodies (Fig. 2d). Endoplasmic reticulum and mitochondria, although compacted, retained normal morphology (Fig. 2e). Among these dying neurons, some were partially or totally engulfed by glial cells, suggesting an ongoing phagocytotic process (Fig. 2c). Fragmented nuclei with condensed chromatin among clusters of melanin were observed in glial cells. Features strongly suggestive of autophagic

degeneration (Clarke, 1990) were observed in the dopaminergic neurons of the substantia nigra of patients 1 and 3 (Table 1). These neurons were characterized by condensation of chromatin, less pronounced than in the apoptotic neuron, moderate vacuolation of endoplasmic reticulum and lysosome-like vacuoles, more numerous than in normal neurons (Fig. 3a-c). The appearance of the mitochondria did not differ from that of dopaminergic neurons devoid of abnormal features. In one of the autophagic degenerating neurons, the number of vacuoles containing remains of cytoplasmic material was high, suggesting an advanced stage of this cell death process (Fig. 3d).

The majority of the melanized neurons with features

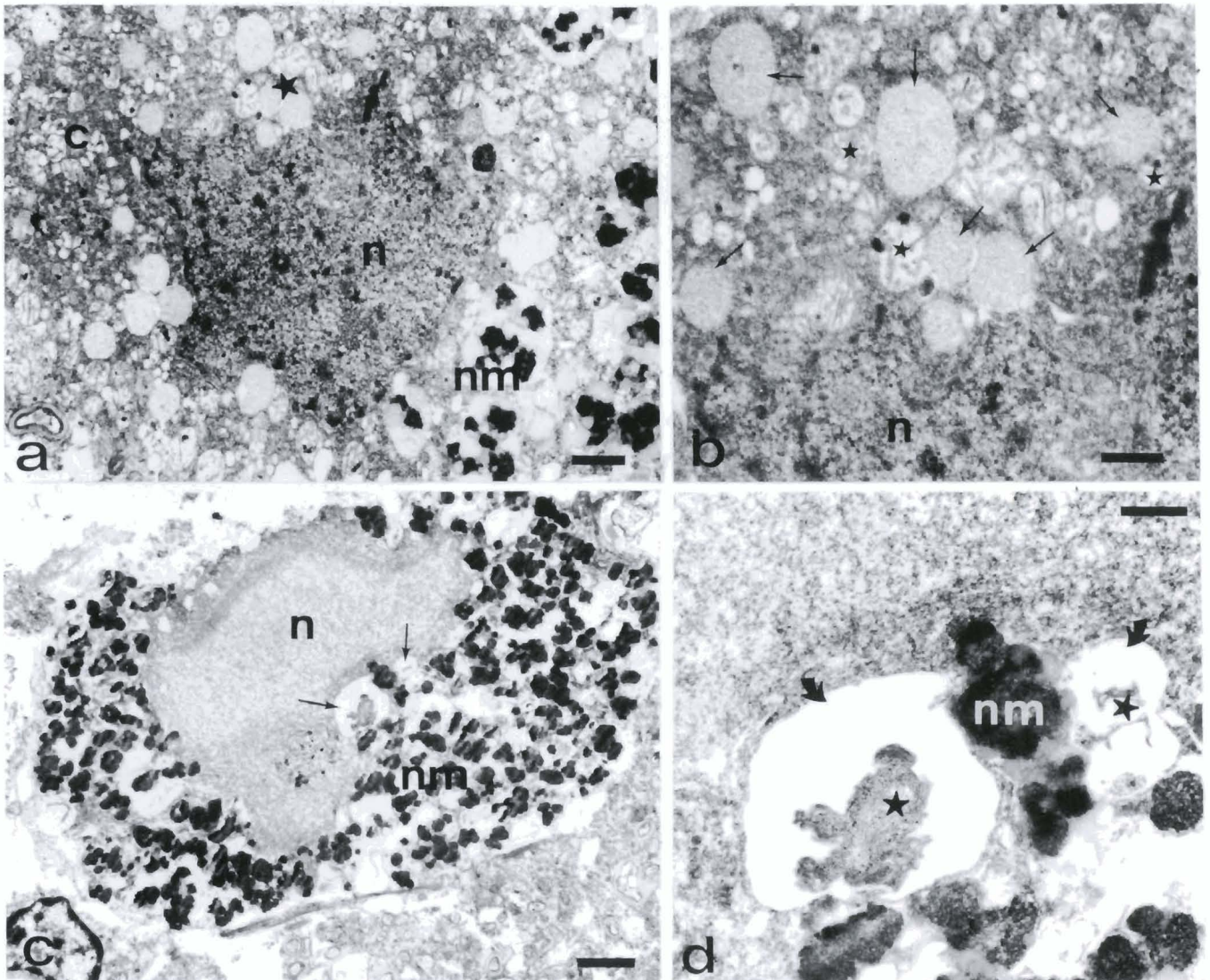


Fig. 3. Nigral dopaminergic (DA) neurons, containing neuromelanin granules (nm), with features of autophagic degeneration. **a.** DA neuron with moderate chromatin condensation in the nucleus (n) and vacuolization of the cytoplasm (c). Bar: 1 μ m. **b.** Detail of the area marked by a star in a. This region has a high density of lysosome-like vacuoles (arrows). Mitochondria (stars) have normal morphology. Bar: 0.5 μ m. **c.** The nucleus (n) of this DA Neuron has a moderate chromatin condensation. Numerous vacuoles (arrows) are present in the cytoplasm. Bar: 2 μ m. **d.** Detail of two vacuoles marked by arrows in c. The vacuoles (curved arrows) contain remains of cytoplasmic fragments (stars). Bar: 0.5 μ m.

Apoptosis in Parkinson's disease

of apoptosis and autophagic degeneration were localized in the ventral part of the substantia nigra of patient 3, the most advanced in age with a disease duration of three years. Examination of ultra-thin sections of this patient indicated that the dying cells were in the proximity of GABAergic neurons of pars reticulata, evidenced by their size (20 μm) and the presence of lipofuscin granules in their cytoplasm (data not shown). Among all the melanized neurons analyzed in the three patients, 8 neurons were found to contain Lewy bodies but no morphological features of cell death (Fig. 1b). Neurons without morphological abnormalities displayed a large nucleus with dispersed chromatin forming a fine network with only small patches and numerous mitochondria interspersed between piles of thin tubules of endoplasmic reticulum (Fig. 1a). Necrosis, characterized by cytoplasmic vacuolation, cell swelling and cytoplasmic membrane breakdown, was occasionally detected in glial but not in dopaminergic cells (not shown).

Discussion

The results indicate that the dopaminergic neurons in PD die by an apoptotic process and also by autophagic degeneration. The morphological criteria of apoptosis parallel those that have been described during development in various species (Kerr et al., 1972; Abrams et al., 1993; Raff et al., 1993) in the substantia nigra following excitotoxic lesion in immature rats (Macaya et al., 1994) and in cultures of catecholaminergic cells intoxicated with 1-methyl-4-phenylpyridinium (MPP+) (Hartley et al., 1994) or dopamine (Ziv et al., 1994). The observation of features of autophagic degeneration indicates that there may be more than one mechanism of cell death in PD. However, it may also reflect the presence of two types of nigral dopaminergic neurons undergoing differential responses to primary insults, although such cellular heterogeneity remains to be demonstrated. DNA fragmentation, either by *in situ* labelling of strand breaks or by gel electrophoresis, has been reported in human brain tumors and in Alzheimer's and Huntington's diseases (Su et al., 1994; Lassmann et al., 1995; Portera-Cailliau et al., 1995; Tompkins and Hill, 1995). Although it can be taken as a criteria of cell death by apoptosis in these disorders, DNA fragmentation is also observed in non-apoptotic dying cells (Su et al., 1994; Lassmann et al., 1995; Portera-Cailliau et al., 1995). Therefore, this study brings the first unequivocal demonstration of neuronal loss by apoptosis and autophagic degeneration in the pathological aged human brain.

The number of apoptotic neurons observed in this study is high compared to quantitative estimates of cell death during development (approximately 1%) (Raff et al., 1993; Bellamy et al., 1995). The clearance rate of apoptotic cells in development is believed to be very rapid, hence the low number observed *in situ*. The greater percentage in PD suggests that the rate of cell

death is higher and/or that the clearance time of dead neurons is slow in pathological situation. However, further analysis in more PD patients and in control subjects is required for statistical evaluation of the rate of PCD in this region. We did not observe morphological features of necrosis except occasionally in glial cells. It is possible that the neurodegenerative process in PD entails necrotic death, as suggested in Alzheimer's disease (Lassmann et al., 1995) or in experimental models of excitotoxicity (Van Lookeren Campagne et al., 1995), and the post-mortem analysis may not reveal the early wave of this type of death. However, the disease duration of patient 3 was only three years and the percentage of apoptotic and autophagic neurons was high in the ventral part of the substantia nigra.

We cannot exclude that the neuronal death observed in this study was a result of aging process. However, the majority of apoptotic and autophagic neurons were observed in the ventral part of the substantia nigra. In the study of Fearnley and Lees (1991) on nigral neuronal loss in PD and in normal aging, the ventral region of the substantia nigra was found to be most affected in PD in comparison to only mild cell loss during normal aging. Although the number of patients examined was too small to draw general conclusions, this distribution suggests that the cell death observed in this study was mostly the consequence of the pathological process rather than normal aging.

As PD patients were treated with levodopa, nigral dopaminergic neurons might theoretically have been injured by long term administration of levodopa through the production of free radicals (Graham et al., 1978). Levodopa has been shown to be toxic to catecholaminergic neurons cultured *in vitro* (Pardo et al., 1993). However, the concentrations of levodopa used in this study and others are far beyond the therapeutical doses used generally in patients. In addition, several lines of experimental and clinical evidences are not in favor of the putative toxic role of levodopa in PD (Blin et al., 1988).

Surprisingly, Lewy bodies were found in apparently normal neurons and not in those with characteristic features of apoptosis or autophagic degeneration. It cannot be excluded that Lewy bodies are extruded from cells undergoing the final step of degeneration. Alternatively, despite their well-established relation with the pathology, Lewy bodies might not be directly related to the cell death process.

In PD, the surviving dopaminergic neurons are likely to be in a persistent state of cellular suffering, as suggested by the following observations: 1) decreased expression of tyrosine hydroxylase mRNA (Javoy-Agid et al., 1990) and protein (Kastner et al., 1993); 2) presence of HLA-DR-activated glial cells, an index of a continuous local inflammatory process (McGeer et al., 1988); 3) accumulation over time of Lewy bodies (Forno, 1986); 4) ongoing production of free radicals, as shown by the decreased concentrations of reduced glutathione (Perry et al., 1982) and the increased iron

Apoptosis in Parkinson's disease

content (Dexter et al., 1989), which indicates the excess production of oxygen species and free radicals; and 5) decreased activity of complex I resulting in a reduced metabolism of the mitochondrial respiratory chain (Schapira et al., 1990). Whether these biochemical changes in the Parkinsonian substantia nigra represent early or late steps in the cascade of events leading to cell death is not known. However, they strongly suggest that, despite their normal ultrastructural morphology, dopaminergic neurons in PD are affected by an ongoing illness. Similarly the factors triggering apoptosis in PD remain to be elucidated. TNF- α , which may induce apoptosis through p55 receptors, was found in glial cells in the substantia nigra of PD patients, whereas the expression of TNF- α p55 receptor was detected in dopaminergic neurons (Boka et al., 1994). Moreover, our recent results showed the expression of *bcl-2* in the nigral dopaminergic neurons (submitted). This suggests that active protection must be overcome for the apoptotic process to occur. In this context, it is tempting to speculate that apoptosis occurs as an ultimate phase of dopaminergic neuronal degeneration and that the susceptible neurons already possess an inherent PCD machinery that may be activated by a stimulus such as TNF- α and protected by an anti-apoptotic molecule like Bcl-2.

In conclusion, we show that an apoptotic process was present in the substantia nigra of patients with PD. Whether apoptosis also occurs during normal senescence remains to be determined. The identification of the factors involved in this process may provide new insights into the mechanisms that underlie cell death and may lead to the discovery of therapeutical strategies aimed at preventing the progression of the disease.

Acknowledgements. We thank Drs. B. Faucheux and S. Tsuji, Mr. N. Barton, Prs J.-J. Hauw and C. Duyckaerts for helpful contribution. This work was supported by the National Parkinson foundation (Miami, USA), Rhône-Poulenc Rorer and the Institut National de la Santé et de la Recherche Médicale.

References

- Abrams J.M., White K., Fessler L.I. and Steller H. (1993). Programmed cell death during *Drosophila* embryogenesis. *Development* 11, 729-743.
- Agid Y., Ruberg M., Javoy-Agid F., Hirsch E., Raisman-Vozari R., Vyas S., Faucheux B., Michel P., Kastner A., Blanchard V., Damier P., Villares J. and Zhang P. (1993). Are dopaminergic neurons selectively vulnerable to Parkinson's disease? In: *Advances in neurology*. Vol. 60. Narabayashi H., Nagatsu T., Yanagisawa N. and Mizuno Y. (eds). Raven Press. New York. pp 148-164.
- Bellamy C.O.C., Malcomson R.D.G., Harrison D.J. and Wyllie A.H. (1995). Cell death in health and disease: *Semin. Cancer Biol.* 6, 3-16.
- Bernheimer H., Birkmayer W., Hornykiewicz O., Jellinger K. and Seitelberger F. (1973). Brain dopamine and the syndromes of Parkinson and Huntington. *Clinical, morphological and neurochemical correlations.* *J. Neurol. Sci.* 20, 415-455.
- Blin J., Bonnet A.M. and Agid Y. (1988). Does levodopa aggravate Parkinson's disease? *Neurology* 38, 1410-1416.
- Boka G., Anglade P., Wallach D., Javoy-Agid F., Agid Y. and Hirsch E.C. (1994). Immunocytochemical analysis of tumor necrosis factor and its receptors in Parkinson's disease. *Neurosci. Lett.* 172, 151-154.
- Clarke P.G.H. (1990). Developmental cell death: morphological diversity and multiple mechanisms. *Anat. Embryol.* 181, 195-213.
- Dexter D.T., Wells F.R., Lees A.J., Agid F., Agid Y., Jenner P. and Marsden D. (1989). Increased nigral iron content and alterations in other metal ions occurring in brain in Parkinson's disease. *J. Neurochem.* 52, 1830-1836.
- Ellis R.E., Yuan J. and Horvitz H.R. (1991). Mechanisms and functions of cell death. *Annu. Rev. Cell Biol.* 7, 663-698.
- Fearnley J.M. and Lees A.J. (1991). Ageing and Parkinson's disease: substantia nigra regional selectivity. *Brain* 114, 2283-2301.
- Forno L.S. (1986). The Lewy body in Parkinson's disease. In: *Advances in neurology*. Vol. 5. Yahr M.D. and Bergmann K.J. (eds). Raven Press. New York. pp 35-43.
- Graham D.G., Tiffany S.M. and Bell W.R. (1978). Autooxidation vs covalent binding of quinones as mechanism of toxicity of dopamine, 6-hydroxydopamine and related compounds toward C1300 neuroblastoma cells in vitro. *Mol. Pharmacol.* 1, 664-653.
- Hartley A., Stone J.M., Heron C., Cooper J.M. and Schapira A.H.V. (1994). Complex I inhibitors induce dose-dependent apoptosis in PC12 cells: relevance to Parkinson's disease. *J. Neurochem.* 63, 1987-1990.
- Hoehn M.M. and Yahr M.D.D. (1967). Parkinsonism: onset, progression and mortality. *Neurology* 17, 427-442.
- Javoy-Agid F., Hirsch E., Dumas S., Duyckaerts C., Mallet J. and Agid Y. (1990). Decreased tyrosine hydroxylase mRNA in the surviving dopamine neurons in Parkinson's disease. *Neuroscience* 38, 245-253.
- Kastner A., Hirsch E.C., Agid Y. and Javoy-Agid F. (1993). TH protein and messenger RNA in the dopaminergic nigral neurons of patients with Parkinson's disease. *Brain Res.* 606, 341-345.
- Kerr J.F.R., Wyllie A.H. and Currie A.R. (1972). Apoptosis: a basic biological phenomenon with wide range implications in tissue kinetics. *Br. J. Cancer* 26, 239-257.
- Lassmann H., Bancher C., Breitschopf H., Wegiel J., Bobinski M., Jellinger K. and Wisniewski H.M. (1995). Cell death in Alzheimer's disease evaluated by DNA fragmentation in situ. *Acta Neuropathol. (Berl)* 89, 35-41.
- Macaya A., Munell F., Gubits R.M. and Burke R.E. (1994). Apoptosis in substantia nigra following developmental striatal excitotoxic injury. *Proc. Natl. Acad. Sci. USA* 91, 8117-8121.
- McGeer P.L., Itagaki S., Akiyama H. and McGeer E. (1988). Rate of cell death in Parkinsonism indicates active neuropathological process. *Ann. Neurol.* 24, 574-576.
- Oltvai Z.N. and Korsmeyer S.J. (1994). Checkpoints of dueling dimers foil death wishes. *Cell* 79, 189-192.
- Pardo B., Mena M.A., Fahn S. and Garcia de Yébenes J. (1993). Ascorbic acid protects against Levodopa-induced neurotoxicity on a catecholamine-rich human blastoma cell line. *Mov. Disord.* 8, 278-284.
- Patt S., Gertz H.-J., Gerhard L. and Cervos-Navarro J. (1991). Pathological changes in dendrites of substantia nigra neurons in Parkinson's disease: a golgi study. *Histol. Histopathol.* 6, 373-380.

Apoptosis in Parkinson's disease

- Perry T.L., Godin D.V. and Hansen S. (1982). Parkinson's disease: a disorder due to nigral glutathione deficiency? *Neurosci. Lett.* 33, 305-310.
- Portera-Cailliau C., Hedreen J.C., Price D.L. and Koliatsos V.E. (1995). Evidence for apoptotic cell death in Huntington disease and excitotoxic animal models. *J. Neurosci.* 15, 3775-3787.
- Raff M.C., Barres B.A., Burne J.F., Coles H.S., Ishizaki Y. and Jacobson M.D. (1993). Programmed cell death and the control of cell survival: lessons from the nervous system. *Science* 262, 695-700.
- Schapira A.H.V., Cooper J.M., Dexter D.T., Clark J.B., Jenner P. and Marsden C.D. (1990). Mitochondrial complex I deficiency in Parkinson's disease. *J. Neurochem.* 54, 823-827.
- Su J.H., Anderson A.J., Cummings B.J. and Cotman C.W. (1994). Immunocytochemical evidence for apoptosis in Alzheimer's disease. *Neuroreport* 5, 2529-2533.
- Tompkins M.M. and Hill W.D. (1995). Apoptotic-like changes in human substantia nigra. *Soc. Neurosci. Abstr.* 21 (Part 2), 1273.
- Van Lookeren Campagne M., Lucassen P.J., Vermeulen J.P. and Balazs R. (1995). NMDA and kainate induce internucleosomal DNA cleavage associated with both apoptotic and necrotic cell death in the neonatal rat brain. *Eur. J. Neurosci.* 7, 1627-1640.
- Yuan J., Shaham S., Ledoux S., Ellis H.M. and Horvitz H.R. (1993). The *C. elegans* cell death gene *ced-3* encodes a protein similar to mammalian interleukin-1 β -converting enzyme. *Cell* 75, 641-652.
- Ziv I., Melamed E., Nardi N., Luria D., Achiron A., Offen D. and Barzilai A. (1994). Dopamine induces apoptosis-like cell death in cultured chick sympathetic neurons: a possible novel pathogenetic mechanism in Parkinson's disease. *Neurosci. Lett.* 170, 136-140.

Accepted May 22, 1996