

# Immunohistochemical expression of Bcl-2 oncoprotein in EBV-associated nasopharyngeal carcinoma correlated to histological type and survival

F.J. Vera-Sempere<sup>1</sup>, J.S. Burgos<sup>1</sup>, M.S. Botella<sup>1</sup> and C. Morera<sup>2</sup>

<sup>1</sup>Service of Pathology II, Laboratory of Molecular Pathology and

<sup>2</sup>Service of Otolaryngology, Hospital La Fe, Medical School of Valencia University, Valencia, Spain

**Summary.** Expression of Bcl-2 is associated with inhibition of apoptosis and extension of cell survival. *In vitro* Bcl-2 protein expression is up-regulated by the EBV-latency associated antigen latent membrane protein (LMP-1). We have investigated the relationship between the presence of EBV-DNA screened by means of sensitive nested-PCR, nasopharyngeal carcinoma (NPC) histological types according to two different schemata (WHO and Micheau classifications) and Bcl-2-124 immunohistochemical expression in 55 biopsy samples of NPC. EBV genome was detected in 100% of samples with sufficient DNA quality to support the previous view that all types of NPC are variants of EBV-infected neoplasia. Bcl-2 was observed in the basal layer of normal nasopharyngeal mucosa and also at cytoplasmic level in 42 of 55 (76.4%) NPC cases. Mitotic neoplastic cells usually showed strong cytoplasmic and chromosomal staining, a finding not well referred to previously. Bcl-2 expression was significantly associated ( $p < 0.05$ ) to undifferentiated NPC (UNPC) when a histological classification with only two major microscopical types was applied. No close correlations were found between the presence of EBV-DNA, NPC location, clinical stage and age or sex of the patients in relation to Bcl-2 positive expression. However, when comparing Bcl-2 expression and known survival mean of the patients, significant differences were observed ( $p < 0.001$ ) so that mean survivals were 31.1, 24.4, 52.2 and 54.1 months respectively for NPC patients with -, +, ++ and +++ Bcl-2 immunoreactivity. Nevertheless this better clinical outcome in Bcl-2 NPC positive cases may depend on the histological type due to close relationship with UNPC. Only studies of larger series with long-term follow-up and multivariate analyses may document whether Bcl-2 expression is an independent prognostic marker in the evolution of NPC patients.

**Key words:** Bcl-2, Nasopharyngeal carcinoma, Epstein-Barr virus, Prognosis, Immunohistochemistry

Offprint requests to: Dr. F.J. Vera-Sempere, M.D., Daoiz y Velarde nº 8-14, 46021 Valencia, Spain

## Introduction

Epstein-Barr virus (EBV) is known to cause infectious mononucleosis and to immortalize *in vitro* B-lymphocytes of humans. The association of EBV with several lymphoid malignancies, such as Burkitt's lymphoma, Hodgkin's disease and polyclonal B lymphoproliferations in immunosuppressed individuals, is well established (Niedobitek and Young, 1994).

However, the tumor showing the strongest worldwide association with EBV is nasopharyngeal carcinoma (NPC) (Pathmanathan et al., 1995) although other causative factors such as genetic susceptibility (Chan et al., 1983) and life-style factors, including diet (Yu, 1991), are postulated in NPCs of high risk geographical areas. These etiological factors and their association are in line with the concept that tumorigenesis is a multistep process with accumulation of genetic cellular alterations, resulting in the activation of oncogenes and/or the inactivation of tumor suppressor genes (Jones et al., 1991).

The Bcl-2 oncogene was first described by virtue of its involvement in t[14-18] [q32;q21] chromosome seen in a large number of follicular B-cell lines (Tsujiimoto et al., 1985). In t[14-18] the Bcl-2 gene is placed adjacent to the immunoglobulin (Ig) heavy-chain gene on chromosome 14q32. The consequence is deregulation of expression of the Bcl-2 with increase in Bcl-2 protein which is an important step in the pathogenesis of B-cell lymphomas. Bcl-2 differs from other oncogenes in that its product localizes to mitochondria (Hockenbery et al., 1990) with a lipophilic character, suggesting that it is perhaps a membrane-spanning protein (Tsujiimoto and Croce, 1986). Moreover, Bcl-2 uniquely blocks programmed cell death without promoting proliferation (Nuñez et al., 1990), even in cells without mitochondria (Jacobson et al., 1993) so that Bcl-2 argues for the existence of a new category of oncogenes, regulators of programmed cell death. Alterations in such oncogenes may prove to be the key events in neoplasia, extending the life span of cells and thus increasing their opportunity to acquire additional genetic aberrations

## *Bcl-2 in EBV-associated NPC*

(Korsmeyer, 1992). Moreover, immunohistochemical studies have detected Bcl-2 oncoprotein in B and T non-Hodgkin's lymphomas, lacking the t[14-18] (Pezzella et al., 1990) and furthermore, Bcl-2 has been detected in epithelial malignancies and is reported to have a prognostic value (McDonnell et al., 1992; Pezzella et al., 1993; Leek et al., 1994).

Various data suggest a close interrelation between EBV and Bcl-2. Recently, Segal et al. (1994) described how primers frequently used for detecting the major breakpoint of t[14-18] also amplify Epstein-Barr viral DNA, producing a potentially mal-interpretable polymerase chain reaction. On the other hand Bcl-2 product is known to have a high degree of homology with BHRF1, an open reading frame product in the EBV genome (Cleary et al., 1986) that disturbs epithelial cell differentiation (Dawson et al., 1995), and that by means of immunoelectron microscopy, shows similar intracellular localization to Bcl-2 (Hickish et al., 1994).

The above observations prompted us to investigate the expression of Bcl-2 in different histological types of NPC in accordance with two different classificatory schemes; we also attempted to define any relation between the expression of Bcl-2 and prognosis.

### **Materials and methods**

#### *Patients and specimens*

Formalin-fixed and paraffin-embedded tissues of 56 biopsy samples (48 primary tumors, 7 metastatic lymph nodes and one non-tumoral nasopharyngeal mucosa adjacent to the tumor) from 49 Spanish patients histologically diagnosed of NPC, were collected from the archives of the Service of Pathology at University Hospital La Fe in Valencia. The patient population comprised 29 men and 20 women aged between 15 and 83 (mean 49.8 years). All were diagnosed, treated and followed up between 1977 and 1994. Clinical and pathological data such as age, sex, initial histological diagnosis, tumor stage, therapeutic procedures and survival time were abstracted from surgical pathology reports and clinical records. Histological diagnoses were re-evaluated by two observers (FJVS and JSB) from the original slides according to two different schemes, WHO classification (Shanmugaratnam and Sobin, 1978) and the Micheau classification that accepts only two major microscopical types (Micheau et al., 1981). Clinical stages were graded according to the UICC staging classification of nasopharyngeal tumors (UICC, 1992).

#### *Immunohistology*

Serial sections of tissues were stained with anti-human Bcl-2 oncoprotein using a monoclonal mouse antibody (Dako-Bcl-2, clone 124, Code No. M887, Glostrup, Denmark) against the peptide sequence comprised of amino acids 51-54 of Bcl-2 protein (Cleary et al., 1986; Tsujimoto and Croce, 1986) and which has

been used on both frozen and paraffin-embedded tissue and validated in previous studies (Pezzella et al., 1990; Lu et al., 1993). Immunostaining with Bcl-2 was carried out on paraffin sections by use of biotinylated rabbit anti-mouse immunoglobulins and avidin biotinylated horseradish peroxidase complex (ABC complex/HRP) (Dako, Denmark) (Wood and Warnke, 1981). The monoclonal anti-Bcl-2 and biotinylated rabbit anti-mouse were used at dilutions of 1/50 and 1/200, respectively. All immunohistological sections were weakly counterstained to emphasize the absence of nonspecific immunostaining.

Negative controls were performed in every case by omitting the primary and secondary antibodies respectively from the immunohistochemical procedure. As positive control we used sections from a human follicular lymphoma t[14-18] carrier that showed (Fig. 1a,b) a characteristic staining in the neoplastic lymphoid follicles as well as a lymph node with reactive follicular hyperplasia showing Bcl-2 immunostaining of small lymphocytes, both in T-cell areas and in mantle zones.

Immunohistological sections were interpreted and evaluated by simultaneous viewing of the slides by two observers (FJVS and JSB) in a blind fashion without any knowledge of the clinical outcome. Immunostaining for Bcl-2 was visually classified into four groups: no staining present in any of the neoplastic epithelial cells (-), slight staining in some or in most of the neoplastic cells (+), moderately strong staining (++), or strong staining present in almost all neoplastic cells (+++).

In order to evaluate statistical significance of immunohistochemical results in relation to histological types and other studies parameters, the chi-square test was applied. A p-value of <0.05 was considered significant.

#### *EBV-DNA detection*

Genomic DNA was extracted from paraffin-embedded tissues following standard procedures (Maniatis et al., 1982). Cross-contamination of samples and false positive PCRs were carefully avoided by frequent changing of gloves, use of positive displacement pipettes and strict spatial separation of the three main PCR steps (preparation of reaction mix, addition of target and amplification and manipulation of PCR products).

DNA presence was verified by amplification of the  $\beta$ -globin gene, with the primers GH20 and PC04 (Innis et al., 1990). A 268 bp fragment was obtained and detected after electrophoresis, when DNA extraction was positive. This presence was also verified and quantified by spectrophotometric analysis absorbance at 260 nm. EBV-DNA detection was carried out with the nested-PCR technique. The DNA concentration used was 0.1 to 0.5  $\mu$ g per 100  $\mu$ l. We employed two primer sets (EB-3,4 and EB-1,2) that amplified a 297 bp or a 209 bp fragment from the EBNA-1 (Cinque et al., 1993). Amplification was done in two successive rounds. The



### Bcl-2 in EBV-associated NPC

total reaction contained 50 mmol/L potassium chloride, 10 mmol/L tris HCl pH 8.4, 2.5 mmol/L magnesium chloride, 400  $\mu$ mol/L of each dNTP, 0.15  $\mu$ mol/L of primers EB-3 and EB-4 in the first round and 0.30  $\mu$ mol/L of primers EB-1 and EB-2 in the second round, as well as 1 unit of ampliTaQ DNA polymerase (Roche Molecular System, Inc., Brachburg, NJ, USA). The final reaction volume in each round was 100  $\mu$ l. The first round was composed of 1 cycle of 95 °C (3 min), 20 cycles of 95 °C (1 min) - 55 °C (1 min) - 72 °C (1 min) and 1 cycle of 72 °C (10 min). The second round consisted of 1 cycle of 95 °C (3 min), 30 cycles of 95 °C (1 min) - 60 °C (1 min) - 72 °C (1 min) and 1 cycle of 72 °C (10 min). PCR was performed in an automated thermal cycler (Perkin-Elmer Cetus). After the first amplification with the EB-3 and 4 primers, 5  $\mu$ l were transferred from the first to the second reaction mixture. After the second amplification with the EB-1 and 2 primers, 17  $\mu$ l of the amplified product from the second mixture were electrophoresed in a 2% agarose gel containing 0.5  $\mu$ g/mL ethidium bromide.

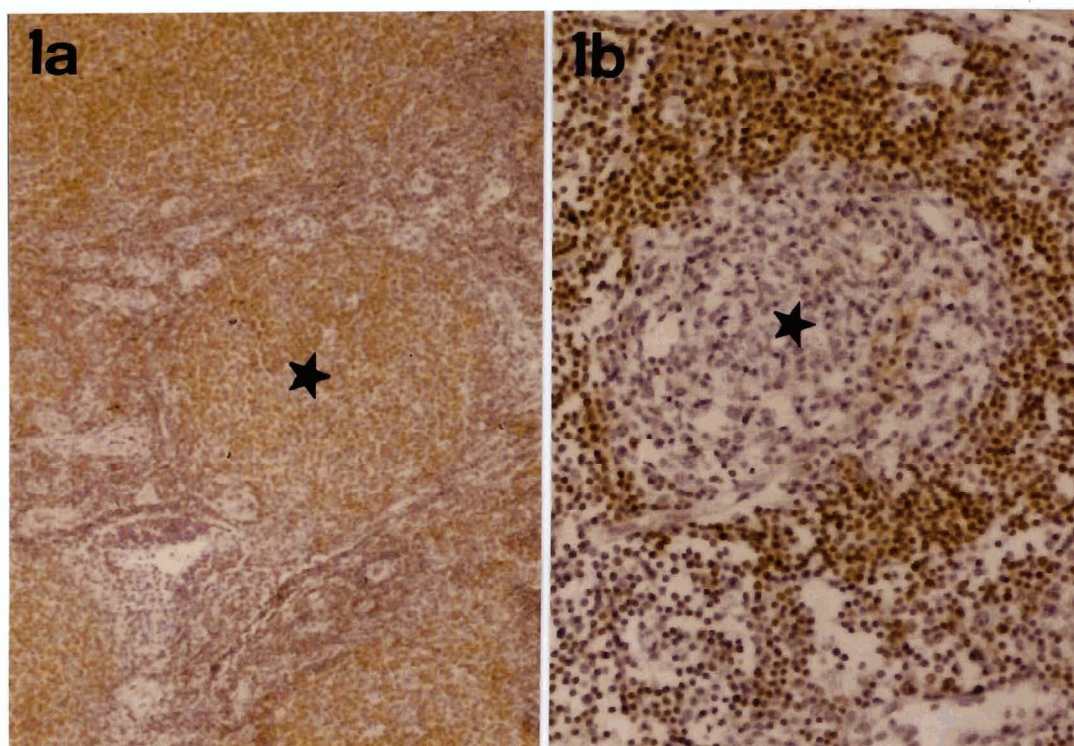
The resulting gel was photographed under ultraviolet illumination and regarded as positive when a band corresponding to the 209 bp fragment was present. The specificity of the amplified fragment visualized on the agarose gel was confirmed by a non-radioactive assay (DNA enzyme immunoassay, GEN-ETI-K-DEIA, Sorin Biomedical, Saluggia, Italy). Two types of controls were used: as amplification positive control, a case of post-transplant lymphoma (data not shown) studied

previously as an EBV carrier (in this case, a 209 bp band appeared after electrophoresis); as negative control, normal samples from healthy individuals negative for EBV-DNA and sterile distilled water were used. All samples were tested at least twice in different experiments and the samples considered positive either in the case of concordant results or when a positive result could be confirmed by a subsequent experiment.

### Results

NPC samples were histologically classified, according to Micheau's classification, as undifferentiated carcinoma of nasopharyngeal type (UCNT) and squamous cell carcinoma (SCC) in 45 and 10 cases respectively. Considering the WHO scheme, NPC samples were morphologically classified as keratinizing squamous cell carcinoma (SCC) (WHO type 1), non-keratinizing squamous cell carcinoma (NKC) (WHO type 2) and undifferentiated carcinoma (UC) (WHO type 3) in 10, 13 and 32 cases respectively. In addition, one tissue sample of non-tumoral nasopharyngeal mucosa adjacent to NPC was also available for immunohistochemical and molecular study.

Bcl-2 immunostaining at cellular level in NPC was predominantly cytoplasmic, extending to the nuclear membrane, although occasionally we could also observe an associated cytoplasmic membranous pattern (Figs. 2, 3). Generally the mitotic neoplastic cells, above all in UC, showed cytoplasmic positivity (Fig. 4a,b),

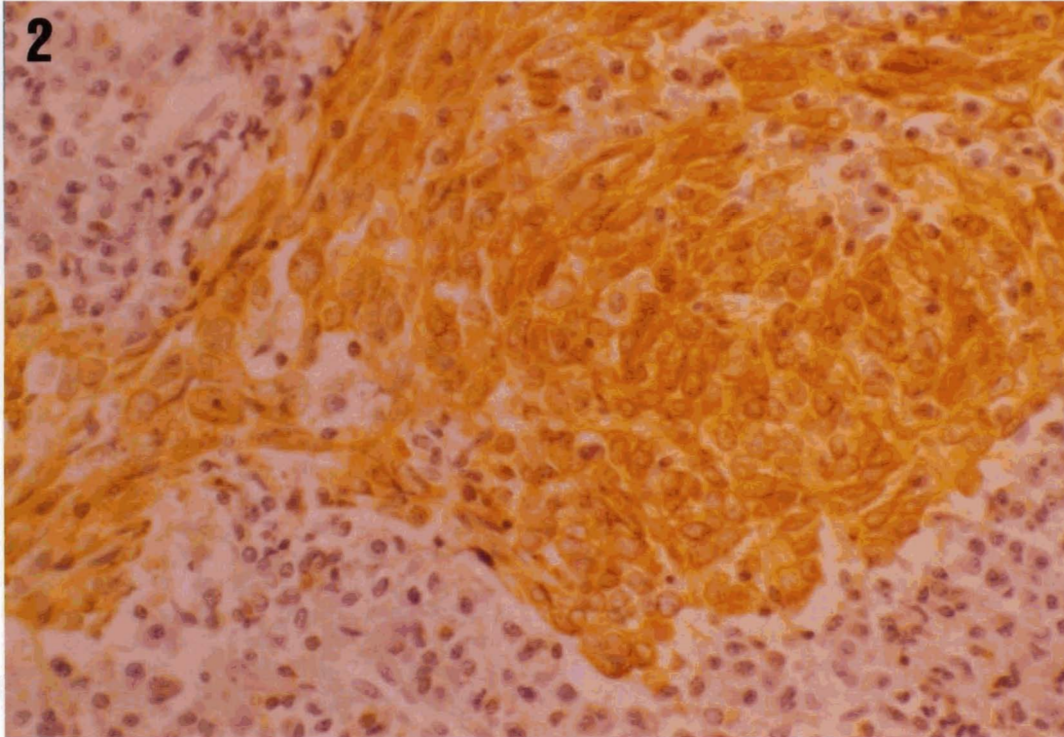


**Fig. 1.** Bcl-2 immunostaining in control samples. Bcl-2, ABC.  
**a.** Follicular lymphoma with positive reaction in neoplastic lymphoid follicles (asterisk). x 200  
**b.** Reactive lymphadenitis showing staining of small lymphocytes in follicular mantle zone, unlike clear center is negative (asterisk). x 400

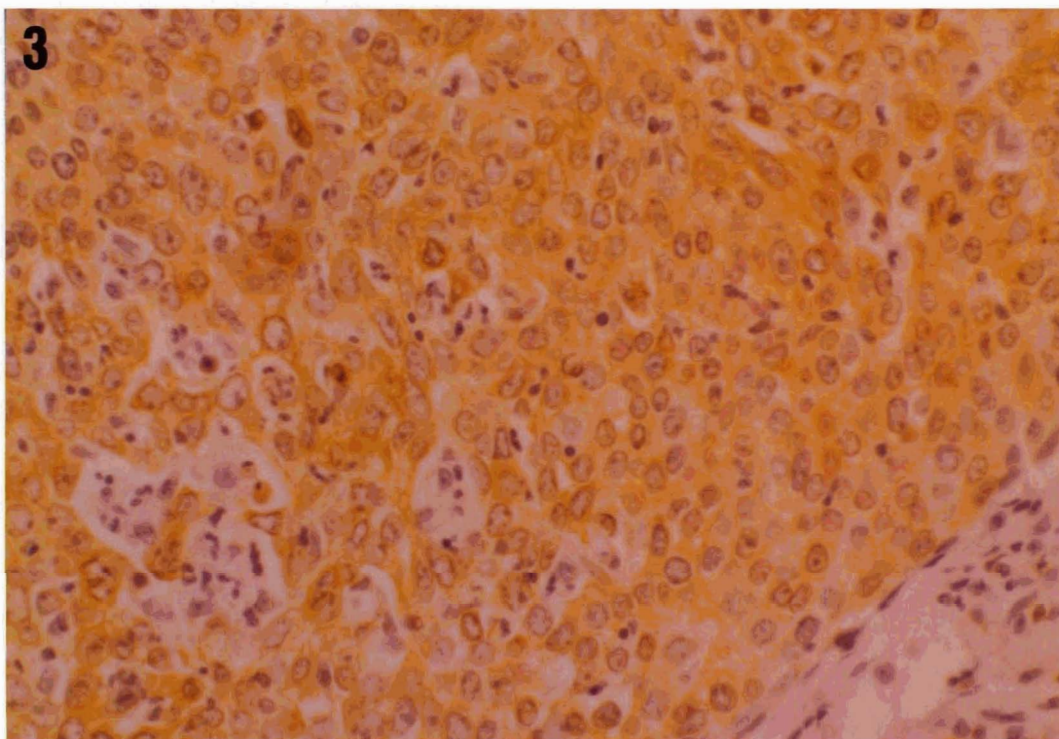


associated to mitotic chromosomal staining, but the immunostaining of chromosomes of dividing cells was more readily apparent in cases with slight or without

cytoplasmic Bcl-2 reactivity. Bcl-2 positive staining was also observed in the basal layer of benign nasopharyngeal mucosa occasionally present in the NPC



**Fig. 2.** Non-keratinizing squamous cell carcinoma (NKC) (WHO type 2) showing cytoplasmic and, up to a point, membranous Bcl-2 immunostaining at neoplastic cell level. Bcl-2, ABC. x 400

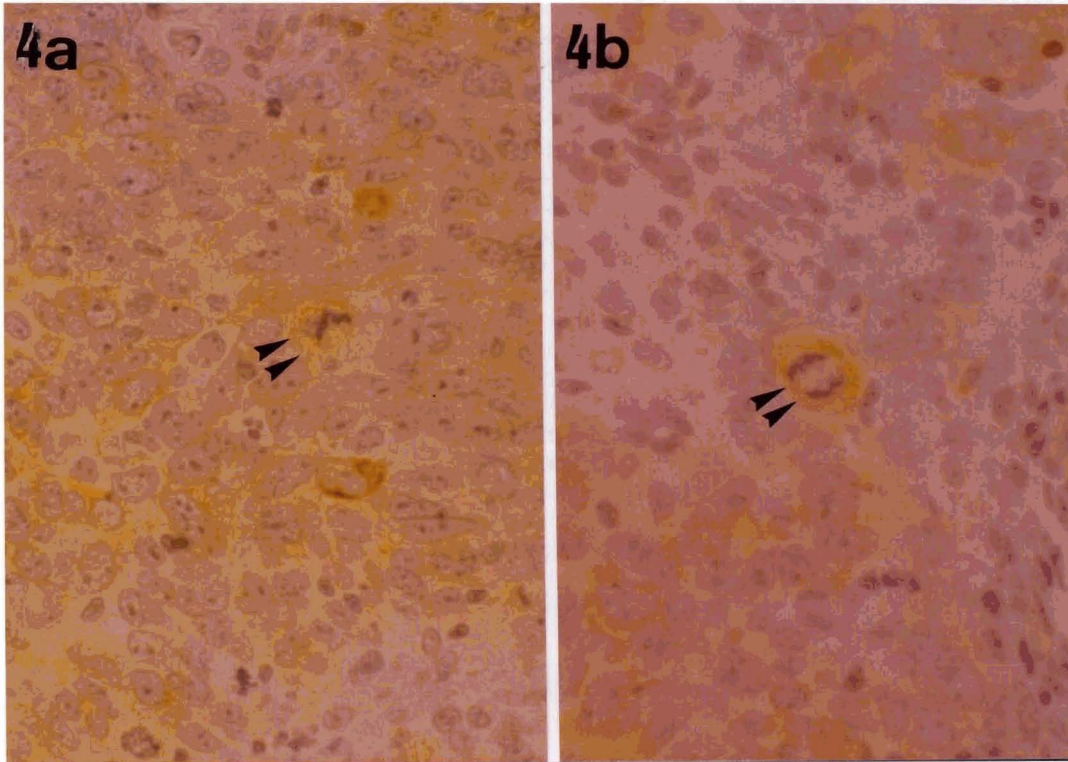


**Fig. 3.** Undifferentiated carcinoma (UC) (WHO type 3) with predominantly cytoplasmic reactivity for Bcl-2 oncoprotein. Bcl-2, ABC. x 400

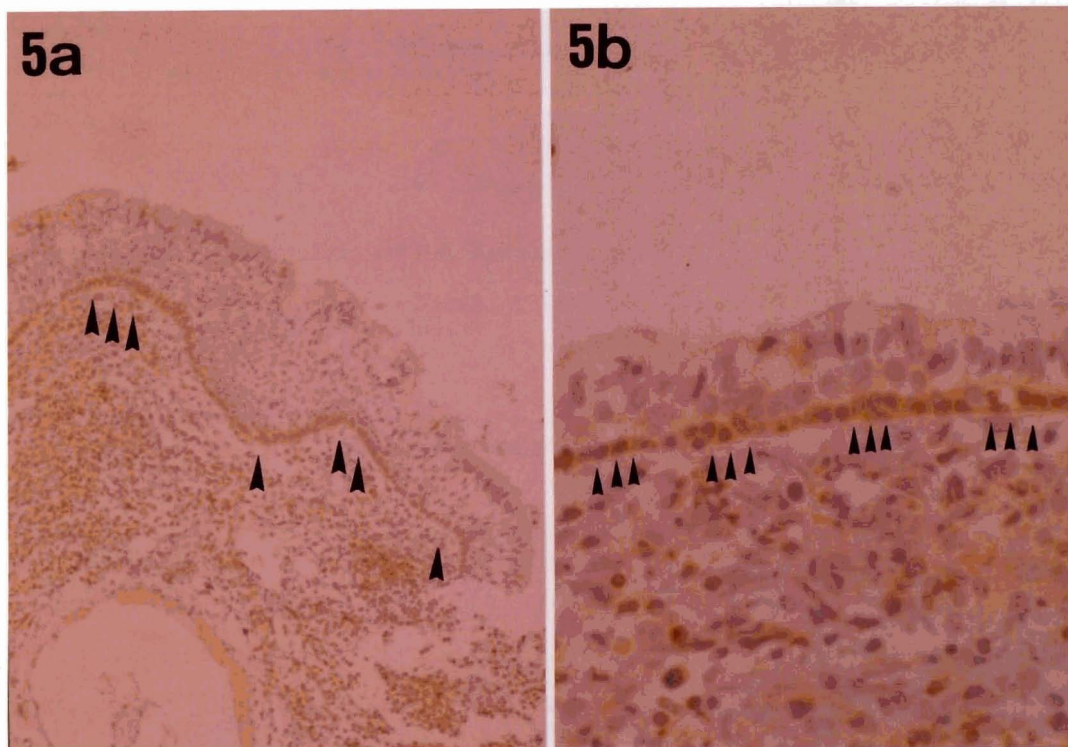


samples (Fig. 5a,b). This basal layer staining was consistent from case to case, regardless of the reactivity of the tumor cells. Likewise, in a non-tumoral naso-

pharyngeal mucosa sample positive Bcl-2 staining was present in the malpighian basal layer. Moreover, some small lymphocytes adjacent to or intermingled with the



**Fig. 4.** Examples of mitotic neoplastic cells (arrows) with Bcl-2 strong cytoplasmic positivity in comparison with the neighboring tumor cells. Bcl-2, ABC. x 400



**Fig. 5.** Marked and constant reactivity of basal layer cells in benign nasopharyngeal mucosa (arrows), both malpighian (a) and pseudostratified (b). Bcl-2, ABC. a, x 100; b, x 250

## Bcl-2 in EBV-associated NPC

**NPC nests were Bcl-2 immunoreactive** as well. Usually, in Bcl-2 positive-NPC cases, the intensity of Bcl-2 staining in tumor cells was stronger than in the benign cells (mucosal basal layer and infiltrating small lymphocytes).

An overall Bcl-2 gene product positive immunostaining was observed in 42 out of 55 (76.4%) NPC cases. No significant differences were found when correlating Bcl-2 positivity with NPC location (primary or metastatic character), clinical stage and age or sex of the patients (Table 1).

In correlating Bcl-2 staining with NPC histological type, according to the WHO classification, positive staining was observed in 30 out of 32 (93.8%) UC, 10 out of 13 (76.9%) of NKC and only in 2 out of 10 (20%) SCC (Table 2). These differences were not statistically significant with a p value of 0.10-0.05. However, when correlating Bcl-2 expression with only two major histological types (UCNT and SCC), according to Micheau's scheme (Table 3), the difference (88.9%

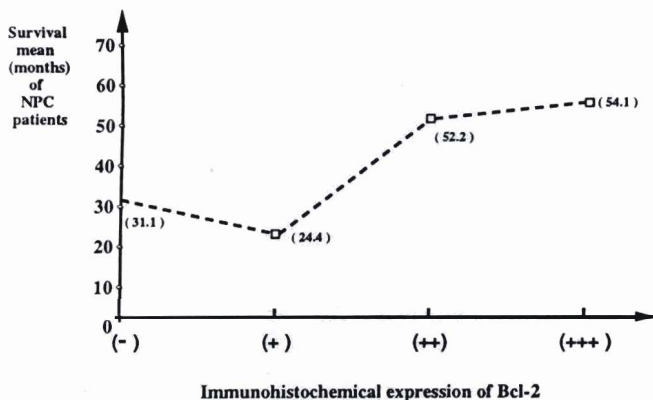
Bcl-2 positive undifferentiated carcinomas and only 20% of Bcl-2 positive squamous cell carcinoma) was statistically significant ( $p < 0.05$ ). Likewise, when comparing Bcl-2 immunohistochemical expression and known survival mean of the patients, significant differences ( $p < 0.001$ ) were observed, so that mean survival times were 31.1 months for Bcl-2 negative NPC patients and 24.4 months, 52.2 months and 54.1 months for NPC patients with Bcl-2-positivity of (+), (++) and (+++), respectively (Table 4) (Fig. 6).

DNA from paraffin of all samples used for the immunohistochemical study was also extracted and PCRs run for  $\beta$ -globin and EBV-DNA. A total of 55 samples of NPC and one normal nasopharyngeal mucosa sample adjacent to NPC was available for amplification, whereas in only one case no  $\beta$ -globin specific product was obtained. In successful cases extraction of human DNA from the samples was confirmed by amplification of the  $\beta$ -globin gene, and EBV-DNA was detected in 100% of these samples (55 samples) (Fig. 7) with sufficient quality to permit viral diagnosis. Therefore, in our study EBV-DNA positivity in NPC was not influenced by histological type, Bcl-2 expression or any other parameter.

**Table 1.** Expression of Bcl-2 protein related to clinicopathological characteristics of NPC.

VARIABLE	EXPRESSION OF Bcl-2			$\chi^2$	p*
	Number	Positive	Negative		
<i>Clinical stage</i>					
Stage I	-	-	-	-	-
Stage II	3	2	1	0.08	>0.95
Stage III	6	5	1		
Stage IV	44	33	11		
<i>Location</i>					
Primary site	7	6	1	0.091	0.90-0.70
Metastatic lymph node	48	36	12		
<i>Sex</i>					
Males	34	24	10	0.240	0.70-0.50
Females	21	18	3		
Mean age	55	47.6	50.9	0.121	0.90-0.70

\*: Chi square test.



**Fig. 6.** Graph showing the relationship between the levels of immunohistochemical Bcl-2 expression and the mean survival time of NPC patients expressed in months

## Discussion

The current study documents a high prevalence (42 out of 55) (76.4%) of Bcl-2 cytoplasmic immuno-

**Table 2.** Comparison of Bcl-2 expression and NPC histological type (WHO).

HISTOLOGICAL TYPE	NUMBER OF CASES	Bcl-2 NEGATIVE	Bcl-2 POSITIVE	$\chi^2$	p
WHO 1 (SCC)	10	8	2	5.242	0.10-0.05
WHO 2 (NKC)	13	3	10		
WHO 3 (UC)	32	2	30		

**Table 3.** Comparison of Bcl-2 expression and NPC histological type\*.

HISTOLOGICAL TYPE	NUMBER OF CASES	Bcl-2 NEGATIVE	Bcl-2 POSITIVE	$\chi^2$	p
SCC	10	2	8	5.082	<0.05
UCNT	45	5	40		

\*: Micheau et al. (1981) classification.

**Table 4.** Bcl-2 expression and survival mean.

Survival mean (months) of NPC patients	Bcl-2 IMMUNOHISTOCHEMICAL EXPRESSION				$\chi^2$	P VALUE
	(-)	(+)	(++)	(+++)		
	31.1	24.4	52.2	54.1	16.302	<0.001

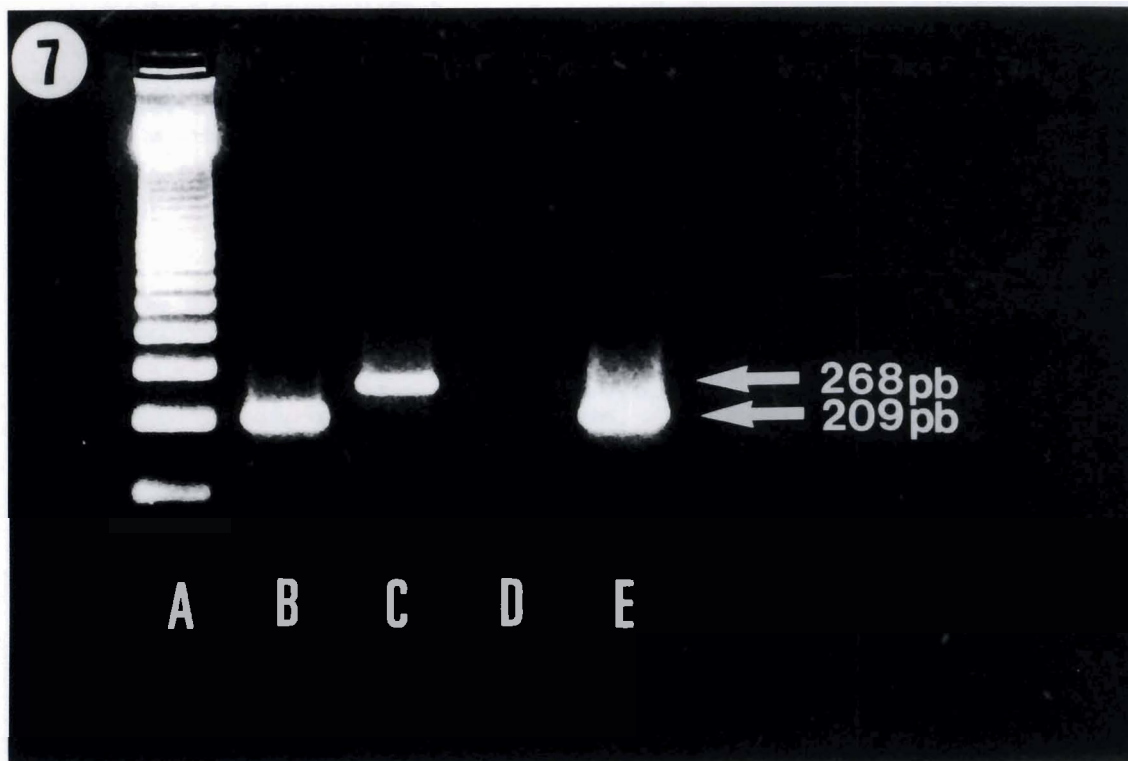


reactivity in a series of 55 biopsy samples of NPC, which likewise were screened with 100% positivity for the presence of EBV-DNA by means of sensitive nested polymerase chain reaction. Bcl-2 expression was particularly common, with significant differences in UC (88,9% of positive causes) when a histological classificatory scheme with only two major categories (Micheau's classification) was employed. This latter finding revives in part an old issue concerning the usefulness of histological classification of NPC in two major types (Micheau, 1986), at the same time suggesting an inverse relationship between the expression of Bcl-2 oncoprotein and the level of NPC differentiation, as has been recently indicated by others (Kouvidou et al., 1995).

The association of NPC with EBV is well documented, but the possible association of squamous cell NPC with the virus has been addressed previously with conflicting results. SCC-NPC, in contrast to SCC occurring in other regions of the head and neck region, is the least common type of NPC, and in this study represented only 18.1% of the NPC samples analyzed. It has been suggested, on the basis of serological data and earlier EBV DNA hybridization studies, that SCCs and undifferentiated carcinomas (UNPC) are different diseases (Pearson et al., 1983; Niedobitek et al., 1991). In our study EBV-DNA amplification indicated that EBV is uniformly associated with NPC regardless of histological type, supporting recent studies (Pathmanathan et al., 1995) which in turn suggest that all

histological types of NPC are in fact variants of EBV-infected neoplasia, although EBV probably plays a different oncogenic role in SCC than in UNPC, given that the viral genome copy is high in UNPC but low in SCC (Raab-Traub et al., 1987; Pathmanathan et al., 1995). This different viral load probably explains the failure referred to by others (Niedobitek et al., 1991; Yeung et al., 1993) in detecting EBV-DNA by *in situ* hybridization (ISH) in SCC because of lesser sensitivity of this last assay to detect smaller amounts of EBV (Ohshima et al., 1995), and in this sense for detection of such potentially low levels of target DNA, amplification by PCR is much more appropriate than ISH.

The high prevalence of Bcl-2 detected in NPC is consistent with the frequent immunoreactivity of this oncoprotein exhibited by the basal layer cells of nasopharyngeal normal mucosa, at the same time that Bcl-2 protein produces a significant extension of cell survival, and extended cell survival may be considered a key event either in cell transformation or in tumor growth (Korsmeyer, 1992). In our study we observed a frequent Bcl-2 expression in normal epithelial cells of basal layer when a non-tumoral nasopharyngeal mucosa was present in NPC samples. This datum is in accordance with previous studies stating that Bcl-2 gene product appears to be preferentially expressed in long-lived cells, including the basal (regenerative) cell compartment in intestinal epithelia, epidermis, bronchial epithelia, breast, thyroid and prostate (Hockenberry et al., 1991; MacDonald et al., 1992; Pezzella et al., 1993).



**Fig. 7.** Gel electrophoresis of amplified products after PCR. **Lane A:** molecular mass marker. **Lane B:** EBV-positive control. **Lane C:** amplification of  $\beta$ -globin gene (268 bp). **Lane D:** negative EBV control (sterile distilled water). **Lane E:** NPC case showing a band corresponding to product amplified size of 209 pb.

## Bcl-2 in EBV-associated NPC

This fact suggests that Bcl-2 may serve to maintain the stem-cell pool by allowing certain cells to avoid following a program of postmitotic differentiation with eventual senescence and death (Le Brun et al., 1993).

In our NPC samples we also found a well built-in positive control for Bcl-2 in small infiltrating lymphocytes. Indeed, NPC are malignant epithelial neoplasms often infiltrated by a dense population of non-neoplastic lymphocytes, composed primarily of T cells (Vera-Sempere, 1988). Immunostaining of some small infiltrating lymphocytes in NPC stroma supports the previous view that Bcl-2 protein is immunohistochemically detectable as a normal constituent of many B and T lymphocytes without t(14:18) in peripheral blood and in lymphoid tissue (Pezella et al., 1990).

Bcl-2 protein expression in relation to epithelial neoplasm component, was characterized mainly by the occurrence of cytoplasmic staining extending to the nuclear membrane, above all in UNPC (40 out of 45 cases), the intensity of staining being usually stronger than that observed in small infiltrating lymphocytes of tumoral stroma and in normal epithelial basal cells of nasopharyngeal mucosae.

A common finding in our study was the strong Bcl-2 immunostaining to the chromosomes of neoplastic epithelial cells in mitosis. Surprisingly this latter finding has been previously reported only once in the literature regarding Bcl-2 immunohistochemistry in human tissues (Chan et al., 1995), and which raises many questions about the possible cellular compartmentalization of Bcl-2 and its mechanism of action. Bcl-2 gene product is generally thought to be an inner mitochondrial protein (Hockenbery et al., 1990), but recently it has also been located, in line with our findings, on the cytoplasmic side of the nuclear membrane (Monaghan et al., 1992), as well as on chromosomes at specific times of the cell cycle in cell lines (Lu et al., 1994).

In our study, Bcl-2 protein expression appears independent of the constant presence of EBV-DNA detected by a sensitive nested-PCR. A similar lack of correlation has been observed between Bcl-2 expression and EBV presence detected by means of ISH of EBV-DNA (Lu et al., 1993) and EBV-EBER-mRNA (Kouvidou et al., 1995). Thus, we conclude that Bcl-2 is abnormally expressed in UNPC, and that there appears to be no correlation of Bcl-2 overexpression with EBV infection. Similarly, a lack of correlation *in vivo* has been detected between Bcl-2 and LMP-1 expression by others (Lu et al., 1993) and ourselves (data not shown) (Vera-Sempere et al., 1996) in NPC. However, these findings do not completely exclude the possibility that EBV encoded protein, other than LMP-1 influences the expression of Bcl-2 (Lu et al., 1993; Tao et al., 1994; Kouvidou et al., 1995).

The pathogenesis of Bcl-2 protein expression in solid tumors is unknown. Immunostaining for Bcl-2 has, apart from lymphomas, been reported for prostatic cancers (MacDonnell et al., 1992; Colombel et al., 1993), lung cancers (Ohmori et al., 1993; Pezella et al., 1993),

renal cell tumors (Paraf et al., 1995), neuroectodermal tumors including neuroblastoma (Reed et al., 1991; Swanson et al., 1993) and in a few hepatocellular carcinomas (Zhao et al., 1994). In some of these solid tumors (non-Hodgkin's lymphomas, non-small cell lung carcinomas and in hormone-refractory human prostate cancers) (Colombel et al., 1993; Leoncini et al., 1995; Pezella et al., 1993), Bcl-2 expression may have prognostic importance, and also in breast cancer, loss of Bcl-2 expression is associated with a range of poor prognostic molecular markers including EGFR, C-erbB-2 and p53 positivity (Leek et al., 1994) and predicting a short recurrence-free survival (Lipponen et al., 1995) although an independent prognostic value is absent (Joensuu et al., 1994), at least in breast cancer with axillary lymph node positive tumors (Silvestrini et al., 1994).

Our results support these data, so that when comparing Bcl-2 immunohistochemical expression and known survival mean of the patients, significant differences ( $p < 0.001$ ) were observed. These results suggest the hypothesis that NPC patients with Bcl-2 expression do have a better clinical outcome and it is possible that Bcl-2 may be a new prognostic marker in NPC, in addition to other recently proposed parameters, such as EGFR and Ki67 (Zeng et al., 1994), as well as EBV-LMP1 expression (Hu et al., 1995). However, the prognostic significance of Bcl-2 in NPC may also depend on the histological type, due to the close relationship with UNPC. Only studies of large series of cases with long-term follow-up may document, with multivariate analysis, whether Bcl-2 expression has independent prognostic relevance in behavior of NPC patients.

---

*Acknowledgements.* This study was supported in part by Grant No. 1590/94 from the Fondo de Investigaciones Sanitarias (FIS), Madrid, Spain.

---

## References

- Chan S.H., Day N.E., Kunaratnam N., Chia K.B. and Simons M.J. (1983). HLA and nasopharyngeal carcinoma in Chinese- a further study. *Int. J. Cancer* 32, 171-176.
- Chan K.W., Mole M.M., Levison D.A., Ball R.Y., Lu Q.L., Patel K. and Hanby A.M. (1995). Nuclear and cytoplasmic bcl-2 expression in endometrial hyperplasia and adenocarcinoma. *J. Pathol.* 177, 241-246.
- Cleary M.L., Smith S.D. and Sklar J. (1986). Cloning and structural analysis of cDNAs for bcl-2 and a hybrid bcl-2/immunoglobulin transcript resulting from the t(14:18) translocation. *Cell* 47, 19-28.
- Cinque P., Brytting M., Vago L., Castagna A., Parravicini C., Zancheta N., Monforte A.A., Wharen B., Lazzarin A. and Linde A. (1993). Epstein-Barr virus DNA in cerebrospinal fluid from patients with AIDS-related primary lymphoma of the central nervous system. *Lancet* 342, 398-401.
- Colombel M., Synmans F., Gil S., O'Toole K.M., Chopin D., Benson M., Olsson C.A., Korsmeyer S. and Buttyan R. (1993). Detection of the



*Bcl-2 in EBV-associated NPC*

- apoptosis-suppressing oncoprotein bcl-2 in hormone-refractory human prostate cancers. *Am. J. Pathol.* 143, 390-400.
- Dawson C.W., Eliopoulos A.G., Dawson J. and Young L.S. (1995). BHRF1, a viral homologue of the Bcl-2 oncogene, disturbs epithelial cell differentiation. *Oncogene* 10, 69-77.
- Hickish T., Robertson D., Clarke P., Hill M., Stefano F., Clarke C. and Cunningham D. (1994). Ultrastructural localization of BHRF1: an Epstein-Barr virus gene product which has homology with bcl-2. *Cancer Res.* 54, 2808-2811.
- Hockenbery D., Nuñez G., Millman C., Scriver R.D. and Korsmeyer S.J. (1990). Bcl-2 is an inner mitochondrial membrane protein that blocks programmed cell death. *Nature* 348, 334-336.
- Hockenbery D.M., Zutter M., Hickey W., Nahm M. and Korsmeyer S.J. (1991). Bcl-2 protein is topographically restricted in tissues characterized by apoptotic cell death. *Proc. Natl. Acad. Sci. USA* 88, 6961-6965.
- Hu L.F., Chen F., Zhen Q.F., Zhang Y.W., Luo Y., Zheng X., Winberg G., Erberg I. and Klein G. (1995). Differences in the growth pattern and clinical course of EBV-LMP1 expressing and non-expressing nasopharyngeal carcinomas. *Eur. J. Cancer* 31, 658-660.
- Innis M.A., Gelfand D.H., Sninsky J.J. and White T.J. (1990). *PCR Protocols. A guide to methods and applications.* Academic Press. San Diego, California.
- Jacobson M.D., Burne J.F., King M.P., Miyashita T., Reed J.C. and Raff M.C. (1993). Bcl-2 blocks apoptosis in cells lacking mitochondrial DNA. *Nature* 361, 365-369.
- Joensuu H., Pylkkänen L. and Toikkanen S. (1994). Bcl-2 protein expression and long-term survival in breast cancer. *Am. J. Pathol.* 145, 1191-1198.
- Jones P.A., Buckley J.P., Henderson B.E., Ross R.K. and Pike M.C. (1991). From gene to carcinogen: a rapidly evolving field in molecular epidemiology. *Cancer Res.* 51, 3617-3620.
- Korsmeyer S.J. (1992). Bcl-2 initiates a new category of oncogenes: regulators of cell death. *Blood* 80, 879-886.
- Korsmeyer S.J. (1992). Bcl-2: an antidote to programmed cell death. *Cancer Surveys* 15, 105-117.
- Kouvidou Ch., Kanavaros P., Papaioannou D., Stathopoulos E., Sotsiou F., Datsis G., Tzardi M., Kittas C. and Delides G. (1995). Expression of bcl-2 and p53 proteins in nasopharyngeal carcinoma. Absence of correlation with the presence of EBV encoded EBER1-2 transcripts and latent membrane protein-1. *J. Clin. Pathol. Mol. Pathol.* 48, M17-M22.
- LeBrun D.P., Warnke R.A. and Cleary M.L. (1993). Expression of Bcl-2 in fetal tissues suggests a role in morphogenesis. *Am. J. Pathol.* 142, 743-753.
- Leek R.D., Kaklamanis L., Pezella F., Gatter K.C. and Harris A.L. (1994). Bcl-2 in normal breast and carcinoma. Association with oestrogen receptor-positive, epidermal growth factor, receptor-negative tumours and in situ cancer. *Br. J. Cancer* 69, 135-139.
- Leoncini L., Del Vecchio M.T., Spina D., Megha T., Barbini P., Sabatini E., Pileri S., Tosi P., Kraft R., Laisue J.A. and Cottier H. (1995). Presence of the bcl-2 protein and apoptosis in non-Hodgkin lymphomas with diffuse growth pattern. *Int. J. Cancer* 61, 826-831.
- Lipponen P., Piiläinen T., Kosma V.M., Aaltomaa S., Eskelinen M. and Syrjänen K. (1995). Apoptosis suppressing protein bcl-2 is expressed in well-differentiated breast carcinomas with favourable prognosis. *J. Pathol.* 177, 49-55.
- Lu Q.L., Elia G., Lucas S. and Thomas J.A. (1993). Bcl-2 protooncogene expression in Epstein-Barr virus associated nasopharyngeal carcinoma. *Int. J. Cancer* 53, 29-35.
- Lu Q.L., Hanby A.M., Hajibagheri M.A.N., Gschmeissner S.E., Lu P.J., Taylor-Papadimitriou J., Krajewski S., Reed J.C. and Wrigth N.A. (1994). Bcl-2 protein localizes to the chromosomes of mitotic nuclei and is correlated with the cell cycle in epithelial cell lines. *J. Cell Sci.* 107, 363-371.
- Maniatis T., Fritsch E.F. and Sambrook J. (1982). *Molecular cloning: a laboratory manual* (Cold Spring Harbor Laboratory Press). Cold Spring Harbor, NY. pp E3-E14.
- McDonnell T.J., Troncoso P., Brisbay S.M., Logothetis C., Chung L.W., Hsieh J.T., Tu S.M. and Campbell M.L. (1992). Expression of the protooncogene bcl-2 in prostate and its association with emergence of androgen-independent prostate cancer. *Cancer Res.* 52, 6940-6944.
- Micheau C. (1986). What's new in histological classification and recognition of nasopharyngeal carcinoma? *Pathol. Res. Pract.* 181, 249-253.
- Micheau C., De-Thé G., Orofiamma B., Schwaab G., Brugere J., Tursz T., Sancho-Garnier H. and Cachin Y. (1981). Practical value of classifying NPC in two major microscopical types. In: *Nasopharyngeal carcinoma. Cancer Campaign. Vol 5.* Grundman E., Krueger G. and Ablashi D.V. (eds). Gustav-Fischer. New York, Stuttgart. pp 51-57.
- Monaghan P., Robertson D., Amos T.A., Dyer M.J., Maso D.Y. and Greaves M.F. (1992). Ultrastructural localization of bcl-2 protein. *J. Histochem. Cytochem.* 40, 1819-1825.
- Niedobitek G. and Young L.S. (1994). Epstein-Barr virus persistence and virus-associated tumors. *Lancet* 343, 333-335.
- Niedobitek G., Agathangeolu A., Barber P., Smallman L.A., Jones E.L. and Young L. (1991). Epstein-Barr virus and carcinomas: undifferentiated carcinomas but not squamous cell carcinomas of the nasopharynx are regularly associated with the virus. *J. Pathol.* 165, 17-24.
- Nuñez G., London L., Hockenbery D., Alexander M., McKearn J. and Korsmeyer S.J. (1990). Deregulated bcl-2 gene expression selectively prolongs survival of growth factor-deprived homopoietic cell lines. *J. Immunol.* 144, 3602-3610.
- Ohmori T., Podack E.R., Nishio K., Takahashi T., Miyahara Y., Takeda Y., Kubota N., Funayama Y., Ogasawara H. and Ohira T. (1993). Apoptosis of lung cancer cells caused by some anti-cancer agents (MMC, CPT-11, ADM) is inhibited by bcl-2. *Biochem. Biophys. Res. Commun.* 192, 30-36.
- Ohshima K., Kikuchi M., Kobari S., Masuda Y., Yoneda S. and Takeshita M. (1995). Demonstration of Epstein-Barr virus genomes, using polymerase chain reaction in situ hybridization in paraffin-embedded lymphoid tissues. *Pathol. Res. Pract.* 191, 139-147.
- Paraf F., Gogusev J., Chretien Y. and Droz D. (1995). Expression of bcl-2 oncoprotein in renal cell tumors. *J. Pathol.* 177, 247-252.
- Pathmanathan R., Prasad U., Chandrika G., Sadler R., Flynn K. and Raab-Traub N. (1995). Undifferentiated nonkeratinizing, and squamous cell carcinoma of the nasopharynx. Variants of Epstein-Barr virus-infected neoplasia. *Am. J. Pathol.* 146, 1355-1367.
- Pearson G.R., Welland L.H., Nell H.B., Taylor W., Earle J., Mulrone S.E., Goepfert H., Lanier A., Talvot M.L., Pilch B., Goodman M., Huang A., Levine P.H., Hyams V., Moran E., Henle G. and Henle W. (1983). Applications of Epstein-barr virus (EBV) serology to the diagnosis of North American nasopharyngeal carcinoma. *Cancer* 51, 260-268.
- Pezzella F., Tse A.G.D., Cordell J.L., Pulford K.A., Gatter K.C. and

## *Bcl-2 in EBV-associated NPC*

- Mason D.Y. (1990). Expression of the bcl-2 oncogene protein is not specific for the 14,18 chromosomal translocation. *Am. J. Pathol.* 137, 225-232.
- Pezzella F., Turley H., Kuzu I., Tungekar M.F., Dunnill M.S., Pierce C.B., Harris A., Gutter K.C. and Mason D.Y. (1993). Bcl-2 protein in non-small-cell lung carcinoma. *N. Engl. J. Med.* 329, 690-694.
- Raab-Traub N., Flynn K., Pearson G., Huang A., Levine P., Lanier A., Pagano J.S. (1987). The differentiated form of nasopharyngeal carcinoma contains Epstein-Barr virus DNA. *Int. J. Cancer* 39, 25-29.
- Reed J.C., Meister L., Tanaka S., Cuddy M., Yum S., Geyer C. and Pleasure D. (1991). Differential expression of bcl-2 protooncogene in neuroblastoma and other human cell lines of neural origin. *Cancer Res.* 51, 6529-6558.
- Shanmugaratnam K. and Sobin L.H. (1978). Histological typing of upper respiratory tract tumours. International histological classification of tumours. N<sup>o</sup> 19. Geneva. WHO.
- Segal G.H., Scott M., Jorgensen T. and Braylan R.C. (1994). Primers frequently used for detecting the t(14:19) major breakpoint also amplify Epstein-Barr viral DNA. *Diagn. Mol. Pathol.* 3, 15-21.
- Silvestrini R., Veneroni S., Daidone M.G., Benini E., Boracchi P., Mezzetti M., Di Franzo G., Rilke F. and Veronesi U. (1994). The bcl-2 protein: a prognostic indicator strongly related to p53 protein in lymph node-negative breast cancer patients. *J. Natl. Cancer Inst.* 86, 499-504.
- Swanson P.E., Humphrey P.A. and Dehner L.P. (1993). Immunoreactivity for bcl-2 protein in peripheral primitive neuroectodermal tumors. *Appl. Immunohistochem.* 1, 182-187.
- Tao Q., Srivastava G., Loke S.L. and Ho F.C.S. (1994). Lack of correlation between expression of Epstein-Barr virus (EBV) latent membrane protein and bcl-2 oncoprotein in vivo. *J. Clin. Pathol.* 47, 589-591.
- Tsujimoto Y. and Croce C.M. (1986). Analysis of the structure, transcripts and protein products of bcl-2, the gene involved in human follicular lymphoma. *Proc. Natl. Acad. Sci. USA* 83, 5214-5218.
- Tsujimoto Y., Gorham J., Cossman J., Jaffe E. and Croce C.M. (1985). The t(14:18) chromosome translocation involved in B-cell neoplasms results from mistakes in VDJ joining. *Science* 299, 1390-1393.
- UICC (1992). TNM Atlas. Illustrated guide to the TNM/pTNM classification of malignant tumours. Third Edition. 2nd Revision 1992. Springer-Verlag, Berlin, Heidelberg. pp 20-32.
- Vera-Sempere F.J. (1988). Carcinoma de nasofaringe. Estado actual de su diagnóstico morfológico. *Med. Clin.* 91, 589-595.
- Vera-Sempere F.J., Burgos J.S., Botella M.S., Córdoba J. and Gobernando M. (1996). Immunohistochemical expression of Epstein-Barr virus (EBV)-encoded latent membrane protein (LMP-1) in paraffin sections of EBV-associated nasopharyngeal carcinoma (NPC) in Spanish patients. *Oral. Oncol. Eur. J. Cancer* 32B, 163-166.
- Wood G.S. and Warnke R. (1981). Suppression of endogenous avidin-binding activity in tissues and its relevance to biotin-avidin detection systems. *J. Histochem. Cytochem.* 29, 1196-1204.
- Yeung W.M., Zong Y.S., Chiu C.T., Cham K.H., Choy D.T.K. and Ng M.H. (1993). Epstein-Barr virus carriage by nasopharyngeal carcinoma *in situ*. *Int. J. Cancer* 53, 736-750.
- Yu M.C. (1991). Nasopharyngeal carcinoma: epidemiology and dietary factors. *IARC Sci. Publ.* 105, 39-47.
- Zhao M., Zhang N-X., Economou M., Blaha I., Laissue J.A. and Zimmermann A. (1994). Immunohistochemical detection of bcl-2 protein in liver lesions: bcl-2 protein is expressed in hepatocellular carcinomas but not in liver cell dysplasia. *Histopathology* 25, 237-245.
- Zheng X., Hu L., Chen F. and Christensson B. (1994). Expression of Ki67 antigen, epidermal growth factor receptor and Epstein-Barr virus-encoded latent membrane protein (LMP1) in nasopharyngeal carcinoma. *Oral Oncol. Eur. J. Cancer* 30B, 290-295.

Accepted May 6, 1996