

Pattern of degeneration of the rat inferior olivary complex after the early postnatal axotomy of the olivocerebellar projection

J.A. Armengol and A. López-Román

Department of Morphological Sciences and Institute of Developmental Biology, School of Medicine, University of Sevilla, Sevilla, Spain

Summary. Neuronal death of inferior olivary neurons after early axotomy of the olivocerebellar tract was studied in newborn (P1) hemicerebellectomized rats during the first six days after lesion. The degeneration of the inferior olive showed a topographic pattern from one (P2) to six days after axotomy (P7), after which this complex had almost completely disappeared. The first degenerative changes were observed in the principal olive (P2), while the medial accessory olive was the later-degenerated area (P5). The analysis of these degenerative changes provides a reference for future experimental studies. Furthermore, the topographic study of the degenerative process demonstrated that: i) the most vulnerable neurons were dorsolaterally located, whereas the most resistant ones occupied the medial aspect of the inferior olivary complex, ii) the comparison between the topographical arrangement of the inferior olivary neurons according to their birth dates, and the rate of degenerative changes observed after hemicerebellectomy, open the possibility that the neuronal generation date and the response to the axotomy of the inferior olivary neurons could be related.

Key words: Hemicerebellectomy, Inferior olivary neurons, Neuronal death, Topographic pattern

Introduction

The olivocerebellar projection is considered as an example of a totally crossed projection in which olivary axons enter the cerebellum through the contralateral inferior cerebellar peduncle (for a review see Brodal and Kawamura, 1980). Because of the accessibility of the inferior cerebellar peduncle, it is possible to section this structure unilaterally. Such a lesion would result in the total loss of the contralateral inferior olivary complex

(IOC) while the ipsilateral IOC would remain intact. This provides a good experimental model for the analysis of some plastic properties of the central nervous system (Sotelo and Arsenio-Nunes, 1976; Angaut et al., 1982, 1985; Armengol and López-Román, 1992). Unilateral pedunculotomy has been used as the method of choice to deprive Purkinje cells of their climbing fibre input (Sotelo and Arsenio-Nunes, 1976). Newborn pedunculotomized rats display a compensatory sprouting in which climbing fibres of the remaining IOC establish correct synaptic relationships with Purkinje cells of the deprived cerebellar hemisphere (Angaut et al., 1982), and develop a topographic pattern within the deprived hemicerebellum, which mimics the normal one (Angaut et al., 1985). In these studies carried out in newborn rats, pedunculotomy was performed on postnatal day one (P1), and the animal was sacrificed in adulthood (1 month or more). The success of the surgical pedunculotomy was checked by the degree of disappearance of the IOC contralateral to the pedunculotomy (Sotelo and Arsenio-Nunes, 1976; Angaut et al., 1982, 1985). Recently, we have analyzed whether Purkinje cells deprived of their climbing fibres by the section of left inferior cerebellar peduncle exert a neurotropic effect on the remaining left IOC neurons, preventing the naturally-occurring cell death which takes place in the IOC during the first two weeks of postnatal life. Therefore, we designed an experimental approach in which newborn pedunculotomized rats (P1) were sacrificed between one and twenty-nine days after the operation (Armengol and López-Román, 1992). The IOC contralateral to the pedunculotomy disappeared almost completely from P6 on. However, the presence from P2 to P5 of healthy neurons within the IOC raised reasonable doubts about the completeness of the pedunculotomy. Therefore, in order to control this, we undertook a separate experimental analysis in which newborn rats (P1) were hemicerebellectomized, and where the changes in the IOC contralateral to the lesion site were examined from one to six days after operation.

This paper reports the degenerative changes

IOC degeneration after postnatal hemicerebellectomy

observed in IOC neurons after the neonatal hemicerebellectomy, to determine whether similar temporal differences in degeneration are seen among the IOC division as are seen after unilateral pedunculotomy.

Materials and methods

Fifty-five one-day-old rat pups (P1) purchased from Iffa-Credo (Madrid), underwent surgery to remove the left cerebellar hemisphere. Under deep ether anesthesia the pups were placed in a plastic mould, in order to maintain the head of the animal with a ventral flexion angle of approximately 45°. The surgical procedure consisted of two steps. Firstly, the left inferior cerebellar peduncle was sectioned by a sharpened needle inserted through the cisterna magna. Secondly, the left hemicerebellum was exposed by a craniectomy in the occipital bone, the vermal midline was sagittally cut, and the left cerebellar hemisphere was gently extracted by vacuum aspiration. A small piece of Spongel® was placed into the cavity left by the hemicerebellectomy. In our experience performing the pedunculotomy prior to the hemicerebellar aspiration minimizes the damage to the brainstem. Rat pups were sacrificed 1 to 6 days after operation (P2 to P7). Anaesthetized animals were perfused with 1% glutaraldehyde and 1% paraformaldehyde in 0.12 M phosphate buffer (pH 7.2). Dissected brains were stored in the same fixative overnight at 4 °C. A block comprising of the remaining hemicerebellum and attached brainstem was embedded in paraffin, serially sectioned at 10 µm in the coronal plane and stained with thionine and cresyl violet.

The sections were examined under a Nikon Labophot microscope equipped with a drawing tube at x40 and x100 objectives. According to previous work on the neuronal death of IOC neurons (Delhaye-Bouchaud et al., 1985), the criteria used to identify degenerating cells were the presence of dark recondensed masses substituting the nuclear elements (Chu-Wang and Oppenheim, 1978), or the hyperchromasy of their cytoplasm and nucleoplasm (Giordano et al., 1980) (Fig. 1C). With the aid of a reticle in the eye piece, the IOC subnuclei were artificially divided into areas of 1000 µm², and degenerating cells were systematically counted and plotted along the caudorostral axis of the IOC on camera lucida drawings. As the diameter of pycnotic figures was less than 10 µm, all sections were examined, and the pycnotic cell counts reported here are raw counts with no correction factor applied. Representative levels of the IOC, along its rostro-caudal extension, were used to express the changes observed at the different survival times (Fig. 6).

Results

For this study, three animals which possessed a complete left hemicerebellectomy, while keeping most of the other hemicerebellum intact, were analyzed for each survival age (Fig. 1).

Table 1. Degenerating cell counts (mean±SEM) of the right IOC in P1 hemicerebellectomized rats.

AGE	NUMBER OF PYCNOTIC CELLS
P2	5230±300
P3	6373±565
P4	1315±200
P5	415±150
P6	88±35
P7	50±15

One day after hemicerebellectomy (P2), there was a significant number of pycnotic figures (Fig. 5, Table 1). However, the right IOC was similar to the non-axotomized one, in that it presented its typical folded appearance in which the three main subnuclei were easily distinguished (Fig. 2A). The first signs of neuronal loss were found in the dorsalmost regions of the principal olive (PON) dorsal lamella, near the junction with the dorsal accessory olive (DAO) (Fig. 2B, arrows) in which pycnotic cells were always medially located (Fig. 2B). A summary drawing of IOC areas containing degenerated cells is illustrated in Figure 6A. At this age the largest number of degenerating cells was found in both lamellae of the PON, although the dorsal ones were usually more affected. Damaged areas were also observed in the medial accessory olive (MAO), mainly in the region of the beta nucleus and group b. In the DAO, degenerating neurons were mainly found in a small area of the dorsal fold; while a few pycnotic figures were also observed within the lateroventral region of this subnucleus (Fig. 2C).

Two days after hemicerebellectomy (P3) the degeneration of the right IOC was still incomplete (Fig. 3A,B, 6B). Although the neuronal density was less than at P2, the IOC subdivisions could still be recognized (Fig. 3A). Pycnotic cells reached their maximum number (Fig. 5, Table 1), and were intermingled with healthy ones, throughout the PON and the DAO (Fig. 3B). In contrast, the medial regions of the MAO exhibited a more normal appearance in which pycnotic cells were found, but where healthy-looking neurons predominated (Fig. 3B open arrows). The area containing damaged neurons clearly increased from P2, and extended through the DAO which became greatly affected in this short period of time (24 h) (Fig. 6B). The MAO was the least affected subnucleus and its medial region remained practically unaffected (Fig. 6B).

Three days after hemicerebellectomy (P4), neuronal death was visible throughout the right IOC, which appeared a cellular mass without clear borders (Fig. 3C). The areas which were occupied by the DAO and the PON evolved into a homogeneous area in which only pycnotic cells, necrotic debris and gliosis were found (Fig. 3D). However, a few healthy neurons could be observed within these highly degenerative areas (Fig. 3D, arrow). The MAO was the only subnucleus that possessed undamaged neurons in any appreciable quantity, and these were located near the raphe of the

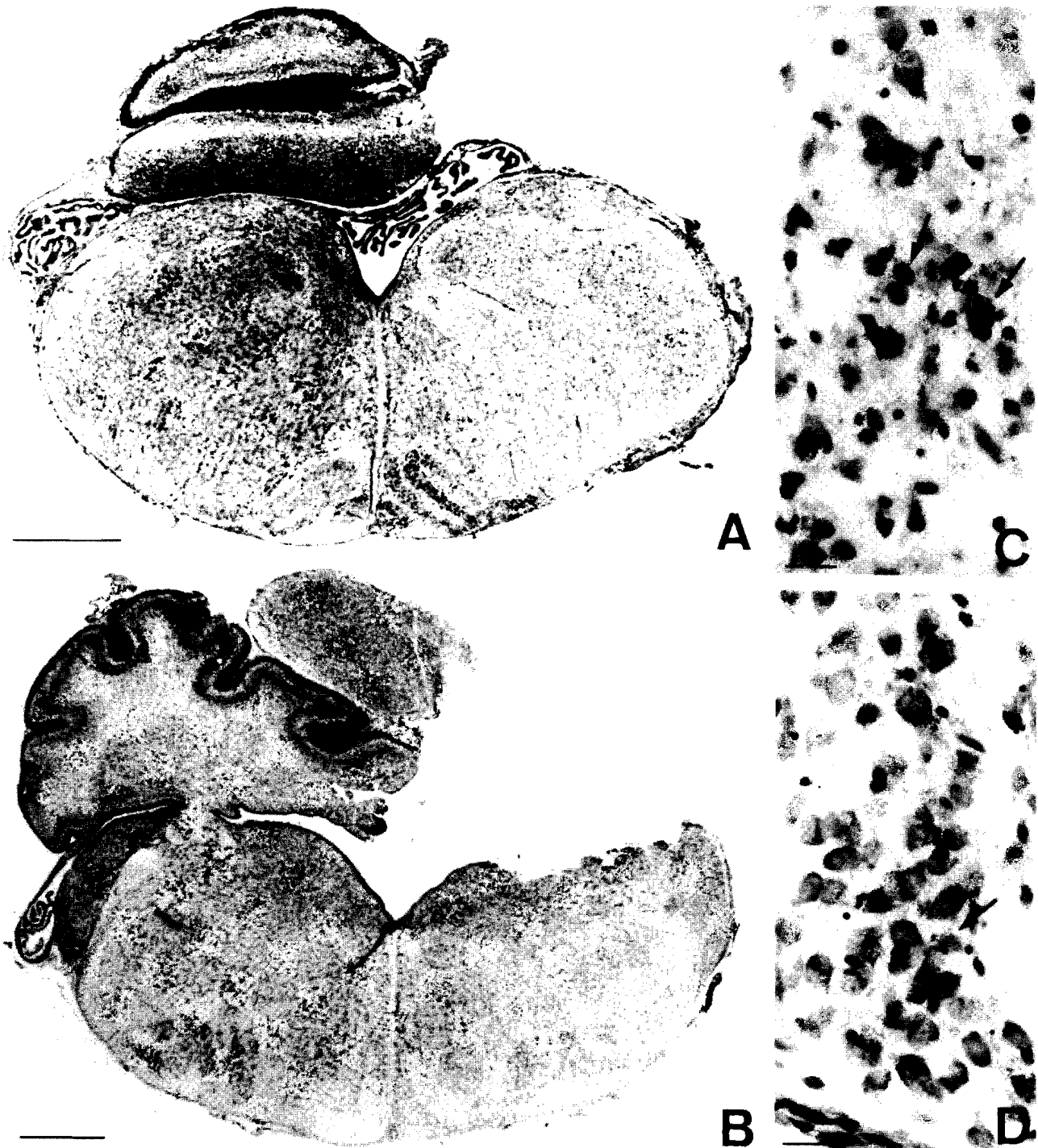


Fig. 1. Coronal sections of the medulla oblongata and the remaining hemicerebellum of a P3 rat. The photomicrographs illustrate the criteria followed in the selection of the cases used in this study. **A.** At the levels of the inferior olivary complexes, both IOC might be symmetrical and the remaining cerebellum correspond with, at least, the right cerebellar hemisphere. Even at such low magnification, it can be noted how the right IOC possesses a more fuzzy appearance than the undamaged left one. Bar: 500µm. **B.** Coronal section through the caudal level of the pons illustrating that the hemicerebellectomy is complete. Bar: 500µm. **C and D.** Illustration of the differences between damaged (C) and undamaged (D) olivary areas. Condensed nuclear or nucleolar masses within a very scarce, and often lacking, cytoplasm, and the blurring of the nucleus together with the darkness of the cytoplasm are considered as evident degenerative signs (arrows). Bars: 20 µm.

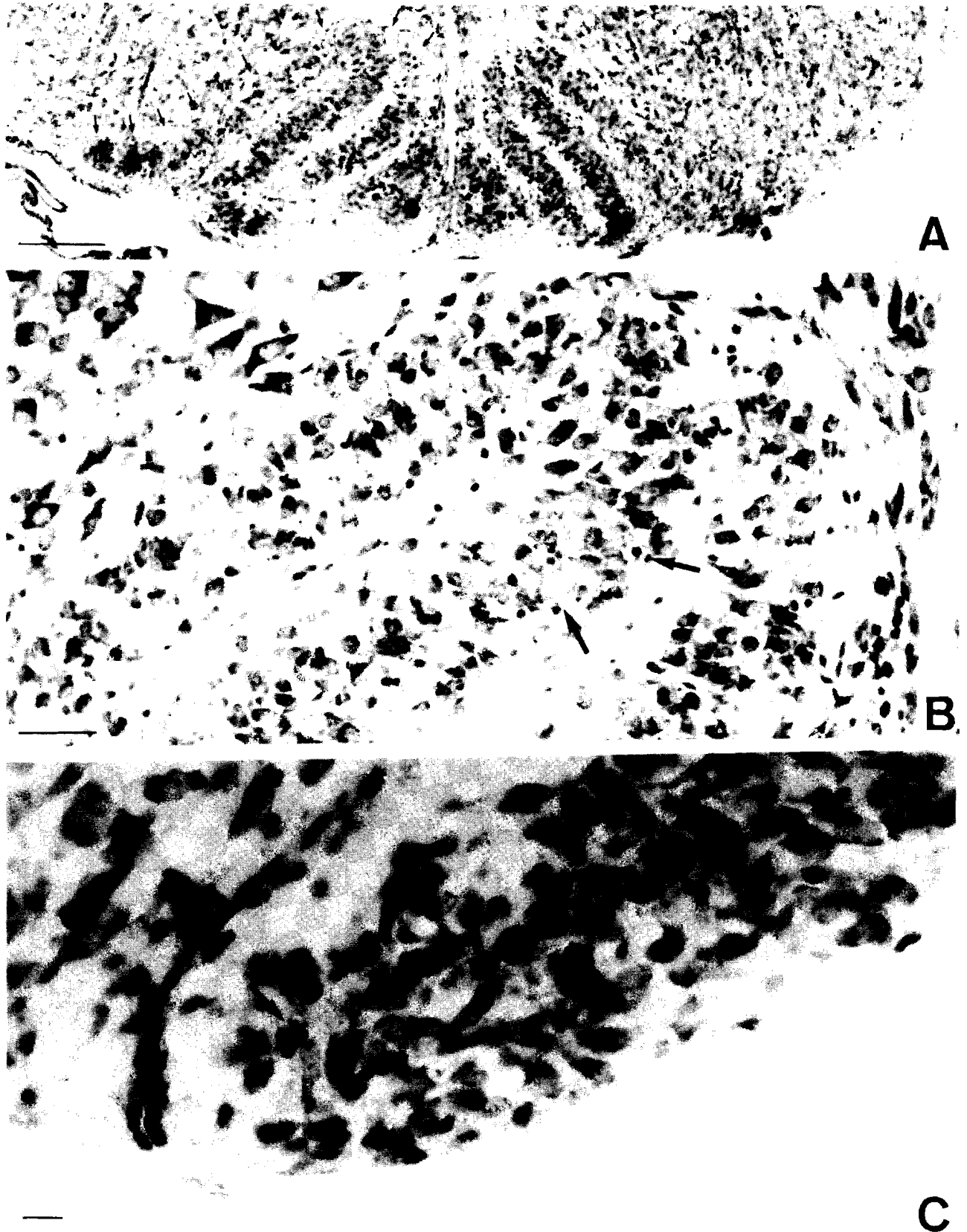


Fig. 2. Coronal sections of the medulla oblongata at the level of the IOC in hemicerebellectomized rats, sacrificed on the second postnatal day. **A.** The right IOC, contralateral to the lesion site, is outlined by arrows. The three main subnuclei of the inferior olive are well defined. Bar: 200 μ m. **B and C.** Degenerating neurons are located within the dorsal lamella of the PON (**B**, arrows) and the lateroventral region of the DAO (**C**, arrow). Note that dying neurons are intermingled with apparently normal ones. Bars: 200 μ m in **B** and 10 μ m in **C**.

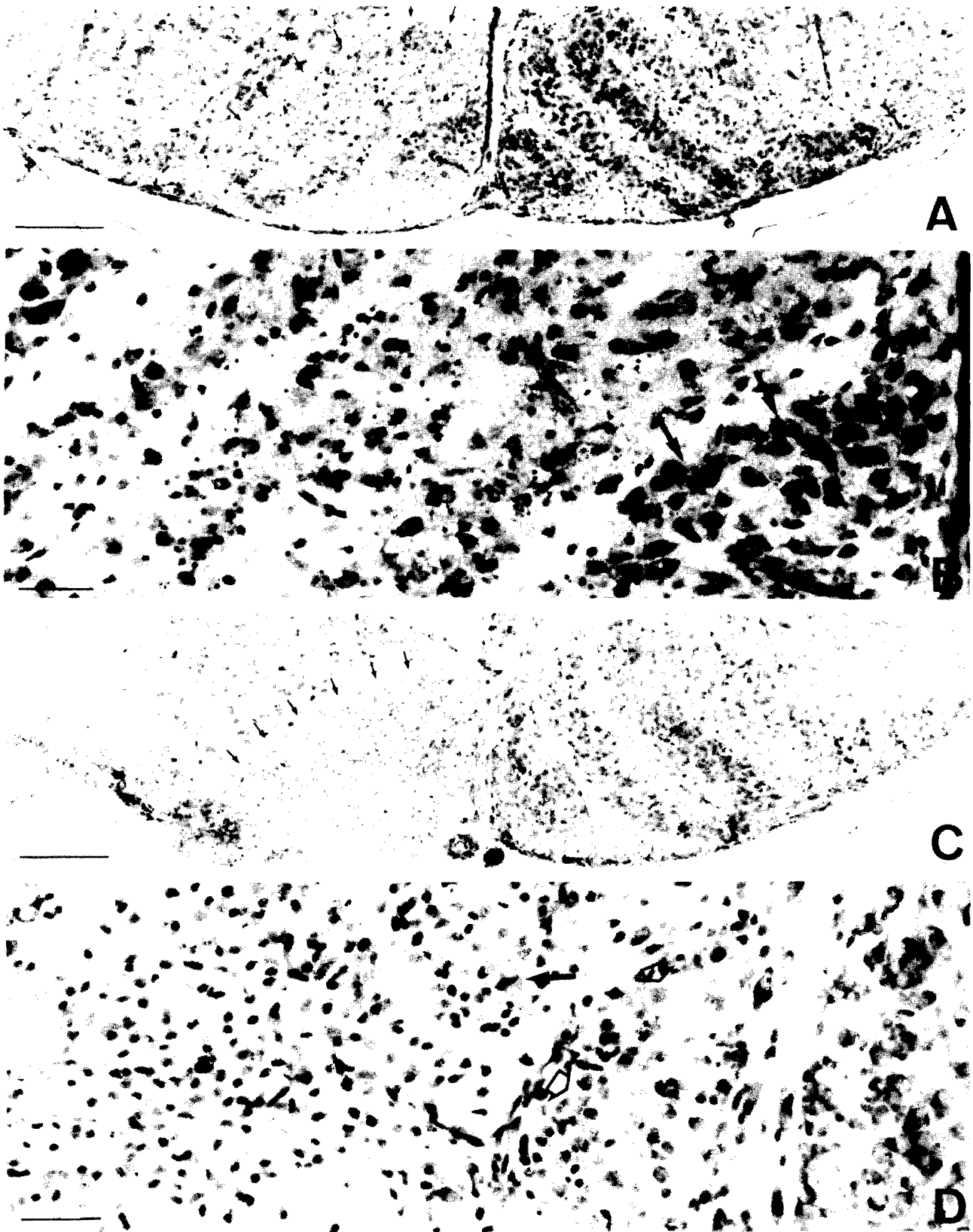


Fig. 3. Coronal section of the medulla oblongata at the level of the IOC in hemicerebellectomized rats, sacrificed on the third (A and B) and fourth (C and D) postnatal days. **A.** arrows outline the right IOC. Two days after hemicerebellectomy the three main subnuclei of the right IOC are still present. Bar: 200 μ m. **B.** Severe neuronal death is evident through the IOC, Mainly in PON and DAO. Healthy neurons are found within the MAO (arrows). Bar: 50 μ m. **C.** Three days after hemicerebellectomy, the right IOC has lost its morphology, evolving into a rather homogeneous cellular mass (outlined by arrows). Bar: 50 μ m. **D.** Some undamaged neurons, intermingled with degenerative debris, are found (black arrows). The majority of healthy neurons remain within the medial part of the MAO (open arrows). Bar: 200 μ m.

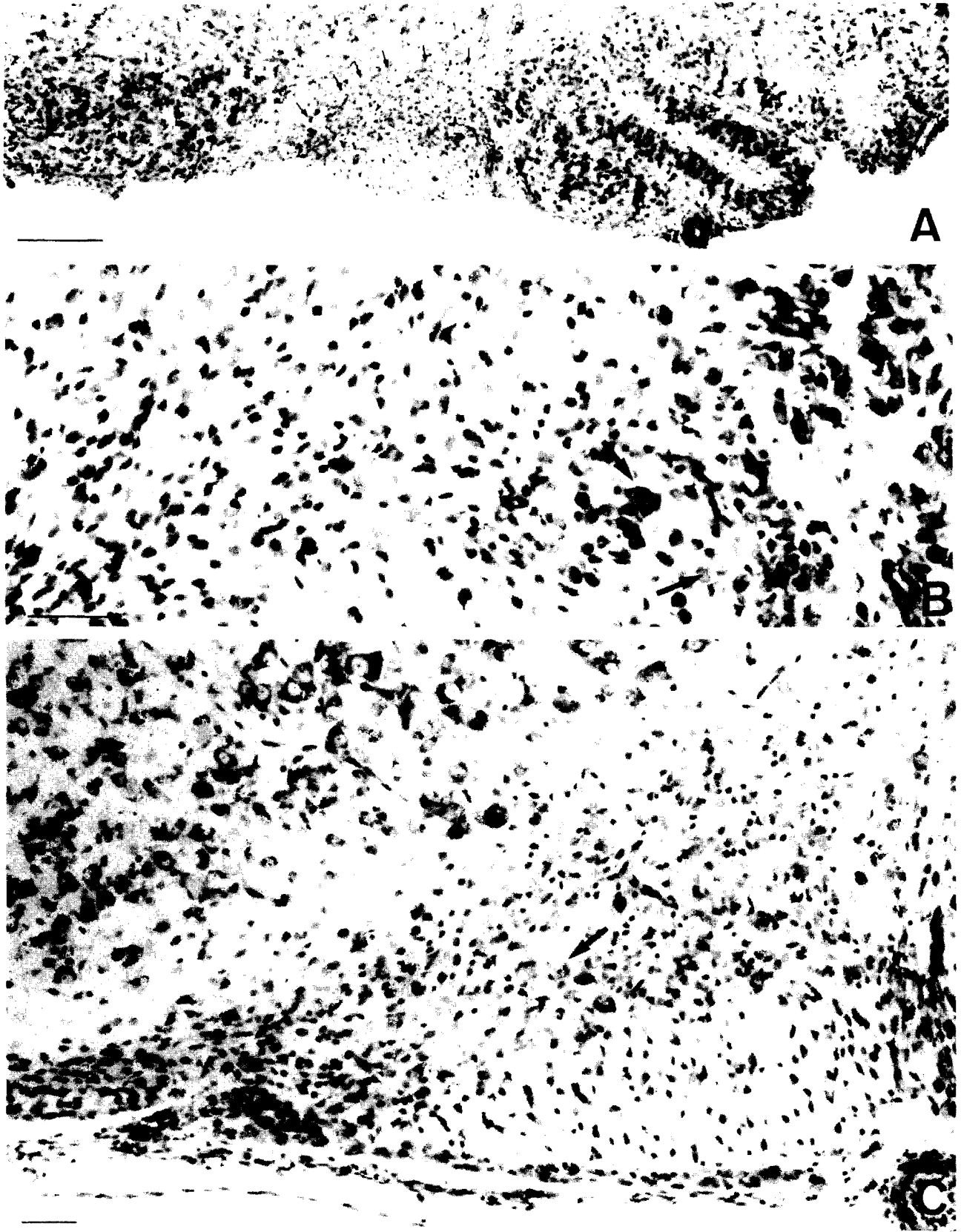


Fig. 4. Coronal sections of the medulla oblongata at the level of the IOC in hemicerebellectomized rats, sacrificed on the fifth (A and B) and seventh (C) postnatal days. **A.** The right IOC has lost all resemblance to the normal one, becoming reduced to a smaller mass of dead cells and necrotic debris (outlined by arrows). Bar: 200 μ m. **B.** Few remaining neurons are observed in the medial part of the IOC (arrows), in a location which corresponds to the normal placement of the MAO. Bar: 50 μ m. **C.** Six days after hemicerebellectomy, the right IOC has almost completely disappeared. However, a few healthy cells can be found within it (arrow). Bar: 50 μ m.

IOC degeneration after postnatal hemicerebellectomy

medulla oblongata (Fig. 3D, open arrows). The analysis of the distribution of degenerating areas through the rostrocaudal extent of the IOC indicated that: i) the remaining healthy neurons were confined to the medial areas of the IOC corresponding to the theoretical location of the MAO with the exception of a small zone of the midrostral levels of IOC (Fig. 6C); and ii) a significant shortening of the right IOC, was weakly evident on P3, with the total length reduced by approximately 300 μm (Fig. 6C).

Four days after hemicerebellectomy (P5), the homogeneous mass of pycnotic cells and necrotic debris which was in the right IOC diminished in size (Fig. 4A, arrows). The shortening of the rostrocaudal extension of IOC, approximately 500 μm (Fig. 6D), was more evident than in preceding days. The few remaining normal-looking neurons were confined to the medial regions of the IOC at about the middle of its rostro-caudal extension (Fig. 4B, arrows; Fig. 6D).

Five and six days after hemicerebellectomy (P6-P7), the IOC was reduced to a small area in the ventral aspect of the medulla oblongata, in which a few scattered neurons or neuron-like cells could be found (Fig. 4C). The necrotic debris and degenerated cells were rapidly removed and this area was invaded and occupied by glial cells.

Discussion

The completely crossed anatomical organization of the olivocerebellar system (Brodal and Kawamura, 1980) provides a good experimental model, in which the destruction of the interolivary commissure deprives the cerebellum of its climbing fibre input. However, this experimental procedure requires a ventral approach to the ventral surface of the medulla oblongata. Although this is feasible in adult animals, it is difficult to accomplish successfully in newborn rats, due to the small size of the operative zone and the proximity of vital centres (i.e. the cardio-respiratory bulbar centres). For these reasons, many investigators have elected to section one inferior cerebellar peduncle as a method of

depriving one hemicerebellum of its climbing fibre inputs (Sotelo and Arsenio-Nunes 1976; Angaut et al., 1982, 1985; Bower and Sherrard, 1986; Armengol and López-Román, 1992). This lesion deprives one hemicerebellum of its olivary afferents, whereas the other remains innervate and can serve as a control. Furthermore, this lesion permits the long survival of the animals after surgery (Sotelo and Arsenio-Nunes, 1976; Angaut et al., 1982, 1985). When this experimental approach has been used in long term experiments, the success of the pedunculotomy has been revealed by the total disappearance of the IOC contralateral to the lesion site (Sotelo and Arsenio-Nunes, 1976; Angaut et al., 1982, 1985). However, when the experiment has been carried out using short survival times, the contralateral IOC does not degenerate rapidly, and during the first four days postoperation, undamaged neurons can always be found (Armengol and López-Román, 1992). The results obtained in hemicerebellectomized newborn rats, agree with these preliminary observations, and can be summarized as follows: i) after the early postnatal axotomy, the contralateral IOC degenerates during the first four days after surgery, disappearing almost completely on the 5th postoperative day (Angaut et al., 1985); ii) during this period of degeneration, neuronal death follows a consistent pattern, from the dorso-lateral to the ventro-medial zones of the IOC. In this degenerative gradient, the most vulnerable neurons are in the PON, whereas the most resistant ones are located in the MAO; iii) this rapid process of degeneration is accompanied by an equally rapid process of clearing of dead cells and necrotic debris, which is completed one week after lesion

The pattern of degenerative changes reported here might have different explanations: i) the first one would be related to the distance between the cell body and the axotomy site, as described by Villegas-Pérez et al. (1988) for the retinal ganglion cells. Thus, the first degenerated cells should possess the shortest distance between their cell bodies and the site of axotomy. Our results seem to rule out this suggestion, since, if this were true, the first neurons that should theoretically die would be found within the MAO, the nearest subnucleus to the interolivary commissure, and hence, to the lesioned contralateral inferior cerebellar peduncle.

ii) The second possibility would be that neurons projecting to a similar cerebellar area, would degenerate at the same time. However, after considering this possibility carefully, and focusing the attention on the MAO and the DAO, this does not seem to be the case. Both of these subnuclei project to the intermediate cerebellar cortex (Sotelo et al., 1984; Azizi and Woodward, 1987). However, the neurons in these subdivisions do not degenerate in a synchronous fashion. The neurons in the DAO were affected 24 to 48 hours before the MAO neurons, even though both projected to the intermediate cerebellar cortex (i.e. the horizontal lamella of Azizi and Woodward (1987)). In our observations, this is one of the IOC areas that disappears

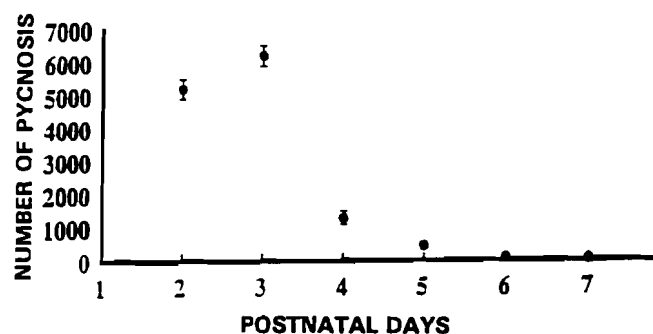


Fig. 5. Number of pycnotic neurons counted within the right IOC from P2 to P7 hemicerebellectomized rats. Note the bulk of neuronal death occurs 48 hours after lesion (P3). Each symbol represents the mean \pm SEM.

IOC degeneration after postnatal hemicerebellectomy

last.

iii) A final possibility would be that post-axotomy neuronal death at early postnatal days (before the onset of the definitive Purkinje cells-climbing fibre synaptogenesis) could be related to the birth date of the dying

neurons. Autoradiographic analyses have shown that IOC neurons are generated during two embryonic days at the rhombic lip level (Ellenberger et al., 1969; Altman and Bayer, 1978, 1987; Bourrat and Sotelo, 1988, 1991; Bourrat et al., 1989). Despite the discrepancy on the

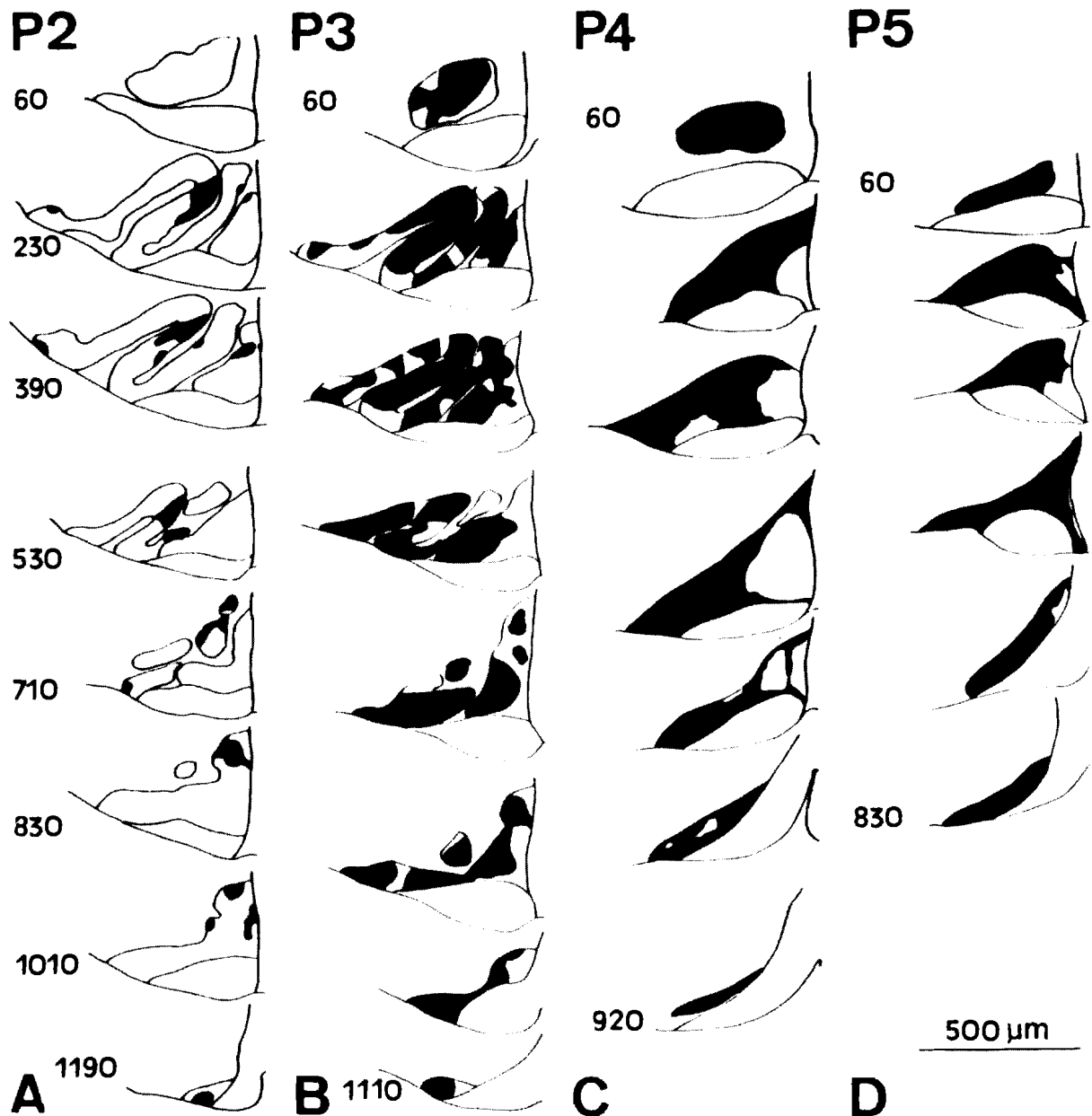


Fig. 6. Diagrams of a rostro-caudal series of coronal sections through the right IOC illustrating the distribution of the areas containing pycnotic neurons (black) in hemicerebellectomized rats, from one (P2) to four days (P) after lesion. **A.** One day after hemicerebellectomy, the main focus of degeneration is located in the dorsal lamella of the PON. **B.** 24 hours later (P3), the extent of the damaged areas increases. The PON is almost completely degenerated, and the DAO is importantly affected. The MAO is less affected; their medial zones being almost devoid of dying cells. **C.** Three days after hemicerebellectomy, there are two striking factors: i) the shortening of the rostrocaudal extent of the IOC; and ii) the loss of the typical morphology of the inferior olive. With the exception of a small area laterally located (C, section corresponding to the 390 μ m level), the remaining neurons are located in the medial regions of the IOC. **D.** Four days after lesion, the right IOC has almost disappeared, being transformed into a zone within the ventral aspect of the medulla oblongata filled with degenerated cells, necrotic debris and glial cells. Only a few neurons remain within the medial regions of this cellular mass. All the drawings have been made at the same distance from the rostral limit of the IOC. Only in those cases in which the drawings could not be made at the same level (B, C and D), the length from the rostral limit is marked.

exact birth date of these neurons (see Bourrat and Sotelo, 1991), there is a general agreement that PON neurons are some of the first to be born, while MAO neurons are generated later (Altman and Bayer, 1978; Bourrat and Sotelo, 1988; Bourrat et al., 1989). Furthermore, based on the different neuronal birth dates, Altman and Bayer (1987) have proposed a neurogenetic organization of the IOC, in which the MAO «is divided into three neurogenetically different components: the earliest generated posterodorsal division (PD), the later-generated posteroventral division (PV) (with possibly two parts, a medial and a lateral; PVm, PVI), and the latest general anterolateral division (AV)» (Altman and Bayer, 1987). It should be pointed out that both later-generated divisions of the IOC correspond to the zone of later dying neurons in hemicerebellectomized rats. Moreover, recent findings have demonstrated that «most of the later-generated PON neurons are located in the ventral aspect of this subnuclei...» (Bourrat and Sotelo, 1988), the same region which, in our experiments, is the latest-degenerated area in the whole PON. However, in their recent neurogenetic analysis, Bourrat and Sotelo (1991) described that the first generated IOC neurons occupied the lateralmost extent of the DAO. In our experiments, although few pycnotic figures were observed at P2, the majority of the neurons of this region of the DAO did not degenerate so early. However, this is the only exception that is not consistent with there being a close relationship between the generation date and the pattern of death followed by the IOC neurons after early axotomy. Combined experiments of ³H-thymidine labelling and postnatal pedunculotomy (now in progress) will answer this question.

In addition, one feature is particularly striking: in both DAO and PON subnuclei the degenerative changes take place from 24 to 48 hours, whereas these necrotic events are slower in the MAO. This different behaviour on the part of MAO neurons, reinforces the idea that neurons located at the olivary midline could have some metabolic differences compared to the rest of the olivary neurons. This has been suggested as a mechanism for the survival of these neurons under diverse experimental conditions, such as the 3-acetylpyridine treatment (Llinás et al., 1975; Balaban, 1985; Rossi et al., 1991), and pedunculotomy (Angaut et al., 1985).

A last point of discussion is related to the persistence of some healthy neurons within the degenerated IOC. This could be due to the existence of a population of IOC neurons that send their axons through the ipsilateral inferior cerebellar peduncle (Bower and Sherrard, 1986; Sherrard and Bower, 1986; López-Román and Armengol, 1994) and therefore were never damaged in the present experiments.

In conclusion, the results reported here concerning the differential degeneration rate of IOC neurons after postnatal hemicerebellectomy, provides a timetable of events that can be used as a reference in future experimental studies. In addition, it is suggested that early-generated IOC neurons might be more vulnerable

to axotomy than those generated later.

Acknowledgements. We are grateful to Dr. L.M. Eisenman for critical reading of the manuscript, A.M. Mosquero for her photographic assistance and F. López for his technical assistance. This work was supported by DGICYT grant PB 87-0946, Junta de Andalucía grants «Consolidación de Grupos de Investigación Científica y Tecnológica 88-91», and Eugenio Rodríguez Pascual Foundation.

References

- Altman J. and Bayer S.A. (1978). Prenatal development of the cerebellar system in the rat. II. Cytogenesis and histogenesis of the inferior olive, pontine gray, and precerebellar reticular nuclei. *J. Comp. Neurol.* 179, 49-76.
- Altman J. and Bayer S.A. (1987). Development of the precerebellar nuclei in the rat. II. The intramural olivary migratory stream and the neurogenetic organization of the inferior olive. *J. Comp. Neurol.* 257, 490-512.
- Angaut P., Alvarado-Mallart R.M. and Sotelo C. (1982). Ultrastructural evidence for compensatory sprouting of climbing and mossy afferents to the cerebellar hemisphere after ipsilateral pedunculotomy in the newborn rat. *J. Comp. Neurol.* 205, 101-111.
- Angaut P., Alvarado-Mallart R.M. and Sotelo C. (1985). Compensatory climbing fiber innervation after unilateral pedunculotomy in newborn rat. *J. Comp. Neurol.* 263, 161-178.
- Armengol J.A. and López-Román A. (1992). Left unilateral inferior pedunculotomy prevents neuronal death during postnatal development of the remaining left inferior olivary complex in the rat. *Eur. J. Neurosci.* 4, 640-647.
- Azizi S.A. and Woodward D.J. (1987). Inferior olivary nuclear complex of the rat: morphology and comments on the principles of organization within the olivocerebellar system. *J. Comp. Neurol.* 263, 467-484.
- Balaban C.D. (1985). Central neurotoxic effects of intraperitoneally administered 3-acetylpyridine, harmaline and niacinamide in Sprague-Dawley and Long-Evans rats: a critical review of central 3-acetylpyridine neurotoxicity. *Brain Res. Rev.* 9, 21-42.
- Bourrat F. and Sotelo C. (1988). Migratory pathways and neuritic differentiation of inferior olivary neurons in the rat embryo. Axonal tracing study using the in vitro slab technique. *Dev. Brain Res.* 39, 19-37.
- Bourrat F. and Sotelo C. (1991). Relationships between neuronal birthdates and cytoarchitecture in the rat inferior olivary complex. *J. Comp. Neurol.* 313, 509-521.
- Bourrat F., Gotow T. and Sotelo C. (1989). Development of the rat inferior olive: migratory routes, formation of afferent and efferent connections. In: *The olivocerebellar system motor control*. Strata P.G. (ed). Springer-Verlag. Berlin. pp 123-149.
- Bower A.J. and Sherrard R.M. (1986). Rate of degeneration of a neonatal ipsilateral olivocerebellar pathway revealed by unilateral cerebellar pedunculotomy in the rat. *Exp. Neurol.* 93, 652-656.
- Brodal A. and Kawamura K. (1980). The olivocerebellar projection: a review. *Adv. Anat. Embryol. Cell. Biol.* 64, 1-140.
- Chu-Wang J.W. and Oppenheim R.W. (1978). Cell death of motoneurons in the thick embryo spinal cord. I. A light and electron microscopic study of naturally occurring and induced cell loss during development. *J. Comp. Neurol.* 177, 33-58.
- Delhaye-Bouchaud N., Geoffroy B. and Mariani J. (1985). Neonatal

IOC degeneration after postnatal hemicerebellectomy

- death and synapse elimination in the olivocerebellar system. I. Cell counts in the inferior olive of developing rats. *J. Comp. Neurol.* 232, 299-308.
- Ellenberger C., Hanaway J. and Netsky M.G. (1969). Embryogenesis of the inferior olivary nucleus in the rat: a radioautographic study and a reevaluation of the rhombic lip. *J. Comp. Neurol.* 137, 71-88.
- Giordano D.L., Murray M. and Cunningham T.J. (1980). Naturally occurring neuron death in the optic layers of superior colliculus of the postnatal rat. *J. Neurocytol.* 9, 603-614.
- Llinás R., Walton K., Hillman D.E. and Sotelo C. (1975). Inferior olive: its role in motor learning. *Science* 190, 1230-1231.
- López-Román A. and Armengol J.A. (1994). Morphological evidence for the presence of ipsilateral inferior olivary neurons during postnatal development of the olivocerebellar projection in the rat. *J. Comp. Neurol.* 350, 485-496.
- Rossi F., Wiklund L., Van der Want J.J.-L. and Strata P. (1991). Reinnervation of cerebellar Purkinje cells by climbing fibres surviving a subtotal lesion of the inferior olive in the adult rat. I. Development of new collateral branches and terminal plexuses. *J. Comp. Neurol.* 308, 513-535.
- Sherrard R.M. and Bower A.J. (1986). An ipsilateral olivocerebellar connection: an autoradiographic study in the unilaterally pedunculo-tomised rat. *Exp. Brain Res.* 61, 355-363.
- Sotelo C. and Arsenio-Nunes M.L. (1976). Development of Purkinje cells in absence of climbing fibers. *Brain Res.* 111, 389-395.
- Sotelo C., Bourrat F. and Triller A. (1984). Postnatal development of the inferior olivary complex in the rat. II. Topographic organization of the immature olivocerebellar projection. *J. Comp. Neurol.* 222, 177-199.
- Villegas-Pérez M.P., Vidal-Sanz M., Bray G.M. and Aguayo A. (1988). Retinal ganglion cell death after axotomy is influenced by the distance between the lesion and the neuronal somata. *Soc. Neurosci. Abstr.* 14, 673.

Accepted November 20, 1995