

Serotonin immunoreactivity in the carotid body of adult humans

J.-O. Habeck¹, D.J. Pallot² and W. Kummer³

¹Institute of Pathology, Municipal Hospital, Chemnitz, Germany, ²Department of Human Anatomy, Faculty of Medicine and Health Sciences, United Arab Emirates University, Al-Ain, UAE and ³Department of Anatomy and Cell Biology, Philipps-University, Marburg, Germany

Summary. The distribution of serotonin immunoreactivity (-IR) was studied in adult human carotid bodies, obtained at post-mortem, using both the peroxidase-antiperoxidase method on paraffin sections and a double-labelling immunofluorescence on frozen sections. Antibodies against synaptophysin and protein gene product (PGP) 9.5 were used for identification of serotonin-IR cells. Serotonin-IR was demonstrable in the carotid bodies of adult humans and it was coexpressed mostly with synaptophysin or PGP 9.5 in type I cells. Some serotonin immunopositive type I cells were located in close proximity to capillaries. Serotonin-IR was also observed in a few endothelial cells.

Key words: Serotonin immunoreactivity, Carotid body, Adult man

Introduction

Previous studies, using a variety of methods, have shown that serotonin is present in the carotid bodies of a number of mammalian species (Chiocchio et al., 1967; Böck and Lassmann, 1973; Hellström and Koslow, 1975; Hellström, 1977; Grönblad et al., 1983; Abramovici et al., 1991). In man, two studies of fetuses and young children, and three of the carotid body in adults, have confirmed the presence of serotonin in the carotid body (Hamberger et al., 1966; Battaglia, 1969; Steele and Hinterberger, 1972; Behar et al., 1979; Perrin et al., 1986). As this substance is able to affect chemosensory discharge (Black et al., 1972; Nishi, 1975; Docherty and McQueen, 1978; Kirby and McQueen, 1984), its distribution within the carotid body is of considerable interest.

The aim of the present report is to demonstrate the localization of serotonin-IR in the carotid body of adult humans.

Materials and methods

Four carotid bodies of 3 men and 1 woman 18, 52, 77 and 78 years old were removed 1.5, 3.5, 7.75, and 12 hours after death.

Carotid bodies were fixed by immersion in phosphate-buffered (pH 7.4) 2% paraformaldehyde/15% picric acid, rinsed several times in 0.1M phosphate buffer, cryoprotected by immersion in the same buffer containing 18% sucrose, and snap frozen in liquid nitrogen. Frozen sections were cut at a thickness of 10-14 µm with a cryostat (Frigocut 2800E, Leica, Nussloch, FRG) and collected on chromalum-coated slides. Prior to application of primary antisera, non-specific protein binding sites of the sections were blocked by incubation for 1 h in phosphate-buffered saline (PBS) containing 10% normal swine serum, 0.1% bovine serum albumin and 0.5% Tween 20.

Primary antisera used for immunofluorescence were directed against the following antigens: protein gene product 9.5 (PGP 9.5; rabbit polyclonal antiserum; UltraClone, Cambridge, UK; diluted 1:200), serotonin (1. polyclonal rabbit antiserum; Immunonuclear, Stillwater, MN, USA; diluted 1:1000; 2. monoclonal mouse antibody; code 5HT-H209; Dako, Glostrup, Denmark; diluted 1:20), and synaptophysin (mouse monoclonal antibody; clone SVP38; Sigma, Deisenhofen, FRG; diluted 1:400). Double labelling immunofluorescence was performed by combining the mouse monoclonal serotonin-antibody with the rabbit polyclonal PGP-antiserum, and the rabbit polyclonal serotonin antiserum with the mouse monoclonal synaptophysin-antibody, respectively. Primary antisera raised in different species were applied as a mixture overnight at room temperature. The slides were then rinsed 3 times for 5 minutes each in PBS, incubated for 1 h with a biotinylated sheep-anti mouse IgG (Amersham Buchler, Braunschweig, FRG; diluted 1:50), washed again in PBS, incubated for 1 h with a mixture of streptavidin-Texas Red (Amersham; diluted 1:50) to label the biotinylated secondary antibody, and a fluorescein isothiocyanate (FITC)-conjugated sheep anti-

Serotonin-IR in human carotid body

rabbit IgG (Wellcome, Beckenham, UK; diluted 1:200) to label the primary antiserum raised in rabbit. Subsequently, the slides were washed in PBS, and coverslipped in carbonate-buffered glycerol at pH 8.6.

The sections were examined with a Polyvar microscope (Reichert, Nussloch, FRG) equipped for epifluorescence microscopy, using a B2 module (excitation filter: band pass 455-490 nm; barrier filter: band pass 515 - 560 nm) for visualization of FITC, and a G1 module (band pass 546/10 nm; long pass 590 nm) for demonstration of Texas Red.

Three carotid bodies of two women and one man 61, 68, and 79 years old were removed 4, 7, and 8.5 hours after death, fixed overnight by immersion in 2% paraformaldehyde, 15% saturated picric acid in 0.1M phosphate buffer at pH 7.4, washed in buffer several times, dehydrated in graded series of ethanols and embedded in paraffin wax. Sections (5 μ m) were dewaxed, rehydrated and incubated in 0.3% hydrogen peroxide to block endogenous peroxidase activity. Following washing in buffered saline, the sections were incubated in diluted serum of the animal used to raise the

link antibody. Two anti-serotonin antisera were used: one polyclonal raised in rabbits (Peninsula Laboratories, St. Helens, England; Lot no. 800237; diluted 1:400) and another monoclonal antiserum (Dakopatts, Glostrup, Denmark; lot no. 018; clone 5HT-H209; diluted 1:10). The sections were incubated at room temperature for 24 h and then washed in three changes of buffered saline. Throughout the procedure 0.05M Tris saline (pH 7.2) was used for washing in cases where the monoclonal antibody was employed; in the case of the rabbit polyclonal antibody the washing solution was 0.02M phosphate-buffered saline. The link antibodies were either swine anti-rabbit IgG (for polyclonal primary antiserum, Dakopatts; lot no. 037, diluted 1:100) or rabbit anti-mouse IgG (for monoclonal antiserum, Dakopatts; lot no. 089, diluted 1:50); sections were incubated for 30 min at room temperature. Following washing with three changes of buffer, the reaction product was visualized by the peroxidase-antiperoxidase (PAP) method (Sternberger, 1979). Sections were incubated for 30 mins at room temperature with either rabbit PAP (Dakopatts; lot no. 039, diluted 1:200) or

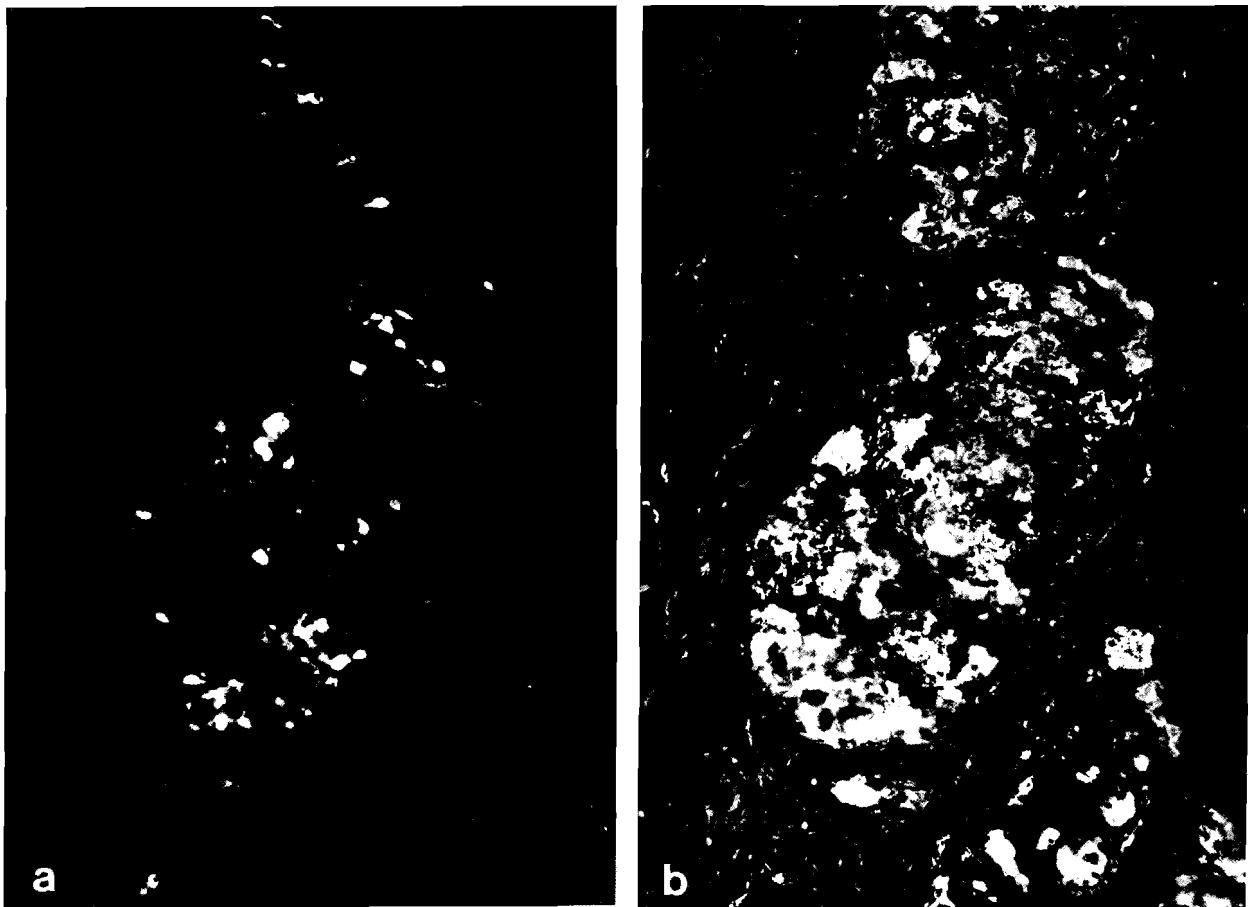


Fig. 1. Double-labelling immunofluorescence demonstrating serotonin- (a) and PGP 9.5-IR (b) in a glomic lobule. The PGP 9.5 antiserum labels a large number of cells and an extensive network of nerve fibres within the lobule. Only serotonin-like immunoreactive cells are demonstrable within the lobule. Most of the glomic cells show coexistence of both immunoreactivities. x 20

Serotonin-IR in human carotid body

mouse PAP (Dakopatts; lot no. 078 and 099, diluted 1:100) following buffer washing. 3,3'-diaminobenzidine-hydrochloride served as chromogene. All sections were counterstained with Meyer's haematoxylin. Negative controls consisted of sections in which the primary antiserum was replaced by PBS and those in which the secondary reagents were replaced by PBS; no staining was observed in these slides.

Results

Serotonin immunoreactive cells were demonstrable in the majority within the glomic lobules (Fig. 1a). In general, in cases with a short post mortem interval (below 4 hours) more serotonin immunopositive cells were found. We were able to distinguish three patterns of stained cells. Cells of the first type were round or polygonal and were situated within the glomic clusters (Fig. 2a); this was the commonest distribution. Some

serotonin-IR cells showed uni- or bipolar cytoplasmic processes (Figs. 2b,c). Sometimes these processes were long and closely related to capillary walls (Fig. 2c). Other spindle-shaped cells were situated directly adjacent to the capillary wall (Fig. 2d). Sometimes distinct intracytoplasmic granules were observed.

Double labelling immunofluorescence of serotonin with PGP 9.5 (Fig. 1b) as well as synaptophysin revealed coexistence in most of the cells. The degree of coexistence of serotonin-IR with synaptophysin-IR was higher than that with PGP 9.5-IR. The rate of coexistence of serotonin-IR and PGP 9.5- or synaptophysin-IR was higher when the post mortem interval was below 4 hours.

Synaptophysin antibodies labelled perivascular varicosities, whereas serotonin antibodies did not (Fig. 3). The PGP 9.5 antiserum labelled an extensive network of nerve fibres within the lobules (Fig. 1b). This network lacked any serotonin-IR (Fig. 1a). Occasionally

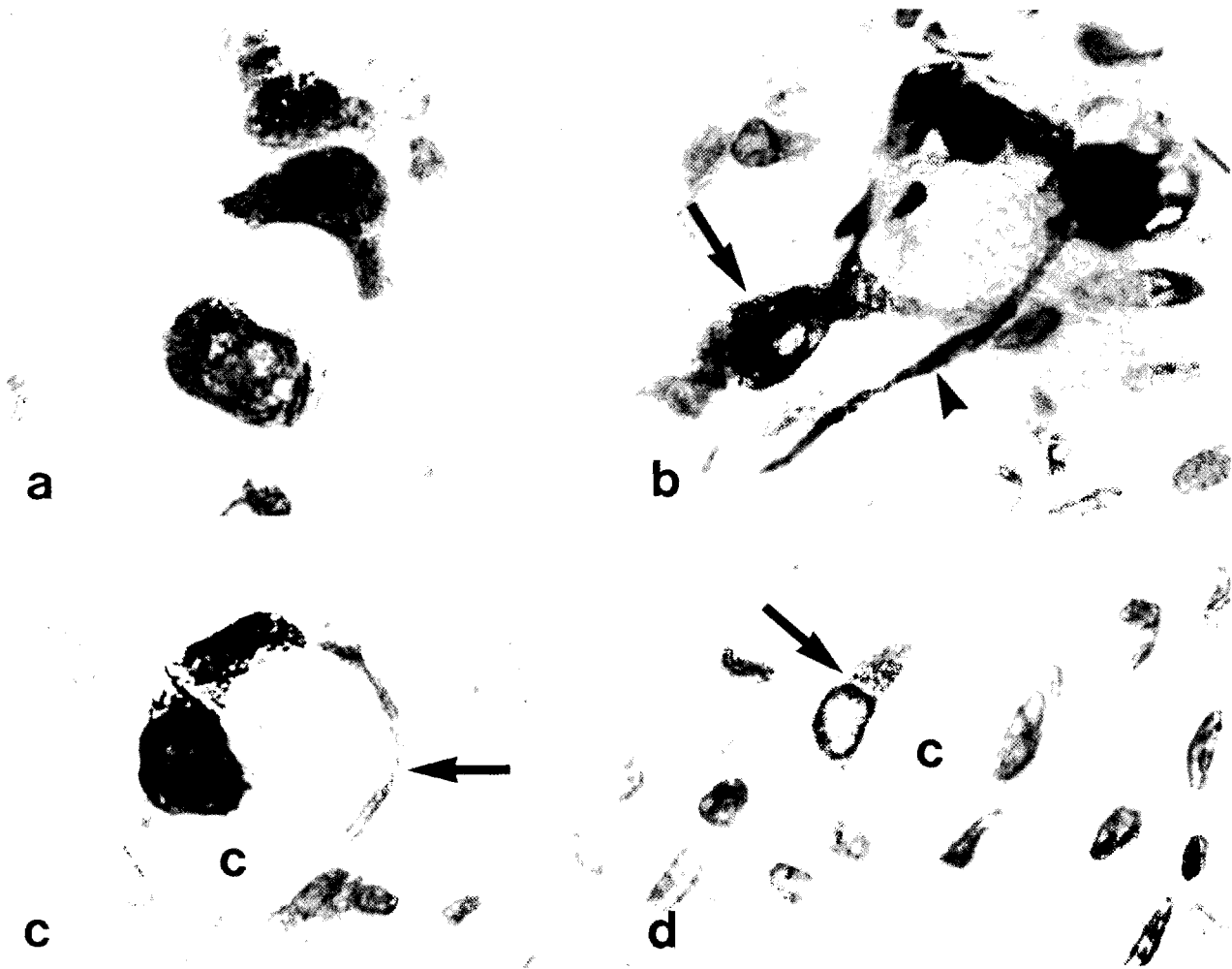


Fig. 2. Cytological details of serotonin-IR cells within the adult human carotid body at light microscopical level. **a.** Three single polygonal cells in a glomic cluster. **b.** One cell with a bipolar process (arrow) and a single process of another cell (arrowhead). **c.** A single cell with a process (arrow) attached to a capillary (c). **d.** A spindle-shaped cell (arrow) closely attached to a capillary (c). All sections counterstained with H&E. x 400

Serotonin-IR in human carotid body

intraglomerular serotonin-IR cells were seen lacking any PGP 9.5- or synaptophysin-IR (Fig. 4). Plump serotonin-IR processes were observed in nerve bundles. These processes also showed a positive reaction after incubation with synaptophysin antibodies. Additionally,

synaptophysin-IR-positive but serotonin-negative processes were found within such nerve bundles. Endothelial cells of intraglomerular veins very seldom contained serotonin-IR, and they lacked synaptophysin-IR (Fig. 5).

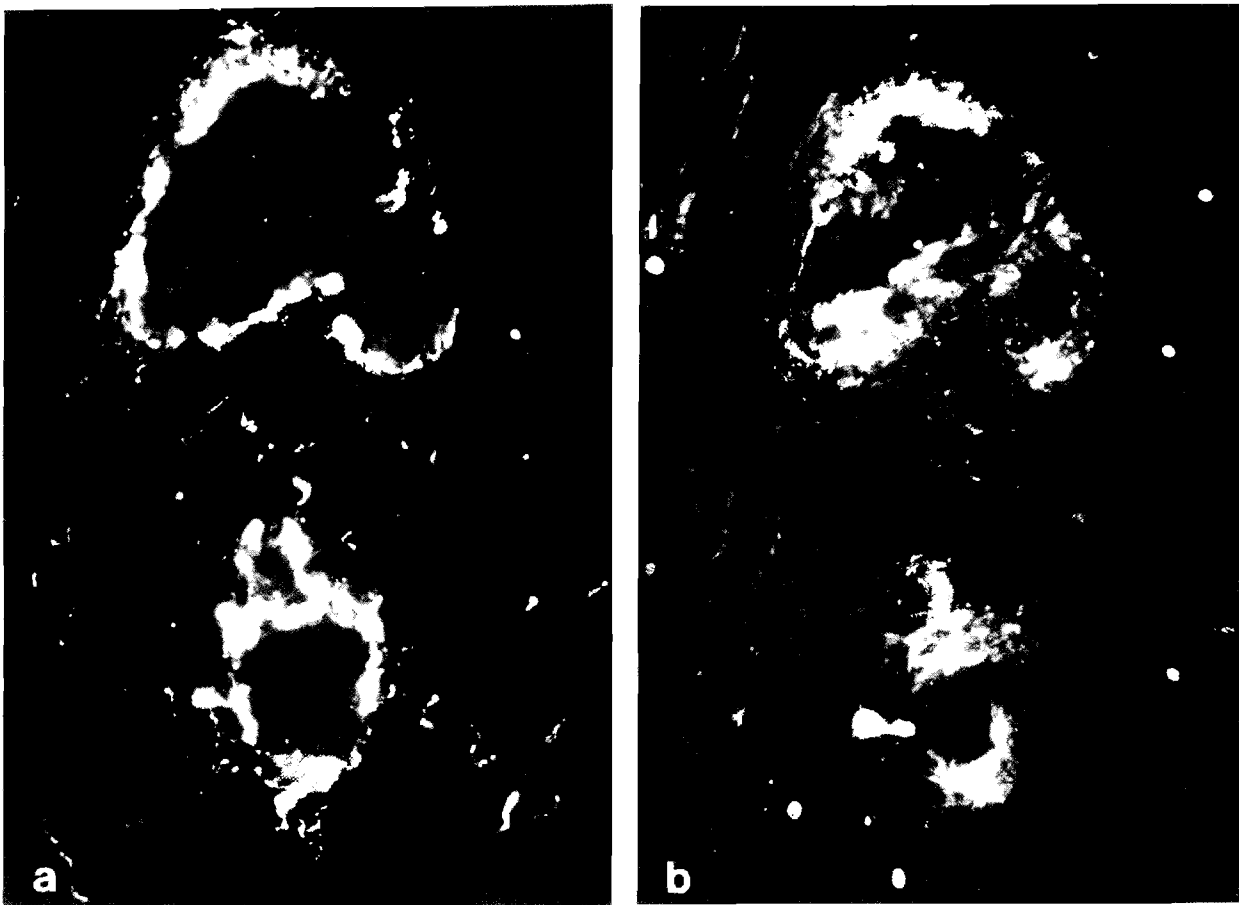


Fig. 3. Double-labelling immunofluorescence to demonstrate synaptophysin- (a) and serotonin-IR (b) in small intraglomerular veins. Only synaptophysin-IR exhibits perivascular varicosities, whereas serotonin-IR lacks immunoreaction. x 32

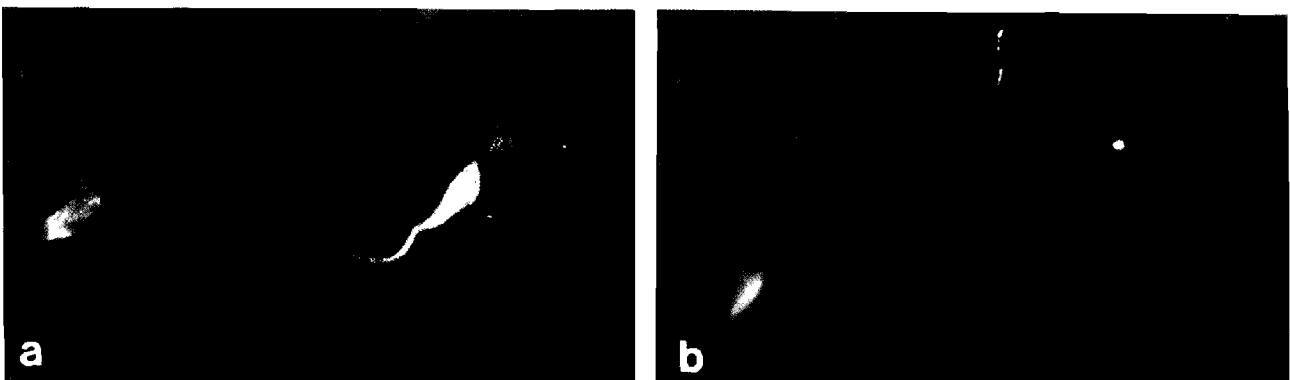

Fig. 4. Double-labelling immunofluorescence demonstrating a serotonin-IR cell (a), which lacks synaptophysin-IR (b). x 80

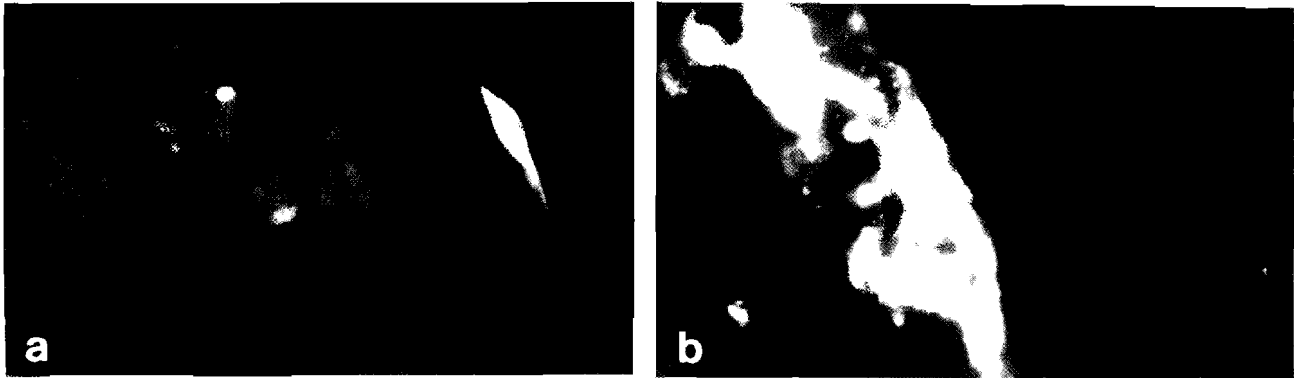


Fig. 5. Double-labelling immunofluorescence showing a serotonin-IR endothelial cell of a vein (a). There is no-coexistence with synaptophysin-IR (b). x 80

Discussion

This study confirms reports that serotonin-IR is demonstrable in human carotid bodies (Hamberger et al., 1966; Battaglia, 1969; Steele and Hinterberger, 1972; Behar et al., 1979; Perrin et al., 1986). In a previous study we have shown that antisera against PGP 9.5 and synaptophysin are good markers for the identification of type I cells of the human carotid body (Habeck and Kummer, 1993). Coexistence of serotonin- and PGP 9.5- or synaptophysin-IR in the glomic lobules revealed that serotonin is mostly localized within type I cells in the adult human carotid body although it is not contained in the entire cell population. This is in agreement with the results of Perrin et al. (1986) in carotid bodies of children. In our study we saw serotonin-IR type I cells which were closely apposed to capillaries or which showed cell processes attaching to capillaries. Grönblad et al. (1983) reported the presence of serotonin-IR cells in close proximity to blood vessels in the rat carotid body. Serotonin affects the chemosensory discharge when injected close-arterial to the carotid body, and it has a biphasic effect (Black et al., 1972; Nishi, 1975; Docherty and McQueen, 1978) with a short period of excitation being followed by a longer-lasting chemodepression. The longer lasting inhibition may well be due to effects upon blood flow, for the compound does not inhibit carotid body activity in the isolated and superfused organ (Eyzaguirre and Koyano, 1965). Local blood changes may be involved in carotid body chemoreceptor discharge (Joels and Neil, 1963). Serotonin may be involved in various ways in a vasculary-mediated control of influence on carotid body function (Kirby and McQueen, 1984).

According to our findings, serotonin-IR is not restricted to glomus cells in the human carotid body. In rodents, mast cells have been described as an additional serotonin store in the carotid body (Grönblad et al., 1983), but human mast cells are not capable of serotonin synthesis. Instead, serotonin-IR was detected in a small proportion of endothelial cells. Similarly, a mosaic

pattern of serotonin-IR has been described in endothelial cells of rat coronary, femoral, and mesenteric arteries where less than 10% of endothelial cells contained the indolamine (Burnstock et al., 1988; Loesch and Burnstock, 1988). Endothelial-derived serotonin is thought to be involved in arterial vasorelaxation caused by hypoxia (Burnstock et al., 1988). In the human carotid body, however, serotonin-IR endothelial cells were found in veins but not in arteries, so that they are apparently not involved in arterial vasodilatation. Since these endothelial cells are located downstream to the numerous serotonin-IR secretory glomus cells, they might be involved in clearance of serotonin from the venous outflow of the carotid body rather than being actively involved in serotonin synthesis. In favour of this interpretation, we did not observe endothelial cells exhibiting immunoreactivity to aromatic-L-amino-acid-decarboxylase, which participates in the catalytic formation of serotonin (Kummer and Habeck, 1992).

It could be of interest to study the serotonin distribution in diseases accompanied with changed carotid body function, such as essential hypertension. In hypertensive humans an elevated serotonin content of the carotid bodies has been described by Steele and Hinterberger (1972).

Acknowledgements. We are grateful to Mrs. J. McWilliam and B. Hoba for expert technical assistance. The work of J.-O. Habeck was financially supported by the Wellcome Trust.

References

- Abramovici A., Pallot D.J. and Polak J.M. (1991). Immunohistochemical approach to the study of the cat carotid body. *Acta Anat.* 140, 70-74.
- Battaglia G. (1969). Ultrastructural observations on the biogenic amines in the carotid and aortic-abdominal bodies of the human fetus. *Z. Zellforsch.* 99, 529-537.
- Behar A.J., Deutsch E., Pomerantz E., Pfeifer Y. and Sulman F.G. (1979). Migraine, serotonin, and the carotid body. *Lancet* 1, 550.
- Black A.M.S., Comroe J.H. and Jacobs L. (1972). Species difference in

Serotonin-IR in human carotid body

- carotid body response of cat and dog to dopamine and serotonin. *Am. J. Physiol.* 223, 1097-1102.
- Böck P. and Lassmann M. (1973). Histochemische Untersuchungen über die Reserpinwirkung am Glomus caroticum (Ratte). *Verh. Anat. Gesellsch.* 67, 229-232.
- Burnstock G., Lincoln J., Fehér E., Hopwood A.M., Kirkpatrick K., Milner P. and Ralevic V. (1988). Serotonin is localized in endothelial cells of coronary arteries and released during hypoxia: a possible new mechanism for hypoxia-induced vasodilatation of the rat heart. *Experientia* 44, 705-707.
- Chiocchio S.R., Biscardi A.M. and Tramezzani J.H. (1967). 5-hydroxytryptamine in the carotid body of the cat. *Science* 158, 790-791.
- Docherty R.J. and McQueen D.S. (1978). Inhibitory action of dopamine on cat carotid chemoreceptors. *J. Physiol.* 279, 425-436.
- Eyzaguirre C. and Koyano H. (1965). Effects of some pharmacological agents on chemoreceptor discharges. *J. Physiol.* 178, 410-437.
- Grönblad M., Liesi P. and Rechart L. (1983). Serotonin-like immunoreactivity in rat carotid body. *Brain Res.* 276, 348-350.
- Habeck J.-O. and Kummer W. (1993). Neuronal and neuroendocrine markers in the human carotid body in health and disease. In: *Neurobiology and cell physiology of chemoreception*. Data P., Acker H. and Lahiri S. (eds). Plenum Publ. Corp. New York. pp 31-35.
- Hamberger B., Ritzen M. and Wersäll J. (1966). Demonstration of catecholamines and 5-hydroxytryptamine in the human carotid body. *J. Pharmacol. Exp. Ther.* 152, 197-201.
- Hellström S. (1977). Putative neurotransmitters in the carotid body: Mass fragmentation studies. *Adv. Biochem. Psychopharmacology* 16, 257-263.
- Hellström S. and Koslow S.H. (1975). Biogenic amines in carotid body of adult and infant rats - a gas chromatographic-mass spectrometric assay. *Acta Physiol. Scand.* 93, 540-547.
- Joels N. and Neil E. (1963). The excitation mechanisms of the carotid body. *Br. Med. Bull.* 19, 21-24.
- Kirby G.C. and McQueen D.S. (1984). Effects of the antagonists MDL 7222 and ketanserin on responses of cat carotid body chemoreceptors to 5-hydroxytryptamine. *Br. J. Pharmacol.* 83, 259-269.
- Kummer W. and Habeck J.-O. (1992). Chemoreceptor A-fibres in the human carotid body contain tyrosine hydroxylase and neurofilament immunoreactivity. *Neuroscience* 47, 713-725.
- Loesch A. and Burnstock G. (1988). Ultrastructural localization of serotonin and substance P in vascular endothelial cells of rat femoral and mesenteric arteries. *Anat. Embryol.* 178, 137-142.
- Nishi K. (1975). The action of 5-hydroxytryptamine on chemoreceptor discharges of the cat's carotid body. *Br. J. Pharmacol.* 55, 27-40.
- Perrin D.G., Chan W., Cutz E., Madapallimattam A. and Sole M.J. (1986). Serotonin in the human infant carotid body. *Experientia* 42, 562-564.
- Steele R.H. and Hinterberger H. (1972). Catecholamines and 5-hydroxytryptamine in the carotid body in vascular, respiratory, and other diseases. *J. Lab. Clin. Med.* 80, 63-70.
- Sternberger L.A. (1979). *Immunocytochemistry*. 2nd. ed. John Wiley and Sons. New York. pp 104-169.

Accepted November 8, 1993