

Neutrophil interaction with tumour cells in small early gastric cancer: ultrastructural observations

R.A. Caruso, G. Speciale and C. Inferrera

Department of Human Pathology, University of Messina, Messina, Italy

Summary. The authors studied the neutrophil inflammatory reaction by light and electron microscopy in 4 small early gastric cancers (three tubular adenocarcinomas and one adenocarcinoma with signet-ring cell component), selected for the absence of coagulative necrosis and ulceration. Neutrophils showed ultrastructural signs of activation such as aggregation, adhesion and lipid bodies. Some neutrophils were found to be in intimate contact with the intact tumour cells and with those that displayed a varying degree of damage. In particular, relatively early damage, such as disorganization of the intermediate filaments and dilatation of the rough endoplasmic reticulum, occurred at the contact regions. In spite of the severe damage to the tumour cells, the neutrophils themselves were intact. These findings are discussed in relationship to a number of recent studies of the neutrophil-mediated tumour cell injury, in man and animals.

Key words: Small early gastric cancer, Electron microscopy, Neutrophil infiltration, Membrane interaction, Tumour cell cytopathic changes

Introduction

During carcinoma spread in the organism, various interactions occur between tumour cells and mesenchymal cells, especially those of immunologic defence. Most literature on the immune system and cancer growth focuses on the role of lymphocytes, natural killer cells and mononuclear phagocytes.

Classically, neutrophils have been thought of as secondary phagocytic cells, infiltrating necrotic areas of tumours (Underwood, 1974). Neutrophil-mediated mechanisms have largely been ignored, although experimental arguments suggest that their role in tumour cell damage might be important. Histological studies of

murine neoplasms have demonstrated that neutrophils are often present during the early stages (Russell et al., 1976; Dvorak et al., 1978) and participate in tumour destruction (Dvorak et al., 1978). Neutrophils have been shown to exert cytotoxic effects against tumour cells in vitro: during phagocytosis of inert particles (Clark and Klebanoff, 1975); in the presence of anti-target cell antibody (reviewed by Weiss and Lo Buglio, 1982); and in the presence of soluble activating agents (Nathan et al., 1979; Slivka et al., 1980; Clark and Szot, 1981). Neutrophils can induce tumour cell injury by the production of reactive oxygen intermediates (Clark and Klebanoff, 1977; Hafeman and Lucas, 1979) and/or by the secretion of small cationic proteins, contained within primary granules and termed defensins (Lichtenstein et al., 1986, 1988). As in the situation with other cytotoxic cells, the killing by neutrophils also requires tumour target cell contact (Dvorak et al., 1978; Becker, 1988).

In an attempt to relate the neutrophil-mediated cytotoxicity against tumour cell in vitro to possible involvement of neutrophils in tumour cell killing or damage in vivo, we focused on identification and role of the neutrophils among the subpopulation of inflammatory cells in contact with gastric carcinoma cells. This report deals with 4 cases of small early gastric cancers (EGC) less than 10 mm in diameter, selected for the absence of coagulative necrosis and ulceration, because these conditions may excite nonspecific tissue neutrophilia.

Materials and methods

Four cases of EGC were selected for their size, less than 10 mm (small EGC), and for the absence of coagulative necrosis, erosions or ulcerations. The age of the patients ranged from 49 to 71 years. None of the patients had undergone preoperative irradiation or immunochemotherapy. All the specimens were obtained by surgical removal. The pathological diagnosis was made by light microscopy, as described in our previous publication (Caruso et al., 1993).

For light microscopy, the tissues were fixed in 10% formalin and prepared for paraffin sectioning. The sections were stained with haematoxylin and eosin (H&E).

The four cases of small EGC were processed for transmission electron microscopy examination. Briefly, in each case, small pieces of the fresh tumour tissue were immediately fixed in 3% phosphate-buffered glutaraldehyde (pH 7.4) and postfixed in 1% osmium tetroxide. Semi-thin araldite-embedded sections were stained with Giemsa's reagent and used for orientation and selection of the representative part of each tumour. Thin sections were double-stained with uranyl acetate and lead citrate; they were then examined with a Siemens 101 electron microscope.

Results

According to the WHO classification (Watanabe et al., 1989), 3 small EGC cases were of the tubular type and 1 case was of the tubular type with a signet-ring cell component.

In the tumour stroma of all examined small EGC, there was a patchy or diffuse chronic type inflammatory reaction, composed of small lymphocytes, plasma cells, mononuclear phagocytes, eosinophils and mast cells in varying proportions. In all four cases a focal acute inflammation involved tumour microvasculature and was manifested by exudation of neutrophils and oedema (Fig. 1). Neutrophils formed varied-sized aggregates in the tumour stroma (Fig. 2a). Some neutrophils were seen passing through the neoplastic epithelium, and others were found lying within neoplastic tubules similar to «crypt abscesses». Blood vessels were lined by plump endothelial cells with large nuclei. Vascular dilatation and sometimes tight intraluminal packing of erythrocytes were present (Fig. 2b). Neutrophils and a smaller

number of eosinophils were distributed in a scattered fashion in these vessels, usually in loose aggregates of 3-7 cells (Fig. 2b). Neither granulocyte plugs nor thrombosis were found. Coagulative necrosis was not found in the tumours, as confirmed by the numerous serial sections examined.

At ultrastructural level, neutrophils were noted either singly or in small clusters in the tumour stroma. They were nonphagocytic and showed the characteristic equipment of discrete primary and secondary granules, glycogen and lipid bodies (Fig. 3a). Neutrophils, singly (Fig. 3a) or in rosette formation (Fig. 4), established pointed or flat areas of membrane contact with individual tumour cells, invading the stroma. At the site of contact with tumour cell, neutrophils sometimes exhibited micropinocytotic vesicles and a thin band of submembranous microfilaments (Fig. 3b). Other areas of intimate contact were characterized by regions where the membranes of the opposing cells could not be defined clearly (Fig. 5). In the concerned neutrophils, primary granules were located mainly in the cytoplasm separating the nucleus and the section of plasma membrane in contact with the tumour cell (Fig. 5). Tumour cells interacting with neutrophils showed focal disruption of the rough endoplasmic reticulum and disorganization of the intermediate filaments (Fig. 5). More severe damage of the tumour cell showed dilated or vesiculated rough endoplasmic reticulum (Figs. 6, 7). In the tumour cell, mucin granules opening in the vicinity of the contact zone were seen (Fig. 7). In spite of the presence of severe damage to the tumour cells, the neutrophils were themselves intact (Fig. 7). Often, the adjacent non-contacted tumour cells appeared morphologically well preserved (Fig. 7).

It was often found that the neutrophils were in direct contact with other stromal cells, such as macrophages, plasma cells, eosinophils, fibroblasts, and myo-

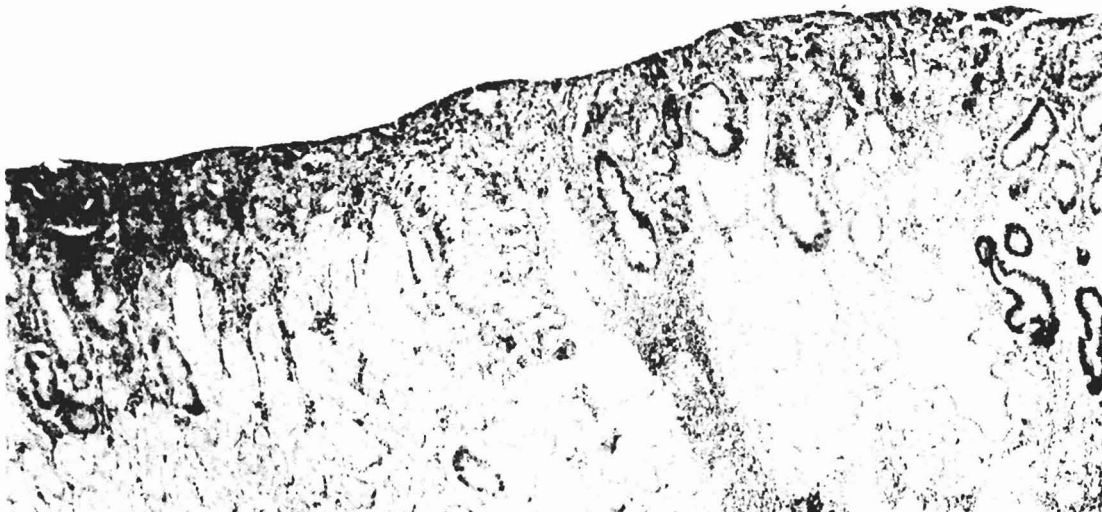


Fig. 1. A llb small EGC. Absence of coagulative necrosis. H&E. x 40

fibroblasts, but these stromal cells remained intact.

Discussion

The morphological findings reported here show neutrophil infiltration and aggregation in the tumour stroma. Clustering of neutrophils is indicative of their functional activation (Tauber, 1987; Sandborg and Smolen, 1988). This is also supported by our ultrastructural findings of lipid bodies in neutrophils, since their presence has been described in activated neutrophils participating in inflammatory or immunological processes (Robinson et al., 1983; Weller and Dvorak, 1985). Activation of neutrophils is also characterized by chemotaxis and cell adhesion (Sandborg and Smolen, 1988). In fact, the neutrophils in contact with gastric tumour cells demonstrated the

following types of surface adherence: a) pointed membrane contacts; b) flat membrane contact, with or without micropinocytotic vesicles.

Our present study demonstrates that the tumour cells contacted by some neutrophils exhibit damage of a varying degree, probably reflecting the different stages of the neutrophil-mediated tumour cell damage. In particular, relatively early damage to the tumour cell frequently occurred at the contacting regions with the neutrophils, whereas the remaining part of the tumour cell stayed unchanged. Often, the adjacent tumour cells not conjugated by the neutrophil were morphologically well preserved. In spite of the presence of damage to the tumour cells, the neutrophils were themselves intact.

Based on the following three reasons, we may rule out the possibility that damage to the tumour cells is due to artifacts associated with fixation or ultrathin section

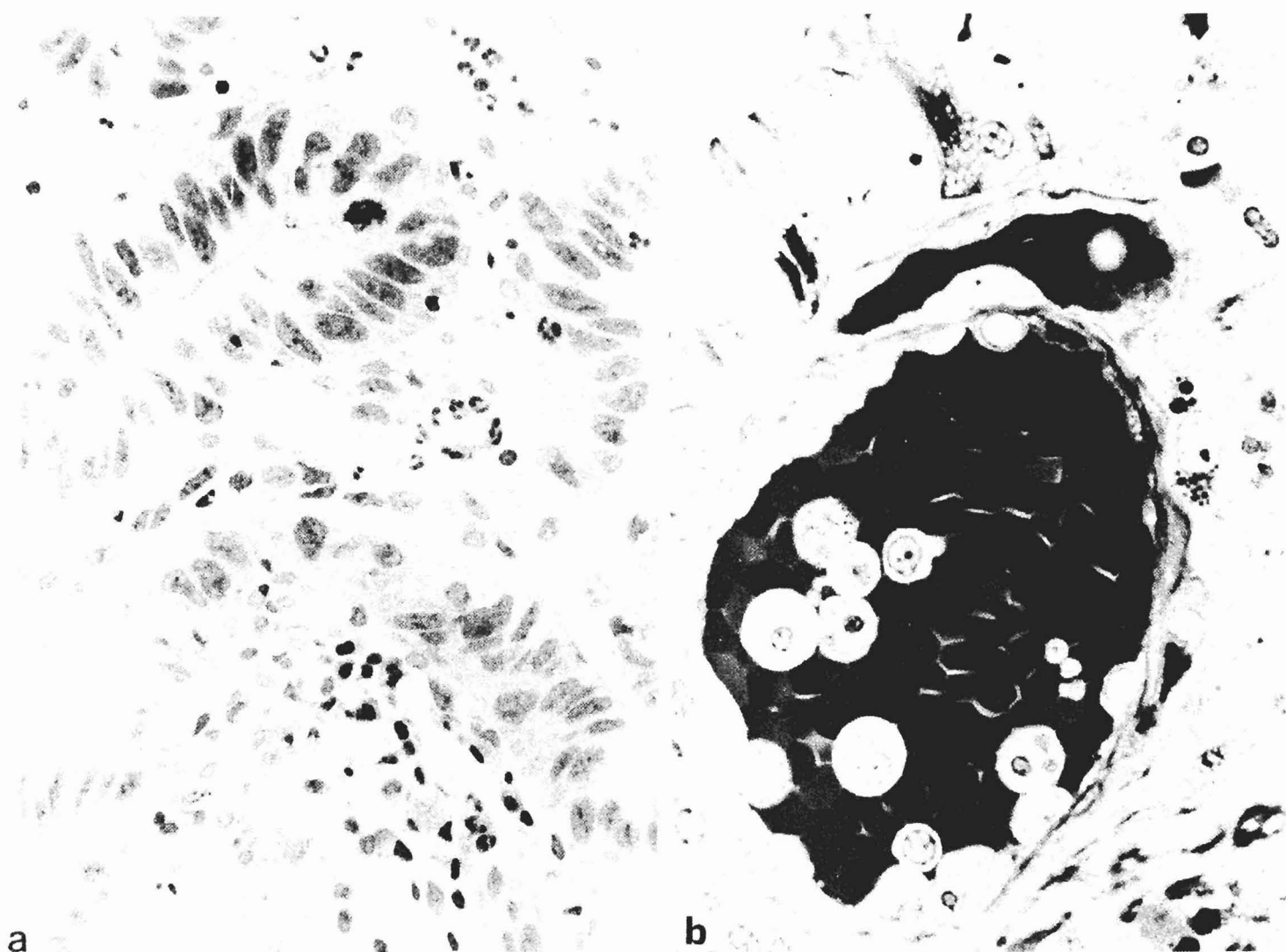


Fig. 2. a. Neutrophil clustering in the tumour stroma. Semi-thin section; Giemsa. x 400. b. Small blood vessel appears dilated and full of erythrocytes. Loose aggregates of neutrophils and eosinophils, some sticking to the endothelium, are evident in this section. Semi-thin section; Giemsa. x 630

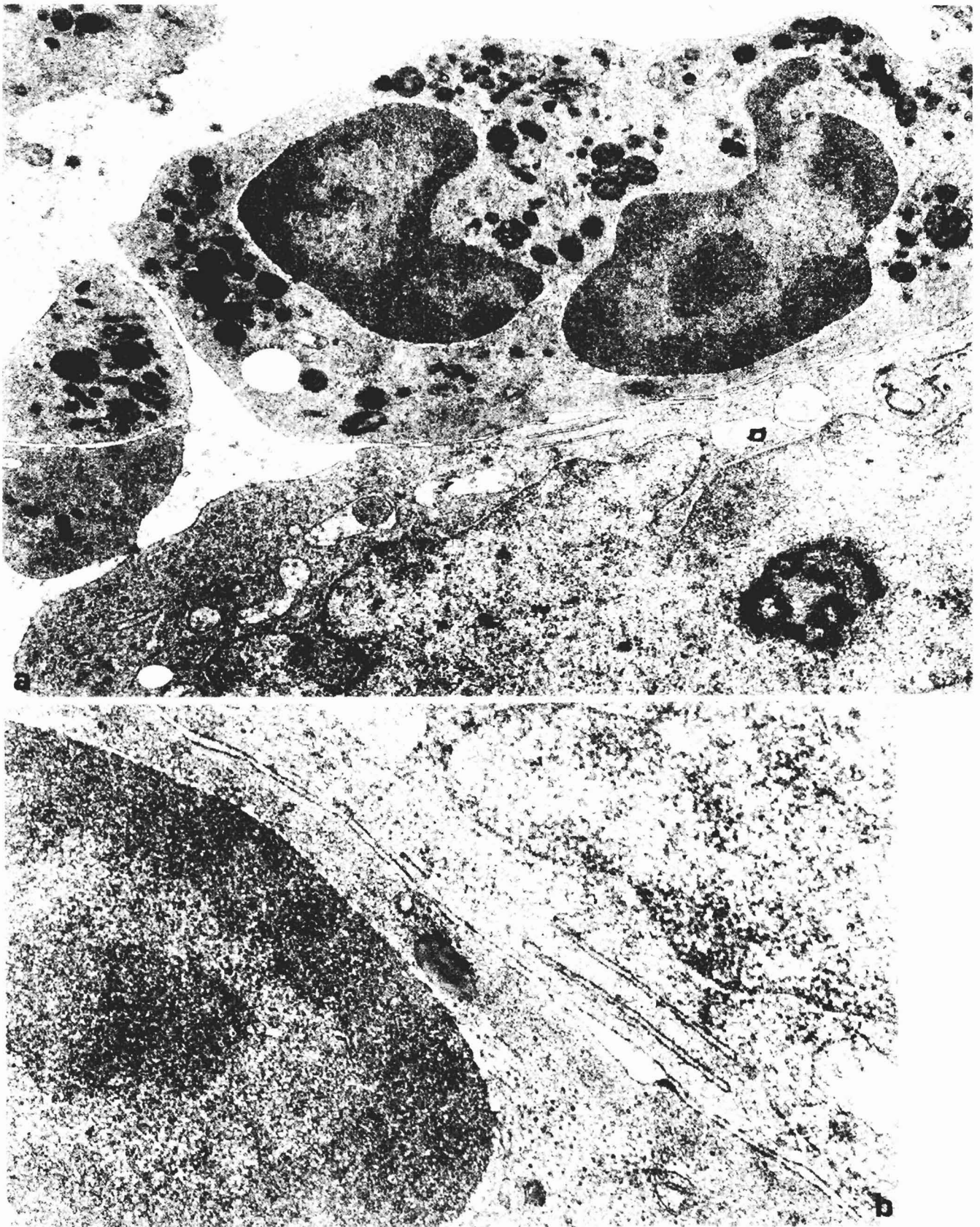


Fig. 3. a. Neutrophils exhibit pointed and broad contact with carcinoma cell. Note the presence of a lipid body in the neutrophil cytoplasm. x 20,000.
b. A closer view of the interface between the neutrophil and the contacting carcinoma cell. A micropinocytotic vesicle and a submembranous aggregate of microfilaments are present in the neutrophil at the site of contact with the tumour cell. x 32,000

Neutrophils and tumour cells in gastric cancer

preparation: 1) in spite of the presence of the damage to the tumour cells, neutrophils were themselves intact: 2) the adjacent tumour cells not contacted by neutrophils and other stromal cells contacted by neutrophils frequently remained intact; and 3) the initial damage to the tumour cells frequently occurred at the contacting regions with the neutrophil.

Also based on two additional reasons, we may exclude the possibility that the neutrophils are cytotoxic to degenerative or necrotic tumour cells. Firstly, the tumour cell only displayed focal cytopathic changes at the region of contact with the neutrophil, the rest of the tumour cell being morphologically well preserved. Secondly, the areas selected for the electron microscopic observations did not belong to those with sheets of coagulative necrosis, as is commonly seen in other

advanced malignant tumours.

Alternatively, the possibility that the tumour cell was secondarily involved by toxic products released from dead or dying neutrophils is ruled out, because neutrophils appear morphologically viable and they do not exhibit ultrastructural signs of regressive changes, such as pyknotic nucleus, autophagic vacuoles, little glycogen, granule clumping and fusion of the granules with plasma membrane.

We also exclude that the above-mentioned individual tumour cell damage may be an apoptosis, a distinct type of cell death which may occur spontaneously in growing tumours (Wyllie, 1987). Apoptosis is morphologically characterized by chromatin condensation into dense granular caps under the nuclear membrane (Arends et al., 1990). These findings were not observed in tumour

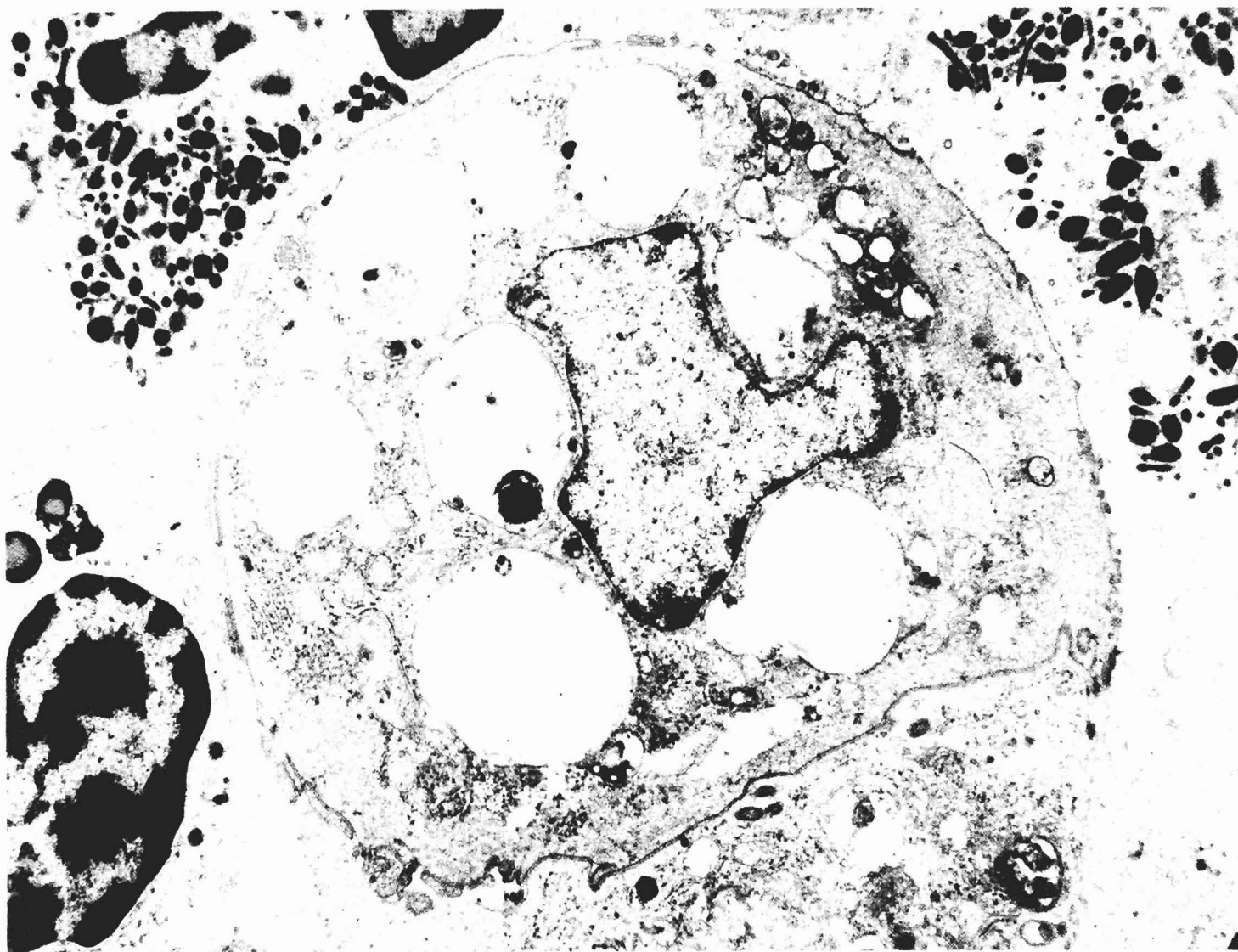


Fig. 4. Aggregates of neutrophils and eosinophil around a signet-ring cell. x 9,000

cells interacting with neutrophils. Furthermore, apoptotic cells do not induce an inflammatory reaction, even when present in large numbers (Arends et al., 1990).

The ability of neutrophils to kill tumour cells has been directly shown *in vivo* during the granulocyte-colony stimulating factor-elicited reaction (Forni et al., 1987; Colombo et al., 1992). Ultrastructural studies during IL-2-induced (Forni et al., 1987) and IL-4-induced (Bosco et al., 1990; Modesti et al., 1993) reactions show that cell death is primarily the outcome of direct membrane and cytoplasmic cell damage and only sometimes of apoptosis. In our cases, tumour cells in contact with neutrophils showed similar

focal cytopathic changes including cytoplasmic vacuolization, disruption or dilatation of the rough endoplasmic reticulum, and disorganization of the intermediate filaments. These ultrastructural features most closely resemble those seen in complement-mediated colloid osmotic tumour cell lysis (Russell et al., 1982).

Because this is a purely morphological study, no direct evidence of cytotoxicity could be provided. We assumed that, at least in small EGC, activated neutrophils might exert a direct cytotoxic effect of a colloid-osmotic type on the tumour cells. Further studies are necessary to reveal the full extent and

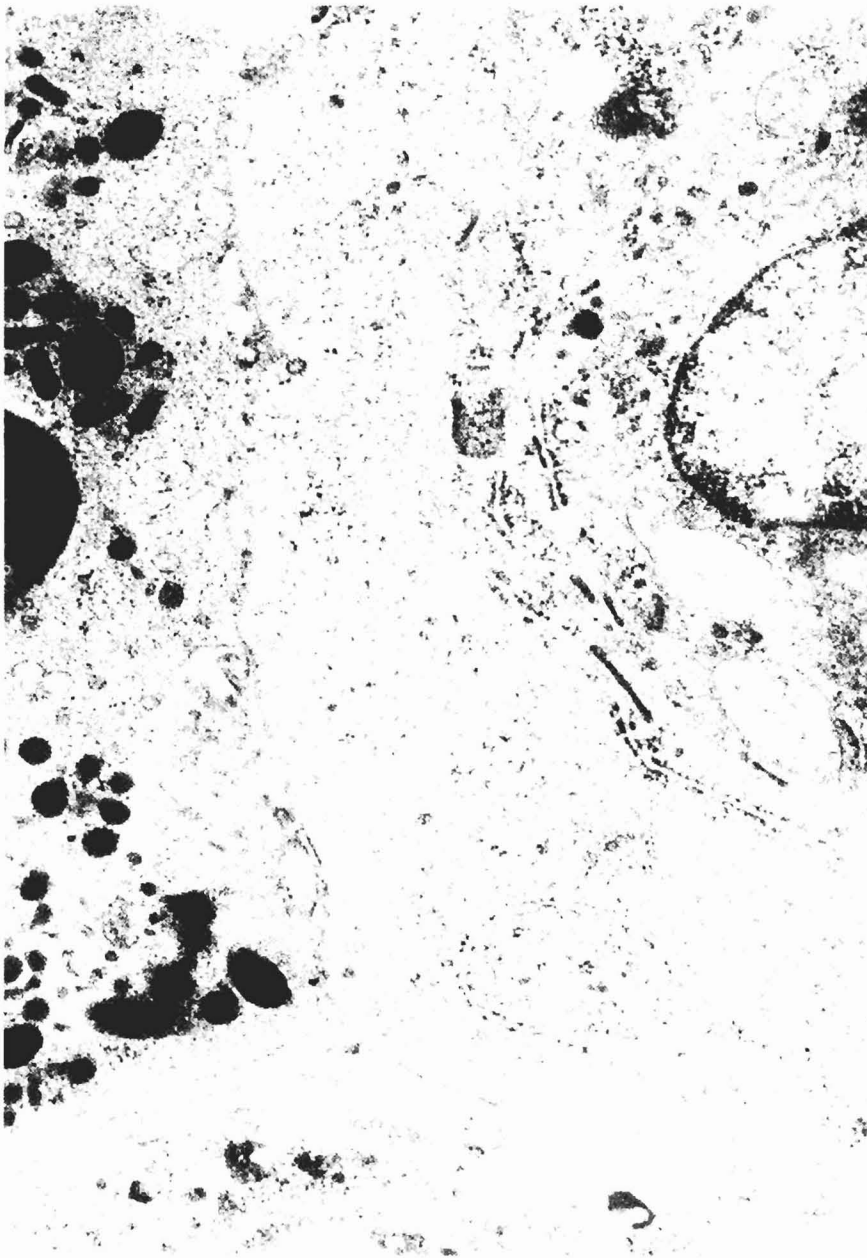


Fig. 5. Neutrophil and carcinoma cell are in intimate contact. Note the focal disruption of the rough endoplasmic reticulum and the disorganization of the intermediate filaments in the carcinoma cell. x 30,000

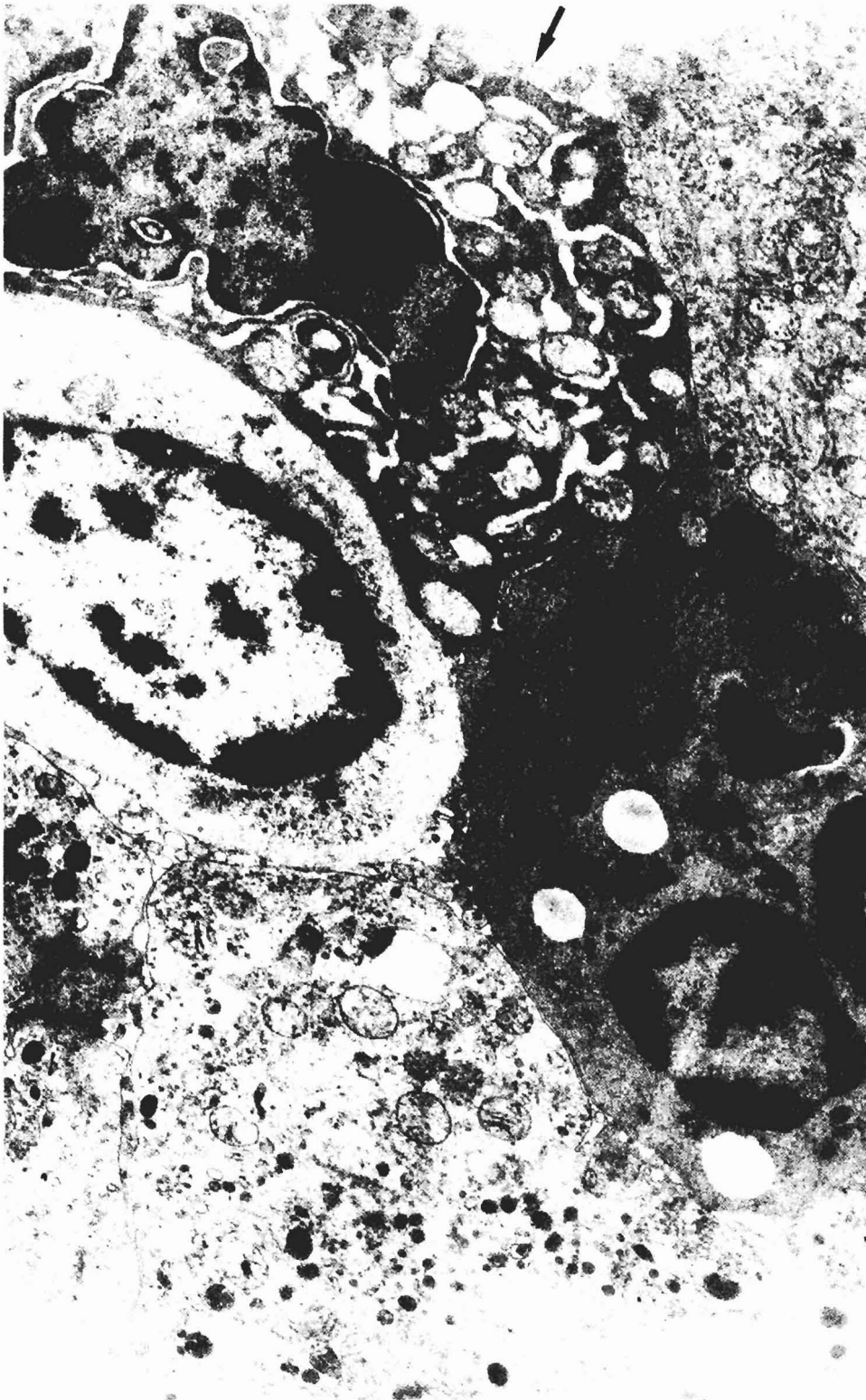


Fig. 6. An intact neutrophil is establishing a membrane interaction with a tumour cell, whose initial degeneration is denoted by some vacuolization and dilatation of the rough endoplasmic reticulum (arrow), x 20,000

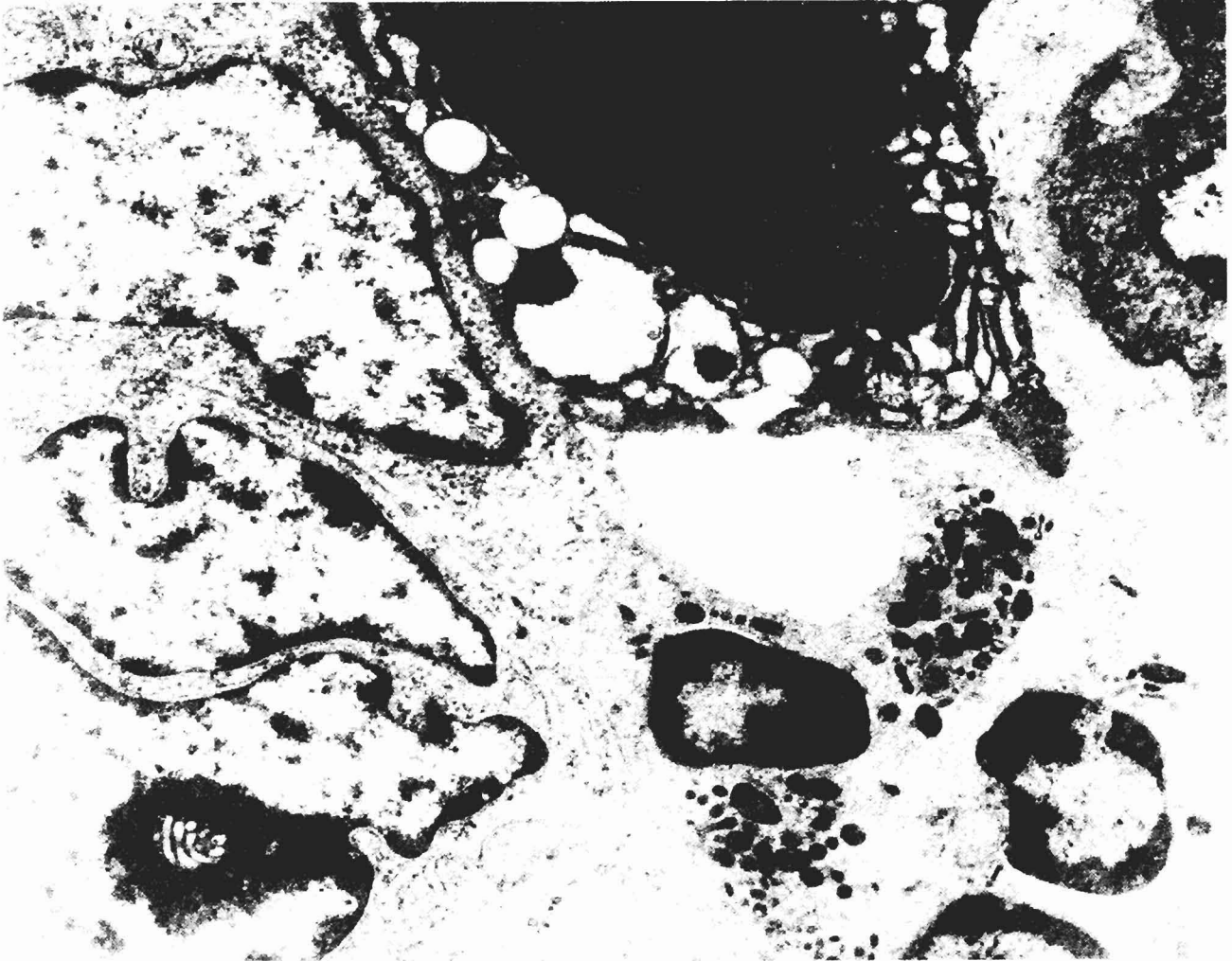


Fig. 7. An intact neutrophil is apparently interacting with severely damaged carcinoma cell. The latter displays dilatation of the rough endoplasmic reticulum and extrusion of granular flocculent material in the extracellular space. The adjacent tumour cells remain intact. x 20,000

prognostic significance of the neutrophil-tumour cell interactions.

Acknowledgements. The authors thank Dr. A. D'Andrea, Mr. M. Carnibella, Mr. S. Scimone, Mr. A. Macri', Mr. E. Sidoti and Mr. A. Raffa for their technical assistance.

References

- Arends M.J., Morris R.J. and Wyllie A.H. (1990). Apoptosis: the role of the endonuclease. *Am. J. Pathol.* 136, 593-608.
- Becker E.L. (1988). The cytotoxic action of neutrophil on mammalian cells in vitro. *Prog. Allergy* 40, 183-208.
- Bosco M.C., Giovarelli M., Forni M., Modesti A., Scarpa S., Masuelli L. and Forni G. (1990). Low doses of IL-4 injected perilymphatically in tumor-bearing mice inhibit the growth of poorly and apparently non-immunogenic tumors and induce a tumor-specific immune memory. *J. Immunol.* 145, 3136-3143.
- Caruso R.A., Giuffre' G. and Inferrera C. (1993). Minute and small early gastric carcinoma with special reference to eosinophil infiltration. *Histol. Histopath.* 8, 155-166.
- Clark R.A. and Klebanoff S.J. (1975). Neutrophil-mediated tumour cell cytotoxicity: role of the peroxidase system. *J. Exp. Med.* 141, 1442-1447.
- Clark R.A. and Klebanoff S.J. (1977). Studies on mechanism of antibody-dependent polymorphonuclear leukocyte-mediated cytotoxicity. *J. Immunol.* 119, 1413-1418.
- Clark R.A. and Szot S. (1981). The myeloperoxidase-hydrogen peroxide-halide system as effectors of neutrophil-mediated tumor cell cytotoxicity. *J. Immunol.* 126, 1295-1301.
- Colombo M.P., Lombardi L., Stoppacciaro A., Melani C., Parenza M., Bottazzi B. and Parmiani G. (1992). Granulocyte-colony stimulating factor (G-CSF) gene transduction in murine adenocarcinoma drives neutrophil-mediated tumor inhibition in vivo. *J. Immunol.* 145, 113-119.

Neutrophils and tumour cells in gastric cancer

- Dvorak A.M., Connell A.P., Proppe K. and Dvorak H.F. (1978). Immunologic rejection of mammary adenocarcinoma (TA3-St) in C57BL/6 mice: Participation of neutrophils and activated macrophages with fibrin formation. *J. Immunol.* 120, 1240-1248.
- Forni G., Giovarelli M., Santoni A., Modesti A. and Forni M. (1987). Interleukin-2 activated tumor inhibition in vivo depends on the systemic involvement of host immunoreactivity. *J. Immunol.* 138, 4033-4041.
- Hafeman D.G. and Lucas Z.J. (1979). Polymorphonuclear leukocyte-mediated, antibody-dependent cellular cytotoxicity against tumor cells: dependence on oxygen and the respiratory burst. *J. Immunol.* 123, 55-62.
- Lichtenstein A., Ganz T., Selsted M. and Lehrer R. (1986). In vitro tumor cell cytotoxicity mediated by peptide defensins of human and rabbit granulocytes. *Blood* 68, 1407-1410.
- Lichtenstein A.K., Ganz T., Selsted M.E. and Lehrer R.I. (1988). Synergistic cytotoxicity mediated by hydrogen peroxide combined with peptide defensins. *Cell. Immunol.* 114, 104-116.
- Modesti A., Masuelli L., Modica A., D'Orazi G., Scarpa S., Bosco M.C. and Forni G. (1993). Ultrastructural evidence of the mechanisms responsible for interleukin-4-activated rejection of a spontaneous murine adenocarcinoma. *Int. J. Cancer* 53, 988-993.
- Nathan C.F., Brukner L.H., Silverstein S.C. and Cohn Z. (1979). Extracellular cytotoxicity by activated macrophages and granulocytes. *J. Exp. Med.* 149, 84-100.
- Robinson J.M., Karnovsky M.F. and Karnovsky M.J. (1983). Glycogen accumulation in polymorphonuclear leukocytes, and other intracellular alterations that occur during inflammation. *J. Cell Biol.* 95, 933-942.
- Russell S.W., Doe W.F., Hoskins R.G. and Cochrane C.G. (1976). Inflammatory cells in solid murine neoplasms. I. Tumor disaggregation and identification of constituent inflammatory cells. *Int. J. Cancer* 18, 322-330.
- Russell J.H., Masakowski V., Rucinsky T. and Phillips G. (1982). Mechanisms of immune lysis. Characterization of the nature and kinetics of the cytotoxic T lymphocyte-induced nuclear lesion in the target. *J. Immunol.* 128, 2087-2094.
- Sandborg R.S. and Smolen J.E. (1988). Early biochemical events in leukocyte activation. *Lab. Invest.* 59, 300-320.
- Slivka A., Lo Buglio A.F. and Weiss S.J. (1980). A potential role for hypochlorous acid in granulocyte mediated tumor cell cytotoxicity. *Blood* 55, 347-352.
- Tauber A.I. (1987). Protein kinase C and the activation of the human neutrophil NADPH-oxidase. *Blood* 69, 711-720.
- Underwood J.C.E. (1974). Lymphoreticular infiltration in human tumors: prognostic and biological implications: a review. *Br. J. Cancer* 30, 538-548.
- Watanabe H., Jass J.R. and Sobin L.H. (1989). Histological typing of oesophageal and gastric tumours. In: World Health Organization; International Histological Classification of Tumours. Springer-Verlag, Berlin. pp 20-26.
- Weiss S.J. and Lo Buglio A.F. (1982). Phagocyte generated oxygen metabolites and cellular injury. *Lab. Invest.* 47, 5-12.
- Weller P.F. and Dvorak A.M. (1985). Arachidonic acid incorporation by cytoplasmic lipid bodies of human eosinophils. *Blood* 65, 1269-1274.
- Wyllie A.H. (1987). Apoptosis: cell death in tissue regulation. *J. Pathol.* 153, 313-316.

Accepted January 10, 1994