

Effects of chronic ethanol administration on the serotonin-producing cells in rat gastric antral and duodenal mucosa

V. Todorović¹, V. Koko¹, J. Varagić¹, V. Lačković², V. Vuzevski³ and J. Milin⁴

¹Institute for Medical Research, Belgrade, Yugoslavia, ²Institute of Histology and Embryology, Faculty of Medicine, Belgrade, Yugoslavia, ³Department of Pathology, Erasmus Universiteit Rotterdam, Rotterdam, The Netherlands and

⁴Institute of Pathology and Histology, Faculty of Medicine, Novi Sad, Yugoslavia

Summary. The present study describes our observations on optical and ultrastructural features of serotonin-containing cells in the rat antral and upper duodenal mucosa, utilizing optic morphometric measurements in a model of experimental chronic alcoholism of rat in which nutrition was well controlled. Male Wistar rats were given ethanol to provide 23 per cent of the total calories, while starch replaced ethanol isocalorically in controls. Twenty-five per cent of the calories were provided by protein in both groups. Blood levels of serotonin were significantly raised after chronic ethanol feeding (0.059 ± 0.06 vs. 0.159 ± 0.012 $\mu\text{g/ml}$, $p < 0.01$). Decrease in the number of immunohistochemically-detectable serotonin-containing cells was found in the pyloric gland mucosal area specimens of the chronically ethanol-treated rats (68.9 ± 5.2 vs 43.3 ± 3.0 ; $p < 0.001$). The immunohistologically-evaluated number of the same cells in the duodenal mucosa specimens was significantly decreased by alcohol feeding. Although total villi and crypt count per whole circular section, and the number of crypts per villus were not significantly changed either in control animals or in chronically ethanol-fed rats, decreased number of these cells per whole circular section (289 ± 21.6 vs. 183 ± 10.5 ; $p < 0.001$) per villus (2.52 ± 0.14 vs. 1.21 ± 0.10 ; $p < 0.001$) and per crypts (0.97 ± 0.08 vs. 0.79 ± 0.04 ; $p < 0.05$) were reported after alcohol consumption. In both control and experimental rats the cells were predominantly found in the basal half of the antropyloric mucosa. Alcohol did not lead to any changes in normal distribution of the duodenal serotonin-producing cells. The above quantitative changes in serotonin-producing cells were not accompanied by changes in their subcellular appearance in stomach and duodenal mucosa of alcohol-treated rat.

Key words: Ethanol, Serotonin-producing cells, Pylorus, Duodenum, Rat

Offprint requests to: Dr. Vera Todorović, M.D., Ph.D., Institute for Medical Research, 4 Dr. Subotića, P.O. Box 721, 11001 Belgrade, Yugoslavia

Introduction

Acute and chronic alcohol ingestion has been shown to produce mucosal injury in the stomach and intestine in various animal species and in man (Chey, 1972; Rubin et al., 1972; Baraona et al., 1974; Bode, 1980; Langman and Bell, 1982; Draper et al., 1983; Mezey, 1985; Todorović et al., 1985; Pavlović et al., 1985a,b; Wienbeck and Berges, 1985; Amindzhanov, 1986). Some of the results indicate that chronic ethanol intake produces disruption of the gastric mucosal barrier and may lead to haemorrhagic-erosive gastritis or ulcer (Chey, 1972; Bode, 1980; Wienbeck and Berges, 1985; Amindzhanov, 1986). Ethanol stimulates (Mezey, 1985) or not (Pavlović et al., 1985a; Todorović et al., 1985) cell regeneration in the upper gastrointestinal tract. Although the pathomechanism of the alcohol-induced lesions is still unclear, Bode et al. (1988) suggest that the inhibition of endogenous PGE_2 synthesis in the stomach following ingestion of appreciable quantities of alcohol might play a role in the pathogenesis of alcohol-induced injury of the gastric mucosa. Whether chronic ethanol ingestion significantly damages the small intestine remains controversial. After chronic ethanol consumption the small intestinal mucosa has been reported histologically normal in experimental animals (Rubin et al., 1972; Mazzanti and Jenkins, 1987) although shortened villi and increased incorporation of ^3H -thymidine into DNA in crypts have also been described (Baraona et al., 1974; Todorović et al., 1985). Mazzanti and Jenkins (1987) shows that chronic ethanol consumption in the rat is associated with a significant decrease in enterocyte turnover though the mucosa appears histologically normal. If there was no evidence of obvious malnutrition in the ethanol-fed rats, results showed only slight ultrastructural alterations of duodenal enterocytes (Pavlović et al., 1985b). Increased passive permeability of the small intestine has been described in chronic alcoholics (Bjornason et al., 1984). Chronic ethanol ingestion produced either a decrease or did not modify transport and absorption of nutrients (Krasner et al., 1976; Worthington et al., 1978; Carreras et al.,

1991).

In comparison to generally mucosal alterations of gastrointestinal tract, relatively little is known about the effect of alcohol on enteroendocrine cells and their hormonal response. Plasma levels of gastrin and peptide YY were not significantly changed under chronic and/or acute alcohol, while enteroglucagon levels were significantly raised after chronic ethanol feeding and even further elevated if an acute dose of alcohol was given to chronically ethanol-fed rats (Simanowski et al., 1989). In the same manuscript, the immunologically-evaluated numbers of the respective hormone-producing cells were not significantly changed by alcohol feeding. Amindzhanov et al. (1986) reported that circulating gastrin, neurotensin, substance P and somatostatin were markedly raised in human chronic alcoholics. The same results indicate that leu-enkephalin level does not significantly affect alcoholic subjects. Gastrin level was also significantly raised after an acute dose of alcohol in dogs and chronically ethanol-fed rats (Amindzhanov et al., 1986). G and ECL endocrine cells were decreased in stomach of alcoholic subjects and total enteroendocrine cell count in the rat gastric and duodenal mucosa was also decreased under conditions of chronic ethanol intake (Pavlović et al., 1985a; Amindzhanov et al., 1986). The acute peroral administration of alcohol did not lead to any changes in the ultrastructural appearance of the rat gastric enteroglucagon- and gastrin-producing cells (Zavlačić et al., 1976).

The cerebral neurotransmitter serotonin (5-HT) may play a role in the mechanism underlying physiological and behavioural effects of ethanol (Davydova and Fomina, 1987; Khatib et al., 1988; Ulrichsen, 1991; Yushimoto et al., 1991). A significant increase in blood serotonin content was observed both in chronically ethanol-fed rats and human alcoholics (Andreanova et al., 1985; Amindzhanov et al., 1986). The number of enterochromaffin (EC) cells visualized with Masson-Fontana techniques was decreased in stomach and duodenal mucosa of chronic alcoholics (Amindzhanov et al., 1986).

Since serotonin is involved in the regulation of many physiologically important actions of gastrointestinal tract, the aim of our work was to investigate possible morphological alterations of serotonin-containing endocrine cells of upper gastrointestinal tract. To the best of our knowledge, the morphometric analysis of immunohistochemically detected serotonin-containing endocrine cells of stomach and duodenum, and their ultrastructural properties, has not yet been studied in chronic experimental alcoholics.

Materials and methods

Experimental design

Thirty 60-day-old male rats of the Wistar strain were maintained in single cages at a constant temperature (22 °C) on an alternate 12:12 h light-dark cycle (lights

on at 7 a.m.). The animals were divided into 2 groups of 15 rats, which initially weighed between 223 and 251 g. Control (C) rats were fed a commercial stock cereal-based pelleted diet (25% of protein) as defined by Bieri et al. (1977). The ethanol group (E) was given free access to a hyperprotein (34% of protein) cereal-based pelleted diet and an aqueous solution of 25% sucrose (w/w)- 31% ethanol (v/v) as recommended by Hartroft (1971). The amount of tap water given to the control group was adjusted so that the rats in both groups received the same amount (approximately 40 ml) of liquid per day. The amount of food fed to control animals was adjusted daily to the energy intake of the animals receiving alcohol (pair-fed controls). The content of fat and vitamin-mineral mixture in each diet was similar. Ethanol was replaced by starch in the control diet. The feeding bottles were renewed daily. The average intake of ethanol, food, water and the body weight were controlled on day 7 and again on day 14, and so every week until the end of the experiment. The experiment lasted for 4 months. After being starved overnight, but with water available *ad libitum*, the animals were killed between 9 a.m. and 1 p.m. by a blow on the neck.

Blood ethanol determination

Samples for blood ethanol determination were obtained from the tail ven and blood ethanol levels determined using the Sigma diagnostic alcohol procedure (No. 322-UV, Sigma Chemical Co., St. Louis, MO). The mean blood ethanol level was determined for all ethanol-treated rats studied based upon multiple blood ethanol determinations (at 10 a.m. on day 1, 15, 30, 45, 60, 75, 90, 105 and 120) performed throughout the 120-day exposure period.

Blood serotonin determination

Serotonin was determined in the blood by the spectrofluorometric technique introduced by Das (1972) in all the examined animals at the end of the experiment.

Immunohistochemistry

Tissue preparation. Small tissue specimens were taken from the pyloric gland area (antrum) and from the upper duodenum of treated rats (n=30 for each specimen). Each specimen was immediately fixed in Bouin's solution for 24 h, dehydrated in xylene and embedded in paraffin wax. During the paraffin-embedding process we tried to orientate the specimen with the mucosal surface perpendicular to the cutting surface. Only «ideal» (with intact stroma from the base of the mucosa to the top of the villi) or «satisfactory» (including the whole mucosa but with the villi or glandular lumen interrupted) 4 µm thick sections were made.

Antiserum. The polyclonal antiserum against serotonin

Ethanol and serotonin-producing cells

(Euro Diagnostics, BV Holland, Code No. LOT 006), working dilution 1:100, used in the present study has been characterized and employed in previous investigations.

Immunohistochemical protocol. After removal of the paraffin wax, the sections were immunostained by the unlabelled peroxidase-antiperoxidase complex (PAP) technique (Sternberger, 1986). Briefly, sections were incubated with antisera against serotonin in appropriate working dilution for 45 min at 22 °C. Then, the sections were incubated with swine anti-rabbit IgG (DAKO Corp., CA) at 1:300 for 45 min and finally with soluble PAP complex (DAKO Corp., CA) at 1:50 for 45 min. Visualization of immunoreactive sites was performed in DAB-HCL/H₂O₂ (0.7 mM diamino-benzidine HCl/0.002% H₂O₂) in TRIS-HCl, pH 7.6, for 5 min. Phosphate-buffered saline (PBS, 0.1M, pH 7.4) served as diluent of all antisera (first, second and third layers) and as rinsing solution between the various steps of the protocol. The nuclei were counterstained with Mayer's haematoxylin. The specificity of the antiserum was examined by immunohistochemistry in sections of the normal human gastric antral and duodenal mucosa. No positive stainings were observed in control sections incubated with either absorbed anti-serotonin serum or normal rabbit serum instead of the 1st layer antiserum.

Routine electron microscopy

The specimens were immediately placed in a mixture of 2% glutaraldehyde and 2% paraformaldehyde in 0.2M sodium cacodylate buffer, pH 7.4, minced into very small pieces and fixed in the same fixative for 20 h at 4 °C. After postfixation for 1 h in 1% osmium tetroxide in cacodylate buffer, the specimens were dehydrated in graded ethanol and embedded in Araldite®, under a magnifying glass, with the mucosa surface perpendicular to the cutting surface. The blocks were sectioned with an LKB ultratome II. Ultrathin sections were doublestained with uranyl acetate and lead citrate before examination in an Opton 109 electron microscope.

Morphometric analysis of serotonin-containing endocrine cells detected by PAP procedure

Conventional morphometry analyses the number of specifically stained cells per measured field. In each examined part of the gastrointestinal tract, three sections at intervals of 50 µm were estimated. In all sections the serotonin-producing enterochromaffin cells were counted at a total magnification of x 400. Only cells with nuclei were counted.

The number of serotonin-producing endocrine cells in the pyloric gland area was estimated in 5 Weibel's multipurpose grid areas with a base of grids on the muscularis mucosa, and the number of cells per unit area (mm²) was calculated. The number of serotonin-

containing endocrine cells in the duodenal mucosa was estimated separately in each whole circular section, all the villi and the crypts.

Results

Nutrition, blood, ethanol and serotonin levels

The average daily amounts of energy consumed from food and separately from ethanol, protein, fat and carbohydrate intakes are shown in Figure 1. The daily intake of food, alcohol, main nutrients, and the growth profile of rats fed the examined diets are summarized in Table 1. The data in Figure 1 and Table 1 show that there was no significant difference between the ethanol-treated rats and controls with regard to daily energy intake, and energy from protein and fat. The ethanol-fed rats consumed 8.42±0.36 g ethanol/kg body weight/day, but gained weight similarly to the pair-fed controls which received an isocaloric diet.

The blood ethanol level was 110±14 mg% (mean±SEM) and ranged from 95 mg% to 130 mg%.

Blood levels of serotonin were significantly raised

Table 1. Daily nutrient intake and body weight (mean±SEM) of the treated animals.

PARAMETER	GROUP C	GROUP E
Food (g/day)	23.92±0.02	16.08±0.13
Ethanol (g/day) (g/kg/day)	-	3.09±0.17 8.42±0.36
Protein (g/day) (g/kg/day)	5.88±0.00 18.47±0.19	5.53±0.00 16.93±0.30
Fat (g/day) (g/kg/day)	1.16±0.00 3.63±0.04	1.09±0.00 3.04±0.10
Carbohydrate (g/day) (g/kg/day)	13.70±0.00 43.03±0.45	9.47±0.16 26.18±0.48
Vitamin-mineral mixture (g/day) (g/kg/day)	0.06±0.00 0.19±0.00	0.06±0.00 0.17±0.00
Body weight (g) 60 days	232±1.4	246±2.40
180 days	376±5.5	388±21.0

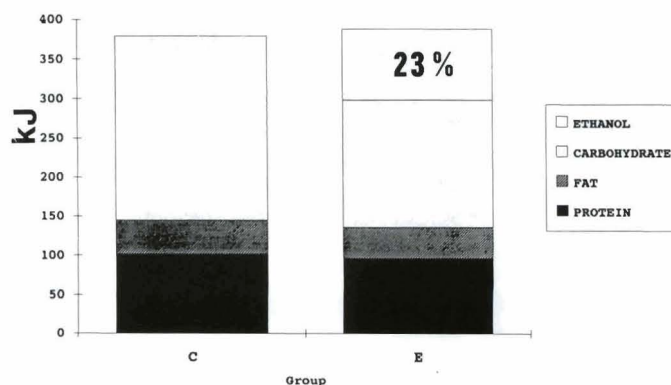


Fig. 1. Daily amount of energy consumed by the treated animals.


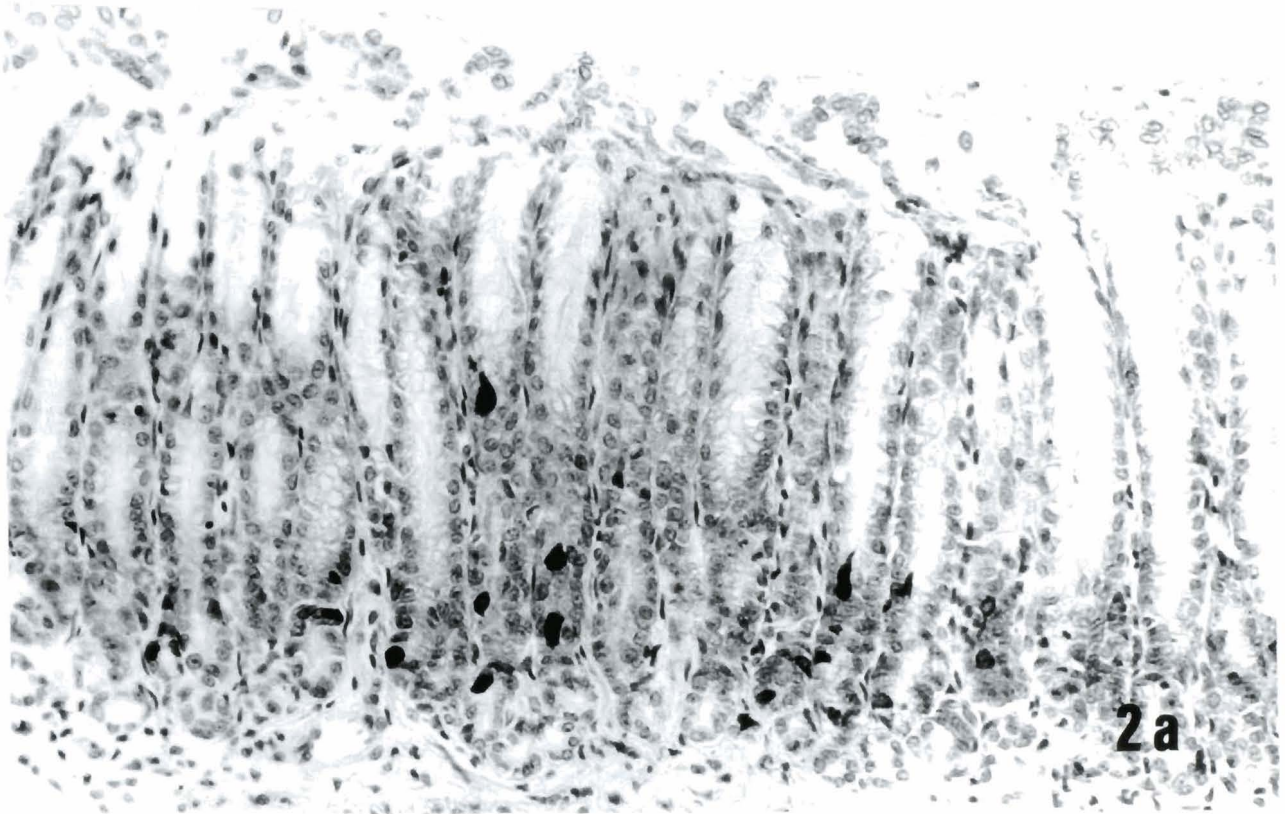


Fig. 2. Pyloric gland area of control (a) and ethanol-treated (b) rat. Serotonin immunoperoxidase (PAP) staining. A smaller number of serotonin-containing cells occur in the alcohol-fed rats. x 900

Ethanol and serotonin-producing cells

after chronic ethanol feeding (0.059 ± 0.006 vs 0.159 ± 0.012 $\mu\text{g/ml}$; $p < 0.01$).

Morphometric analysis of immunostained serotonin-producing endocrine cells

A summary of the quantitative analysis of immunohistochemically-detected serotonin-containing endocrine cells of the pyloric gland area and duodenal mucosa is shown in Table 2.

Decrease in the number of immunohistochemically-detectable serotonin-producing cells was found in the pyloric gland mucosal area specimens of the chronically ethanol-treated rats (Fig. 2). In both control and experimental rats the respective cells were found

Table 2. Summary of quantitative data of immunohistochemically detected serotonin-containing endocrine cells of the pyloric gland area and duodenal mucosa.

PARAMETER	C (n=15)	E (n=15)	P<
<i>Number of cells</i>			
Pyloric gland area (per mm ² mucosa)	88.9 \pm 5.2*	42.3 \pm 3.0	0.001
<i>Duodenum</i>			
Whole circular section	289.8 \pm 21.6	183.2 \pm 10.5	0.001
Per villus	2.52 \pm 0.24	1.21 \pm 0.10	0.001
Per crypt	0.97 \pm 0.08	0.79 \pm 0.04	0.05
<i>Number of duodenal villi per whole circular section</i>			
	47.9 \pm 1.6	42.0 \pm 1.2	n.s.
<i>Number of duodenal crypts per whole circular section</i>			
	175.5 \pm 4.6	168.4 \pm 4.1	n.s.
<i>Number of crypt per villus</i>			
	3.72 \pm 0.15	4.05 \pm 0.13	n.s.

*: $\bar{X} \pm \text{SEM}$.

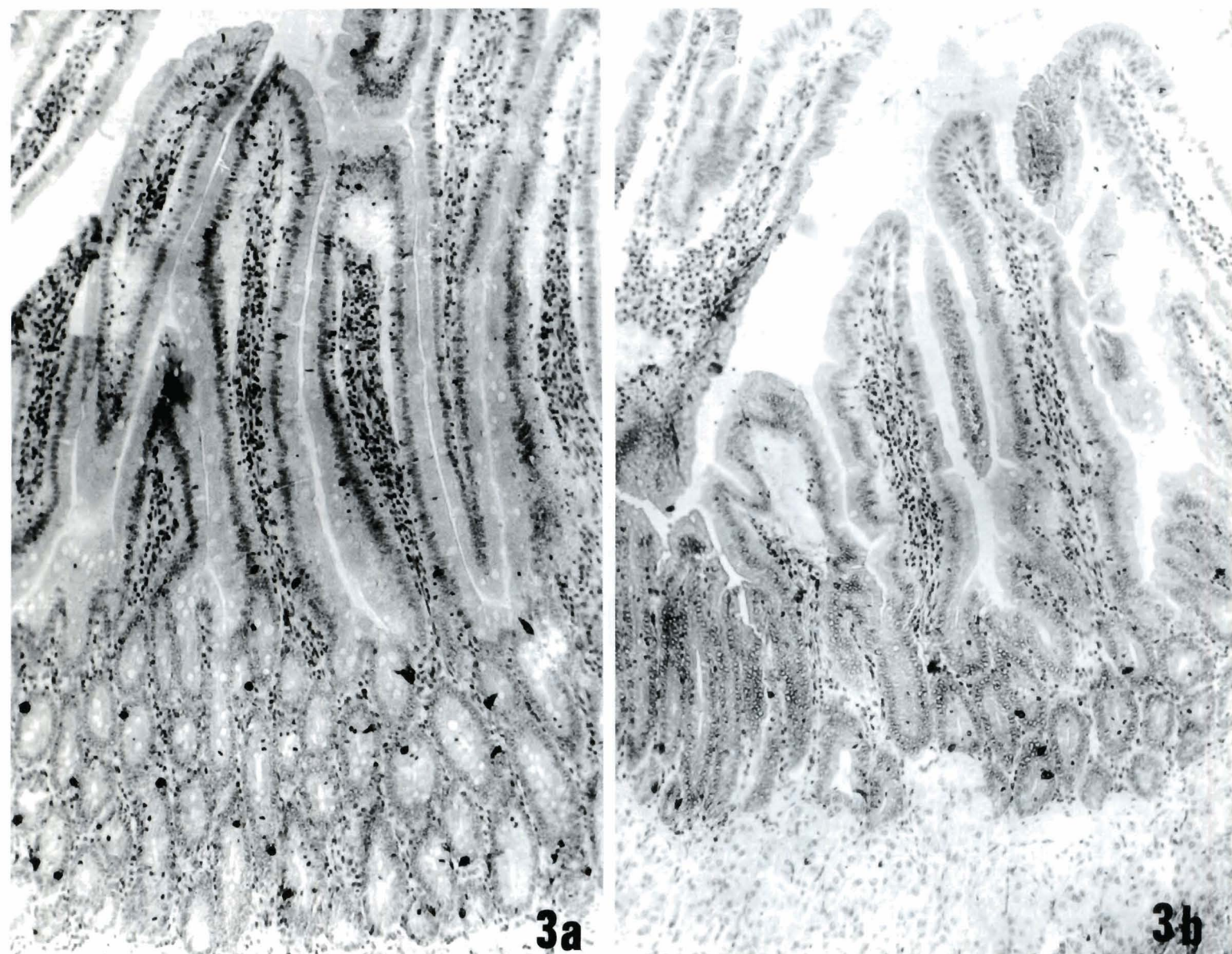


Fig. 3. Immunostained EC cells in perpendicular sections obtained from rat duodenal mucosa of control (a) and alcohol-fed (b) rats. Note different size of cells between groups from top of villi to base of crypts. $\times 450$

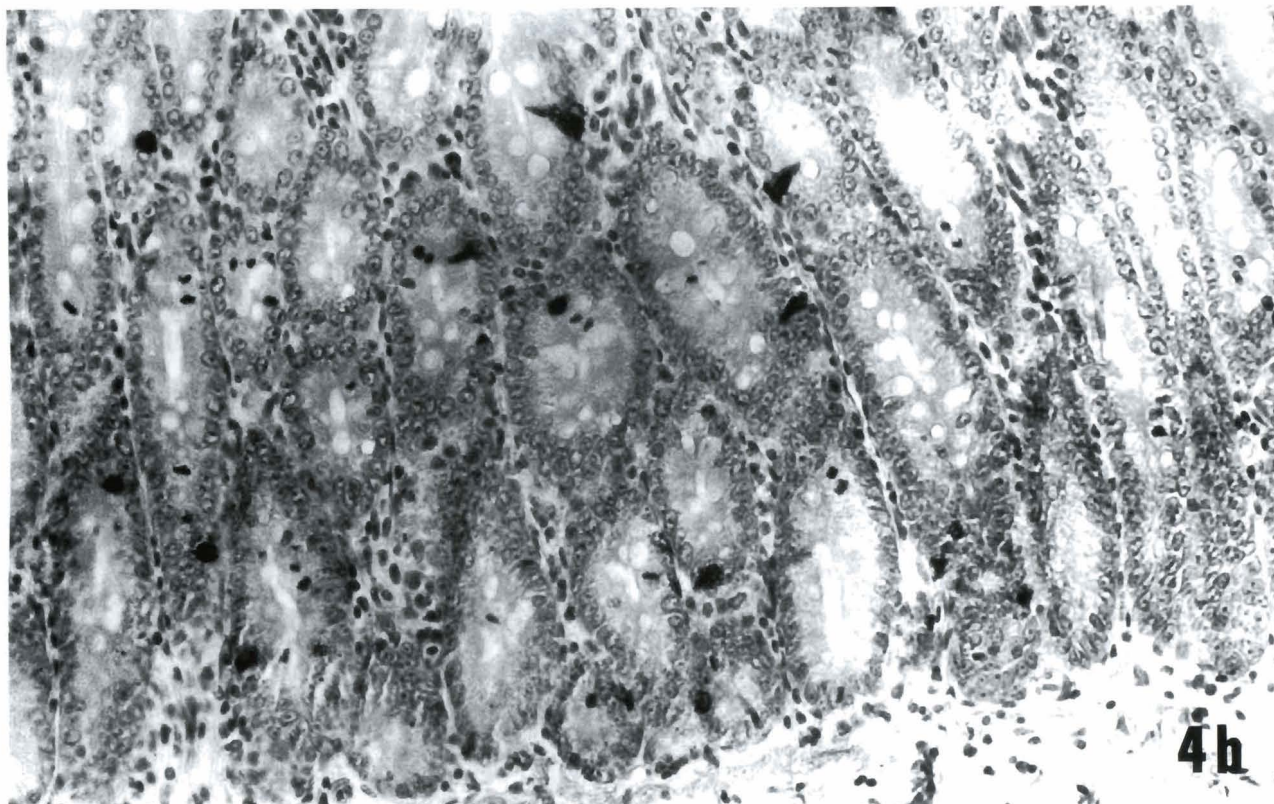
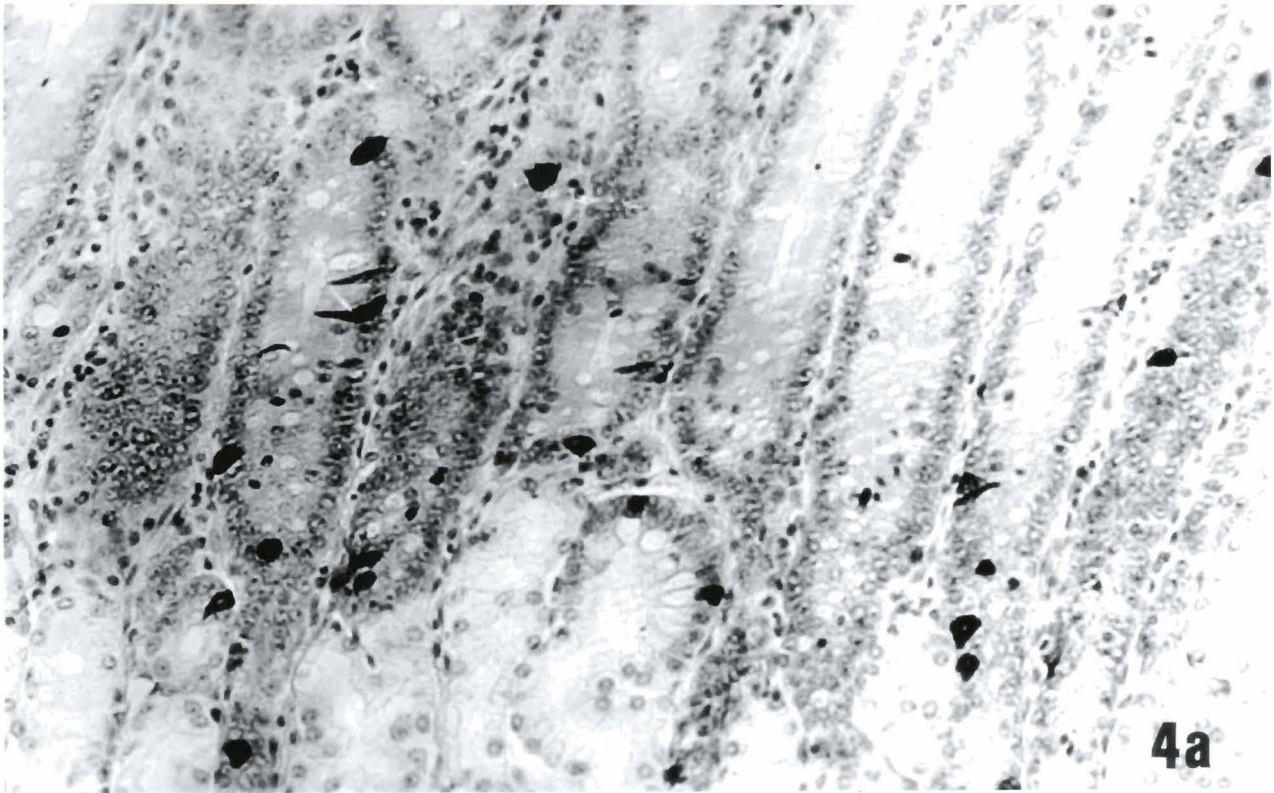


Fig. 4. Crypts of rat duodenal mucosa; section stained with the serotonin immunoperoxidase technique. Note decreased number of cells per crypt after alcohol consumption (**b**) in comparison to control rat (**a**) x 900

predominantly in the basal half of the antropyloric mucosa.

Although total villi and crypt count per whole circular section, and the number of crypts per villus, were not significantly changed in control animals nor in chronically ethanol-fed rats, decreased number of these cells per whole circular section, per villus and per crypt were reported after alcohol consumption (Figs. 3, 4). Alcohol did not lead to any changes in normal distribution of the duodenal serotonin-producing cells (Fig. 5).

Ultrastructural studies

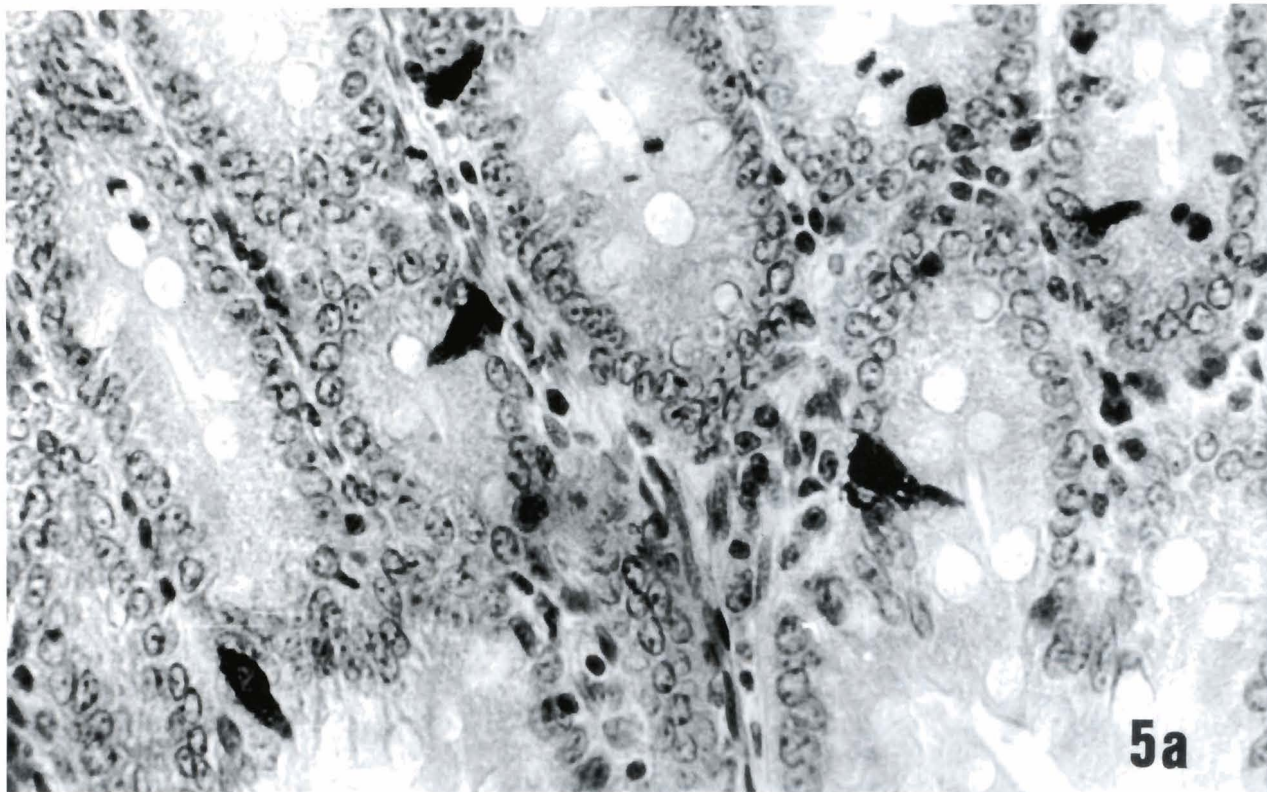
Enterochromaffin endocrine cells of stomach and duodenal mucosa, identified in the above described manner, were photographed and classified according to the 1977 Lausanne nomenclature and data of Larsson and Jørgensen (1978), Sinyavska and Vinogradova (1981), Dey and Hoffpauir (1984) and Portela-Gomes et al. (1984a,b).

Electron microscopic examination showed that the argentaffin cells contained secretory granules in all the cytoplasmic area (Figs. 6, 7), but in some argentaffin cells of alcohol-treated rats secretory granules were observed in a more luminal position. Essentially two different profiles of membrane-bound secretory granules could be distinguished, one round and the other (more numerical) pleomorphic (oval, biconcave, kidney-shaped, rod-like) (Fig. 8). The majority of the secretory

granules were electron-dense. The size of the secretory granules in the different zones of the individual cells of the stomach and duodenal mucosa did not differ significantly after alcohol consumption. The cells contained only a small amount of rough endoplasmic reticulum, mainly parallel to the nuclear surface. Smooth endoplasmic reticulum was very rare and mitochondria were few. The nucleus was often oval with scanty chromatin which was mainly concentrated in the periphery. A large nucleolus was often seen centrally. These properties support the view that chronic administration of alcohol does not lead to any changes in the ultrastructural appearance of argentaffin cells of pyloric and duodenal mucosa.

Discussion

Alcohol, direct and indirect, alters the function of the endocrine system in clinically relevant ways. Alcohol use and abuse causes clinical abnormalities of the following endocrine functions: the hypothalamic-pituitary-gonadae axis; the hypothalamic-pituitary-adrenal axis; thyroid gland; and secretion of atrial natriuretic peptide (Noth and Walter, 1984; Adler, 1992; Leppäluoto et al., 1992). Despite much new data, concepts remain difficult to formulate, because of differences in dosage and route of administration of alcohol, in hormone assays, in factors such as nutritional state and liver disease in patient populations, and even in interpretation of the same data by different researchers.



Neuroendocrine system of gastro-entero-pancreatic (GEP) axis in acute and chronic alcohol ingestion remains controversial and an unexplored area.

Enterochromaffin (EC) cells, comprising a major population of the gut endocrine cells, have been identified by conventional and immunohistochemical techniques, and their morphology, functional and metabolic activity are very well known (Larsson and Jergensen, 1978; Sinyavskaya and Vinogradova, 1981; Dey and Hoffpauir, 1984; Solovyova et al., 1984; Jaffe and Brooklyn, 1984; Portela-Gomes et al., 1984a,b). The contribution to the central, as well as peripheral regulation of gastrointestinal activity by 5-HT, is well

documented. Serotonin, as a product of gut enterochromaffin cell, myenteric plexus and serotonergic nerves, effects acid secretion, mucus output, motility, mesenteric blood flow, duodenal mucosal blood flow (Ormsbee III and Fondacoro, 1985; Baez et al., 1990; Tsukamoto et al., 1991; Lee and Fanburg, 1992). 5-HT is also directly or indirectly involved in the regulation of food ingestion (Lyons and Truswell, 1988; Bubenik et al., 1992; Curzon, 1992).

In our study, we use a model of experimental chronic alcoholism of rat in which nutrition was well controlled, and alcohol intake was high (8.42 ± 0.36 g/kg body weight/day).




Fig. 5. Immunostained serotonin-containing cells showing normal their distribution in crypts (a) and villi (b) of duodenal mucosa after alcohol consumption. x 1,800

Ethanol and serotonin-producing cells

There is very little data about the effect of acute or chronic administration of alcohol on blood serotonin levels and quantitative analysis of gut enterochromaffin serotonin-producing cells. Our analysis showed that blood levels of serotonin were significantly raised after chronic ethanol feeding, and this data agrees with results of Andrianova et al. (1985) and Amindzhanov (1986). Although total villi and crypt count per whole circular section, and the number of crypts per villus were not significantly changed in control animals nor in chronically ethanol-fed rats, decreased number of these cells per whole circular section, per villus and per crypts were reported after alcohol consumption. Decrease in the number of immunohistochemically-detected serotonin-containing cells was found in the pyloric gland area mucosal specimens of the chronically ethanol-treated rats. These results agree with data of Amindzhanov (1986) who was found decreased number of silver-stained entero-

chromaffin cells of antral and duodenal mucosa in chronic alcoholics. However, it is very difficult to compare these data because our study is the first of quantitative analysis of immunohistochemically-detected EC cells in upper gastrointestinal tract of chronically ethanol-treated rats.

Evaluation of subcellular structure of these cells in chronic alcoholic man and animals has not yet been investigated. Alcohol did not lead to any changes in the ultrastructural appearance of these cells. These data agree with similar data from Zaviačič et al. (1976) who reported that after fasting, peroral administration of alcohol was not accompanied by changes in EC cell subcellular appearance.

We hypothesized that enterochromaffin cells may play a role in the pathogenesis of the disturbed function of upper gastrointestinal tract after chronic alcohol feeding, but these findings need further investigation.

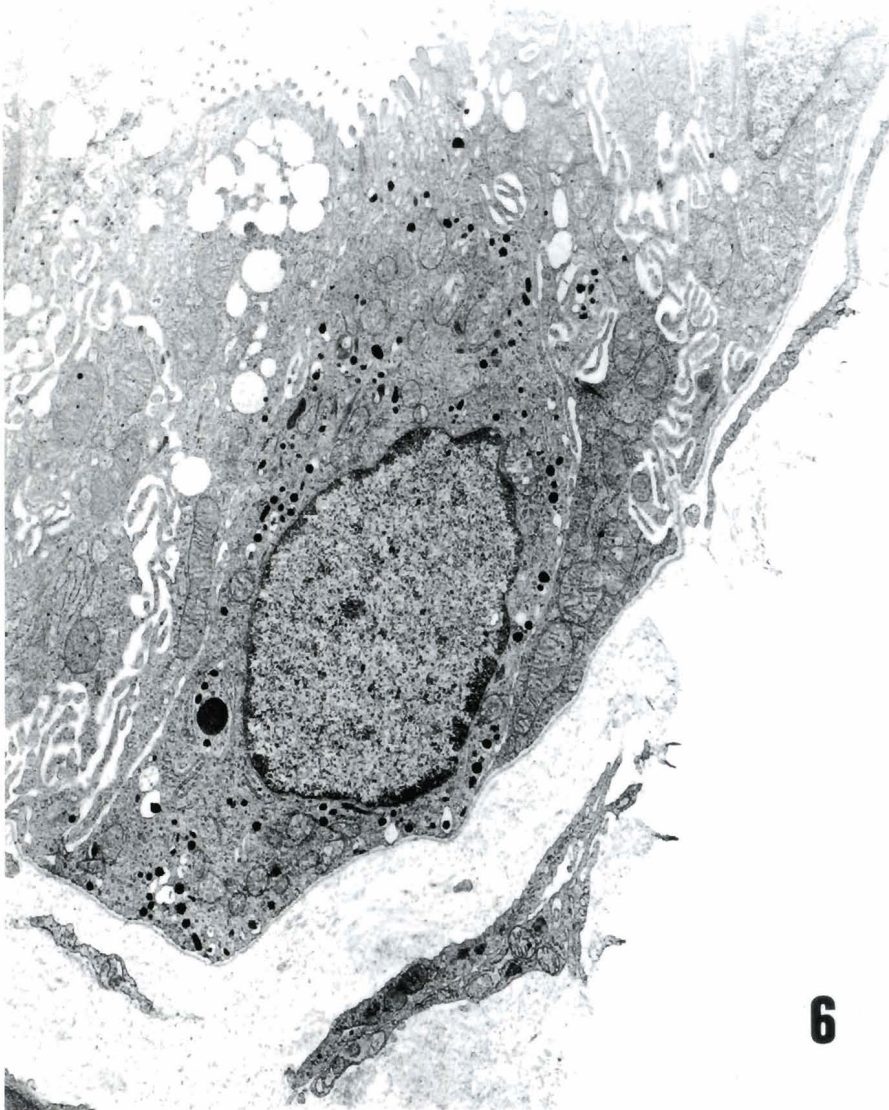
**6**

Fig. 6. Electron micrograph of enterochromaffin cell from the pyloric gland area of alcohol-fed rat. This normal ultrastructure was characterised by the presence of pleomorphic dense core granules. x 8,800

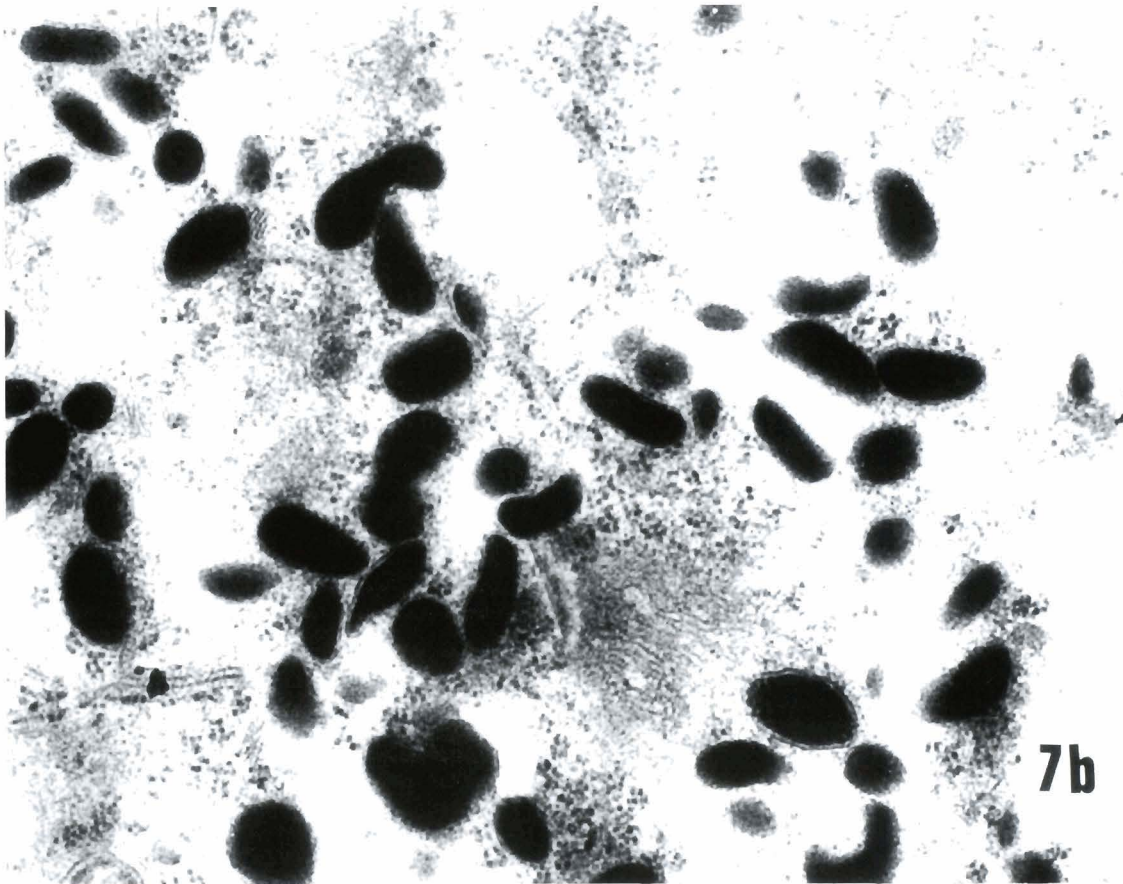
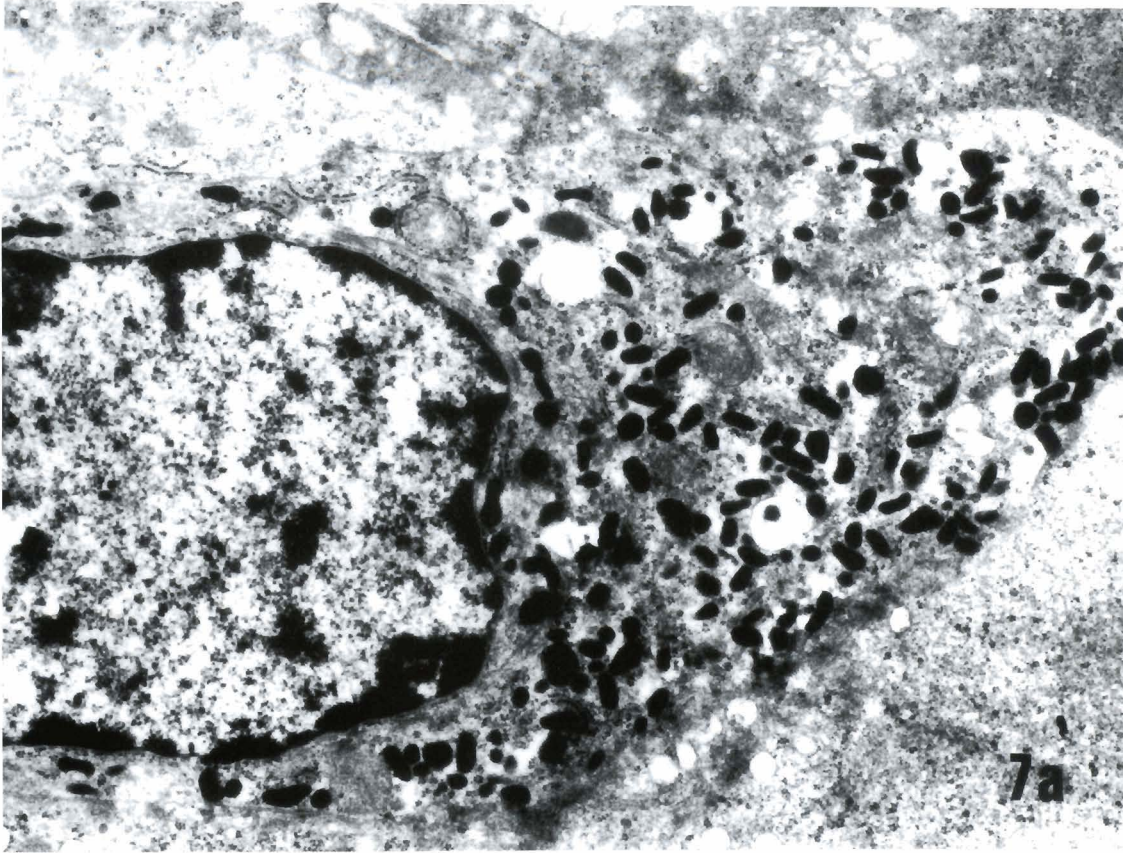
Ethanol and serotonin-producing cells

Fig. 7. Part of the enterochromaffin cell from the duodenum of alcohol-fed rat (**a**), showing normal mitochondria, ribosomes and sparse secretory granules in the cytoplasmic zone towards the basal lamina. x 14,000. High power electron micrograph of the duodenal enterochromaffin cell of alcohol-fed rat (**b**). Of distinguished two subgroups of profiles 3/4 were pleomorphic. x 40,000

Acknowledgements. This work was supported by the Republic of Serbia Research Found and private company S.T.R. «Ibis Petrol» (bb M. Tita Street, Ruma, Srbija). The technical help of M. sci. Mihailo Ristic is highly appreciated.

References

- Adler R. (1992). Clinically important effects of alcohol on endocrine function. *J. Clin. Endocrinol. Metabol.* 74, 957-960.
- Amindzhanov S. (1986). Alterations of upper part of the gastrointestinal tract by alcohol: clinical and experimental research. D. Sc. Thesis. Leningrad (USSR).
- Andreanova M.V., Amindzhanov S.A., Ardemassowa V.N., Kalikhevitch V.N., Shvatvkhin Yu.P., Smirnova Yu.A., Shishkina A. and Zavalishina N.A. (1985). Changes of serotonin and histamine contents in the rat blood after chronic administration of neuropeptides and ethanol. *Sechenov Physiol. J. USSR* 71, 921-924.
- Baez M., Yu L. and Cohen L. (1990). Pharmacological and molecular evidence that the contractile response to serotonin in rat stomach fundus is not mediated by activation of the 5-hydroxy tryptamine $1C$ receptor. *Mol. Pharmacol.* 38, 31-37.
- Baraona E., Pirola E.C. and Lieber C.A. (1974). Small intestinal damage and changes in cell population produced by ethanol ingestion in the rat. *Gastroenterology* 66, 226-234.
- Bieri J.G., Stroewsand G.S., Briggs G.M., Phillips R.W. and Woodard J.C. (1977). Report of the American Institute of Nutrition ad hoc Committee on standards for nutritional studies. *J. Nutr.* 107, 1340-1349.
- Bjornason I., Ward K. and Peters T.J. (1984). The leaky gut of alcoholism: possible route of entry for toxic compounds. *Lancet* I, 179-182.
- Bode J.C. (1980). Alcohol and the gastrointestinal tract. *Adv. Intern. Med. Pediatr.* 45, 1-75.
- Bode C., Ito T., Rollenhagen A. and Bode J.C. (1988). Effect of acute and chronic alcohol feeding on prostaglandin E_2 biosynthesis in rat stomach. *Dig. Dis. Sci.* 33, 814-818.
- Bubenik G.A., Ball R.O. and Pang S-F. (1992). The effect of food deprivation on brain and gastrointestinal tissue levels of tryptophan, serotonin, 5-hydroxyindoleacetic acid, and melatonin. *J. Pineal Res.* 12, 7-16.
- Carreras O., Vázquez A.L., Rubio J.M., Delgado M.J. and Murillo M.L. (1991). Effect of chronic ethanol on D-galactose absorption by the rat whole intestinal surface. *Alcohol* 9, 83-86.
- Chey W.Y. (1972). Alcohol and gastric mucosa. *Digestion* 7, 239-255.
- Curzon G. (1992). Serotonin and eating disorders: pharmacological relationships. In: Serotonin receptor subtypes: Pharmacological significance and clinical implications. Vol 1. Langer S.Z., Brunello N., Ricagni G. and Mendlewicz J. (eds). Karger. Basel. pp 112-128.
- Das M.A. (1972). A rapid sensitive method for direct estimation of serotonin in whole blood. *Biochem. Med.* 6, 299-303.
- Davydova T.V. and Fomina V.G. (1987). Antibodies to catecholamines and serotonin during alcoholic intoxication in animals with different predisposition to the development of experimental alcoholism. *Bull. Exp. Biol. Med. (USSR)* 104, 672-673.
- Dey R.D. and Hoffpaur J. (1984). Ultrastructural immunocytochemical localization of 5-hydroxytryptamine in gastric enterochromaffin cells. *J. Histochem. Cytochem.* 32, 661-666.
- Draper L.R., Gyure L.Y., Hall J.G. and Robertson D. (1983). Effect of alcohol on the integrity of the intestinal epithelium. *Gut* 24, 339-404.
- Hartroft W.S. (1971). Methods of alcohol administration in chronic experiments. In: Biological basis of alcoholism. Israel Y. and Mardones I. (eds). John Wiley & Sons, Inc. New York. pp 106-108.
- Jaffe B.M. and Brooklyn N.Y. (1984). The gastrointestinal tract as an endocrine organ. *J. Thorac. Cardiovasc. Surg.* 88, 880-883.
- Khatib S.A., Murphy J.M. and McBride W.J. (1988). Biochemical evidence for activation of specific monoamine pathways by ethanol. *Alcohol* 5, 295-299.
- Krasner N., Cochran K.M. and Russel R.I. (1976). Alcohol and absorption from the small intestine. *Gut* 17, 245-248.
- Langman J.S. and Bell G.D. (1982). Alcohol and the gastrointestinal tract. *Br. Med. Bull.* 82, 71-75.
- Larsson L-I. and Jørgensen L.M. (1978). Ultrastructural and cytochemical studies on the cytodifferentiation of duodenal endocrine cells. *Cell Tissue Res.* 194, 79-102.
- Lee S-L. and Fanburg B.L. (1992). Serotonine produces a configurational change of cultured smooth muscle cells that is associated with elevation of intracellular cAMP. *J. Cell Physiol.* 150, 396-405.
- Leppäluoto J., Vuolteenaho O., Arjama O. and Ruskoaho H. (1992). Plasma immunoreactive antral natriuretic peptide and vasopressin after ethanol intake in man. *Acta Physiol. Scand.* 144, 121-127.
- Lyons P.M. and Truswell A.S. (1988). Serotonin precursor influenced by type of carbohydrate meal in healthy adults. *Am. J. Clin. Nutr.* 47, 433-439.
- Mazzanti R. and Jenkins W.J. (1987). Effect of chronic ethanol ingestion on enterocyte turnover in rat small intestine. *Gut* 28, 52-55.
- Mezey E. (1985). Effect of ethanol on intestinal morphology, metabolism and function. In: Alcohol-related diseases in gastroenterology. Seitz H.K. and Hommerell B. (eds). Springer. Berlin. pp 342-360.
- Noth R.H. and Walter M. Jr. (1984). The effects of alcohol on the endocrine system. *Med. Clin. North Am.* 68, 133-146.
- Ormsbee III H.S. and Fondacaro J.D. (1985). Action of serotonin on the gastrointestinal tract. *Proc. Soc. Exp. Biol. Med.* 178, 333-338.
- Pavlović M., Todorović V. and Ristić M. (1985a). Evaluation of the quantitative state of individual cell types in rat gastric and duodenal mucosa during normoprotein nutrition and chronic ethanol intake. Study II. *Acta Med. Iug.* 39, 57-73.
- Pavlović M., Todorović V. and Ristić M. (1985b). Protein nutrition, chronic ethanol intake, histochemical and ultrastructural properties of rat duodenal mucosa enterocytes. *Iugoslavica Physiol. Pharmacol. Acta* 21, 245-245.
- Portela-Gomes G.M., Grimelius L. and Bergström R. (1984a). Enterochromaffin (argentaffin) cells of the rat gastrointestinal tract. *Acta Pathol. Microbiol. Immunol. Scand. (A)*. 92, 83-89.
- Portela-Gomes G.M., Grimelius L., Petersson R. and Bergström R. (1984b). Enterochromaffin cells in the rat gastrointestinal tract. *Upsala J. Med. Sci.* 89, 189-203.
- Rubin E., Rybak B.J. and Lindenbaum J. (1972). Ultrastructural changes in the small intestine induced by ethanol. *Gastroenterology* 63, 801-814.
- Simanowski U.A., Hubalek K., Ghatei M.A., Bloom S.R., Polak J.M. and Seitz H.K. (1989). Effects of acute and chronic ethanol administration on the gastrointestinal hormones gastrin, enteroglucagon, pancreatic glucagon and peptide YY in the rat. *Digestion* 42, 167-173.

Ethanol and serotonin-producing cells

- Sinyavskaya I.M. and Vinogradova M.S. (1981). Ultrastructural study of gastric endocrine cells of hungry and fed immature rats. *Bull. Exp. Biol. Med.* 41, 238-241.
- Solovyova I.A., Kocherginsky E.B. and Kazakov V.K. (1984). Serotonin and neurotensin-containing cells in the digestive tract tunica mucosa. *Arch. Anat. Histol. Embriol. (USSR)* 86, 75-80.
- Stenberger L.A. (1986). *Immunohistochemistry*. 3rd edn. Wiley. New York.
- Todorović V., Pavlović M. and Ristić M. (1985). Integrity, histologic organization and renewal ability of rat gastric and duodenal mucosa under condition of normoprotein dietary regime and chronic alcohol ingestion. Study I. *Acta Med. Iug.* 39, 41-55.
- Tsukamoto Y., Goto H., Hase S., Arisawa T., Ohara A., Suzuki T. and Hoshino H. (1991). Serotonin-induced decrease of duodenal mucosal blood flow plus acid load produces duodenal mucosal lesion in rats. *Digestion* 50, 99-113.
- Uhrichsen J. (1991). Alterations in serotonin receptor subtypes in ethanol-dependent rats. *Alcohol and Alcoholism* 26, 567-573.
- Wienbeck M. and Berges W. (1985). Esophageal and gastric lesions in the alcoholic. In: *Alcohol related diseases in gastroenterology*. Seitz H. and Kommerall B. (eds). Springer. Berlin. pp 361-375.
- Worthington B.S., Meserole L. and Syrotuck J.A. (1978). Effect of daily ethanol ingestion of the intestinal permeability to macromolecules. *Am. J. Dig. Dis.* 28, 23-32.
- Yushimoto K., McBride W.J., Lumeng L. and Li T-K. (1991). Alcohol stimulates the release of dopamine and serotonin in the nucleus accumbens. *Alcohol* 9, 17-22.
- Zavlačić M., Brozman M. and Jakubovsky J. (1976). Influence of fasting and stimulation on the rat gastric endocrine cells. Histochemical and ultrastructural study. *Histochemistry* 49, 315-325.

Accepted December 1, 1992