

## Morphometric study on the renal glomeruli of streptozotocin (SZ)-induced diabetic APA hamsters

J.-S. Han and K. Doi

Department of Biomedical Science, Faculty of Agriculture, The University of Tokyo, Bunkyo-ku, Tokyo, Japan

**Summary.** Morphometrical analysis was done on the renal glomeruli of streptozotocin (SZ)-induced diabetic and control APA hamsters. In coincidence with the histopathological and ultrastructural findings, the areas of whole glomerulus (WG) and mesangial region (MR) were significantly larger in diabetic animals than in controls at 1 and 3 months after SZ-injection (1 and 3MAI). The area of capillary lumen in diabetic animals was larger than that in controls at 1MAI but it became similar between both groups at 3MAI probably due to an increase in the area of MR. The thickness of basement membrane was significantly larger in diabetic animals than in controls at 3MAI. The present morphometrical findings, together with histological and ultrastructural ones, suggest that SZ-induced diabetic APA hamsters are useful as a model system for the investigation of focal and segmental glomerulosclerosis.

**Key words:** APA hamster, Focal segmental glomerulosclerosis, Morphometry, Streptozotocin

### Introduction

Syrian hamsters of APA strain have been developed in Japan (Tajima, 1968) and maintained as a closed colony by random breeding in our laboratory. APA hamsters are known to develop spontaneous mesangial thickening in the renal glomeruli from 4 weeks of age (Han et al., 1992a). They also develop focal and segmental glomerulosclerosis (FSG) after 6 months of age (Doi et al., 1987) instead of glomerular amyloidosis which is the most common renal lesion in aged Syrian hamsters of other strains (Mezza et al., 1984). Recently Han et al. (1992b) succeeded in the induction of glomerular lipidosis and subsequent FSG in APA hamsters by streptozotocin (SZ). It is a precious

model which can easily produce glomerular lipid deposition; one of the early changes observed in FSG (Diamond and Karnovsky, 1988; Magil and Cohen, 1989). This paper describes the morphometric analysis of the renal glomeruli of SZ-induced diabetic APA hamsters.

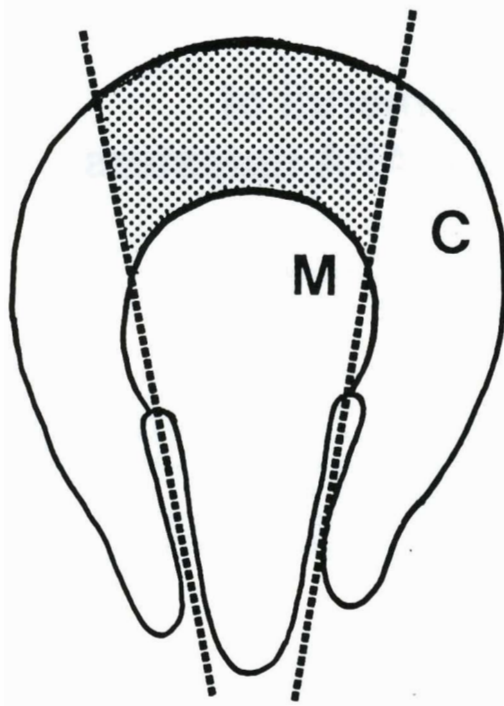
### Materials and methods

Based on the previous study (Han et al., 1990), 12 2-month-old male APA hamsters were injected intraperitoneally with 40 mg/kg b.w. of SZ (Lot No. 78F-0517, Sigma) dissolved in 0.1M citrate buffer (pH 4.5). One out of 12 animals was excluded from the experiment at 1 day after injection (1DAI) because its blood glucose level failed to rise. Eight age-matched male APA hamsters which were injected with citrate buffer alone served as controls. The animals were maintained under controlled conditions (temperature,  $24\pm1^{\circ}\text{C}$ ; relative humidity,  $55\pm5\%$ ) in plastic cages with sterilized wood shavings for bedding, and fed a commercial diet, CMF (Oriental Yeast Co. Ltd., Tokyo) and tap water *ad libitum* throughout the experimental period.

Blood samples collected after overnight fasting from the orbital sinus of each animal at 1 and 3 months after injection (1 and 3MAI) were measured colorimetrically for serum glucose levels using Glucose C-test kit (Wako Pure Chemical Industries Inc., Osaka). Twenty-four hour urine samples were collected using metabolic cages at 1 and 3MAI. Urinalysis for glucose and total protein excretion was done using uropaper (Eiken Chemical Co., Tokyo) and micro-TP test kit (Wako Pure Chemical Industries Inc., Osaka), respectively.

Four SZ-injected and 4 control animals were sacrificed by exsanguination under ether anaesthesia at both 1 and 3MAI. Immediately after macroscopic examination, kidneys were fixed in 10% neutral buffered formalin, and 2  $\mu\text{m}$  paraffin sections of the kidney were stained with haematoxylin and eosin (HE) or periodic acid-Schiff (PAS). For electron microscopic

### Renal morphometry of diabetic APA hamsters



**Fig. 1.** Schematic diagram of glomerulus of APA hamster. Thirty glomeruli were chosen randomly from the dotted area of the cortex (C). M = medulla.

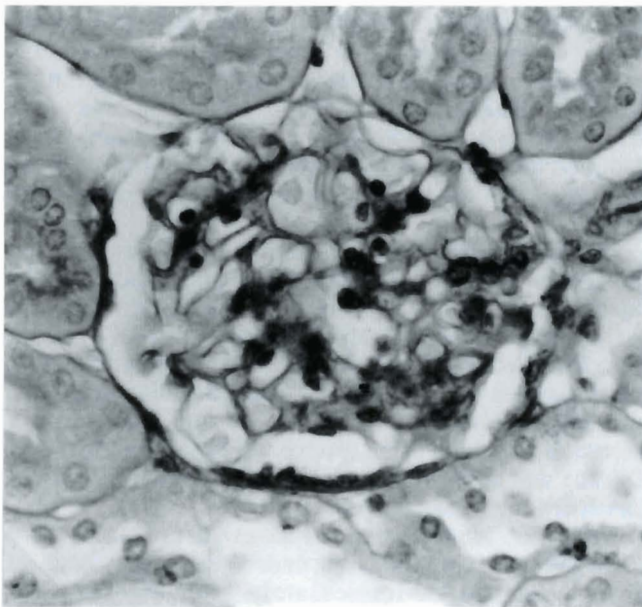
examination, small pieces of the renal cortex obtained from each animal were fixed in 2.5% glutaraldehyde and 2% paraformaldehyde in 0.1M phosphate buffer (pH 7.4), post-fixed in 1% osmium tetroxide in the same buffer, and embedded in epoxy resin, Quetol 812 (Nisshin EM Co. Ltd., Tokyo). Ultrathin sections were double-stained with uranyl acetate and lead citrate.

Morphometric analysis of the renal glomeruli was performed on PAS-stained paraffin sections at 1 and 3 MAI using colour image analyzer (SPICCA II: Olympus Co. Ltd., Tokyo) and on the above-mentioned ultrathin sections at 3MAI using electron microscopic analyzer (JEM-1200 EXII : JEOL Co. Ltd., Tokyo), respectively. Thirty glomeruli per kidney of an animal were randomly chosen from the cortical area (Fig. 1) of 4 animals of each group. The following items were analyzed on paraffin sections; the areas of whole glomerulus (WG), glomerular mesangial region (MR) and glomerular capillary lumen (CL), and the number of glomerular mesangial cells (MC). In addition, vertical thickness of the basement membrane (BM) of glomerular capillary was measured on ultra-thin sections at 3MAI. Namely, 4 glomeruli per kidney of an animal were randomly chosen from 4 animals of each group. Then, the vertical thickness of BM was measured on 10 capillary loops per glomerulus at the distal portion from the junction of MR and BM of each capillary loop.

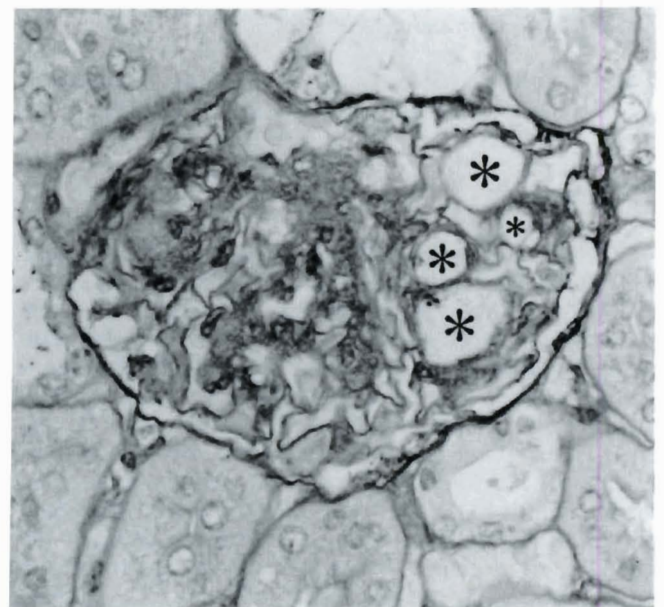
Statistical analysis was performed using Student's t-test and values were expressed as mean  $\pm$  SD.

### Results

Clinically, 11 of 12 SZ-injected hamsters showed



**Fig. 2.** A glomerulus of SZ-injected APA hamster at 1MAI. Mild expansion of mesangial region. PAS. x 480



**Fig. 3.** A glomerulus of SZ-injected APA hamster at 3MAI. Prominent expansion of mesangial region with foam cells (asterisks). PAS. x 480



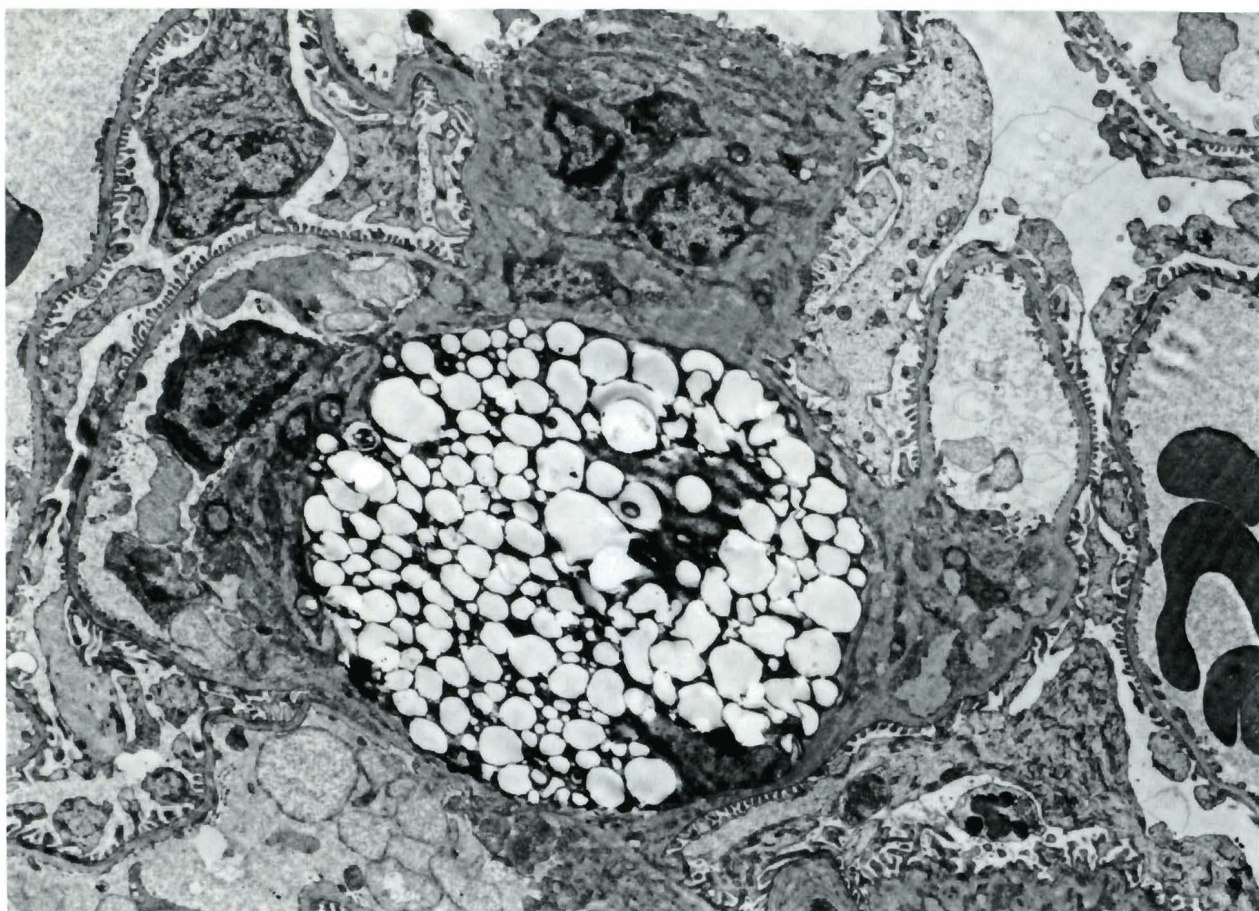


Fig. 4. A glomerulus of SZ-injected APA hamster at 3MAI. Foam cell in expanded mesangial region.  $\times 3,750$

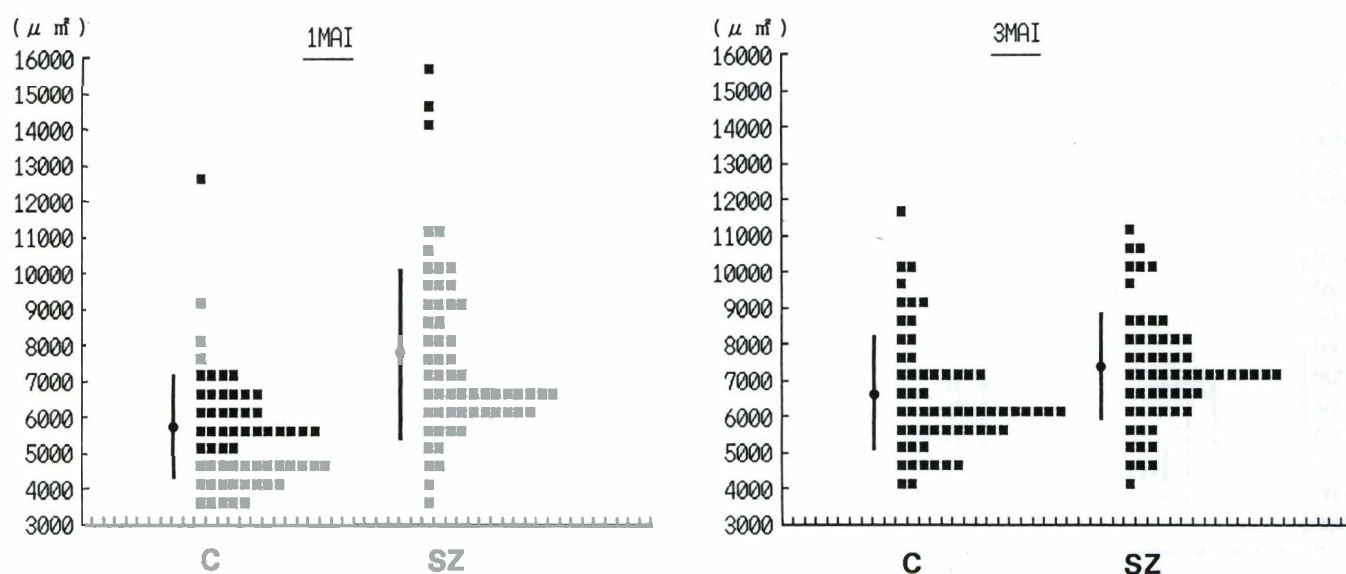


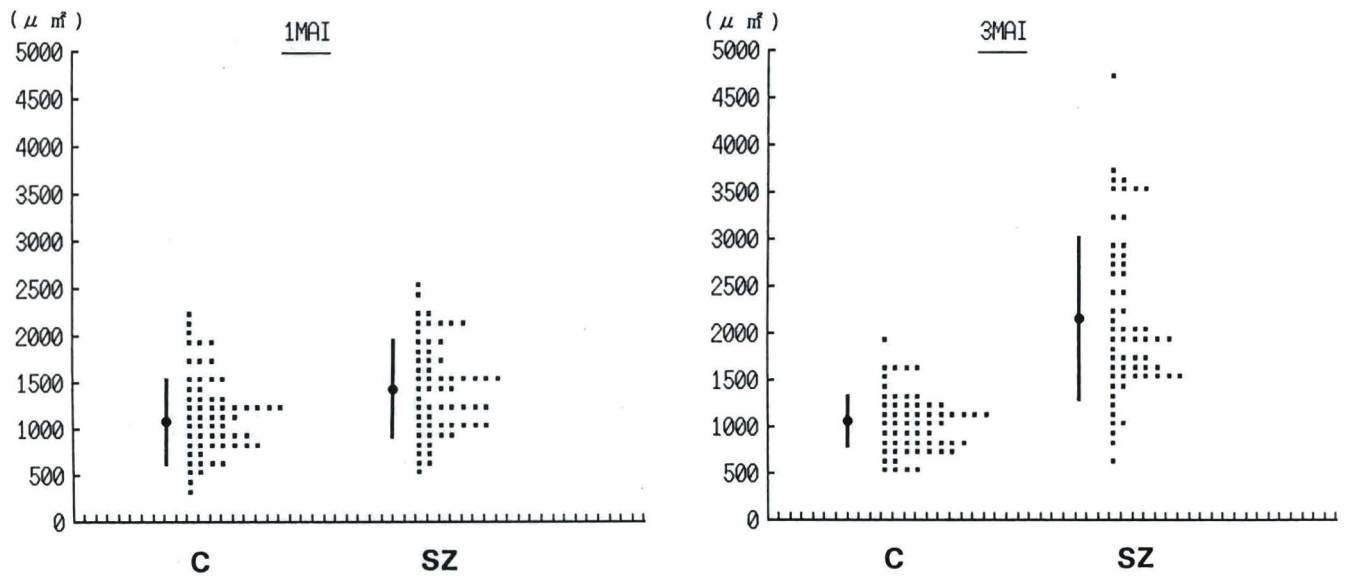
Fig. 5. Changes in the area of whole glomerulus of APA hamster. Values are expressed by  $50 \text{ nm}^2$  unit. Bar (  $\bullet$  ) is mean  $\pm$  SD. C: control group, SZ: SZ-induced diabetic group.

# Renal morphometry of diabetic APA hamsters

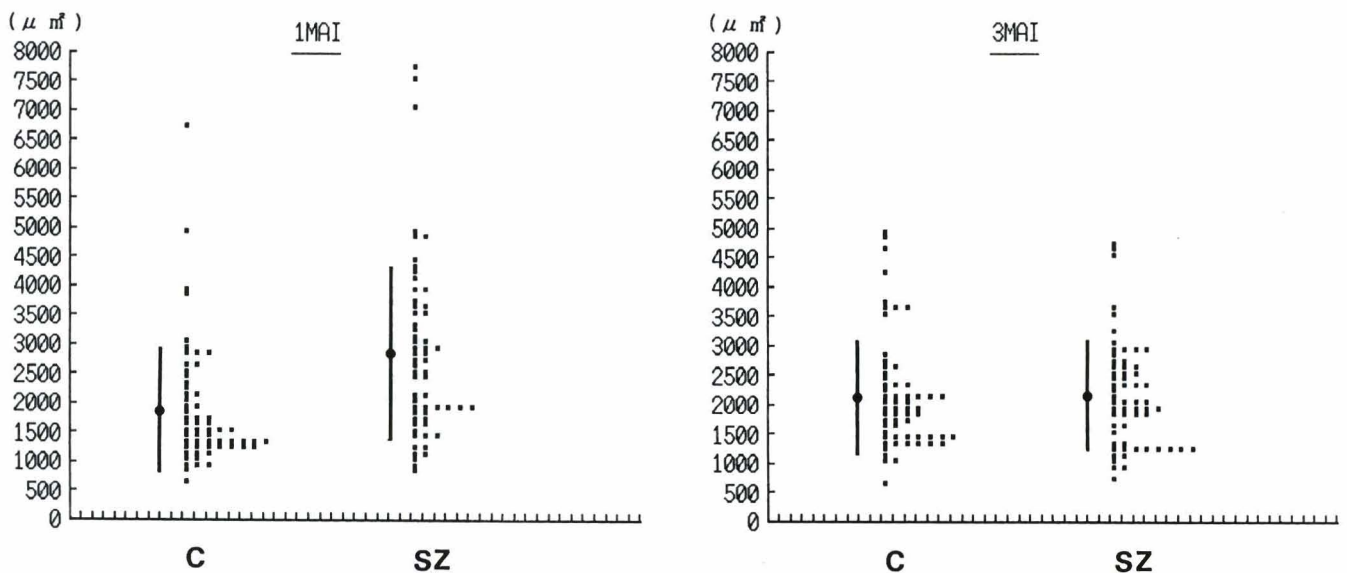
prominent hyperglycemia ( $>320$  mg/dl) at 1DAI and kept that level until killed as scheduled. They were also positive for urine protein (1MAI:  $10.3 \pm 4.2$  mg/day; 3MAI:  $18.6 \pm 6.0$  mg/day) and for urine glucose (500–2,000 mg/dl) throughout the experimental period. Urine samples of control animals were positive for protein

(1MAI:  $3.4 \pm 1.3$  mg/day; 3MAI:  $5.4 \pm 2.5$  mg/day) but not for glucose.

Glomeruli of SZ-induced diabetic hamsters showed mild FSG with mild lipid deposition and irregular capillary dilatation at 1MAI (Fig. 2). These lesions were found in some glomeruli in the juxtamedullary cortex.



**Fig. 6.** Changes in the area of mesangial region of APA hamster. Values are expressed by  $10\text{nm}^2$  unit. Bar (—●—) is mean  $\pm$  SD. C: control group, SZ: SZ-induced diabetic group.



**Fig. 7.** Changes in the area of capillary lumen of APA hamster. Values are expressed by  $100\text{nm}^2$  unit. Bar (—●—) is mean  $\pm$  SD. C: control group, SZ: SZ-induced diabetic group.



**Table 1.** Morphometrical findings of renal glomeruli of APA hamster.

	1MAI		3MAI	
	C	SZ	C	SZ
WG ( $\mu\text{m}^2$ )	5688 $\pm$ 1529.8	7749 $\pm$ 2400.7 <sup>a</sup>	6686 $\pm$ 1591.1	7376 $\pm$ 1564.1 <sup>b</sup>
MR ( $\mu\text{m}^2$ )	1161 $\pm$ 396.2	1451 $\pm$ 487.9 <sup>a</sup>	1062 $\pm$ 310.8	2152 $\pm$ 861.4
CL ( $\mu\text{m}^2$ )	1874 $\pm$ 1037.3	2848 $\pm$ 1506	2171 $\pm$ 956.2	2176 $\pm$ 900.1
MC (n)	20.5 $\pm$ 5.33	28.7 $\pm$ 8.32	18.9 $\pm$ 3.67	23.7 $\pm$ 7.11
BM (nm)	N.E.	N.E.	0.22 $\pm$ 0.028	0.33 $\pm$ 0.37 <sup>a</sup>

Values are mean $\pm$ S.D. of 4 animals. Significantly different from age-matched controls (a:  $p \leq 0.001$ ; b:  $p \leq 0.05$ ). C: control group. SZ: SZ-induced diabetic group MAI: months after injection. N.E.: not examined.

At 3MAI, more prominent FSG with lipid droplets and foam cells developed (Fig. 3) and progressed from the juxtamedullary cortex to the subcapsular cortex. FSG in SZ-induced diabetic APA hamsters was characterized by focal and segmental expansion of mesangial region due to an increase of matrix material and mesangial cells with lipid droplets and foam cells (Fig. 4).

In the morphometrical examination of renal glomeruli, as shown in Table 1, the area of WG of SZ-injected animals was significantly larger than that of controls both at 1MAI (Fig. 5) and at 3MAI (Fig. 5). The area of MR was significantly larger than that of controls at 1MAI (Fig. 6) and showed almost twice as much at 3MAI (Fig. 6). The area of CL was larger in SZ-injected animals than in controls at 1MAI (Fig. 7), even though not significant statistically, but it became similar between both groups at 3MAI (Fig. 7). Although not significant, the number of MC was larger in SZ-injected animals than in controls and decreased at 3MAI (Table 1) as suggested by histopathological examination. As to the thickness of BM, it was significantly larger in SZ-injected animals than in controls (Table 1).

## Discussion

Serum biochemical and urinalytic findings and histopathological and ultrastructural changes of renal glomeruli in SZ-injected APA hamsters were essentially the same as those observed in the previous report (Han et al., 1992b), and gave proof of a good reproducibility of this model system.

In the morphometrical examination of renal glomeruli, the area of WG of SZ-injected animals was significantly larger than that of controls both at 1MAI and at 3MAI. Similar tendency was detected in the area of MR. These data corresponded well with the above-mentioned clinical and histopathological findings of renal glomeruli, and enlarged glomeruli seemed to be due to persistent and marked polydipsia and polyuria observed in these animals. In diabetic patients the renal growth of early diabetes is accompanied by glomerular enlargement (Kroustrup et al., 1977). However, Wehner and Petri (1983) could not detect significant difference

in total glomerular surfaces between SZ-induced diabetic rats and nondiabetic ones even though there was significant increase of mesangial surfaces in diabetic rats.

The area of CL was larger in SZ-injected animals than in controls at 1MAI probably due to regional haemodynamic perturbation (Diamond and Karnovsky, 1988), but it became similar between 2 groups at 3MAI. This seems to be mainly due to an increase in the area of MR in the course of time, and progressive mesangial expansion could ultimately contribute to glomerular functional deterioration by restricting the glomerular capillary vasculature and its filtering surface (Mauer et al., 1984).

The number of MC was larger in SZ-injected animals than in controls as suggested by histopathological examination, and an increase in number of MC especially in the early stage may be a reaction against mesangial lipid deposition and seems to play an important role in the production of mesangial matrix material (Striker et al., 1984; Striker and Striker, 1985; Adler et al., 1986; Fries et al., 1989). The number of MC, however, decreased at 3MAI. These data are well coincident with those obtained from the experiments using SZ-diabetic rats (Al-Awadi and Al-Adnani, 1989).

As to the thickness of BM, it was significantly larger in SZ-injected animals than in controls as in the case of rats (Wehner and Petri, 1983), and an increase in the thickness of BM as well as an expansion of MR probably brought about proteinuria (Kanwar, 1984; Mauer et al., 1984; Ellis et al., 1989).

In conclusion, the present study clarified the reproducibility and quantitative characteristics of SZ-induced FSG in APA hamsters.

## References

- Adler S., Striker L.J., Striker G.E., Perkinson D.T., Hibbert J. and Couser W.G. (1986). Studies of progressive glomerular sclerosis in the rat. *Am. J. Pathol.* 123, 553-562.
- Al-Awadi F.M. and Al-Adnani M.S. (1989). Structural changes in glomeruli and proteinuria in streptozotocin diabetic rats. *Histol. Histopath.* 4, 129-135.
- Diamond J.R. and Karnovsky M.J. (1988). Focal and segmental glomerulosclerosis: Analogies to atherosclerosis. *Kidney Int.* 33, 917-924.
- Doi K., Yamamoto T., Isegawa N., Doi C. and Mitsuoka T. (1987). Age-related non-neoplastic lesions in the heart and kidneys of Syrian hamsters of the APA strain. *Lab. Anim.* 21, 241-248.
- Ellis E.N., Mauer S.M., Sutherland D.E.R. and Steffes M.W. (1989). Glomerular capillary morphology in normal humans. *Lab. Invest.* 60, 231-236.
- Fries J.W.U., Sandstorm D.J., Meyer T.W. and Rennke H.G. (1989). Glomerular hypertrophy and epithelial cell injury modulate progressive glomerulosclerosis in the rat. *Lab. Invest.* 60, 205-218.
- Han J.-S., Norimatsu M., Sugawara Y. and Doi K. (1990). Acute toxicity of streptozotocin in Syrian hamsters of the APA strain. *J. Toxicol. Pathol.* 3, 189-199.

*Renal morphometry of diabetic APA hamsters*

- Han J.-S., Norimatsu M., Itagaki S. and Doi K. (1992a). Early development of spontaneous glomerular lesion in Syrian hamsters of APA strain. *J. Vet. Med. Sci.* 54, 149-151.
- Han J.-S., Sugawara Y. and Doi K. (1992b). Rapid induction of glomerular lipidosis in APA hamsters by streptozotocin. *Int. J. Exp. Pathol.* 73, 75-84.
- Kanwar Y.S. (1984). Biophysiology of glomerular filtration and proteinuria. *Lab. Invest.* 51, 7-21.
- Kroustrup J.P., Gundersen H.J.G. and Sterby R. (1977). Glomerular size and structure in diabetes mellitus. III. Early enlargement of the capillary surface. *Diabetologia* 13, 207-210.
- Magil A.B. and Cohen A.H. (1989). Monocytes and focal glomerulosclerosis. *Lab. Invest* 61, 404-409.
- Mauer S.M., Steffes M.W., Ellis E.N., Sutherland D.E.R., Brown D.M. and Goetz F.C. (1984). Structural functional relationships in diabetic nephropathy. *Clin. Invest.* 74, 1143-1155.
- Mezza L.E., Quimby F.W., Durham S.K. and Lewis R.M. (1984). Characterization of spontaneous amyloidosis of Syrian hamsters using the potassium permanganate method. *Lab. Anim. Sci.* 34, 376-380.
- Striker G. and Striker L.J. (1985). Glomerular cell culture. *Lab. Invest.* 53, 122-131.
- Striker L.M.M., Killer P.D., Chi E. and Striker G.E. (1984). The composition of glomerulosclerosis: I. Studies in focal sclerosis, crescentic glomerulonephritis, and membranoproliferative glomerulonephritis. *Lab. Invest.* 51, 181-192.
- Tajima Y. (1968). Species and strains of experimental animals developed in Japan (in Japanese with English summary). *Exp. Anim.* 17, 27-39.
- Wehner H. and Petri M. (1983). Glomerular alterations in experimental diabetes of the rat. *Pathol. Res. Pract.* 176, 145-157.

Accepted May 2, 1992