

Expression of HBsAg and HBcAg in liver tissue: correlation with disease activity

Lydia Nakopoulou¹, N. Adraskelas¹, K. Stefanaki¹, D. Zacharoulis¹ and St. Hadziyannis²

¹Department of Pathology, Medical School, University of Athens and ²Academic Department of Medicine, Hippokrateo General Hospital, Athens, Greece

Summary. The patterns of Hepatitis B surface antigen (HBsAg) and Hepatitis B core antigen (HBcAg) expression were studied in liver biopsies taken from 41 patients with chronic HBV disease. Immunohistochemical methods were used on deparaffinized sections for the identification of HBsAg and HBcAg in liver tissue.

Twenty-one of the 41 cases (51.2%) were classified as inactive liver disease and 20 (48.8%) as active liver disease. In liver biopsies with inactive disease, HBsAg demonstrated varying types of cytoplasmic expression in a rather high number of hepatocytes distributed mainly in clusters, while HBcAg was rarely expressed in liver nuclei. On the other hand, in liver biopsies with active disease HBsAg was characterized by a diffuse cytoplasmic expression in a few discrete hepatocytes, while HBcAg was expressed in the nuclei of the hepatocytes in 70% of the cases and in half of the positive cases it was also detected in the cytoplasm.

In conclusion, HBsAg expression in a few scattered hepatocytes correlates with active liver disease and positive HBcAg, while varying HBsAg cytoplasmic expression in a rather high number of clustered hepatocytes is related to chronic inactive liver disease and negative expression of HBcAg.

Key words: Hepatitis B, Chronic liver disease, Immunostaining

Introduction

In 1972, Hadziyannis et al. were the first to describe the ground-glass hepatocyte, which is considered a useful histological marker for HBsAg carriage or HBsAg-carrier state (Borchard and Gussmann, 1979; Hsu et al., 1983a).

Since then, special histochemical stains, mainly

Orcein Shikata and immunohistochemical methods using antibodies to HBsAg have been applied to liver biopsies for the identification of HBsAg-positive hepatocytes (Hadziyannis et al., 1972; Shikata et al., 1974; Hsu et al., 1983a,b). Immunohistological investigations have indicated different patterns of HBsAg cytoplasmic expression (Borchard et al., 1979). Recent studies have shown that group distribution of HBsAg cytoplasmic-positive hepatocytes is associated with inactive liver disease (Hsu et al., 1988), whereas discrete distribution of HBsAg cytoplasmic-positive hepatocytes and membrane HBsAg expression are related to virus replication (Ray et al., 1976). Hepatocyte HBcAg expression is related to HBV replication, which is divided into two phases.

In the first phase, nuclear HBcAg expression is associated with viremia but very rarely with active disease, reflecting active virus replication with immune tolerance, while in the second phase cytoplasmic HBcAg expression correlates with viremia and active disease, indicating active virus replication and enhanced immune response (Chu et al., 1985; Hsu et al., 1987).

We have studied the immunohistochemical expression of HBsAg and HBcAg in liver biopsies taken from patients with chronic HBV disease and their relation to the natural course of hepatitis B virus infection.

Materials and methods

Forty-one liver needle biopsies taken from HBsAg sero-positive patients aged 19 to 65 years (mean age 42 years) were studied.

Sections, 5 µm thick, were cut from formalin-fixed, paraffin-embedded tissue blocks and stained with hematoxylin-eosin, trichrome-Masson, PAS-diacetate, Gomori-Silver and Orcein-Shikata.

The immunohistochemical peroxidase-antiperoxidase (PAP) method (Sternberg, 1979) was applied to other 5 µm paraffin sections in order to detect HBsAg and HBcAg using polyclonal antisera. HBsAg was also detected with a monoclonal antibody using the avidin-

*HBsAg and HBcAg in liver***Table 1.** Distribution pattern Hepatocyte HBsAg pattern and liver pathology.

Liver pathology	No of biopsies	Liver HBsAg patterns			
		A	B	C	D
INACTIVE LIVER DISEASE	21	1	2	12	6
Non-specific changes	8	—	—	5	3
Chronic persistent hepatitis	8	—	—	6	2
Inactive cirrhosis	5	1	2	1	1
ACTIVE LIVER DISEASE	28	3	16	1	—
Chronic lobular hepatitis	4	1	2	1	—
Chronic active hepatitis	11	2	9	—	—
Active cirrhosis	5	—	5	—	—

Table 2. Correlation of expression patterns of tissue HBsAg and HBcAg with HBeAg/anti-HBe and histological diagnosis.

Liver HBsAg pattern	No of biopsies	CHRONIC HBe/ Anti-HBe	INACTIVE Expression of Cytoplasm.	HBcAg Nuclei	No of biopsies	CHRONIC HBe/ Anti-HBe	ACTIVE Expression of Cytoplasm.	HBcAg Nuclei
A	1	0/2	—	—	3	1/3	—	2
B	2	0/2	—	1	16	2/16	10	10
C	12	0/12	—	2	1	0/1	—	—
D	6	0/6	—	1	—	—	—	—

biotin-complex (ABC) method (Hsu et al., 1981). Following deparaffinization and rehydration, sections were incubated in 0.3% methanolic peroxide to block endogenous peroxidase activity.

In order to detect HBsAg and HBcAg with polyclonal anti-bodies, sections were incubated with the following antisera:

- 1) Normal swine serum 1 : 10 for 20 min.
- 2) Special rabbit anti-human HBsAg (Dakopatt's kit Denmark) and HBcAg sera (Dakopatt's Denmark) diluted 1 : 80 to 1 : 100 for 60 min.
- 3) Swine anti-rabbit serum (Dakopatt's Denmark) 1 : 40 for 30 min.
- 4) Peroxidase-anti peroxidase complex 1 : 60 for 30 min (Dakopatt's Denmark).

The avidin-biotin-complex method (Dakopatt's ABC Kit, Denmark) was used for the detection of HBsAg with a monoclonal antibody (kindly provided by Prof. Hadziyannis). Sections were rinsed with PBS at pH 7.4 between reaction steps.

In all cases, antibody localization was performed with the diaminobenzidine (DAB) (Sigma Chem. Co.) reaction (6 mg DAB in 10 ml PBS at pH 7.4 to which 0.025 ml 30% H₂O₂ was added prior to use). Slides were well rinsed with running tap water, counterstained with Mayer's hematoxylin, dehydrated in alcohol and mounted.

For each test, negative control studies were carried out

in which normal saline was used instead of primary anti-serum. Sections taken from known HBsAg- and HBcAg-positive cases were stained for use as positive controls.

The histological lesions were classified according to standard criteria (International group, 1977).

To facilitate disease correlation with HBsAg and HBcAg expression, the histological lesions were divided into two groups: 1) chronic inactive; and 2) chronic active liver disease. The chronic inactive liver disease group included: normal liver histology; non-specific lesions; chronic persistent hepatitis; and inactive cirrhosis. The chronic active group included: chronic lobular hepatitis; chronic active hepatitis; and active cirrhosis.

The cytoplasmic pattern of HBsAg was classified according to Borchard and Gussman (1979) as: diffuse; inclusion-like; globular; marginal; and membrane.

HBsAg expression was also classified into four categories according to the criteria of Hsu et al. (1988) regarding grouped and discrete HBsAg-positive hepatocyte distribution as follows: pattern A is characterized by diffuse and intense cytoplasmic HBsAg in discrete hepatocytes; pattern B has diffuse but moderate or faint cytoplasmic HBsAg as in pattern B, but distribution in clusters of hepatocytes; pattern D includes globular, spotty or marginal cytoplasmic HBsAg expression in clustering distribution (Figs. 1 - 5).




Fig. 1. Pattern C. Cytoplasmic HBsAg staining of many hepatocytes in clustering distribution (arrows). (ABC x 125).

Marginal HBsAg is characterized by a marginal band of HBsAg beneath the cell membranes. Although in our material various patterns of HBsAg expression coexisted, each case was classified according to the predominant pattern.

The membrane expression of HBsAg was not described separately, as it was always associated with cytoplasmic HBsAg, especially patterns A and B. Enzyme immunoassays (Abbott Lab, North Chicago, Ill) were used for the detection of HBsAg, anti-HBs, HBeAg, anti-HBe and anti-HBc.

Results

Table 1 demonstrates the classification of our material according to histological lesion type. Twenty-one out of 41 cases were classified as chronic inactive disease and 20 cases as chronic active disease.

Chronic inactive liver disease was predominantly associated with pattern C and less commonly with pattern D, with the exception of two cases of inactive

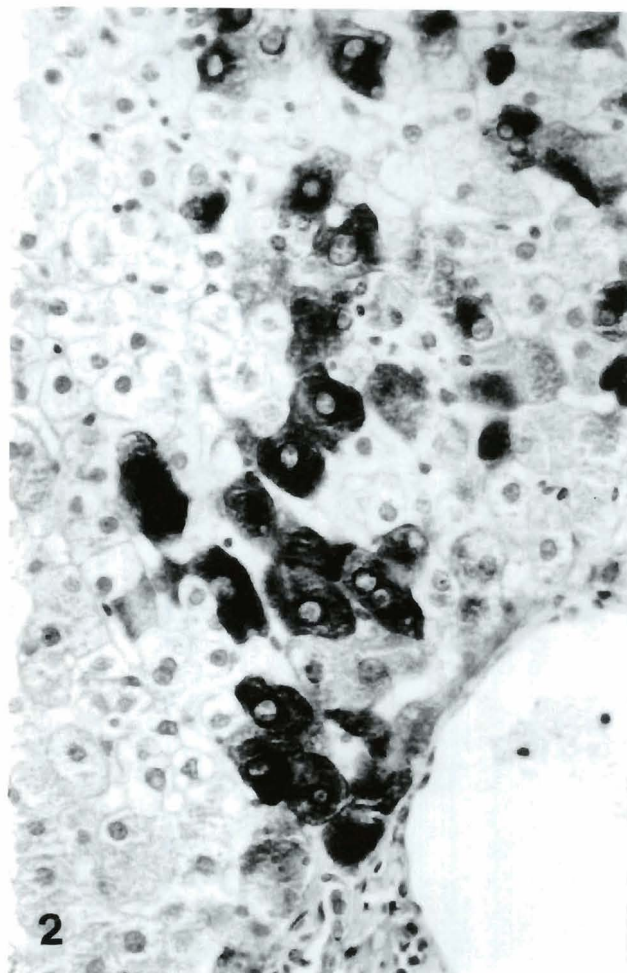


Fig. 2. High-power photomicrograph of figure 1. Many hepatocytes with diffuse and intense cytoplasmic HBsAg expression (ABC x 500).

cirrhosis which demonstrated patterns A and B respectively. The number of marginal HBsAg-positive hepatocytes (pattern D) was higher than that of other types.

Chronic active liver disease was more commonly associated with pattern B (diffuse but moderate cytoplasmic staining in discrete hepatocytes), while three cases demonstrated pattern A. The number of HBsAg-positive hepatocytes was small in the chronic active liver disease group. There was no important expression-related difference in using a monoclonal and polyclonal antibody to HBsAg, but the monoclonal antibody showed a more intense staining and confirmed the HBsAg detection in dubious cases.

Table 2 demonstrates the correlation between HBsAg expression and HBcAg nuclear and/or cytoplasmic expression. Our results show that HBcAg was rarely expressed in chronic inactive liver disease, being positive in the nuclei of only four cases.

In chronic active liver disease, HBcAg had nuclear expression in 70% of the cases (Fig. 6), while in half of

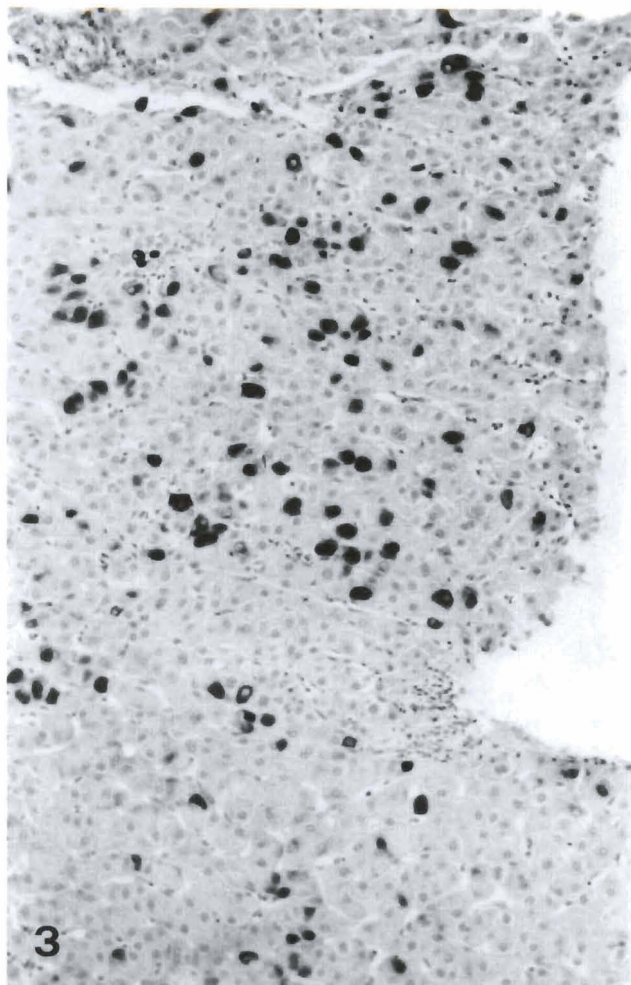


Fig. 3. Globular HBsAg shows in discrete hepatocytes (ABC x 400)

them it showed cytoplasmic expression as well. The number of pattern C or pattern D HBsAg-positive hepatocytes was higher, especially when HBsAg demonstrated marginal staining in a cluster distribution.

Positive serum HBeAg is conventionally regarded as a viremia marker. In this series, serum HBeAg was positive in only three cases of chronic persistent hepatitis with signs of virus replication, which also expressed HBcAg in liver tissue.

All the other cases included in the present study were HBeAg seronegative and anti-HBe seropositive (Table 2).

Discussion

Chronic HBV infection may result in either a viremic or a nonviremic course. Patients with virus replication are seropositive for hepatitis e antigen (HBeAg) and hepatitis B DNA (HBV DNA) (Boino et al., 1981; Hadziyannis, 1982). Furthermore, the reactivation of HBV may also be demonstrated immunohistochemically (Chu et al., 1985; Tassopoulos et al., 1988) by the detection of HBcAg in the nuclei and cytoplasm of

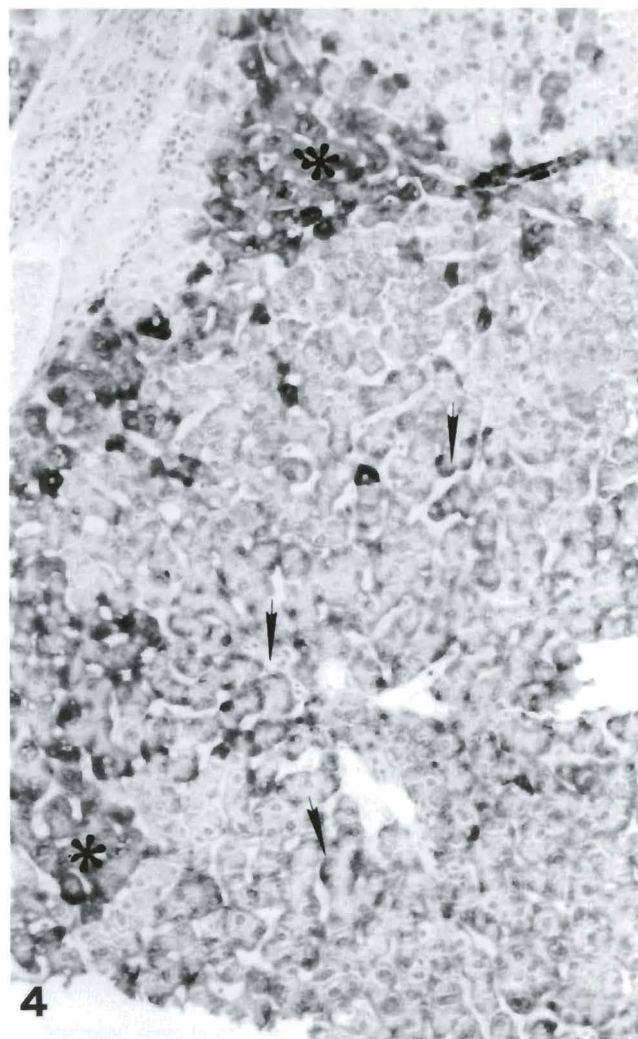


Fig. 4. A large group of hepatocytes show faint marginal accumulation of HBsAg beneath the cell membrane (arrows). A small group of hepatocytes (asterisk) with diffuse but moderately intense HBsAg staining (ABC x 400)

hepatocytes as well of HBV DNA through in situ hybridization (Tassopoulos et al., 1986). In contrast, the non-viremic state is characterized by seroconversion from HBeAg to anti-HBe, disappearance of HBV DNA from the serum and absence of HBcAg and HBV DNA in liver tissue (Hadziyannis, 1982; Hoofnagle, 1983).

Recent studies have demonstrated that hepatocytes HBsAg expression patterns closely correlate with the viremic and non-viremic phases of HBV-infection (Hadziyannis et al., 1983; Tur-Kaspa et al., 1986; Hsu et al., 1988).

In our study, chronic inactive liver disease was associated with patterns C and D HBsAg cytoplasmic expression in hepatocytes with group distribution, while HBcAg was rarely detected in the nuclei of hepatocytes. Patients with chronic inactive liver disease and HBcAg in liver tissue are probably in an early phase of active virus replication, which is characterized by mild histological

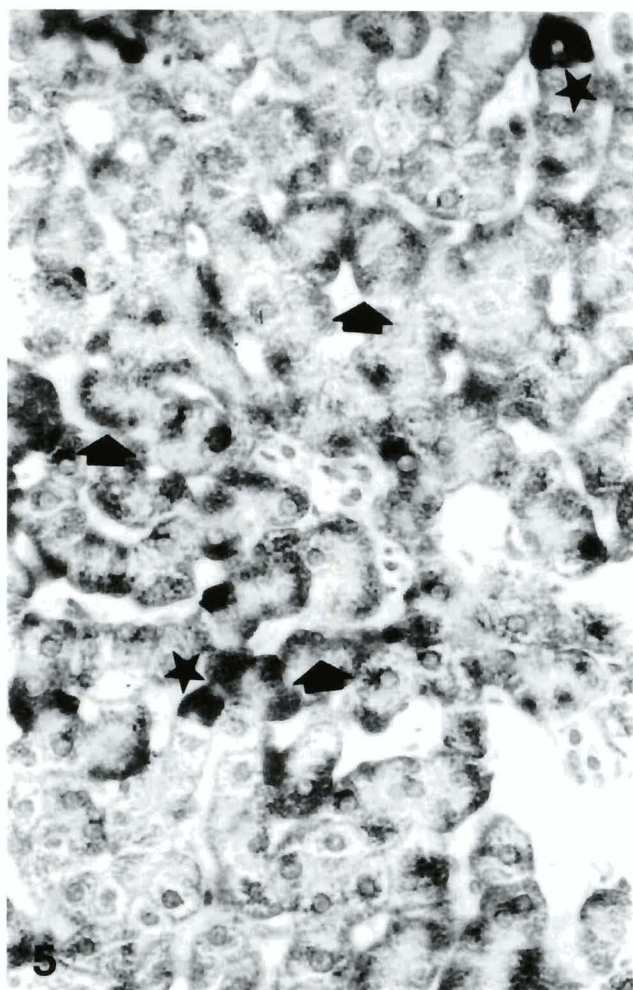


Fig. 5. High-power photomicrograph of figure 4. Marginal cytoplasmic HBsAg expression beneath the cell membrane (arrows). Some discrete hepatocytes show diffuse and intense HBsAg (asterisks) (ABC x 500)

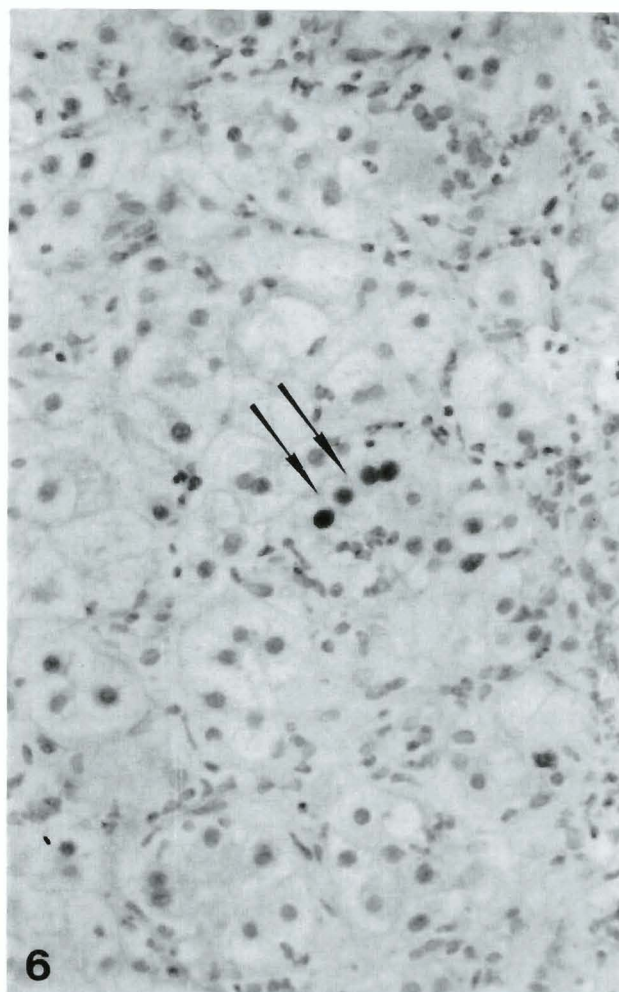


Fig. 6. Some hepatocytes show presence of nuclear HBcAg expression (arrows) associated with evident necro-inflammatory reaction (PAP x 500)

lesions. Moreover, in some patients after the first phase of active HBV replication, an intermediate or atypical replication of HBV may persist for a long time despite the anti-HBe seropositivity (Tassopoulos et al., 1988; Carman et al., 1989).

Immunohistological observations (Hadziyannis et al., 1983; Shafritz and Hadziyannis, 1984) have shown that «ground-glass hepatocytes» in group distribution have been found in anti-HBe seropositive patients with an absence of HBcAg in liver tissue and HBV DNA in the serum. Hsu et al. (1988) and Naoumov et al. (1990) agree with the mentioned findings and have concluded that the characteristic group distribution of marginal HBsAg is an important histological marker of inactive virus replication and is closely associated with viral integration.

In our group of inactive liver disease, the marginal HBsAg type was detected in a small number of cases, while pattern C was more commonly demonstrated. In our case showing the marginal HBsAg pattern, the

number of marginal HBsAg hepatocytes in group distribution was quite high. Moreover, Blum et al. (1984) and Chen et al. (1986) have observed low titers of HBsAg in the serum of their HBeAg-negative carriers. These findings are difficult to explain and probably suggest that hepatocytes with marginal accumulation of HBsAg may have a defective secretory mechanism and less efficient HBsAg secretion. The twenty cases with chronic active liver disease were mainly associated with pattern B and less commonly with pattern A HBsAg expression in discrete hepatocytes. In 70% of these cases HBcAg was detected in the nuclei of the hepatocytes, while in half of the positive cases it was also demonstrated in the cytoplasm.

As observed by other researchers (Vento et al., 1985; Pignatelli et al., 1987) these results are associated with active virus replication and enhanced immune response. Recently, Naoumov et al. (1990) have suggested that cytoplasmic hepatitis B core antigen is the target for immune-system-mediated cytolysis of hepatocytes and is

associated with active liver disease.

Hsu et al. (1988) have also correlated the HBsAg expression patterns with patient's age, as they have noticed that patterns A and B occur in young adults, and patterns C and D in older patients. In our material no age-related difference in HBsAg and HBcAg immunohistochemical expression was observed.

It is of particular interest that 17/20 (90%) cases with chronic active liver disease were anti-HBe seropositive and HBeAg seronegative despite the HBcAg expression in the nuclei and cytoplasm of the hepatocytes. These findings are in agreement with previously reported data from Greece and Italy (Hadziyannis et al., 1981; Bonino et al., 1986), showing that the HBeAg/anti-HBe system lacks diagnostic significance in the evaluation of active replication of HBV in chronic liver disease as new molecular techniques have revealed HBV-DNA in some anti-HBe-positive patients (Karayiannis et al., 1985). Moreover, the identification of chronic active hepatitis and cirrhosis 12/18 HBeAg-negative and HBcAg-positive cases confirmed previous data that associated continued viral replication with chronic active liver disease (Hadziyannis et al., 1981; Bonino et al., 1986).

A recent Greek-English study (Carman et al., 1989) concerning HBeAg-negative and anti-HBe-positive patients with rapidly progressive liver disease suggests that the absence of HBeAg production may be due to a change in the nucleotide sequence of the pre-core region of the genome.

In conclusion, the diffuse cytoplasmic HBsAg expression in discrete hepatocytes was related to chronic active disease and HBcAg detection in liver tissue despite HBeAg being seronegative. Moreover, the number of HBsAg-positive hepatocytes was small.

In contrast, the spotty and marginal cytoplasmic HBsAg expression in hepatocytes with group distribution was associated with chronic inactive disease and absence of HBcAg from liver tissue. In the latter group, the number of HBsAg-positive hepatocytes, especially the marginal type, was quite high, suggesting that further investigation is indicated.

References

- Blum H.E., Figus A. and Bhartnagar P.K. (1984). Immunochemistry of hepatitis B surface antigen and molecular pathogenesis of chronic liver disease. In: Chisari F.V. ed. *Advances in hepatitis research*. 69 - 79. New York. Masson Publishing Inc.
- Bonino F., Hoyer B., Nelson J., Engle R., Verme G. and Gerin J.L. (1981). Hepatitis B virus DNA in the sera of HBsAg carriers: a marker of active hepatitis B virus replication in the liver. *Hepatology* 1, 386-391.
- Bonino F., Rosina F., Rizzetto M., Rizzi R., Chiaberge E. and Tardanico R. (1986). Chronic hepatitis in HBsAg carriers with serum HBV-DNA and anti-HBe. *Gastroenterology* 90, 1268-1273.
- Borchard P. and Gussman V. (1979). Detection of HBsAg containing cells in liver biopsies by different stains and classification of positively reacting ground-glass hepatocytes. *Virchows Arch.* 384, 245-261.
- Carman W.F., Jacyna M.R., Hadziyannis S., Karayiannis P., McGarvey M.J., Makris A. and Thomas H.C. (1989). Mutation preventing formation of hepatitis e antigen in patients with chronic hepatitis B infection. *Lancet* 9, 588-591.
- Chen S.D., Lai M.Y. and Lee S.C. (1986). Serum HBsAg, HBeAg, anti-HBe and hepatitis B viral DNA in asymptomatic carriers in Taiwan. *J. Med. Virol.* 19, 87-94.
- Chu C.M., Karayiannis P., Fowler M.J., Monjardino J., Liaw Y.f. and Thomas H.C. (1985). Natural history of chronic hepatitis B virus infection in Taiwan: study of hepatitis B virus DNA in serum. *Hepatology* 5, 431-434.
- Hadziyannis S., Vissoulis C., Moussouros A. and Afroudakis A. (1972). Cytoplasmic localization of Australia-antigen in the liver. *Lancet* 1, 976-988.
- Hadziyannis S.J., Lieberman H.M., Karvountzis G.G. and Shafritz D.A. (1981). Analysis of liver disease, nuclear HBcAg, viral replication and hepatitis B virus DNA in liver and serum of HBeAg vs anti-HBe positive carriers of hepatitis B virus. *Hepatology* 3, 656-662.
- Hadziyannis S.J. (1982). Anti-HBe positive chronic active hepatitis. In: Szmuness W., Alter H.J., Maynard J.E. (eds). *Viral hepatitis*. 683:1981 International Symposium, Philadelphia, Franklin Institute Pres.
- Hadziyannis S., Lieberman H.M., Karvountzis G.G. and Shafritz D.A. (1983). Analysis of liver disease, nuclear HBcAg, viral replication and hepatitis B virus DNA in liver and serum of HBeAg vs anti-HBe positive carriers of hepatitis B virus. *Hepatology* 3, 656-662.
- Hoofnagle J.H. (1983). Chronic type B hepatitis. *Gastroenterology* 83, 422-424.
- Hsu S.M., Raine L. and Fanger H. (1981). Use of avidin-biotin peroxidase complex (ABC) in immunoperoxidase techniques: A comparison between ABC and unlabelled antibody (PAP) procedures. *J. Histochem. Cytochem.* 29, 577-580.
- Hsu H.C., Kao M.T. and Lin Y.H. (1983a). Detection of hepatitis B surface antigen in liver tissue: a comparative study of the sensitivity of histochemical and immunoperoxidase techniques. *J. Formosan Med. Assoc.* 82, 657-666.
- Hsu H.C., Lin W.S.J. and Tsai M.J. (1983b). Hepatitis B surface antigen and hepatocellular carcinoma in Taiwan: with special reference to types and localization of HBsAg in the tumor cells. *Cancer* 52, 1825-1832.
- Hsu H.C., Su I.J. and Lai M.J. (1987). Biologic and prognostic significance of hepatitis B core antigen expression in the natural course of chronic hepatitis B virus infection. *J. Hepatology* 5, 45-50.
- Hsu G.C., Lai M.Y., Su I.J., Chen D.S., Chang M.H., Yang P.M. and Hsieh H.C. (1988). Correlation of hepatocyte HBsAg expression with virus replications and liver pathology. *Hepatology* 8, 749-754.
- International Group (1977). Acute and chronic hepatitis revisited. *Lancet* 2, 914-919.
- Karayiannis P., Fowler M.J.F., Lok A.S.F., Greenfield C., Monjardino J. and Thomas H.C. (1985). Detection of serum HBV-DNA by molecular hybridization: correlation with HBeAg/anti-HBe status, racial origin, liver histology and hepatocellular carcinoma. *J. Hepatol.* 1, 99-106.
- Naoumov N.V., Portman B.C., Tedder R.S., Ferns B., Eddleston A., Alexander C. and Williams R. (1990). Detection of hepatitis B virus antigens in liver tissue. A relation to viral replication and histology in chronic hepatitis B infection. *Gastroenterology* 99, 1248-1253.
- Pignatelli M., Waters J., Lever A.M.L., Iwarson S., Gerety R. and Thoms N.C. (1987). Cytotoxic T cell responses to the nucleocapsid proteins of HBV in chronic hepatitis B. *J. Hepatol.* 4, 15-21.
- Ray M.B., Desmet V.S. and Bradburne A.F. (1976). Differential distribution of hepatitis B surface antigen and hepatitis B core antigen

HBsAg and HBcAg in liver

- in the liver of hepatitis B patients. *Gastroenterology* 71, 462-469.
- Shafritz D.A. and Hadziyannis S.J. (1984). Hepatitis B virus DNA in liver and serum, viral antigens and antibodies, virus replication and liver disease activity in patients with persistent hepatitis B virus infection. In, Chisari F.V. Ed. *Advances in hepatitis research*. 80 - 90. New York, Masson Publishing Inc.
- Shikata T., Uzaewa T., Yoshimura N., Akastuka T. and Yamazaki S. (1974). Staining methods of Australia-antigen in paraffin section-detection of cytoplasmic inclusion bodies. *Jap. J. Exp. Med.* 44, 25-36.
- Sternberger I.A. (1979). *Immunohistochemistry*. Second edition. 104-160. John White and Sons, New York.
- Tassopoulos N., Papaioannou G., Roumeliotou-Karayannis A., Ticehurst J., Feinstone S.M. and Purcell R.H. (1986). Search for hepatitis B virus DNA in sera from patients with acute type B or non-A, non-B hepatitis. *J. Hepatol.* 2, 410-418.
- Tassopoulos N., Papaioannou C., Kyriakis P. and Hadziyannis S.J. (1988). Liver expression of hepatitis B core antigen in chronic Hepatitis B virus (HBV) infection: a marker for active replication of HBV and antiviral treatment. *Hellenic Journal of Gastroenterology* 1, 27-31.
- Tur-Kaspa R., Burk R.D., Lieberman H.H. and Shafritz D.A. (1986). Hepatitis B virus gene expression in reaction to virus replication and HBV-DNA integration. *J. Hepatol.* 3 25-33.
- Vento S., Hegarty J.E. and Alberti A. (1985). T lymphocyte sensitization of HBcAg and T cell - mediated unresponsiveness to HBsAg in hepatitis B virus - related chronic liver disease. *Hepatology* 5, 129-197.

Accepted April 10, 1992