

## Microscopic correlates of adaptive cytoprotection in an ethanol injury model

Karmen L. Schmidt<sup>1</sup>, Gregory S. Smith<sup>2</sup> and Thomas A. Miller<sup>2</sup>

<sup>1</sup>Department of Pathology and Laboratory Medicine and <sup>2</sup>Department of Surgery, The University of Texas Medical School, Houston, Texas, USA

**Summary.** The present study histologically investigated the efficacy of pretreating rat gastric mucosa with the mild irritants, 10% and 25% ethanol (EtOH), against the known damaging effects of 100% EtOH. Fasted rats received 1 ml of either water, 10% EtOH, or 25% EtOH by orogastric intubation. Fifteen minutes later, a portion of these animals was sacrificed and tissue samples of the oxyntic region of the stomach were excised and processed for quantitative histologic analysis. Remaining animals received a 1 ml oral bolus of the necrotizing agent, 100% EtOH. Five minutes later, these animals were sacrificed and tissues were prepared in a like manner. In a separate series of experiments, the aforementioned protocols were repeated, except that all animals received the prostaglandin synthetase inhibitor, indomethacin (5.0 mg/kg intraperitoneally), 30 min before administration of the mild irritant. Microscopically, the administration of water or 10% EtOH alone caused a small and comparable amount of superficial injury to the gastric mucosa. Moreover, both substances failed to induce protection in stomachs subsequently exposed to 100% EtOH. Indomethacin pretreatment did not significantly alter any of these findings. In marked contrast, 25% EtOH alone elicited a substantial degree of superficial damage to the gastric mucosa. Nevertheless it significantly reduced the depth of injury in animals subsequently challenged by 100% EtOH. Indomethacin failed to aggravate the effects of 25% EtOH alone, but partially inhibited the protective effect of this mild irritant against 100% EtOH induced damage. Our findings indicate that adaptive cytoprotection is a real phenomenon that can be demonstrated microscopically. Such protection is limited primarily to the deep mucosal layers (i.e. gastric glands), appears in part to be prostaglandin mediated and seems to require the generation of moderate surface cell damage (as

occurred with 25% EtOH, but not 10% EtOH) to induce its initiation.

**Key words:** Rat, Ethanol, Gastric mucosa, Adaptive cytoprotection, Indomethacin, Prostaglandin, Mild irritants

---

### Introduction

In 1978 Robert and associates reported the curious observation that the known damaging effect of various noxious agents, such as 100% ethanol, when topically applied to the gastric epithelium could be prevented or markedly attenuated if the mucosa was previously exposed to a low concentration of the same agent or even differing agents, such substances being termed «mild irritants» (Robert et al., 1978). They called this phenomenon «adaptive cytoprotection» and, because it could be inhibited by indomethacin, suggested that it might be mediated through endogenous prostaglandins (PGs) (Robert et al., 1978; Chaudhury and Robert, 1980). Subsequent studies have demonstrated that a number of mild irritants actually stimulate PG synthesis, further implicating a role for PGs (Danon and Assouline, 1979; Konturek et al., 1982; Robert et al., 1983).

Unfortunately, the majority of studies that have assessed the existence of adaptive cytoprotection under various experimental circumstances have relied almost entirely on macroscopic injury and consequently whether a given «mild irritant» is indeed protective. Recent studies in assessing the cytoprotective properties of PGs when administered exogenously have clearly underscored the limitations of determining gastric injury grossly and have emphasized the importance of careful examination using histologic techniques of the «presumed» protected epithelium (Lacy and Ito, 1982; Guth et al., 1984; Schmidt et al., 1985, 1986). Except for a few semi-quantitative published observations, no systematic study has

---

Offprint requests to: Thomas A. Miller, M.D., Department of Surgery, The University of Texas Medical School, 6431 Fannin, MSB 4.266, Houston, Texas 77030, USA

been undertaken to carefully examine the microscopic correlates of adaptive cytoprotection. Accordingly, the present study was conceived to address this deficiency using a standard ethanol injury model involving the rat stomach. An abstract of this work was published earlier (Smith et al., 1987).

### **Materials and methods**

Female Sprague Dawley rats weighing approximately 200 grams were used in all studies. The animals were fasted for 24 hrs in wide wire mesh cages to prevent coprophagia, but were allowed free access to water. On the day of experimentation, they were randomized into various groups, and received 1 ml of either distilled water, or the mild irritants 10% ethanol (EtOH) or 25% EtOH (vol/vol) by orogastric intubation. Fifteen minutes later, a portion of the animals from each group were sacrificed and tissue samples from the oxyntic gland region of the stomach were removed for histologic evaluation. All remaining animals received 1 ml of the necrotizing agent, 100% EtOH, and then were sacrificed five minutes later, again retrieving tissue samples of the gastric corpus for microscopy. The 5 min sacrifice time was chosen because previous studies have shown that within 5 min following 100% EtOH exposure, consistent, reproducible injury occurs in the rat stomach without any superimposed restitution of denuded epithelium (Schmidt et al., 1985, 1986). In a separate series of experiments, the above protocol was repeated with the exception that these additional animals were pretreated with indomethacin (5.0 mg/kg intraperitoneally) 30 minutes prior to the administration of the initial instillate. This dose of indomethacin was employed because it has been shown to potently and consistently inhibit endogenous PG synthesis in the stomach (Fitzpatrick and Wynalda, 1976; Wallace, 1988).

For all morphologic studies, animals were quickly anesthetized with ether and the abdominal cavity was opened via a midline laparotomy. The pylorus and gastroesophageal junctions were ligated using 3-0 silk ligatures and 2.0 ml of half-strength Karnovsky's fixative (Karnovsky, 1965) were then injected through a small stab wound made in the forestomach. The entire stomach was then excised and immediately immersed in the same fixative for a period of at least 24 hours. After fixation, the stomach was opened along the lesser curvature, pinned flat and examined for the presence of macroscopic damage. A lesion index was tabulated for each stomach by estimating the total percentage of macroscopic damage to the glandular mucosa. As described in an earlier publication (Schmidt et al., 1985), two samples (2 mm × 10 mm) of the oxyntic glandular portion were then excised at a region just below the limiting ridge along the greater curvature of each stomach. All tissue blocks were removed at right angles to the long axis of the stomach. From these blocks, hematoxylin and eosin stained, paraffin embedded sections were prepared using conventional techniques. All glass slides were coded in such a way that the observer (K.L.S.) was unfamiliar with the experimental

protocol. Only after examination and quantitation had been completed were the specimens decoded. Upon retrieval of stomachs for macroscopic and microscopic assessment of injury, animals were killed by cervical dislocation.

Using a graded micrometer eyepiece mounted on a Zeiss III photomicroscope (Carl Zeiss, Inc., Thornwood, N.Y.), tissue sections (4 μm) from each of the two tissue blocks from each stomach were evaluated microscopically. The overall length of each tissue section was measured and the corresponding length of each category of damage along this surface was determined using a scoring system published previously (Schmidt et al., 1985). The criteria for damage based on the extent of injury from the luminal surface to the muscularis mucosa are summarized in Table 1. Surface mucous cells were considered to be injured if they exhibited one or more of the following characteristics: marked cytoplasmic vacuolization, intracellular edema, nuclear pyknosis, or nuclear edema with related chromatin margination. Lucent cytoplasm and pyknotic nuclei were indicative of parietal cell damage. Hyperemic vessels, hemorrhage, and gland dilation were further indicators of injury.

Measurements from each sample pair of the length of surface mucosa injured in each category (Types 1-4 or normal) were averaged to obtain a mean value for each test stomach. All values were reported as mean percentage ± SEM. Differences between the various experimental groups were evaluated statistically using one way analysis of variance. A P value of < 0.05 was deemed to be significant.

### **Results**

#### *Macroscopic findings*

##### Non-Indomethacin Studies

Macroscopic results for all experimental groups are summarized in Table 2. Grossly visible evidence of mucosal injury was virtually nonexistent in stomachs that received water, 10% EtOH, or 25% EtOH alone (< 1% of the glandular mucosa). The slight damage that was present consisted mainly of small petechiae and minute punctate lesions.

Animals pretreated with water or 10% EtOH followed by 100% EtOH, however, showed extensive macroscopic damage. In water pretreated animals exposed to 100% EtOH, 33% of the gastric mucosa showed obvious damage at the 5 minute sacrifice time. Similarly, in animals pretreated with 10% EtOH followed by 100% EtOH, 31% of the gastric mucosa showed signs of overt damage at sacrifice. Such damage was characterized by the presence of hemorrhagic lesions in the oxyntic mucosa with sparing of the nonsecreting forestomach and the antrum. These lesions consisted mainly of long red bands ranging from 2 to 10 mm in length and from 1 to 4 mm in width generally running parallel to the long axis of the stomach. In contrast to these findings, animals pretreated with 25% EtOH and subsequently exposed to

**Table 1.** Criteria for depth of injury\*

Depth of Damage	Kind of Damage
Type 0	None
Type 1	Interfoveolar surface mucous cells (SMCs) only.
Type 2	Interfoveolar SMCs plus some or all gastric pit SMCs
Type 3	interfoveolar and gastric pit SMCs and up to 1/3 depth of gastric glands
Type 4	Interfoveolar and gastric pit SMCs and more than 1/3 depth of gastric glands

\*Scoring system previously published (Schmidt et al., 1985).

**Table 2.** Percent damage of glandular gastric mucosa based on macroscopic evaluation

Protocol	Without Indomethacin Pretreatment	With Indomethacin <sup>c</sup> Pretreatment
H <sub>2</sub> O <sup>a</sup>	0.2 ± 0.2 n = 6	0.0 ± 0.0* n = 6
10% EtOH <sup>a</sup>	0.3 ± 0.3 n = 6	0.0 ± 0.0* n = 6
25% EtOH <sup>a</sup>	0.6 ± 0.3 n = 7	1.4 ± 0.6* n = 5
H <sub>2</sub> O - 100% EtOH <sup>b</sup>	33.0 ± 4.8 n = 10	46.7 ± 3.1* n = 6
10% EtOH - 100% EtOH <sup>b</sup>	31.4 ± 7.1 n = 7	45.8 ± 2.4* n = 6
25% EtOH - 100% EtOH <sup>b</sup>	2.3 ± 0.8** n = 10	23.0 ± 3.2*** n = 6

H<sub>2</sub>O = Oral Water; EtOH = Oral Ethanol

a Animals sacrificed 15 minutes after instillation of H<sub>2</sub>O or 10% or 25% EtOH

b Animals sacrificed 5 minutes after instillation of 100% EtOH

c Indomethacin (5 mg/kg intraperitoneally) 30 minutes before administration of initial test solution

\* Not significant compared with corresponding studies without indomethacin pretreatment

\*\* p < 0.05 compared with H<sub>2</sub>O or 10% EtOH - 100% EtOH without indomethacin pretreatment

\*\*\*p < 0.05 compared with 25%-100% EtOH without indomethacin pretreatment and H<sub>2</sub>O or 10% EtOH - 100% EtOH with indomethacin pretreatment

100% EtOH showed considerably less overt damage to the gastric mucosa, on the average involving only 2% of the gastric glandular mucosa (see Table 2).

#### Indomethacin Studies

Intraperitoneal indomethacin (INDO) administration had no adverse effects upon stomachs exposed to water or 10% EtOH alone when examined macroscopically. In two animals pretreated with INDO and then exposed to 25% EtOH alone several diffuse petechiae and one or two small punctate lesions were noted, but as a group the extent of damage was not significantly different from those animals receiving water or 10% EtOH (Table 2) with or without INDO pretreatment.

Compared with corresponding animals not receiving INDO, pretreatment with this agent exacerbated the amount of grossly visual damage in all three experimental groups challenged by 100% EtOH (Table 2). INDO-treated animals that received water followed by 100% EtOH exhibited grossly visible evidence of injury

involving 47% of the glandular mucosa compared to 33% not receiving such treatment. Similar results were obtained if 10% EtOH was given prior to 100% EtOH. However, results with INDO-treated animals were not significantly different from animals without such treatment. On the other hand, INDO-treated animals receiving 25% EtOH followed by 100% EtOH exhibited only 23% injury (significantly less than if water or 10% EtOH preceded 100% EtOH), but significantly more injury than if INDO had not been administered (only 2.3% without INDO).


#### Microscopic findings

#### Non-Indomethacin Studies

Control Tissue (Water followed by sacrifice 15 min later)

A complete description of the histology of normal mucosa has been published previously (Schmidt et al.,

### Adaptive cytoprotection



**Fig. 1.** Light micrograph of rat gastric mucosae exposed to water or 25% ethanol.

**a)** Animal sacrificed at 15 min following oral water administration. Luminal surface mucous cells (SMCs) as well as pit SMCs (arrow heads) are normal appearing. Cells are typically cuboidal or columnar in shape with varying amounts of mucin in their apical cytoplasm. Intact parietal (P) and chief (C) cells lie in the gastric glands (G). The histologic pattern following 10% ethanol exposure was not dissimilar.

**b)** Animal sacrificed at 15 min following oral 25% ethanol. Numerous SMCs in luminal and pit locales (arrow heads) exhibit pyknotic nuclei and/or vacuolated cytoplasm. Exfoliated cells, mucus and debris are present in the gastric lumen (L). Additionally, parietal cells (P) in the upper gland region show lucent cytoplasm indicative of injury. A focal area of vascular congestion is also evident (V). Paraffin embedded, hematoxylin and eosin stained. Bars = 10.0  $\mu$ m.



1985, 1986). These earlier observations were confirmed in the present study. Briefly, the lamina propria facing the gastric lumen or gastric pits was covered with a sheet of contiguous surface mucous cells (SMCs). These SMCs were cuboidal or columnar in shape and were characterized by a palely-stained apical cytoplasm which, in the living state, is filled with mucin granules (Fig. 1a). Gastric pits were of normal width and depth. Parietal, chief and mucous neck cells were readily visible within gastric glands. Connective tissue of the lamina propria was present as thin slips between adjacent gastric glands and as expansions within interfoveolar zones.

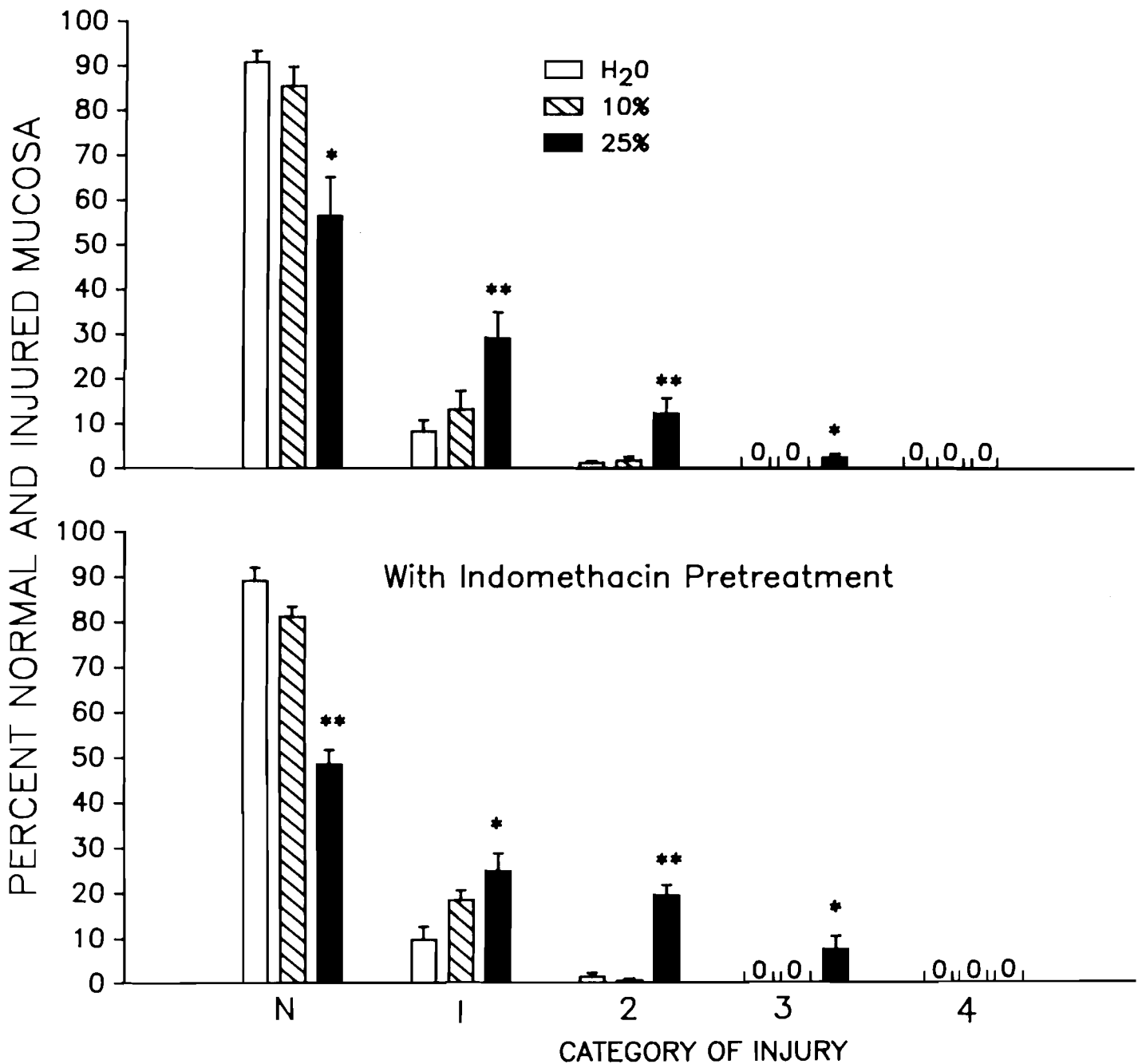
Quantitative histologic analysis revealed that approximately 8% of the mucosal surface demonstrated evidence of scattered interfoveolar SMCs that displayed pyknotic nuclei and/or cytoplasmic vacuoles (Fig. 2). These cells were apparently undergoing senescence preparatory to the normal exfoliative process. Nevertheless, since such areas cannot be distinguished from what we commonly call Type 1 injury, they were classified as such. In addition, approximately 1% of the surface was involved in what we would generally classify as Type 2 injury. This type of alteration was confined to SMCs localized to interfoveolar zones and the gastric pits.

10% Ethanol Exposed Tissue (10% EtOH followed by sacrifice 15 min later)

Light microscopic evaluation of gastric mucosae exposed to 10% oral EtOH indicated a pattern of tissue injury quite similar to that observed in the oral water controls. Injury was confined to individual SMCs or focal, minute regions of contiguous SMCs which displayed the preestablished criteria for cell injury. Approximately 15% of gastric mucosa was characteristic of Types 1 and 2 damage but, although this amount was higher than that for water controls, the difference did not achieve statistical significance (Fig. 2).

25% Ethanol Exposed Tissue (25% EtOH followed by sacrifice 15 min later)

Microscopy of 25% EtOH-exposed stomachs revealed increased numbers of compromised luminal SMCs and damaged pit SMCs, and a concomitant increase in the depth of mucosal injury, some of which extended into the gastric glands (Fig. 1b). More SMCs facing the gastric luminae and lining the pits were injured than in animals receiving either water or 10% EtOH orally. Type 1 damage was found in 29.0% of the mucosal surface and Type 2 injury was present in another 12.2% (Fig. 2). A small amount (2.4%) of Type 3 damage, limited to the upper gastric gland region, was detected in a few tissue sections.



**Fig. 2.** Microscopic analysis of the effect of oral water, 10% EtOH or 25% EtOH upon the mean percentage depth of gastric mucosal injury with and without indomethacin pretreatment. H<sub>2</sub>O, water; 10%, 10% ethanol; 25%, 25% ethanol; n = 5-7 animals/group; 0 = no histologic evidence of injury; N = normal tissue. \* p < 0.05; \*\* p < 0.01 vs. H<sub>2</sub>O under same experimental conditions.

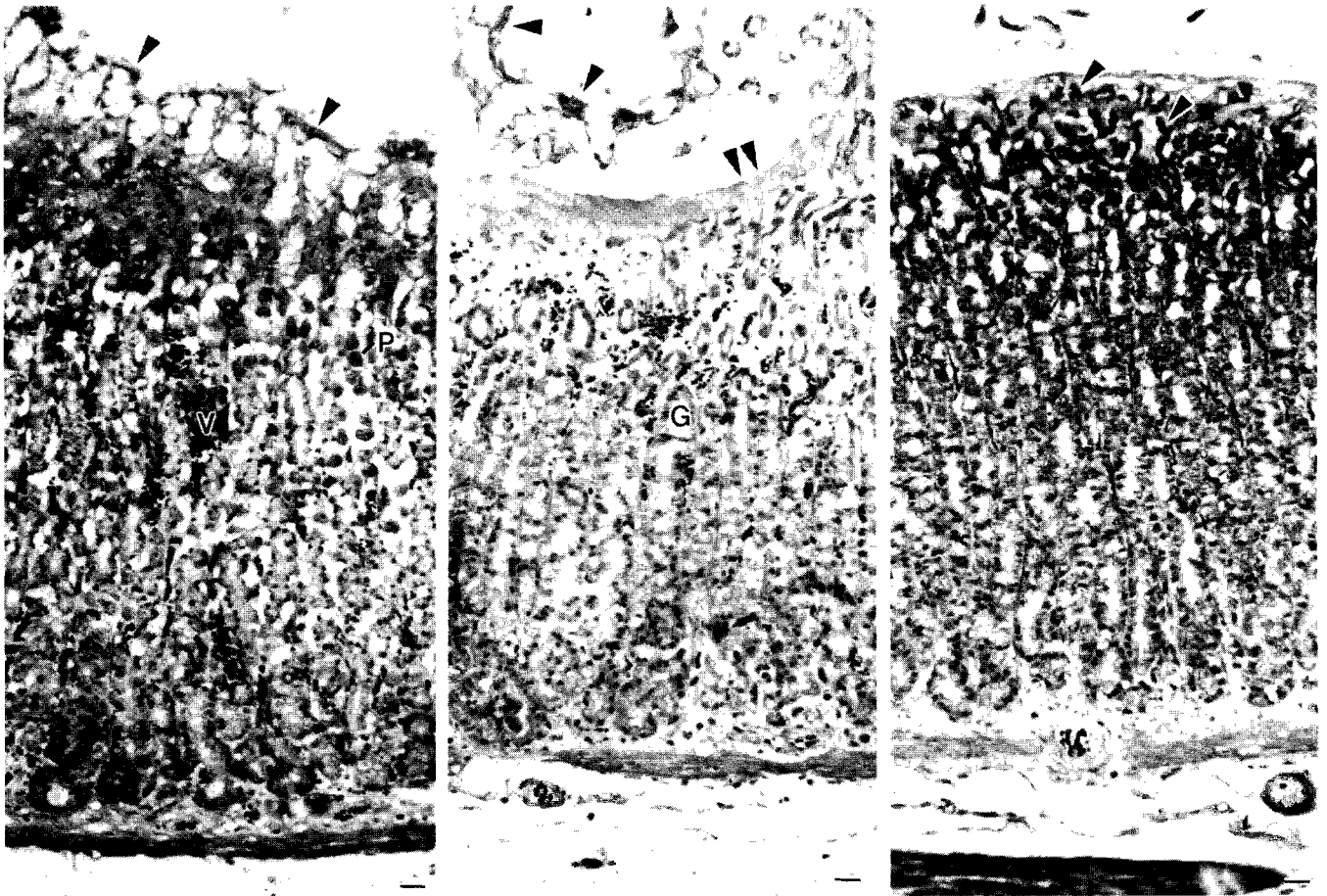
#### 100% Ethanol Exposed Tissue (Following Water Pretreatment)

The gastric mucosae of animals exposed to water prior to 100% EtOH were severely injured (Fig. 3a). This damage consisted of extensive surface cell insult such that less than 1% of the mucosal surface was normal. Depth of injury ranged from about 1% Type 1 damage to greater than 41% Type 4 damage (Fig. 4). Types 1 and 2

damage involved injury to and, in many instances, exfoliation of SMCs confined to interfoveolar and gastric pit locales often with accompanying collapse of the pit wall. Type 3 injury was present in approximately 48% of mucosal tissues receiving this protocol.

A large portion of the Type 4 injured tissues displayed the characteristics of what we have elected to call EtOH-induced «in situ fixation». This type of injury was accompanied by rapid death and a lifting of but not

## Adaptive cytoprotection



**Fig. 3.** Light micrographs of rat gastric mucosae exposed to 100% ethanol after various pretreatment regimens.

**a)** Animal administered oral water and sacrificed at 5 min following oral 100% ethanol. Extensive injury of the gastric mucosa is evidenced by exfoliated arcades of SMCs (arrow heads), and damaged parietal cells (P). Vascular congestion is also evident (V).

**b)** Animal administered 10% ethanol and sacrificed at 5 min following oral 100% ethanol. The depth and extent of gastric mucosal injury does not differ significantly from that observed with the water/100% ethanol protocol (compare with 3a). SMCs are damaged and exfoliated (arrow heads), glands (G) are dilated and many associated epithelial cells are injured. Mucus and cell debris fill the gastric lumen (double arrows).

**c)** Animal administered 25% ethanol and sacrificed at 5 min following oral 100% ethanol. Extensive superficial mucosal injury is clearly present and comparable to that observed accompanying water or 10% ethanol prior to 100% ethanol. However, the depth of injury of animals in this group was considerably less pronounced than that observed in animals in the other two groups. Arrows indicate damaged SMCs. Vascular congestion and glandular injury are markedly reduced. Paraffin embedded, hematoxylin and eosin stained. Bars = 10.0 µm.

exfoliation of interfoveolar epithelial cells. In addition, the underlying connective tissue was markedly acidophilic and its normal histoarchitecture was destroyed. Lastly, red blood cells were lysed although little hemorrhage was evident.

When Type 4 injury did not involve EtOH-induced «in situ fixation», sheets of SMCs, cell debris, fibrin and mucus were shed into the gastric lumen. Few red blood cells were lysed but profound hyperemia and hemorrhage were prevalent. Gastric glands were dilated and most or all of the glandular epithelium was injured.

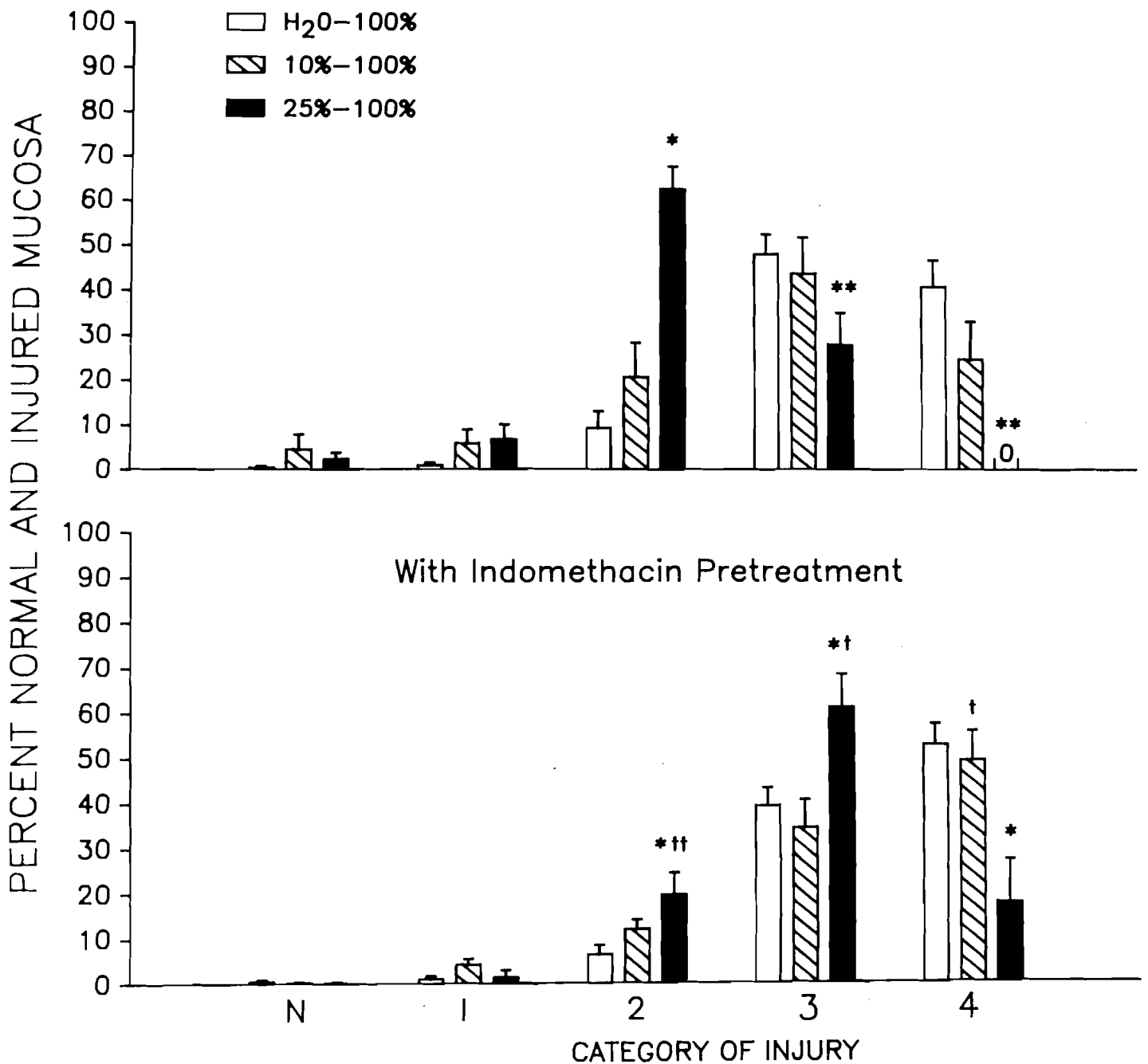
#### 100% Ethanol Exposed Tissue (Following 10% EtOH Pretreatment)

Tissue destruction in stomachs of animals exposed to 10% EtOH followed by 100% EtOH displayed a pattern

of injury virtually identical to that observed in the water-100% EtOH group (Fig. 3b). Approximately 6% of the epithelium was Type 1, 21% was Type 2, 44% was Type 3, and 25% was Type 4 damage (Fig. 4). None of these values were significantly different from the findings of the water-100% EtOH group. The full range of injury described in the water-100% EtOH group was present, including «in situ» Type 4 damage.

#### 100% Ethanol Exposed Tissue (Following 25% EtOH Pretreatment)

Gastric mucosae exposed to 25% alcohol followed by 100% EtOH displayed a different pattern of injury compared with either water-100% EtOH or 10%-100% EtOH treated tissues (Fig. 3c). Although little normal tissue was preserved (2.4%), the deepest injury present



**Fig. 4.** Microscopic analysis of the effect of oral 100% ethanol following pretreatment with water, 10% ethanol or 25% ethanol upon the percentage depth of gastric mucosal injury. H<sub>2</sub>O, water; 10%, 10% ethanol; 25%, 25% ethanol; 100%, 100% ethanol; n = 6-10 animals/group; O = no histologic evidence of injury; N = normal tissue. \* p < 0.05; \*\* p < 0.001 vs H<sub>2</sub>O-100% under same experimental conditions. † p < 0.05; †† p < 0.001 compared with corresponding group not receiving indomethacin pretreatment.


was Type 3 and Type 4 damage was totally absent. Most of the injury observed (~70%) consisted of Types 1 and 2 damage (Fig. 4).

#### Indomethacin Studies

Exposure to Water, 10% Ethanol or 25% Ethanol Alone (5.0 mg/kg intraperitoneal INDO followed 30 min later by oral administration of water, 10% EtOH or 25%

EtOH and sacrifice 15 min later).

Gastric mucosae exposed to water following INDO administration displayed a pattern of tissue injury which was virtually identical to that observed in animals receiving water without INDO pretreatment (Fig. 2). Greater than 89% of the mucosal tissue was normal; the remainder demonstrated alterations characteristic



**Fig. 5.** Light micrographs of rat gastric mucosae pretreated with indomethacin and exposed to 100% ethanol after water or 10% or 25% ethanol.

**a)** Animal administered oral water and then sacrificed at 5 min following oral 100% ethanol. Extensive mucosal injury is clearly present as indicated by exfoliated cells (arrow heads). Gland dilation (G) and hyperemia (double arrows) are also indicators of injury. M, mucus.

**b)** Animal administered oral 10% ethanol and then sacrificed at 5 min following oral 100% ethanol. Comparison with **Fig 5a** shows similar degree and depth of tissue disruption. Arrow heads, exfoliated SMCs; V, vascular congestion.

**c)** Animal administered oral 25% ethanol and then sacrificed at 5 min following oral 100% ethanol. Extensive injury of the gastric mucosa is clearly evident (compare with **Figs. 5a and 5b**). Paraffin-embedded, hematoxylin and eosin stained. Arrow heads, exfoliated SMCs; V, vascular congestion; M, mucus. Bars = 10.0  $\mu$ m.

predominantly of Type 1 injury with a small amount typifying Type 2 injury.

If the mucosae were exposed to 10% EtOH following INDO, again the damage profile was virtually identical to that observed with INDO pretreatment and water exposure or with water or 10% EtOH exposure alone without INDO (**Fig. 2**). More than 81% of the tissue was normal with about 19% demonstrating alterations typical of Types 1 and 2 injury; Types 3 and 4 damage were absent.

Administration of 25% EtOH following INDO pretreatment demonstrated tissue injury in which only 48% of the mucosae was judged as normal. Approximately 44% of such treated tissue was characteristic of Types 1 and 2 injury and about 7% was Type 3 damage. This resultant distribution reflected very closely that observed when mucosa was exposed to 25% EtOH alone without INDO pretreatment so that these findings could not be ascribed to INDO itself (**Fig. 2**).

#### Exposure to 100% Ethanol Following Oral Water, 10% Ethanol or 25% Ethanol Pretreatment

In tissues from animals pretreated with INDO and oral water administration prior to 100% EtOH exposure, virtually no normal tissue could be identified (**Fig. 5a**). Tissue damage was characterized predominantly by Types 3 and 4 injury. Greater than 50% of the mucosa demonstrated Type 4 injury and although this was greater than the water-100% EtOH group without INDO, this difference was not significant (**Fig. 4**).

Gastric instillation of 10% EtOH into INDO-treated rats prior to 100% EtOH showed the same form and distribution of injury as observed in the INDO-treated tissues exposed to water followed by 100% EtOH. Normal tissues were virtually absent and almost 84% of the injury present was identified as Types 3 and 4 (**Fig. 5b**). Again, the pattern of injury was similar to tissues exposed to 10% EtOH prior to 100% EtOH but without



INDO pretreatment and was not significantly different, except when comparing the magnitude of Type 4 injury between the two groups (Fig. 4).

The group of INDO-treated animals which received 25% EtOH prior to 100% EtOH exhibited marked tissue injury which consisted of approximately 79% Types 3 and 4 damage (Fig. 5c). In concert with the INDO-treated tissues exposed to water or 10% EtOH prior to 100% EtOH, almost no normal tissue could be detected by microscopic analysis. It should be noted that the INDO-treated tissues which received 25% EtOH prior to 100% EtOH did not demonstrate as much Type 4 injury as seen in the water or 10% EtOH counterparts [18% versus 53% and 49% respectively, and was not consistently observed in all animals (only four of six animals possessed such injury)]. However, there was considerably more Type 3 injury when compared with the same groups (61% versus 39% and 34%, respectively). Further, compared to tissue exposed to 25% EtOH prior to 100% EtOH without INDO pretreatment, the depth of injury in this group was increased (Fig. 4).

## Discussion

Cytoprotection has been defined as that property of PGs, independent of their known antisecretory effects, which enables them to protect the mucosa of the gastrointestinal tract (particularly the stomach) against the damaging effects of various noxious agents when administered topically (Robert, 1979). Two forms of cytoprotection have been described. Direct cytoprotection refers to the prevention or attenuation of gastric mucosal injury that would normally occur following exposure of the epithelium to a damaging agent in response to exogenous PGs (i.e. either parenterally or topically) given prior to the administration of the damaging substance or concomitant with it (Robert, 1979; Miller, 1983). In adaptive cytoprotection, the mucosal damage known to occur in response to a necrotizing agent is reduced or eliminated if the gastric mucosa is previously exposed to a dilute or low concentration of the same agent or even differing agents, such substances referred to as «mild irritants» (Chaudhury and Robert, 1980; Robert et al., 1983). Thus, in studies with rats orally treated with various mild irritants such as low concentrations of ethanol, hydrochloric acid, taurocholate, alkali, sodium chloride, and 70°C water, the usual gastric mucosal damaging effects of acidified 80mM taurocholate, 100% ethanol, concentrated acid, concentrated base, hyperosmolar sodium chloride, and even boiling water could be prevented or markedly attenuated (Robert et al., 1978, 1983; Chaudhury and Robert, 1980). The finding that this protective effect of mild irritants could be abolished by pretreatment with indomethacin (an inhibitor of PG synthesis) and that a number of mild irritants themselves could stimulate PG synthesis suggested that these findings were elicited by endogenous PGs (Danon and Assouline, 1979; Konturek et al., 1982; Robert et al., 1983).

Although a large body of experimental evidence has

accumulated over the last decade that strongly supports the existence of a cytoprotective property of exogenous PGs, most initial observations evaluating this phenomenon have assessed protection in terms of the absence or reduction in macroscopically visible necrotic lesions (Robert, 1979; Miller, 1983). Thus, if a particular damaging agent induced the formation of mucosal damage (usually in the form of necrotic lesions that appear as hemorrhagic streaks) macroscopically and pretreatment with a given PG prevented such lesions, the PG being evaluated was said to be cytoprotective. The major drawback in assessing cytoprotection in this fashion is that what might be perceived as damage or protection macroscopically may not correspond to what is actually observed when affected mucosa is carefully evaluated microscopically. In assessing the phenomenon of direct cytoprotection microscopically, it is now firmly established as a result of a number of very carefully conducted histologic studies that PG mediated protection is primarily limited to the deeper layers of the mucosa rather than to the surface epithelium (Lacy and Ito, 1982; Guth et al., 1984; Schmidt et al., 1985, 1986). Consequently, when one observes the prevention of necrotic lesions macroscopically by a given PG what is really being noted is the prevention of deep mucosal injury rather than surface cell protection since evaluation of this more superficial layer can only be adequately ascertained microscopically.

Whether a similar circumstance involving a discrepancy between macroscopic and microscopic findings exists with respect to adaptive cytoprotection formed the basis of the present study. With the exception of a few semi-quantitative histologic observations, virtually all studies to date evaluating the phenomenon of adaptive cytoprotection have relied exclusively on macroscopic information to determine whether a mild irritant under a given set of experimental circumstances elicits protective effects. This study is the first rigorously conducted histologic study of which we are aware to determine whether an alleged «mild irritant», such as a low concentration of ethanol, can indeed prevent the known damaging effects of 100% ethanol when administered orally to the rat stomach. Our findings indicate that adaptive cytoprotection is a real phenomenon microscopically, and like direct cytoprotection, involves preservation of primarily the deeper layers of the gastric epithelium, namely the gastric glands. This was exemplified microscopically by the complete absence of Type 4 injury and a significant reduction of Type 3 injury in mucosa pretreated with the mild irritant, 25% ethanol.

Like previous observations assessing the histologic correlates of direct cytoprotection (Lacy and Ito, 1982; Guth et al., 1984; Schmidt et al., 1985, 1986), this study is a further example of the discrepancy that exists between macroscopic evaluation of the gastric mucosa and what was observed microscopically. Based on macroscopic findings, one would conclude that adaptive cytoprotection involved all layers of the gastric epithelium. As clearly shown by our microscopic results,

this was not the case. If one realizes, however, that the necrotic hemorrhagic streaks seen grossly are really a macroscopic expression of deep Type 3 injury and particularly Type 4 injury, then using macroscopic findings as an index of the presence or absence of such microscopic lesions can be of value in assessing whether adaptive cytoprotection occurs under a given set of experimental conditions without embarking on a detailed histologic evaluation of tissues in question. When viewed in that context, our macroscopic findings, both with and without indomethacin treatment, paralleled quite closely the microscopic observations.

A curious finding of our study is the apparent need for the generation of a threshold level of superficial damage by a mild irritant prior to exposure to a necrotizing agent such as 100% ethanol for adaptive cytoprotection to occur. This is borne out by the different effects of 10% ethanol and 25% ethanol in their ability to prevent deep gastric injury induced by 100% ethanol. Pretreatment with 10% ethanol, for example, had no significant damaging effects to the gastric mucosa when compared with water controls, but neither was it able to elicit protection against the injurious effects of 100% ethanol. In contrast, 25% ethanol elicited mild damage (Types 1 and 2 injury) and significantly reduced the depth of injury induced by 100% ethanol when compared with water and 10% EtOH pretreatment. Exactly how the superficial injury induced by 25% ethanol elicits its protective effects remains to be determined and must await further study. Perhaps the deeper damage (Type 2 injury) that was elicited by 25% ethanol, but not water and 10% ethanol, is a necessary «triggering event» for adaptive cytoprotection to occur. Wallace's finding of the induction of surface epithelial damage when using 1 M NaCl as the mild irritant to prevent deep gastric damage in the rat stomach elicited by 70% ethanol supports this contention (Wallace, 1988).

Our findings also suggest that endogenous PGs may at least in part be responsible for the mediation of adaptive cytoprotection since the protective effects by 25% ethanol could be partially obliterated by pretreatment with indomethacin. The dose of indomethacin employed in this study has been previously shown to profoundly inhibit endogenous gastric PG synthesis; in fact, synthesis of 6-keto  $\text{PGF}_{1\alpha}$  (the breakdown product of prostacyclin) was inhibited by 77% with this dose (Wallace, 1988). Although the exact sequence of events by which a mild irritant would be coupled with endogenous PGs to mediate adaptive cytoprotection remains to be elucidated, one possible mechanism is suggested by our data, namely that the degree of injury to the superficial gastric mucosa induced by 25% ethanol sets into motion a response that then triggers the release of endogenous PGs from either epithelial cells themselves or some other cell type such as macrophages, neutrophils or mast cells, all of the latter being known to contain high quantities of PGs (Bailey, 1985). If such events do in fact occur, this would explain why some significant degree of epithelial injury is necessary (perhaps Type 2 injury), as induced by 25% ethanol, and why 10% ethanol was not

an effective protective agent. Exactly how endogenous PGs would then prevent the deep mucosal injury normally elicited by 100% ethanol remains to be elucidated. Possible mechanisms that have been proposed include stimulation of mucus and bicarbonate secretion, enhanced mucosal blood flow, and more efficient epithelial restitution capabilities, all of which appear to be important in enabling the gastroduodenal epithelium to protect itself from injury and to initiate repair once injury has occurred (Miller, 1983, 1988).

In conflict with our findings are the recent observations of Wallace (1988) who used the mild irritant 1 M NaCl prior to 70% ethanol exposure to produce adaptive cytoprotection in an *ex vivo* rat stomach preparation. Employing semi-quantitative histology and macroscopic evaluation to assess the presence of injury or protection, adaptive cytoprotection could not be reversed following application with the same dose of indomethacin that we used even though it reduced endogenous PG synthesis by as much as 77%. He concluded that the mechanism of adaptive cytoprotection did not require a role for prostaglandins. The explanation for the discrepancy between our findings and those of Wallace (1988) is not immediately apparent. Perhaps the different mild irritants used in the two studies (1 M NaCl vs 25% ethanol) have different efficacies in terms of their ability to elicit adaptive cytoprotection and the extent to which inhibition of prostaglandin synthesis could influence this effect. Of interest in this regard is the observation by Wallace that indomethacin was able to partially reverse the protective effect of 20% ethanol against 70% ethanol induced injury macroscopically (Wallace, 1988), but unfortunately no histologic information was provided. An additional difference in comparing the two studies lies in the semi-quantitative histology which was employed in the Wallace study: a given tissue section received a score of 0 to 3 depending on the overall presence of necrosis and the continuity of epithelium. Our studies (Schmidt, 1985, 1986) have shown that cytoprotection pivots around the preservation of cells lying at or below the gastric pit and the non-protection of cells luminal to this locale. Mild and/or harsh irritants cause a highly varied destruction of the mucosal surface such that a single grade per tissue section could be highly misleading. Had a more critical and discerning histological quantitation been performed, a significant decrease in cytoprotection with indomethacin may have been demonstrated.

Despite the role that PGs may ultimately be shown to play in mediating adaptive cytoprotection, it seems equally clear from our findings that other mechanisms may also be involved. This suggestion stems from the observation that even in animals pretreated with indomethacin and exposed to topical 25% ethanol prior to the necrotizing effects of 100% alcohol, the degree of subsequent injury was still less than what occurred when water or 10% ethanol was given prior to 100% alcohol. Either the remaining endogenous PGs (approximately 20% of that usually present) after indomethacin treatment

was sufficient to allow some degree of adaptive cytoprotection to occur or other, yet undefined, mechanisms are important in eliciting this effect.

In summary, our studies clearly show that adaptive cytoprotection is a real phenomenon and can be demonstrated microscopically. Like direct cytoprotection, it is limited primarily to the deeper layers of the glandular epithelium without preservation of the superficial epithelial cells. Further, our data strongly indicate that some degree of superficial mucosal injury may be a necessary catalyst to induce adaptive cytoprotection. Finally, the ability to prevent this phenomenon, at least partially, with indomethacin implicates a potentially important role for endogenous PGs in the mediation of this effect.

---

*Acknowledgements.* This work was supported by Research Grant DK 25838 awarded to Dr. Miller from the National Institutes of Health and by Research Grant AA 06887 awarded to Dr. Schmidt from the National Institute of Alcohol Abuse and Alcoholism. The authors thank Ms. Inci Akkaya for her able secretarial skills in the preparation of this manuscript.

---

## References

- Bailey J.M. (editor) (1985). Prostaglandins, Leukotrienes and Lipoxins, Plenum Press, New York.
- Chaudhury T.K. and Robert A. (1980). Prevention by mild irritants of gastric necrosis produced in rats by sodium taurocholate. *Dig. Dis. Sci.* 25, 830-836.
- Danon J.A. and Assouline G. (1979). Antiulcer activity of hypertonic solutions in the rat: Possible role of prostaglandins. *Eur. J. Pharm.* 58, 425-531.
- Fitzpatrick F.A. and Wynalda M.A. (1976). In vivo suppression of prostaglandin biosynthesis by non-steroidal anti-inflammatory agents. *Prostaglandins* 12, 1037-1051.
- Guth P.H., Paulsen G. and Nagata H. (1984). Histologic and microcirculatory changes in alcohol-induced gastric lesions in the rat: Effect of prostaglandin cytoprotection. *Gastroenterology* 87, 1083-1090.
- Karnovsky M.J. (1965). A formaldehyde-glutaraldehyde fixative of high osmolality for use in electron microscopy. *J. Cell. Biol.* 27, 137A.
- Konturek S.J., Brzozowski T., Piastucki I., Radecki T., Dembinski A. and Dembinska-Kiec A. (1982). Role of locally generated prostaglandins in adaptive gastric cytoprotection. *Dig. Dis. Sci.* 27, 967-971.
- Lacy E.R. and Ito S. (1982). Microscopic analysis of ethanol damage to rat gastric mucosa after treatment with a prostaglandin. *Gastroenterology* 83, 619-625.
- Miller T.A. (1983). Protective effects of prostaglandins against gastric mucosal damage: Current knowledge and proposed mechanisms. *Amer. J. Physiol.* 245, G601-G623.
- Miller T.A. (1988). Gastroduodenal mucosal defense: Factors responsible for the ability of the stomach and duodenum to resist injury. *Surgery* 103, 389-397.
- Robert A. (1979). Cytoprotection by prostaglandins. *Gastroenterology* 77, 761-767.
- Robert A., Lancaster C., Hanchar A.J. and Nezamis J.E. (1978). Mild irritants prevent gastric necrosis through prostaglandin formation: Histologic study. *Gastroenterology* 74, 1086 (Abstract).
- Robert A., Nezamis J.E., Lancaster C., David J.P., Field S.O. and Hanchar A.J. (1983). Mild irritants prevent gastric necrosis through «adaptive cytoprotection» mediated by prostaglandins. *Amer. J. Physiol.* 245, G113-G121.
- Schmidt K.L., Henagan J.M., Smith G.S., Hilburn P.A. and Miller T.A. (1985). Prostaglandin cytoprotection against ethanol-induced gastric injury in the rat: A histologic and cytologic study. *Gastroenterology* 88, 649-659.
- Schmidt K.L., Bellard R.L., Smith G.S., Henagan J.M. and Miller T.A. (1986). Influence of prostaglandin on repair of rat stomach damaged by absolute ethanol. *J. Surg. Res.* 41, 367-377.
- Smith G.S., Schmidt K.L. and Miller T.A. (1987). Morphologic characteristics of adaptive cytoprotection in the rat. *Gastroenterology* 92, 1646 (Abstract).
- Wallace J.L. (1988). Increased resistance of the rat gastric mucosa to hemorrhagic damage after exposure to an irritant: Role of the «mucoïd cap» and prostaglandin synthesis. *Gastroenterology* 94, 22-32.

Accepted September 10, 1988