

# Immunohistochemical study of Warthin's tumour with special regard to the germinal centre

Akihiro Masuda

Department of Pathology, Yamagata University, School of Medicine, Zao-lida, Nishinomae, Yamagata, Japan 990-23

**Summary.** In order to analyze the role of the lymphoid stroma of Warthin's tumour, the author made an immunohistochemical study especially focussing on the germinal centre (GC). In the GCs, IgM and IgE were much more clearly observed in a lace-like network than other heavy chains, and also could be detected electron microscopically on the surface of GC cells and follicular dendritic cells (FDCs). Plasma cells scattered beneath the epithelial component were mainly positive for IgG and IgA. IgG-positive plasma cells were more predominant than IgA plasma cells. Among the cases examined, there was a significant difference in the number of IgE-positive GC and plasma cells. In the GCs five complement components (C1g, C4, C3c, C3d, C5) and complement receptors (C3bR and C3dR) were positive, displaying a lace-like pattern, which were proved, electron microscopically, to coincide with the surface of FDCs and GC cells. IgE-positive GCs showed the same result. DRC1, which specifically reacts to FDC-membrane, was located only in GCs, and electron microscope also revealed positive findings on the surface of FDCs. The above mentioned findings in the GC of Warthin's tumour were similar to those of lymph nodes except for the frequent distribution of IgE. Salivary amylase was seen in the GC on rare occasions, but was not positive on the surface of GC cells and FDCs. It is suggested that FDCs play an important role in immunological behaviour with complement and complement receptors in the GC of Warthin's tumour.

**Key words:** Warthin's tumour - Germinal centre - Follicular dendritic cell - Immunohistochemistry

## Introduction

The histological features of Warthin's tumour are very characteristic, being composed of double layered epithelium and lymphoid stroma. Although many reports on the histogenesis of Warthin's tumour, especially concerning the lymphoid component, have been published, no consensus has been reached. Moreover, the existence of lymph follicles with germinal centre (GCs) is one of the noticeable characteristics of Warthin's tumour. It is supposed that the GCs of lymph follicles have the function of retention and presentation of antigen-antibody complex (Van Rooijen, 1977), and that the complement components and complement receptors play important roles in these functions (Papamichail et al., 1975; Klaus and Humphery, 1977). In consideration of these respects, the present study used immunohistochemical methods to focus on the nature of lymphoid stroma, especially on the GCs, of Warthin's tumour.

## Materials and methods

Twenty-four cases of Warthin's tumour of the parotid gland, only one case of which was female, were studied. Tumour-free perigastric lymph nodes of four cases were used as a control study for lymph follicles.

All specimens were fixed in 10% formalin and embedded in paraffin. Sections were stained with hematoxylin-eosin for histological evaluation and also prepared for the immunohistochemical study (PAP method) in order to detect immunoglobulins (IgM, IgG, IgA, IgE, K and light chain), lysozyme, secretory component and salivary amylase.

Freshly obtained tumour tissues of 4 cases were fixed in periodate-lysine-paraformaldehyde (PLP) solution for 6 hours and then frozen in OCT compound (Lab Tek Products) after rinsing in increasing concentrations of sucrose in PBS. Fresh specimens were sectioned with a cryostat and put on albumin-coated slides. Direct and

indirect immunohistochemical examinations on light and electromicroscopic levels were performed for detection of the following materials: immunoglobulins, secretory component, salivary amylase, complement components (C1q, C4, C3c, C3d, C5, C6, C8, C9, C3b inactivator (C3bINA),  $\beta$ 1H globulin, C3 proactivator (C3PA) and properdine), additionally monoclonal antibodies, Leu1, Leu2a, Leu3a, C3bR, CR2, CR3, B1, DRC1. Details of the immunostaining procedure were described previously (Farr and Nakane, 1981; Kasajima et al., 1986). For the detection of IgM, IgE and C3d,  $F(ab')_2$  fragments of immunoglobulin were labelled with horseradish peroxidase (HRP). Details of the method and preparation of peroxidase conjugated  $F(ab')_2$  fragment were described previously (Farr and Nakane, 1981; Yamakawa, 1985).

Control studies to examine the specificity of stainability were carried out as follows. 1) Non-immunized sera were used instead of specific first sera. 2) The first step sera or second step sera were omitted. 3) Only the DAB reaction was performed to check endogenous peroxidase activity. 4) Absorption tests were performed on some antisera. Antisera and their sources are shown in Table 1.

## Results

Variable amounts of lymphoid stroma were associated with lymph follicle and GCs in the examined cases. The morphological features of the GCs were fundamentally identical to those of lymph nodes composed of GC cells, FDCs and tingible body macrophages. In addition, there were prominent plasma cells in the stroma, especially near the basement membrane of the epithelial component. Paraparotid lymph nodes could be extirpated simultaneously with tumour removal in one case. Lymph nodes of this case contained epithelial components of Warthin's tumour (Fig. 1). Some cases showed infiltration of granulocytes, stromal fibrosis or granulomatous reaction consisting of epithelioid cells.

### Immunoglobulins

In most cases examined, IgM, IgE and IgG showed reticular positive staining in the GCs of lymph follicles (Table 2). In general, GCs of Warthin's tumour showed reticular staining of IgM, IgE and IgG. Reticular positive staining of IgM and IgE could be recognized more clearly than other classes of immunoglobulins (Fig. 2). There was, however, significant difference among the cases in terms of the rate of IgE-positive GCs. Some GC cells of all cases showed intracytoplasmic positive staining of immunoglobulins, especially of IgG and IgM. Both  $\kappa$  and  $\lambda$  light chains expressed similarity to heavy chains. Electron microscopy demonstrated immunoglobulins showing a positive reaction on the surface of cytoplasmic processes with complicated labyrinth structures (Fig. 3). IgM and IgG showed positive reaction in the perinuclear space and rough endoplasmic reticulum of some lymphoid GC cells. On the other hand, there was no positive

reaction for immunoglobulins in the cytoplasm of FDCs.

Plasma cells were frequently distributed beneath the epithelium in Warthin tumour and were polyclonally stained with IgG, IgM, IgA and IgE. IgE-positive plasma cells and IgM-positive plasma cells were rarely observed. Only in case no. 23 were IgE-positive plasma cells predominantly observed. In all cases, the ratio of IgG-positive plasma cells to IgA-positive plasma cells was 1:1 to 2:1 in the serial sections (Fig. 4). Both  $\kappa$  and  $\lambda$  light chains showed polyclonal staining.

In all cases, many mast cells were observed, many of which showed positive staining of IgE on their surface. Mast cells were scattered in the intraepithelial layer, and sometimes in lymphoid stroma, especially in the vicinity of the epithelial component.

The epithelial component of Warthin's tumour was positive for IgA (Fig. 4) and SC, and sometimes for IgG or IgM, in the cytoplasm.

### Complement components and complement receptors

C1q, C4, C3c, C3d, and C5 could be detected in the GCs of Warthin's tumour. C3d especially showed a high degree of distinct positivity. These complement components were detected in a lace-like pattern (Fig. 5). In most GCs, there were no positive reactions for C6, C8, C9, C3PA, properdine and  $\beta$ 1H although a positive reaction for C3bINA was sometimes observed. Some GCs were weakly positive for C3bINA showing a lacy pattern. IgE positive germinal centre also showed the same result. Electron microscopically, their reaction products were revealed as electron dense deposits attached to the surface of GC cells and FDCs (Fig. 5). Positive reaction of complement components in the cytoplasm was never detected. Outside the GCs, some complement components were sometimes seen in macrophages and blood vessels.

CR-1 (C3b receptor) and CR-2 (C3d receptor) were also positive demonstrating a lace-like pattern in the GCs (Fig. 6). Electron microscopically, positive reactions were seen on the surface of GC cells, FDCs, and their cytoplasmic processes with complicated labyrinth structure (Fig. 6). On the other hand, CR-3 (C3bi receptor) could not be detected in the GCs.

### Other monoclonal antibodies

The GCs showed positive for DRC1 with a lace-like network (Fig. 7). Positive reaction could not be observed in areas apart from GCs. Electron microscopically, positive reactions were seen on the surface of FDCs and their cytoplasmic processes (Fig. 7).

Leu-3a positive cells were more predominant than Leu-2a positive cells both in GCs and outside GCs. Leu-1 positive cells were observed around the lymph follicle and in interfollicular area (T-area) (Fig. 8). The areas in which B1 positive cells accumulated mainly corresponds to the lymph follicle (B-area). In cases in which the lymphoid stroma was scanty, the T-area/B-area was smaller than cases in which the lymphoid stroma was

ample. Leu-7 positive cells were scattered in the GC.

Summarized data concerning the reactivity of immunoglobulins, complement components, complement receptors and DRC1 in GC of Warthin's tumour and lymph nodes are shown in Table 3.

#### Other antigens

Tingible body macrophages in GCs and macrophages

in subepithelial areas were positive for lysozyme.

Salivary amylase was positive in GCs on Warthin's tumour on rare occasions (Fig. 8). However, electron microscopic examination revealed that amylase was not stained on the surface and cytoplasm of GC cells and FDCs, but positive in amorphous materials in the GC. GCs of lymph nodes never stained for salivary amylase.

**Fig. 1.** Lymph node containing epithelial component of Warthin's tumour. The marginal sinus is visible (arrow). H.E.,  $\times 75$

**Fig. 2.** (a) IgM showed reticular staining in a germinal centre of Warthin's tumour. Methyl green counterstain.  $\times 250$ . (b) IgE also showed reticular staining in a germinal centre of Warthin's tumour. Intraepithelial mast cell containing metachromatic granules is visible (arrow). Toluidine blue counter stain.  $\times 250$ . (c) IgM showed a positive reaction on the surface of germinal centre cells and cytoplasmic process of FDC (arrows).  $\times 9600$ . (d) IgE, Electron micrography revealed a positive reaction on the surface of germinal centre cells and the surface of cytoplasmic process of FDC (arrows).  $\times 9,600$

**Fig. 3.** Immunostaining of IgG (a) and IgA (b) in serial sections: IgG plasma cells are predominant in comparison to IgA plasma cells: intracytoplasmic positive staining for IgG in germinal centre is detected (arrow head): Epithelial component of Warthin's tumour shows positive staining for IgA (arrows). Methyl-green counterstain.  $\times 150$

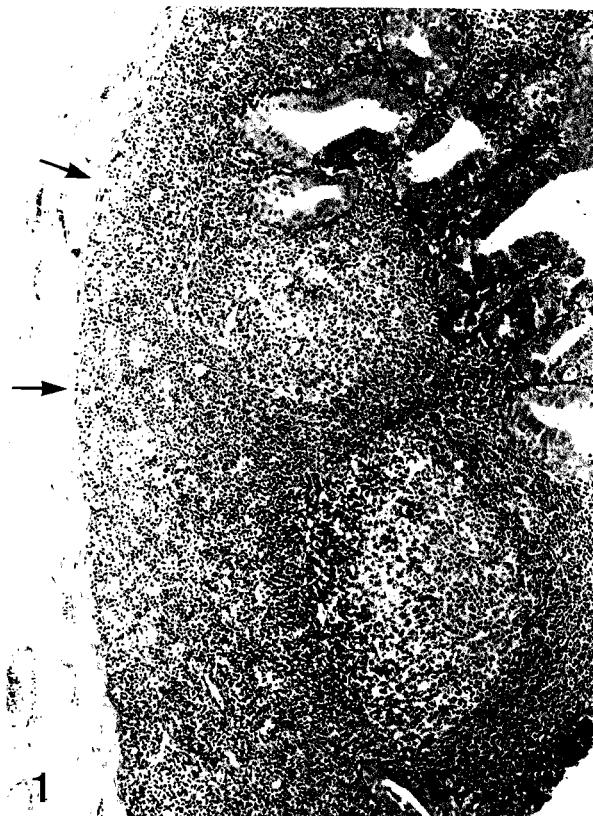
**Fig. 4.** (a) C3d expresses reticular staining in a germinal centre of Warthin's tumour. Methyl-green counterstain.  $\times 300$ . (b) C5 displays reticular fashion in a germinal centre of Warthin's tumour. Methyl-green counterstain.  $\times 250$ . (c) C3d, Electron micrograph of a germinal centre of Warthin's tumour, shows positive reaction on the surface of germinal centre cells and the surface of cytoplasmic process of FDC (arrows).  $\times 9,600$



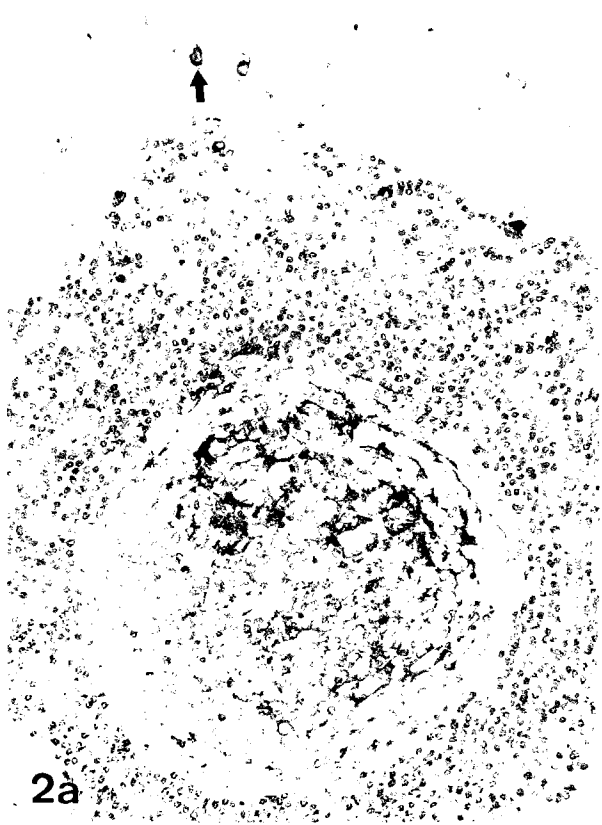
**Fig. 5.** (a) C3bR is positive in a reticular pattern in a germinal centre of Warthin's tumour. Methyl-geen counterstain.  $\times 150$ . (b) Immunostaining of C3dR, showing reticular staining in a germinal centre of Warthin's tumour. Methyl-green counterstain.  $\times 150$ . (c) C3bR shows an electron dense positive reaction on the surface of germinal centre cells and the surface of cytoplasmic process of FDC (arrows).  $\times 5,800$


**Fig. 6.** (a) DRC-1 shows reticular positive staining in a germinal centre of Warthin's tumour. Methyl-green counterstain.  $\times 300$ . (b) DRC-1, shows a positive reaction on the surface of cytoplasmic process of FDC (arrows).  $\times 5,800$

**Fig. 7.** Leu1 positive cells surround the lymph follicle and are scattered in the germinal centre. Methyl-green counterstain.  $\times 75$

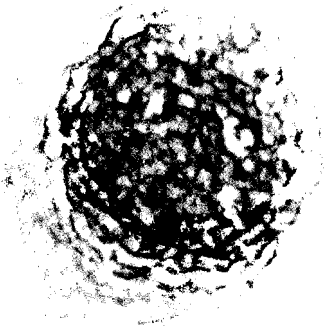
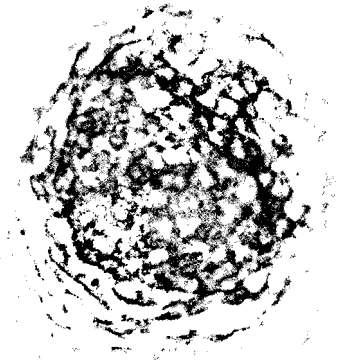
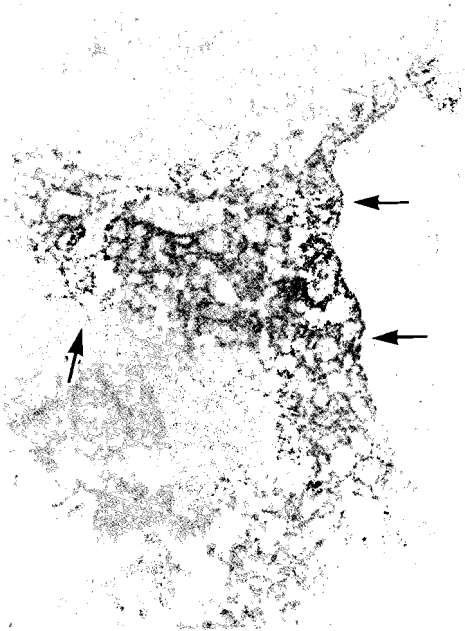
**Fig. 8.** Salivary amylase, shows positive reaction in the germinal centre of Warthin's tumour. Methyl-green counterstain.  $\times 250$






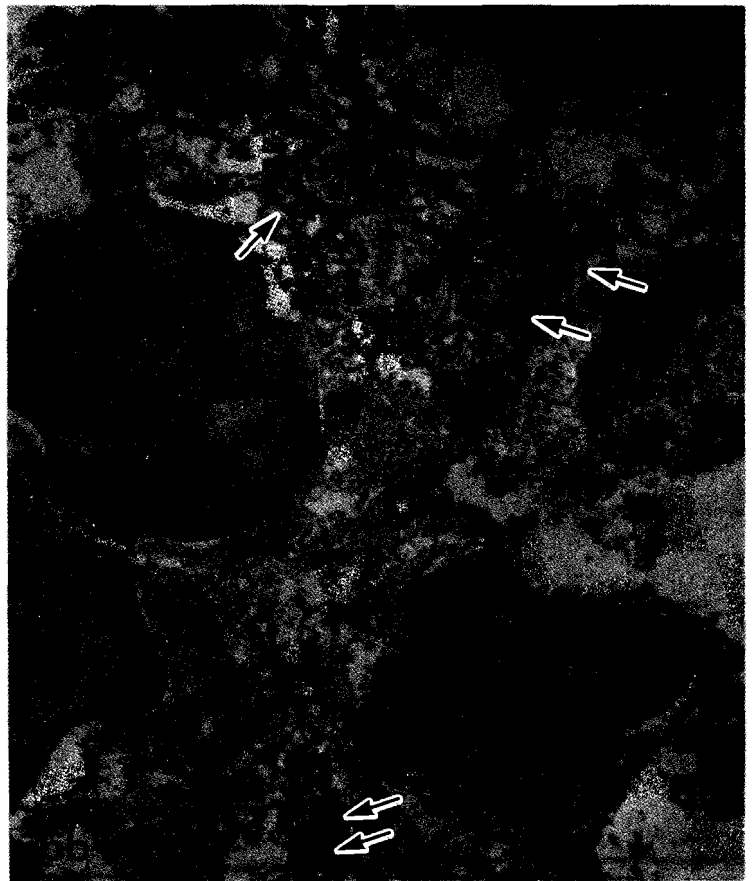
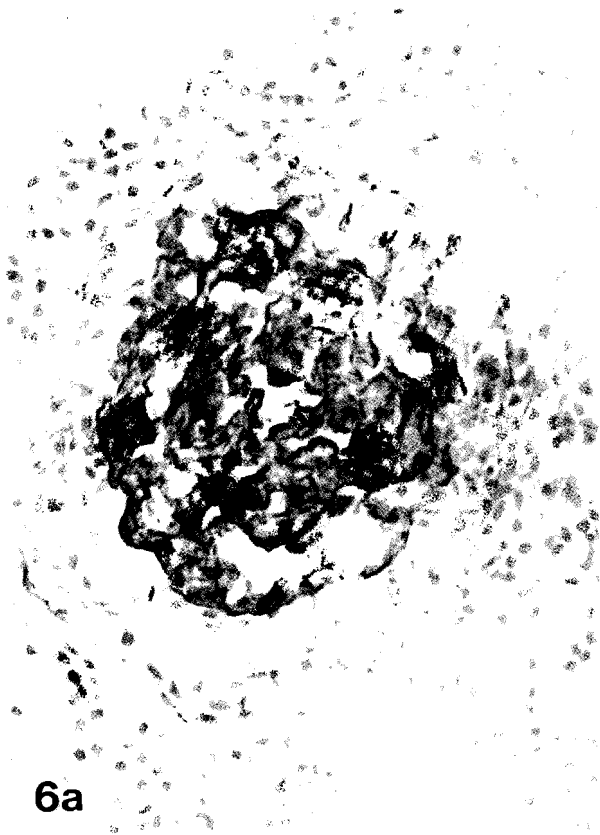


*GC of Warthin's tumour*



5b

5c



**Table 1.** Antibodies employed.

<b>POLYCLONAL ANTIBODIES TO:</b>		(sources)
Immunoglobulins		(DAKOPATTS)
IgG, IgM, IgE, κ & λ light chains		(Behringerwerke)
IgA		(Nordic Immunological Lab.)
Secretory component		
Complement components		(DAKOPATTS)
C1q, C3d, C5		(Behringerwerke)
C3c, C3 activator		(Miles Scientific)
C9, Properdine		(Cappel Lab.)
C6, C8, β1H globulin		(Kent Lab.)
C4, C3bINA		(Nordic Immunological Lab.)
Salivary amylase		(DAKOPATTS)
Lysozyme		
<b>MONOCLONAL ANTIBODIES</b>		
CR1	C3b receptor	(DAKOPATTS)
CR2	C3d receptor	(Becton-Dickinson Monoclonal Center)
CR3	C3bi receptor	(Becton-Dickinson)
DRC-1	Follicular dendritic cells	(DAKOPATTS)
Leu1	T cells	(Becton-Dickinson Monoclonal Center)
Leu2a	Cytotoxic/suppressor cells	(Becton-Dickinson Monoclonal Center)
Leu3a	Helper/inducer cells	(Becton-Dickinson Monoclonal Center)
Leu7	NK cells	(Becton-Dickinson Monoclonal Center)
B1	B cells	(Coulter Clone)
<b>OTHER SERA</b>		
Anti-Rabbit Immunoglobulins for PAP		(DAKOPATTS)
Peroxidase-antiperoxidase complex		(DAKOPATTS)
HRP conjugated goat anti-rabbit IgG		(Cappel Lab.)
HRP conjugated rabbit anti-goat IgG		(Cappel Lab.)
HRP conjugated sheep anti-mouse immunoglobulin		(Amersham International)

**Table 2.** The distribution pattern of immunoglobulins in germinal centre of Warthin's tumour.

	sex	age	IgG	IgA	IgM	IgE
1	M	68	(-)	(-)	* :r	/
2	(#) M	56 lt	(-)	***:r	***:r	(-)
		59 rt	***:s	(-)	* :r,s	** :r
3	M	61	* :s	(-)	***:r	** :r
4	M	52	(-)	(-)	(-)	(-)
5	M	72	***:s	(-)	***:r	(-)
6	M	60	** :r	(-)	** :r	** :r
7	M	56	** :r,s	* :r,s	***:r,s	***:r
8	F	67	* :s	(-)	***:r,s	* :r
9	M	57	***:s	(-)	* :r,s	* :r,s
10	M	72	* :s	(-)	***:r	** :r
11	M	50	* :r	(-)	* :r	(-)
12	M	64	* :s	(-)	(-)	/
13	M	76	* :r	(-)	(-)	/
14	M	69	(-)	(-)	***:r	***:r
15	M	70	***:s	* :r,s	***:r,s	* :r
16	M	45	** :r	(-):r	***:r,s	* :r
17	M	67	(-)	(-)	* :r	(-)
18	M	64	(-)	(-)	(-)	/
19	M	62	(-)	(-)	(-)	* :r
20	M	76	* :s	(-)	***:r	* :r
21	(#) M	57 rt	(-)	(-)	***:r	* :r
		lt	(-)	(-)	***:r	* :r
22	M	71	***:s	(-)	***:r	***:r
23	M	71	(-)	(-)	***:r	** :r
24	( ) M	76	* :r	(-)	***:r	** :r

(-): negative  
 \*: more germinal centre unstained than stained  
 \*\*: more germinal centre stained than unstained  
 \*\*\*: almost all of germinal centres are stained  
 r: reticular pattern  
 s: intracytoplasmic positive cells are scattered  
 /: not examined  
 (#): bilateral occurrence  
 ( ): serum IgE 71 U/ml



**Table 3.** Immunohistochemical findings in germinal centre of Warthin's tumour and lymph node (LN).

	Warthin's tumour	LN
IgG	+	+
IgM	++	++
IgA	- ~ +	- ~ +
IgE	++ ~ -	-
DRC-1	++	++
Complement components and receptors		
C1q	+	+
C4	+	+
C3c	+	+
C3d	++	++
C5	+	+
C6	-	-
C8	-	-
C9	-	-
C3 PA	-	-
Properdine	-	-
$\beta$ 1H	-	-
C3b INA	(+)	(+)
CR1	++	++
CR2	++	++
CR3	-	-

- : negative  
+ : positive  
++: strongly positive  
(+): weakly positive

## Discussion

GCs of lymph follicle have been considered to play important roles in immunological behaviour. It has been generally accepted that FDCs have the function of trapping immune complexes and presenting antigen during long periods with close relation to lymphoid cells (Nossal et al., 1968; Klaus et al., 1980; Gerdes et al., 1983; Imai et al., 1983). DRC-1, which specifically reacts to FDC-membrane (Neiemen et al., 1983), showed a positive reaction in GCs of Warthin's tumour. It has already been reported that complement components and complement receptors are located in GCs of lymph node, tonsil, lymph follicle of thyroid gland and synovia of rheumatoid arthritis (Yamakawa, 1985; Kasajima et al., 1986). The localization of immune complex in GC is complement dependent (Papamichail et al., 1975; Gajl-Peczalska et al., 1969). In the GCs of Warthin's tumour, early components of classical pathways were distributed in lace-like networks similar to C3b receptor and C3d receptor. Complement components, complement receptors and immunoglobulins were located on the surface of labyrinth structure of FDC. It was suggested that FDCs have complement receptors (Gerdes et al., 1982) and also have the function of trapping and retaining immune complexes through these receptors. Iida et al. (1981) reported that C3bR inactivates the C3 and C5 convertase of the classical pathway, and also suggested that C3bR might protect host cells from the

damaging effect of the complement activation. The absence of cytolytic complement components in the GC supports this view. It is still unknown what kinds of antigen participate in hyperplasia of GCs of Warthin's tumour. The present study tried to detect salivary amylase which is a salivary gland associated antigen. Salivary amylase was seen in GC, but did not present the same distribution of immunoglobulins and complement components. This seems reasonable because of Warthin's tumour shows no evidence of autoimmune disease with salivary amylase as an autoantigen. The significance of the distribution of salivary amylase is still undetermined.

From the view of the multicentricity (Vistnes et al., 1968; Ibi et al., 1981), occurrence in lymph node (Bernier et al., 1958; Azzopardi et al., 1964; Dietert, 1975) and ontogenical peculiarity of parotid gland (Thackray et al., 1974), it has been supposed that Warthin's tumour arises from ectopic parotid salivary gland tissue within the lymph node. Some authors supposed that the lymphoid element of Warthin's tumour appears as a cellular response to the epithelial component. Allegra (1971) stated that the lymphoid stroma of Warthin's tumour was due to a cell-mediated immune mechanism of the delayed hypersensitivity type. Hsu et al. (1981) postulated that the lymphoid stroma of Warthin's tumour represented an exaggerated secretory immune response in consequence of the predominant existence of IgA plasma cells.

On the contrary, the author detected a majority of IgG positive plasma cells in the examined tumour tissues. The predominance of IgG plasma cells differs from predominance of IgA plasma cells in the mucosa of gastrointestinal tract. Although, like the duct of salivary gland (Korsrud et al., 1982), epithelial element stains for IgA and secretory component as previously reported (Korsrud et al., 1979), the lymphoid element of the tumours is not similar to the lymphatic tissue of the gastrointestinal tract.

From these observations, Warthin's tumour is thought to be composed of epithelial components with IgA-producing plasma cells in the propria mucosa and lymphoid stroma, which indicates that the origin of this tumour is the ectopic salivary gland in lymph node. Diamond et al. (1979) and Haward et al. (1982) reported that Warthin's tumour originated from ectopic salivary gland within the lymph node constituting predominant T lymphocyte. On the other hand, Tubbs et al. (1980) and Cossman et al. (1977) stated that the T-cell population decreases in Warthin's tumour. There seem to be differences in the ratios of T-cells and B-cells among individual cases.

As previously reported (Korsrud et al., 1984), IgE was recognized in GCs of many cases examined. IgE appears sometimes in tonsils and lymph nodes under ordinary circumstances (Tada et al., 1971). Furthermore, reticular staining of IgE was observed in the GCs of Kimura's disease (eosinophilic lymphfolliculoid granuloma) and parasite infection (Ishikawa et al., 1981; Mayerhofer et al., 1976). There is

a significant difference in number of IgE-positive GCs among the cases examined. The variability of the existence of IgE indicates that the appearance of IgE is succeeded by the formation of the tumor. There were no reports of hyperimmunoglobulinemia E in cases of Warthin's tumour and in one case examined in this report hyperimmunoglobulinemia E could not be recognized. The IgE distribution in Warthin's tumour seems to be due to local response. Electron microscopical observation revealed that IgE was distributed on the surface of labyrinth-formed FDCs in the same manner as complement components and C3 receptor. Although it had been considered that IgE did not activate the classical pathway of complement components, a recent report proposed that IgE could activate the classical pathway in some diseases (Saint-Remy, 1984). Concerning the distribution of the complement components, there was no difference between the IgE-positive GCs and IgE-negative GCs of Warthin's tumour. It is speculated that complements and complement receptors are related to the localization of IgE in GCs.

---

*Acknowledgements:* The author would like to take this opportunity to express his sincere gratitude to Professor Y. Imai, the Department of Pathology, Yamagata University School of Medicine and Professor T. Kasajima, the Department of Pathology, Tokyo Women's Medical College, for their critical comments and advice. Many thanks are also given to all staff members of the Department for their encouragement and also Associate Professor J. Petrich Barron, St Marianna University School of Medicine, for his revision of the manuscript.

---

## References

- Allegra S.R. (1971). Warthin's tumour: A hypersensitive disease? *Hum. Pathol.* 2, 403-420.
- Azzopardi J.G. and Hou L.T. (1964). The genesis of adenolymphoma. *J. Pathol. Bact.* 88, 213-218.
- Bernier J.L. and Bhaskar S.N. (1958). Lymphoepithelial lesions in salivary glands. *Cancer* 11, 1156-1179.
- Cossmann J., Deegan M.J. and Batsakis J.G. (1977). Warthin's tumour. B-lymphocyte within the lymphoid infiltrate. *Arch. Pathol. Lab. Med.* 101, 354-356.
- Diamond L.W. and Braylan R.C. (1979). Cell surface markers on lymphoid cells from Warthin's tumour. *Cancer* 44, 580-583.
- Dietert S.E. (1975). Papillary cystadenoma lymphomatousum (Warthin's tumour) in patient in a general hospital over a 24 year period. *Am. J. Clin. Pathol.* 63, 866-875.
- Farr A.G. and Nakane P.K. (1981). Immunohistochemistry with enzyme labeled antibodies: A Brief review. *J. Immunol. Methods.* 47, 129-144.
- Gajl-Peczalska K.J., Fish A.J., Neuwissen H.J., Frommel D. and Good R.A. (1969). Localization of immunological complexes fixing  $\beta$ 1c (C3) in germinal center of lymph nodes. *J. Exp. Med.* 130, 1367-1393.
- Gerdes J. and Stein H. (1982). Complement (C3) receptor on dendritic reticulum cells of normal and malignant lymphoid tissue. *Clin. Exp. Immunol.* 48, 348-352.
- Gerdes J., Stein H., Mason D.Y. and Ziegler A. (1983). Human dendritic reticulum cells of lymphoid follicle: Their antigen profile and their identification as multinucleated giant cell. *Virchows. Arch. (Cell Pathol.)* 42, 161-172.
- Howard D.R., Bagley C. and Batsakis J.G. (1982). Warthin's tumour: A functional immunologic study of the lymphoid cell component. *Am. J. Otolaryngol.* 3, 15-19.
- Hsu S.M., Hsu P.L. and Nayak R.N. (1981). Warthin's tumour: An immunohistochemical study on its lymphoid stroma. *Hum. Pathol.* 12: 251-257.
- Ibi A., Yokobayashi T., Kawasaki T. and Nakajima T. (1981). Bilateral Warthin's tumour: report of case and review of Japanese literature. *J. Oral. Surg.* 39, 362-366.
- Iida K. and Nussenzweig V. (1981). Complement receptor is an inhibitor of the complement cascade. *J. Exp. Med.* 153, 1138-1150.
- Imai Y., Terashima K., Matsuda M., Dobashi M., Maeda K. and Kasajima T. (1983). Reticulum cell and dendritic reticulum cell: Origin and function. *Recent Adv. Res.* 21, 51-81.
- Ishikawa E., Tanaka H., Kakimoto S., Tanaka S., Kirino Y., Sakata A. and Suzuki M. (1981). A pathological study on eosinophilic lymph follicular granuloma (Kimura's disease). *Acta Pathol. Jpn.* 31, 767-781.
- Kasajima T., Sato T., Yamakawa M., Masuda A. and Imai Y. (1986). Immunocytochemical study on immune complex and germinal center of synovial tissue of rheumatoid arthritis with special regard to complement and follicular dendritic cell. *Acta Pathol. Jap.* 36, 839-855.
- Klaus G.G.B., Humphery J.H., Kunkl A. and Dongworth D.W. (1980). The follicular dendritic cell: Its role in antigen presentation in the generation of immunological memory. *Immunological Rev.* 53, 3-28
- Klaus G.G.B. and Humphery J.H. (1977). The generation of memory cells. I. The role of C3 in the generation of B memory cells. *Immunology* 33: 31-40.
- Korsrud F.R. and Brandtzaeg P. (1979). Immunohistochemical studies on the epithelial and lymphoid component of Warthin's tumour. *Acta Otolaryngol. (Suppl.)* 360, 221-224.
- Korsrud F.R. and Brandtzaeg P. (1982). Characterization of epithelial elements in human major salivary glands by functional markers: Localization of amylase, lactoferrin, lysozyme, secretory component, and secretory immunoglobulins by paired immunofluorescence staining. *J. Histochem. Cytochem.* 655-666.
- Korsrud F.R. and Brandtzaeg P. (1984). Immunohistochemical characterization of cellular immunoglobulin and epithelial marker antigen in Warthin's tumour. *Hum. Pathol.* 15, 361-367.
- Mayerhofer G., Bazin H. and Gowans J.L. (1976). Nature of cells binding anti IgE in rats immunized with *Nippostrongylus Brasiliensis*. IgE synthesis in regional lymph nodes and concentration in mucosal mast cell. *Eur. J. Immunol.* 6, 537-545.
- Neiem M., Gerdes J., Mason D.Y. and Stein H. (1983). Production of monoclonal antibody reactive with human dendritic reticulum cells and its use in the immunohistological analysis of lymphoid tissue. *J. Clin. Pathol.* 36: 167-175.
- Nossal G.J.V., Abbot A., Mitchel J. and Lummus Z. (1968). Antigen capture in primary and secondary lymph follicle. *J. Exp. Med.* 127, 277-286.
- Saint-Remy J.M.R. (1984). Mechanism of activation of the

- classical pathway of complement by monoclonal IgE (DES). Restricted regulation of C4b by C4b-binding protein, *Eur. J. Immunol.* 14, 254-259.
- Tada T. and Ishizaka K. (1970). Distribution of  $\gamma$  E-forming cells in lymphoid tissue of the human and monkeys. *J. Immunol.* 104, 377-387.
- Thackray A.C. and Lucas R.B. (1974). Tumor of major salivary glands, second series, Fascicle 10, AFIP, Washington D.C.
- Thompson A.S., and Bryant H.C. (1950). Histogenesis of papillary cystadenoma lymphomatosum (Warthin's tumour) of the parotid salivary gland. *Am. J. Pathol.* 26, 807-849.
- Tubbs R.R., Sheibani K. and Weiss R.A. (1980). Immunohistochemistry of Warthin's tumor. *Am. J. Clin. Pathol.* 74, 795-797.
- Van Rooijen N. (1977). Immune complex in the spleen: three concentric area of immune complex trapping, their interrelationships and possible function. *J. Reticuloendoth. Soc.* 21, 143-152.
- Vistnes L.M. and Anylan A.J. (1968). Papillary cystadenoma lymphomatosum: Multiple and bilateral involvement. *JAMA* 204, 1140-1141.
- Yamakawa M. (1985). Immunocytochemical study in the function and structure of lymph follicle of thyroid tissue. *J. Jap. Soc., R.E.S.* 25, 15-32 (in Japanese).

Accepted September 2, 1987