

## Endogenous sex hormone and estrogen binding activity in thyroid cancer

Yutaka Imai<sup>1</sup>, Mitsunori Yamakawa<sup>1</sup>, Mikio Matsuda<sup>1</sup> and Takeshi Kasajima<sup>2</sup>

<sup>1</sup>Department of Pathology, Yamagata University, School of Medicine, Zao-lida, Nishinomae, Yamagata, Japan, 990-23 and

<sup>2</sup>Department of Pathology, Tokyo Women's Medical College, 10 Kawada-cho, Shinzuku-ku, Tokyo, Japan 162

**Summary.** The reactions of four anti-sex hormone (Estrone, Estradiol, Estriol and Testosterone) antisera were immunohistochemically examined in 109 cancerous and 80 normal and benign thyroid tissues. Four kinds of sex hormones were detected in the tumour cells of 61 cases (56%) of thyroid cancer and in the follicular epithelial cells of 4 cases (5%) of normal and benign thyroid tissues. Among the thyroid cancers, 54 female (61%) and 7 cases in males (33%) were positive for sex hormones. Furthermore, estrogen binding activity was screened histochemically in 36 thyroid tissues of various types, and detected not only in thyroid cancer (6/15 cases), but in normal and benign thyroid tissues (4/21 cases) as well. It was concluded that endogenous estradiol was located in thyroid cancers more frequently in females than in males and that there was estrogen binding activity in the cells of not only thyroid cancers, but also normal and benign thyroid tissues. This is the first report of the demonstration of endogenous sex hormones in thyroid cancer.

**Key words:** Endogenous sex hormone, Estrogen binding activity, Thyroid cancer, Immunohistochemistry

### Introduction

By using many techniques, estrogen binding activity (EBA) has been identified in a variety of not only normal (Kruzon, 1978; Bergqvist et al., 1985; Press et al., 1985), but also neoplastic tissues of human sex hormone target organs, including mammary cancer (Lee, 1978; Nenci, 1981; Nishiki et al., 1984; Poulsen et al., 1985), endometrial carcinoma (Spona, 1979) and prostatic cancer (Gustaffson, 1978). On the other hand, EBA has also been demonstrated in the neoplasms of organs which are not considered to be related to sex hormones,

for example, meningioma (Martuza et al., 1985), colonic cancer (McClendon et al., 1977), malignant melanoma (Fisher et al., 1976) and renal cell carcinoma (Batra et al., 1979).

Recently it has been reported that some types of thyroid cancers and normal thyroid tissues had EBA (Molteni et al., 1981; Clark et al., 1985). However, it has never been clear whether endogenous sex hormones actually correlated with thyroid cancer. Moreover, no immunohistochemical study of endogenous sex hormone in thyroid cancer tissues has been reported. In this study, we used histochemical techniques to examine whether there were endogenous sex hormones and EBA in various thyroid tissues.

### Materials and methods

#### *Thyroid tissues*

Human thyroid tissues obtained during thyroidectomy were immediately immersed in 10% formalin fixative, dehydrated and embedded in paraffin. As shown in Table 1, 109 thyroid cancer and 80 non-malignant thyroid tissues were screened for the purpose of detection of sex hormones. Ten cases with histologically normal thyroid tissues distant from adenoma nodules were selected from among many thyroidectomized tissues. The age of the 189 cases examined in this study ranged from 12 to 84 years of age (mean age: 46 years). The cases of thyroid cancers were classified according to WHO classification (International classification of histological typing of tumours. No. 11, Histological typing of tumours of the thyroid gland. 1974). Moreover, as shown in Table 2, 32 fresh-frozen thyroid tissues were prepared and used for the histochemical detection of EBA.

#### *Immunohistochemical study of endogenous sex hormones:*

Paraffin sections 4  $\mu$ m thick were prepared and stained with anti-sex hormones antisera by the indirect

Offprint requests to: Dr. Yutaka Imai, M.D., Department of Pathology, Yamagata University School of Medicine, Zao-lida, Yamagata 990-23, Japan

immunoperoxidase method of Farr and Nakane (1981). Rabbit anti-human Estrone ( $E_1$ ) (Teikoku Zoki Co., Japan), Estradiol ( $E_2$ ), Estriol ( $E_3$ ) and Testosterone (Oriental Yeast Co., Japan) antisera were used as first antisera, and peroxidase-linked swine anti-rabbit Immunoglobulin antiserum (DAKO patts a/s, Copenhagen, Denmark) as the second antiserum. These five types of antisera were used in their respective optimal dilution, that is,  $E_1$ : 1/400;  $E_2$ : 1/800;  $E_3$ : 1/400; Testosterone: 1/400 and the second antiserum: 1/30.

#### Histochemical study of EBA

$E_2$ -17 $\beta$ -hemisuccinate-bovine serum albumin (Seikagaku Kogyo Co., Japan) was labelled with horseradish peroxidase ( $E_2$ -BSA-HRP), as previously described (Farr and Nakane, 1981). Histochemical study of EBA using  $E_2$ -BSA-HRP was done according to the modified method of Walker et al. (1980). Thirty six fresh-frozen thyroid tissues were sliced 4  $\mu$ m thick by cryostat (Leitz, Germany). These cryostat sections were dried for 10 min. at room temperature, and washed in 0.01 M phosphate-buffered saline, pH7.4 (PBS) before being fixed in cooled acetone for 5 min at 4°. The sections were washed in PBS and immersed in periodate solution (114 mg/dl of distilled water) for 10 min at 4°.  $E_2$ -BSA-HRP was applied on the slides for 2 hr at 4° at a  $E_2$  concentration of 11 ( $\pm 10\%$ ) nmoles/ml, and the excess removed by washing. The sections were incubated in 100 ml of 0.05M tris-HCl buffer, pH7.6, containing 30 mg of 3,3'-diaminobenzidine tetrahydrochloride (DAB) (Dojin Chemical Co., Japan) and 15  $\mu$ l of  $H_2O_2$  (33%) for 10 min at room temperature. Finally, the sections were counterstained with methylgreen and mounted in resin.

#### Control study

Five human tissues from sex hormone target and non-target organs, namely from normal uterine endometrium in the proliferative phase, normal mammary gland, mammary cancer, normal testis and normal muscular tissue were used for the control study. These tissues were fixed in 10% formalin, embedded in paraffin, sliced 4  $\mu$ m thick and used for immunohistochemistry. Furthermore, a part of the human normal mammary gland and mammary cancer tissues were fresh-frozen and used for the control study of EBA. Moreover, to evaluate the specificity of each antiserum used in this study the following were carried out: (1) instead of the first step antisera, normal rabbit serum was used; (2) non-specific staining was checked by omitting the first antisera; (3) the first antisera were absorbed by corresponding antigens. Simultaneously, specific reactions to each antigen were checked by using the double immunodiffusion method (Ouchterlony); (4) the second step antiserum was omitted; (5) endogenous peroxidase activity was checked by using only DAB reaction.

## Results

#### Immunohistochemical study of endogenous sex hormones:

Immunohistochemically analyzed data are summarized in Table 1. In 61 (56%) out of 109 thyroid cancers, cancer cells reacted to four kinds of anti-sex hormone antisera. Immunostained cancer cells were mainly distributed in the area showing scirrhous cancer invasion. Sex hormones were recognized in the cytoplasm of thyroid cancer cells. Sixty-one cases of sex hormone positive cases included 54 females and 7 males. The former accounted for 61% (54/88) of the female thyroid cancers and the latter 33% (7/21) of the male ones. Among thyroid papillary carcinomas, the proportion of positive cases for the four antisera was 4.5% for  $E_1$ , 31% for  $E_2$  ( $z$ ,  $p < 0.01$ ) (Fig. 1a), 17% for  $E_3$  ( $z$ ,  $p < 0.08$ ) (Fig. 2) and 8.0% for Testosterone.  $E_2$  positive papillary carcinoma was found more often in females ( $z$ ,  $p < 0.08$ ). In male papillary carcinomas, no marked difference was found among the immunostainings of four sex hormones. On the other hand, in thyroid follicular carcinomas, the positive ratio shown were 5.6% in  $E_1$ , 11% in  $E_2$ , 22% in  $E_3$  and 5.6% in Testosterone. However, none of the thyroid follicular carcinomas in male patients were positive.

The age distribution of the 61 cases with thyroid cancers, stained with anti-sex hormone antisera, is shown in Fig. 3. Ages of these 61 patients ranged from 18 to 82 years (mean age: 48 years). Many positive cases were seen in the third (19 cases) and fourth decade (19 cases). As compared with the age distribution of thyroid cancers examined, positive cases in the third decade (83%), the fourth (58%), the seventh (56%) and the eighth (100%) showed high ratios. Of the 23 cases in the third decade, 19 cases were positive, but in 2 cases in the eighth decade both were positive.

Among non-malignant thyroid tissues, one case of thyroid follicular adenoma ( $E_2$ ), two cases of simple goiter ( $E_2$  or  $E_3$ ) and one case of normal thyroid tissue ( $E_3$ ) were positive. However, no immunostaining of sex hormones was found in the follicular epithelia of Graves's disease and chronic thyroiditis.

#### Histochemical study of EBA

Results are shown in Table 2. Among 15 thyroid cancers, EBA was found in 6 female cases (40%). Five cases (42%) out of 12 thyroid papillary carcinomas had EBA (Fig. 4), while only one case of the thyroid follicular carcinoma had EBA. Moreover, in 4 cases (19%) out of 21 non-malignant thyroid tissues EBA was found. All these 4 cases were female, that is, 2 cases were thyroid follicular adenoma, 1 was simple goiter and 1 was normal thyroid tissue.

#### Control study

In the normal uterine endometrium, normal mammary gland and mammary cancer, the immunostainings of  $E_1$ ,  $E_2$  and  $E_3$  were found in the cells of the

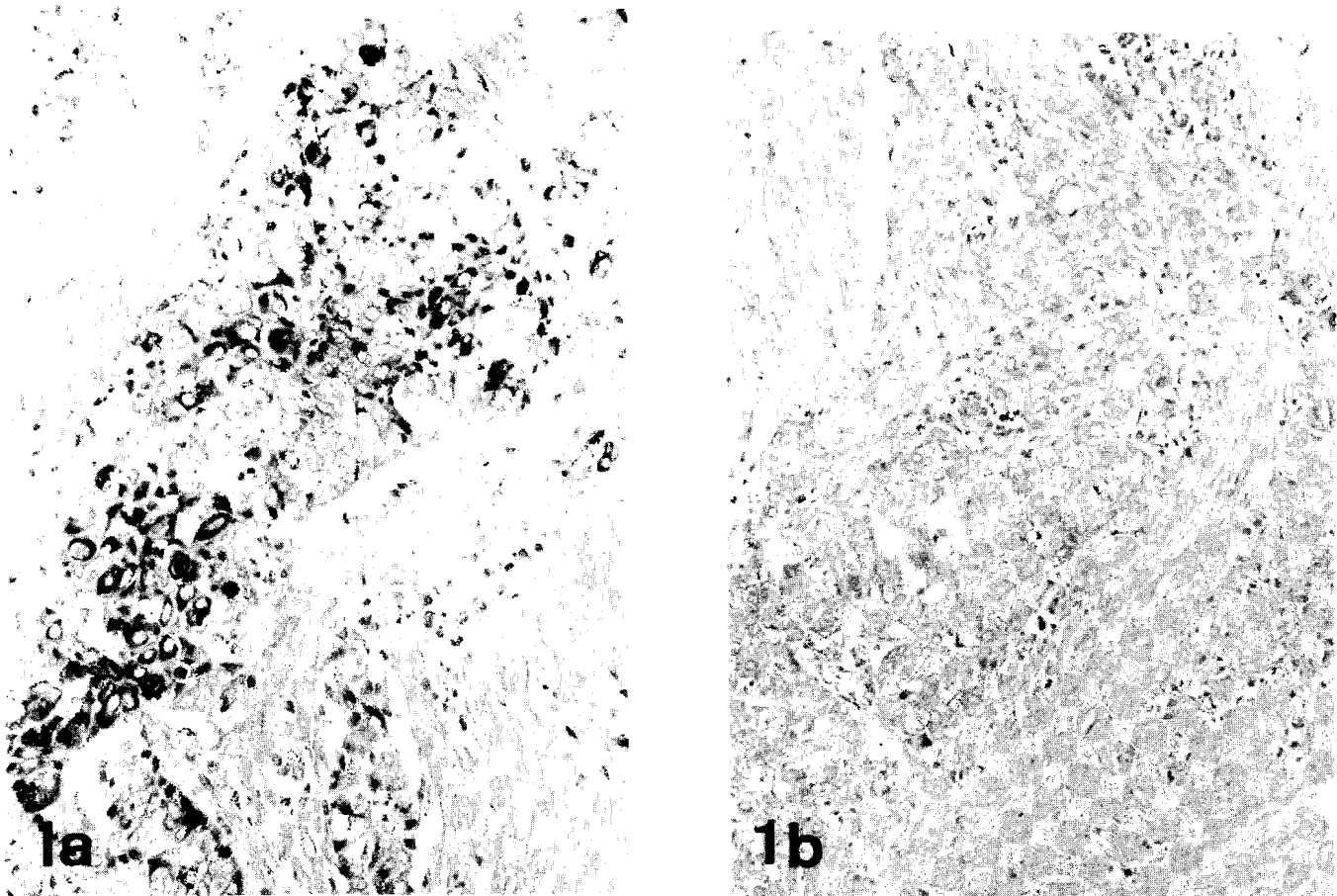


Fig. 1. Estradiol; papillary carcinoma. Many cancer cells are intensely stained (Fig 1. a), but no marked reaction is found against anti-Estradiol antiserum after absorption with Estradiol (Fig. 1b). Counterstained with methylgreen. Fig. 1a;  $\times 500$ , Fig. 1b;  $\times 300$

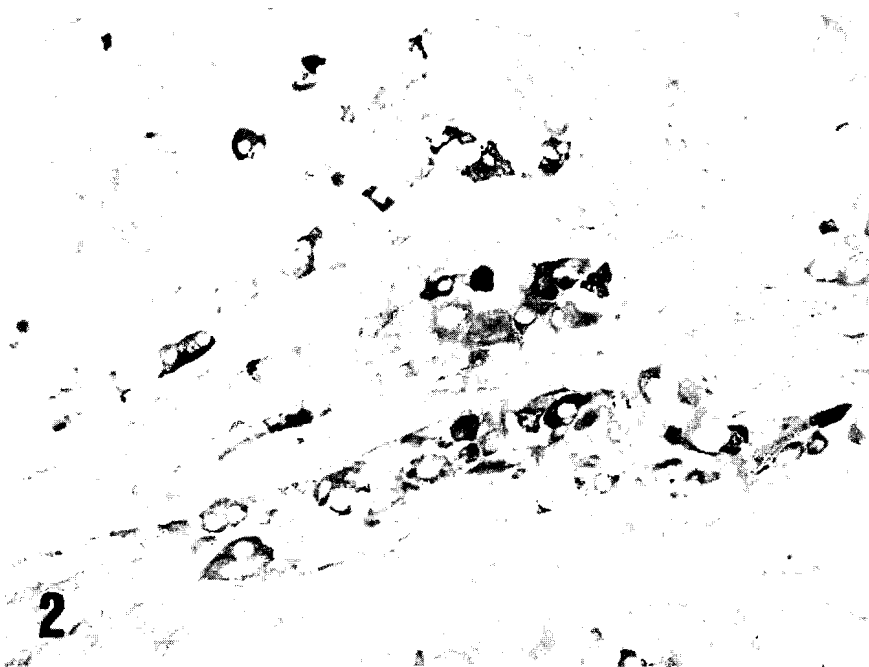


Fig. 2. Estriol; papillary carcinoma. Many cancer cells showing scirrhous invasion are clearly stained. Counterstained with methylgreen.  $\times 400$

## Sex hormone in thyroid cancer

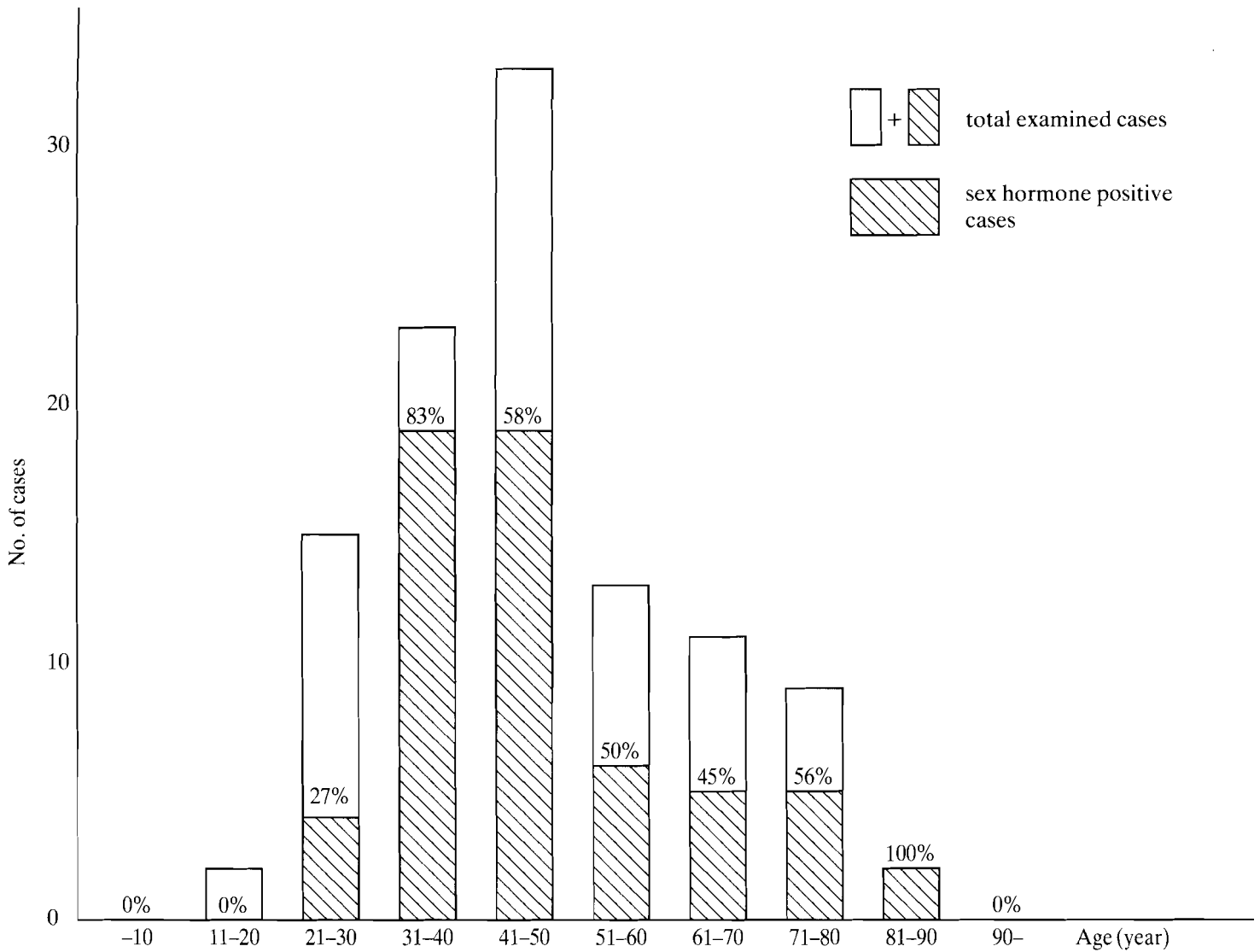


Fig. 3. Number of sex hormone positive-thyroid cancer by age decade. % indicates the ratio of sex hormone positive cases to examined cases for each decade.




Fig. 4. Estrogen binding activity; papillary carcinoma. Estrogen binding activity shown in many cancer cells. Counterstained with methylgreen.  $\times 160$

**Table 1.** Results of immunostaining of sex hormones in various thyroid diseases<sup>a)</sup>

Type of disease	No. of cases (F:M) <sup>b)</sup>	No. of positive cases (F:M) <sup>b)</sup>			
		Estrone	Estradiol	Estriol	Testosterone
Thyroid cancer					
papillary	88(70:18)	4( 3: 1)	27(25: 2) <sup>†</sup> §§	15(14: 1) <sup>††</sup>	7( 4: 3)
follicular	18(15: 3)	1( 1: 0)	2( 2: 0) <sup>†</sup>	4( 4: 0)	1( 1: 0)
others	3( 3: 0)	0	0	0	0
Total	109(88:21)	5( 4: 1)	29(27: 2) <sup>†</sup> §§	19(18: 1)	8( 5: 3)
Benign & Normal adenoma	35(30: 5)	0	1( 1: 0)	0	0
simple & nodular goiter	15(12: 3)	0	1( 1: 0) §	1( 1: 0) §	0
Graves' disease	12(10: 2)	0	0	0	0
chronic thyroiditis	8( 7: 1)	0	0	0	0
normal thyroid	10( 7: 3)	0	0	1( 1: 0) <sup>††</sup>	0
Total	80(66:14)	0	2( 2: 0)	2( 2: 0)	0

<sup>a)</sup> Positive findings on the tumour cells of follicular epithelial cells

<sup>b)</sup> (F:M) - (Female:Male) †:z, p<0.01 ††:z, p<0.08 §:χ<sup>2</sup>, p<0.01 §§:χ<sup>2</sup>, p<0.05

**Table 2.** Estrogen binding activity in human thyroid tissues<sup>a)</sup>

Type of disease	No. of cases (F:M) <sup>b)</sup>	No. of positive cases (F:M) <sup>b)</sup>
Thyroid cancer		
papillary	12(10: 2)	5( 5: 0)
follicular	3( 3: 0)	1( 1: 0)
Total	15(13: 2)	6( 6: 0)
Benign & Normal adenoma	5( 4: 1)	2( 2: 0)
simple & nodular goiter	4( 4: 0)	1( 1: 0)
Graves' disease	4( 3: 1)	0
chronic thyroiditis	3( 3: 0)	0
normal thyroid	5( 3: 2)	1( 1: 0)
Total	21(17: 4)	4( 4: 0)

<sup>a)</sup> positive findings on the tumour cells or follicular epithelial cells

<sup>b)</sup> (F:M)-(Female:Male)

endometrial glands, mammary ductuli and/or acini and mammary cancer cells, respectively. In normal testis the immunostaining of Testosterone was found in testicular interstitial cells. No immunostains, however, were detected in human normal muscular tissue. Moreover, no marked reaction in thyroid cancer tissue, which showed positive to untreated anti-E<sub>2</sub> antiserum, was found against anti-E<sub>2</sub> antiserum absorbed with E<sub>2</sub> (Fig. 1b). Furthermore, EBA was detected in fresh-frozen tissues of normal mammary gland and mammary cancer.

## Discussion

It has been recently reported that Estrogen Receptor (ER) activity was found not only in thyroid normal tissue but also in thyroid cancer, and that higher ER activity was apparently found in thyroid cancer (Clark et al.,

1985). However, it has not been clear whether thyroid cancer cells really correlated with endogenous sex hormones.

In this study, four sex hormones were found in cancer cells of 61 cases (56%) out of 109 thyroid cancers, while the epithelial cells of colloid follicles were positive in only 4 cases (5.0%) out of 80 non-malignant thyroid tissues. There was a marked difference in the incidence of the sex hormone positivity between cancerous and non-malignant thyroid tissue (E<sub>2</sub> and E<sub>3</sub>; X<sup>2</sup>, p< 0.01). Consequently, it can be concluded that the immunohistochemical stainings of endogenous sex hormones may be useful for a differential diagnosis between malignant and benign neoplastic tumors.

In our study, endogenous sex hormone positive cancer cells were chiefly distributed in the areas showing cancer invasion, so that sex hormones may be related to

cancer invasion and the growth of cancer cells. Paloyan et al. (1982) have reported that castration induced a marked reduction in the incidence of male rat thyroid cancer, so that Testosterone may also be an effective factor in the tumour growth of thyroid cancer.

We have also studied the relationship between endogenous sex hormone positive thyroid cancers and age distribution. Endogenous sex hormones were found in high ratios in the thyroid cancers of patients from 31 to 50 and from 71 to 90 years of age. Especially in the cases from 31 to 40, sex hormone positive ratios were significantly high. It has been reported that the prognosis for thyroid cancer patients under 50 years of age was better than that for patients over 50 years of age (Franssila, 1975), but no marked difference in sex hormone positivity between the two groups was found in our study.

The result of the histochemical study of 36 fresh-frozen thyroid tissues for the presence of EBA was that the cases with EBA comprised 40% of the 15 thyroid cancers, and 19% of the 21 non-malignant tissues examined. However, statistical analyses revealed no marked difference. Molteni et al. (1981) have measured ER binding protein in neoplastic thyroid tissues, and found the existence of ER binding protein in 2 out of 4 thyroid papillary carcinomas. Furthermore, Clark et al. (1985) have reported that ER was found in 14 out of 15 neoplastic thyroid tissues and 6 out of 15 non-neoplastic tissues. In our histochemical study, EBA was found in 6 (40%) of 15 thyroid cancers, 3 (33%) of 9 benign thyroid neoplasm and 1 (20%) of 5 normal and non-neoplastic thyroid tissues. Occurrence of EBA in thyroid neoplasms in our examination was lower than that in Clark's report. The frequency difference of EBA may be dependent on many factors, for example, technical procedures, race, ER specificity and so on. It is, however, certain that EBA was detected often in thyroid cancer although it cannot be easily concluded that thyroid cancer cells have a certain ER.

Anti-estradiol is used as the primary antiserum in the immunoperoxidase method to visualize endogenous estrogen-binding sites in potential hormone target organ tissues and tumors (Taylor et al., 1981; O'Connell and Said, 1983). The influence of fixation and processing is variously considered by many authors (Yamakawa et al., 1986). Van Bogaert already analysed the influence of fixatives and of fixation of ER cytochemistry (Van Bogaert et al., 1984; Van Bogaert, 1985). Similar contradictions are found in the field of ER immunocytochemistry. So, Raam et al. (1982) claimed that the most commonly used fixatives destroyed both the antigenicity and estrogen-binding capacity. However, Shimizu et al. (1983) and Katayama et al. (1984) demonstrated that E<sub>2</sub> bound in vivo survived the steps of processing (formalin fixation, paraffin embedding). Further, Nishi et al. (1987) have already reported that availability of the immunohistochemical staining of E<sub>2</sub> using formalin fixed paraffin sections with gastric cancer. Moreover, in their hands endogenous estrogen could not be demonstrated by the peroxidase anti-peroxidase method in frozen

sections of fresh tissue, but only after fixation. In our study, endogenous sex hormones could be prevented from the steps of tissue preparation processing (formalin fixation-paraffin embedding). Moreover, from the result of absorption test using primary antisera absorbed with specific antigen (E<sub>2</sub>), it seems that there is no doubt about the immunoreactivity. It suggested that immunohistochemical methods were probably not detecting ER directly, but multiple classes of steroid-binding sites, the presence of which may correlated with the presence of ER.

As a result of our histochemical study it can be concluded that there actually were endogenous sex hormones and EBA in thyroid cancer tissues, and endogenous E<sub>2</sub> were found more often in females than in males. Furthermore, the immunostainings of endogenous sex hormones may be helpful for a differential diagnosis between malignant and benign neoplasms.

## References

- Batra S., Coleen S. and Grundsell H. (1979). Progesterone and estradiol concentration in human kidney and renal cell carcinoma. *J. Steroid Biochem.* 11, 1535-1537.
- Bergqvist A., Ekman R. and Ljungberg O. (1985). Binding of estrogen and progesterone to human endometrium in the different phases of the menstrual cycle. A histochemical study. *Am. J. Clin. Pathol.* 83, 444-449.
- Clark O.H., Grend P.L., Davis M., Goretzki P.E. and Hoffman P.G. (1985). Estrogen and thyroid-stimulating hormone receptors in neoplastic and human thyroid tissue. *J. Surg. Res.* 38, 89-96.
- Farr A.G. and Nakane P.K. (1981). Immunohistochemistry with enzyme labeled antibodies. A brief review. *J. Immunol. Methods.* 47, 129-144.
- Fisher P., Neifeld G. and Lippmann M. (1976). Estrogen receptors in human malignant melanoma. *Lancet* 2, 337-338.
- Franssila K.O. (1975). Prognosis in thyroid carcinoma. *Cancer* 36, 1138-1146.
- Gustaffson J.Å. Eckman R. and Snochowski M. (1978). Correlation between clinical response to hormone therapy and steroid receptor content in prostatic cancer. *Cancer Res.* 38, 4345-4348.
- Katayama I., Shimizu M., Miura M., Maruyama M., Kobayashi M., Iino Y., Izuo M. and Wakatsuki S. (1984). Histochemical demonstration of endogenous estrogen in breast carcinomas: biochemical and clinical correlation. *Virchows Arch (Pathol Anat)* 402, 353-359.
- Kruzon R.M. (1978). Estrogen receptor immunocytochemistry. *J. Histochem. Cytochem.* 26, 803-808.
- Lee S.H. (1978). Cytochemical study of estrogen receptor in human mammary cancer. *Am. J. Clin. Pathol.* 70, 197-202.
- Martuza R.L., Miller D.C. and MacLaughlin D.T. (1985). Estrogen and progestin binding by cytosol and nuclear fractions of human meningiomas. *J. Neurosurg.* 62, 750-756.
- McClendon J., Appleby D. and Clandon D. (1977). Colonic neoplasms, tissue estrogen receptors and carcinoembryonic antigen. *Arch. Surg.* 112, 240-241.
- Molteni A., Warpeha R.L., Brigio-Molteni L. and Fors E.M. (1981).

- Estradiol receptor-binding protein in head and neck neoplastic and normal tissue. *Arch. Surg.* 116, 207-210.
- Nenci I. (1981). Estrogen receptor cytochemistry in human breast cancer. *Cancer* 48, 2674-2686.
- Nishi K., Tokunaga A., Shimizu Y., Yoshiyuki T., Wada M., Matsukura N., Tanaka N., Onda M. and Asano G. (1987). Immunohistochemical study of intracellular estradiol in human gastric cancer. *Cancer* 59, 1328-1332.
- Nishiki M., Amano K., Yamane M., Okumichi T. and Ezaki H. (1984). Estrogen receptors in human breast cancer detected by the fluorescent estradiol histochemical and dextran coated charcoal techniques. *Jap. J. Surg.* 14, 459-464.
- O'Connell M.D. and Said J.W. (1983). Estrogen receptors in carcinoma of the breast. A comparison of the dextran-coated charcoal, immunofluorescent and immunoperoxidase technique. *Am. J. Clin. Pathol.* 80, 1-5.
- Paloyan E., Hofmann C., Prinz R.A., Oslapas R., Shan K.H., Ku W.W., Ernst K. and Smith M. (1982). Castration induced a marked reduction in the incidence of thyroid cancers. *Surgery* 92, 839-848.
- Poulsen H.S., Ozzello L., King W.J. and Greene G.L. (1985). The use of monoclonal antibodies to estrogen receptor for immunoperoxidase detection of estrogen receptor in paraffin sections of human breast cancer tissue. *J. Histochem. Cytochem.* 33, 87-92.
- Press M.F., Nousek-Goebel N.A. and Greene G.L. (1985). Immunoelectron microscopic localization of estrogen receptor with monoclonal estrophilin antibodies. *J. Histochem. Cytochem.* 33, 915-924.
- Raam S., Nemeth H., Tamura D.S., O'Briain D.S. and Cohen J.L. (1982). Immunochemical localization of estrogen receptors in human mammary carcinoma using antibodies to the receptor protein. *Eur. J. Cancer Clin. Oncol.* 18, 1-12.
- Shimizu M., Osamu W., Miura M. and Katayama I. (1983). PAP immunoperoxidase method demonstrating endogenous estrogen in breast carcinoma. *Cancer* 52, 486-492.
- Spona J., Ulm R., Bieglmayer C. and Husslein P. (1979). Hormone serum levels and hormone receptor contents of endometria in women with normal menstrual cycles and patients bearing endometrial carcinoma. *Gynecol. Obstet. Invest.* 10, 71-80.
- Taylor C.R., Cooper C.L., Kurman R.J., Goebelsmann U. and Markland F.D. (1981). Detection of estrogen receptor in breast and endometrial carcinoma by the immunoperoxidase technique. *Cancer* 47, 2634-2640.
- Van Bogaert L.J. (1984). Present status of estrogen-receptor cytochemistry and its application in breast cancer research. *Acta Histochem.* 74, 37-43.
- Van Bogaert L.J. (1985). Present status of estrogen-receptor immunohistochemistry. *Acta Histochem.* 76, 29-35.
- Walker R.A., Cove D.H. and Howell A. (1980). Histological detecting of estrogen receptor in human breast carcinomas. *Lancet* 26, 171-173.
- Yamakawa M., Sato T., Matsuda M., Imai Y. and Kasajima T. (1986). Sex hormone and its receptor assay in thyroid cancer (in Japanese). *Pathology and Clinical Medicine* 4, 421-427.

Accepted July 1, 1988