

# **Non Hodgkin's lymphomas following chemoradiotherapy for Hodgkin's disease. Two new cases and a review of the literature**

**M.A. Marigil<sup>1</sup>, F.J. Pardo-Mindan<sup>1</sup>, B. Cuesta<sup>2</sup>, E. Rocha<sup>2</sup>, M.A. Idoate<sup>1</sup> and M.C. Gomez-Bezarez<sup>2</sup>**

Departments of Pathology<sup>1</sup> and Hematology<sup>2</sup>, Clínica Universitaria, Facultad de Medicina, Universidad de Navarra, Spain

**Summary.** Two patients developed non-Hodgkin's lymphoma (NHL) six and ten years after radiotherapy and chemotherapy for Hodgkin's disease nodular sclerosis type. The histological classification of the developing NHL for the two patients was: IgG (K) secreting lymphoplasmacytoid lymphoma of the stomach, and immunoblastic lymphoma of the cervical lymph nodes. Both patients responded well to conventional chemotherapy for NHL and are alive 22 and 5 months after the diagnosis of the secondary tumor. Forty eight cases of NHL after treatment for HD have been previously reported. We present a review of the literature of these cases, adding to this literature the first reported case of gastric lymphoplasmacytoid lymphoma under such circumstances.

**Key words:** Hodgkin's disease - Chemoradiotherapy - Lymphoplasmacytoid lymphoma - Immunoblastic lymphoma

## **Introduction**

With the use of high-dose wide-field irradiation, COPP and MOPP treatment modalities and surgical staging of patients, the survival of patients with Hodgkin's disease (HD), during the past 15 years, has dramatically improved (Kaplan, 1977; Durante et al., 1978; de Vita, 1981; Gottlieb, 1981; Mauch et al., 1983). However, for some years, it has been recognized that patients who have been treated with chemotherapy and/or radiotherapy are at an increased risk of developing secondary tumors, such as myelogenous leukemia (Cadman et al., 1977; Toland et al., 1978;

Coleman et al., 1982; Schmahl, 1982; Grunwald and Rosner, 1982; Glicksman et al., 1982; Bartolucci et al., 1983; Henry-Amar, 1983), acute lymphoblastic leukemia (Boucheix et al., 1979; Arkin et al., 1981; Nassar et al., 1982), non-Hodgkin lymphomas (Razis et al., 1959; Burns et al., 1971; Mims and Costanzi, 1974; Cardinali and Eusebio, 1975; Kirkorian et al., 1979; Spaulding et al., 1979; Lichtenstein et al., 1979; D'Agostino, 1979; Valagussa et al., 1980; Case record, 1980; Rubins et al., 1980; Andrieu et al., 1980; Kim et al., 1980; Lowenthal et al., 1981; Boivin and Hutchison, 1981; Coleman et al., 1982; Glicksman et al., 1982; Armitage et al., 1983; Henry-Amar, 1983; Miettinen et al., 1983; Jacquillat et al., 1984; Gowitt et al., 1985) and non-hematologic malignancies (Canellos et al., 1975; Valagussa et al., 1980).

In this report, we describe the clinical, histological, immunohistochemical and ultrastructural findings of a lymphoplasmacytoid lymphoma of the stomach and an immunoblastic lymphoma of the cervical lymph nodes which appeared in two patients, six and ten years respectively, following chemoradiotherapy treatment for HD.

## **Case reports**

### **Case 1**

A 13 year-old male who for weeks had experienced respiratory difficulty and asthenia was admitted to our hospital, in October 1976. The physical examination revealed lateral cervical and right axillary adenopathy. The WBC was elevated to  $22 \times 10^9/l$ , with 78% neutrophils, 16% lymphocytes, 4% monocytes and 1% eosinophils. Other laboratory data were unremarkable. X-Ray of the thorax revealed a right paratracheal lymphadenopathy causing tracheal stenosis. An excisional biopsy of a lateral cervical lymph node revealed broad collagen bands

## Secondary malignancy in Hodgkin's disease

separating the lymphoid tissue into nodules (Fig. 1). The cytologic pattern within the nodules was formed by few Reed-Sternberg cells, lymphocytes, eosinophils and numerous lacunar cells. (Fig. 1, inset). It was diagnosed as Hodgkin's disease, nodular sclerosis type. Subsequent staging laparotomy with splenectomy demonstrated nodular sclerosis Hodgkin's disease, stage IIa.

The patient was treated with six cycles of COPP (cyclophosphamide, vincristine, procarbazine, and prednisolone), given over 32 weeks, and supradiaphragmatic radiation of 4800 rads. Remission was achieved but the patient experienced a relapse six months later resulting in hepatic obstructive disease due to hilar adenopathy, demonstrated by CT-Scan. Over the succeeding six months he received six additional cycles of COPP and complete clinical remission was achieved for five years. In December 1983, he noted epigastric pain developing over a period of one month. Radiographic and gastroscopic examination showed a thickening of the gastric folds. A gastroscopic macrobiopsy revealed lymphoplasmacytoid lymphoma.

Subsequent gastrectomy with a Rous-en-Y esophagojejunostomy was performed. Eight abdominal lymph nodes were resected.

Macroscopically, an infiltration of the wall of the antrum and distal part of the body, which was 2 cm in thickness in its greatest dimension, was observed. The mucosa had thick prominent rugae with a moist, ruculent appearance (Fig. 2). The cut surface was homogeneous and had a fish-flesh appearance. The muscular layer was focally infiltrated (Fig. 3).

Microscopic examination revealed a diffuse cellular infiltrate of the mucosa and submucosa and focal infiltrates in the muscular layer, which consisted of a population of small lymphoid cells with round nuclei and inconspicuous nucleoli (Fig. 4). The lymphocytes were small and noncleaved. Some lymphocytes had undergone plasmacytoid differentiation as evidenced by lateralization of the nucleus, coarse chromatin crumpling and increased basophilic cytoplasm (Fig. 5).

Immunoperoxidase stain for immunoglobulin staining of antibodies to Kappa light chain and heavy chain IgG was positive.

The tumor was diagnosed as Lennert's lymphoplasmacytoid lymphoma (Rappaport's well differentiated lymphocytic lymphoma). The margins of the excised stomach were free of tumor. Abdominal lymph nodes were not infiltrated by the lymphoma.

Five cycles of CHOP (cyclophosphamide, adriamycin, vincristine, prednisone) chemotherapy were initiated and well tolerated. Twenty-two months following diagnosis of the non-Hodgkin's lymphoma there was complete remission.

### Case 2

A 46 year-old female was admitted to our hospital in January 1975 because of asthenia, fever, night sweats, pruritus and weight loss. Physical examination revealed bilateral axillar adenopathies. Blood chemistry determinations were within normal limits as was the X-ray

of the thorax. Microscopic examination of the axillary lymph node revealed Hodgkin's disease, nodular sclerosis type, similar to that seen in case 1.

Subsequent staging laparotomy with splenectomy demonstrated Hodgkin's disease, nodular sclerosis type, stage II<sub>B</sub>.

The patient was treated with six cycles of COPP given over 32 weeks, and supradiaphragmatic radiation of 4800 rad. Complete remission was achieved in September 1975. Ten years after complete remission, she presented a left cervical adenopathy (4x4 cm). A biopsy of the node showed a diffuse infiltration. The predominant cell type had the appearance of an immunoblast containing a large vesicular nucleus with a thick nuclear membrane and a prominent central nucleoli and deeply staining pyroninophilic cytoplasm with a distinct nuclear hof. The tumor was diagnosed as Lennert's immunoblastic lymphoma (Rappaport's poorly differentiated histiocytic lymphoma (Fig. 6). Immunoperoxidase stain for immunoglobulin staining of antibodies to Kappa light chain and heavy chain IgM was positive. After classification of the tumor as stage I<sub>A</sub>, six cycles of CHOP were initiated and complete remission was achieved five months following diagnosis of the NHL.

---

**Fig. 1.** Hodgkin's disease sclerosis type. Bands of collagen separate nodules. (H.E., x40). Inset: lacunar cells (H.E. x750) (Case 1).



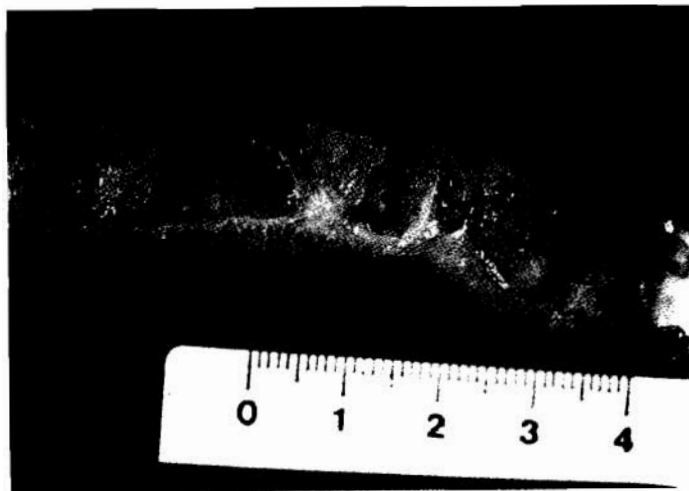
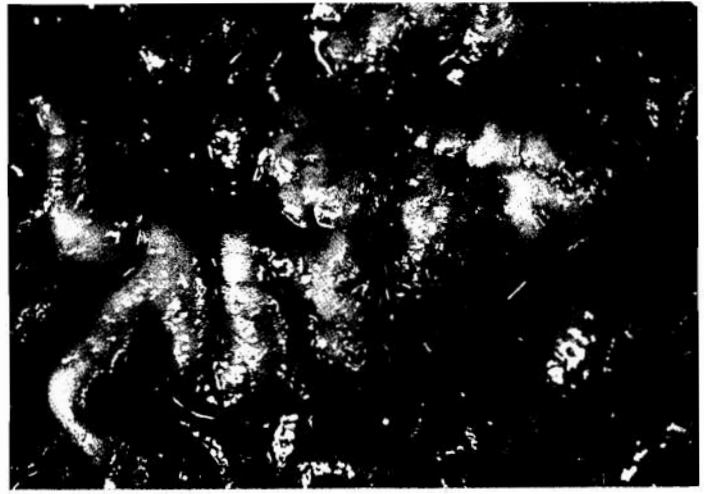
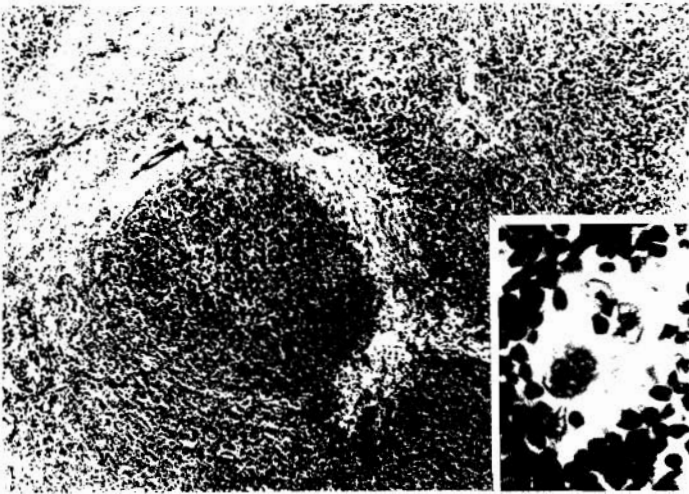
**Fig. 2.** Local infiltration with thick prominent rugae having a slightly granular or cobblestone surface. (Case 1).

**Fig. 3.** Cut surface showing a diffuse infiltrate of mucosa and submucosa. (Case 1).

**Fig. 4.** Diffuse cellular infiltrate of a population of small lymphoid cells in mucosa and submucosa (H.E., x 45). (Case 1).

**Fig. 5.** Plasmacytoid differentiation (H.E., x 1,200). (Case 1).

**Fig. 6.** High-power view of immunoblastic lymphoma. Individual tumor cells have large vesicular nuclei, prominent central nucleoli and abundant cytoplasm (H.E., x 700). (Case 2).



## Secondary malignancy in Hodgkin's disease

**Table 1.** Reported cases of non-Hodgkin's lymphoma (NHL) occurring in patients treated for Hodgkin's disease (HD).

REFERENCES	CASES	TYPE OF HD	TREATMENT OF HD	TIME TO ONSET OF NHL (mo)	TYPE OF NHL
Razis et al., 1959	2	NS	—	—	HL(2)
Burns et al., 1971	1	G	—	—	HL
Mims and Costanzi, 1974	1	MC	XRT+CX	48	HL
Cardinali and Eusebio, 1975	1	MC	CX	156	DPDL
Krikorian et al., 1979	6	NS(6)	XRT+CX(6)	44-124	ML UL(4) HL(2)
Spaulding et al., 1979	1	NS	CX	48	HL
Lichtenstein et al., 1979	1	MC	XRT+CX	36	HL
D'Agostino, 1979	1	LP	XRT	79	HL
Valagussa et al., 1980	1	—	XRT+CX	16	HL
Case record, 1980	1	NS	XRT+CX	132	UL
Rubins et al., 1980	1	MC	XRT+CX	96	UL
Andrieu et al., 1980	1	MC	XRT+CX	—	Burkitt
Kim et al., 1980	3	MC(2) LP(1)	XRT(1) CX(2)	36-72	DPDL(2) HL(1)
Lowenthal et al., 1981	1	NS	XRT+CX	39	HL
Boivin and Hutchison, 1981	1	MC	XRT+CX	36	LS
Coleman et al., 1982	8	—	XRT+CX(6) XRT(2)	44-180	UL(5) HL(3)
Glicksman et al., 1982	1	—	—	—	—
Armitage et al., 1983	5	NS(4) MC(1)	XRT+CX(1) CX(2) XRT(2)	12-54	HL(4) LL(1)
Henry-Amar, 1983	3	—	XRT+CX(2) XRT(1)	120-180	HL(3)
Miettinen et al., 1983	1	LP	XRT	72	HL
Jacquillat et al., 1984	4	NS(2) MC(1) LP(1)	XRT+CX(3) CX(1)	28-180	HL(4)
Gowitt et al., 1985	3	NS(2)	XRT+CX(1) CX(2)	17-106	T-cell(3)
Our case	2	NS(2)	XRT+CX(2)	74-120	LPL HL

LP=Lymphocyte predominance; NS=Nodular sclerosis;MC=Mixed cellularity.  
XRT= Radiotherapy; CX=Chemotherapy; PG=Paragranuloma; G=Granuloma.  
UL=Undifferentiated lymphoma; HL=Histiocytic lymphoma; ML=Mixed lymphoma.  
DPDL=Difuse poorly differentiated lymphocytic; LL=Lymphoblastic lymphoma.  
LPL=Lymphoplasmocytoid lymphoma; LS=Lymphosarcoma.

## Secondary malignancy in Hodgkin's disease

### Discussion

The appearance of a second malignancy, especially of the lymphoid type, in patients previously treated for HD occurs more frequently than would be expected by chance alone (Armitage et al., 1983). Acute non-lymphoblastic leukemia and NHL are the most frequent secondary neoplasms (Armitage et al., 1983). Incidence of leukemias is nearly two-fold greater than incidence of NHL (Coleman et al., 1983). Table 1 summarizes the literature describing the main features of 48 NHL occurring malignancy which has been estimated between 1% and 4% (Krikorian et al., 1979; Coleman et al., 1982; Armitage et al., 1983). The latent period varies between five and ten years after treatment for HD (Krikorian et al., 1979; Armitage et al., 1983). The subtypes of HD developing secondary malignancies following treatment are: nodular sclerosis, 54%; mixed cellularity, 33%; lymphocytic predominance 13% (Rubins et al., 1980; Andrieu et al., 1980; Boivin et al., 1981; Coleman et al., 1982; Glicksman, 1982; Miettinen et al., 1983; Armitage et al., 1983; Henry-Amar, 1983; Jacquillat et al., 1984). Secondary malignancies following treatment for HD lymphoid depletion type have not been described, probably because patients with this subtype of HD have low incidence and survival rates. The types of NHL described following treatment for HD are: histiocytic lymphoma, 60%, and undifferentiated lymphoma, 25%, the remaining 15% consisting of other miscellaneous types of NHL, but, to the best of our knowledge, lymphoplasmacytoid lymphoma has not been previously described under such conditions (Razis et al., 1959; Burns et al., 1971; Mims and Constanzi, 1974; Cardinali and Eusebio, 1975; Krikorian et al., 1979; Spaulding et al., 1979; Lichtenstein et al., 1979; D'Agostino, 1979; Valagussa et al., 1980; Case record, 1980; Rubins et al., 1980; Andrieu et al., 1980; Kim et al., 1980; Lowenthal et al., 1981; Boivin and Hutchison, 1981; Coleman et al., 1982; Glicksman et al., 1982; Armitage et al., 1983; Henry-Amar, 1983; Miettinen et al., 1983; Jacquillat et al., 1984; Gowitt et al., 1985).

Thus, the IgG-Kappa lymphoplasmacytoid lymphoma here described is the first reported case of this tumor type developing in patients following treatment for HD. Of added interest is the exclusive involvement of the stomach in our first case. Other cases have been described in which the stomach was affected by a secondary tumor, but involvement of other organs was always noted (Spaulding et al., 1979; Krikorian et al., 1979; D'Agostino 1979; Armitage et al., 1983). Lowenthal et al (1981) considered that abdominal radiotherapy might produce a local carcinogenic effect, thus producing the high incidence of NHL involving the digestive tract in these patients (Razis et al., 1959; D'Agostino, 1979; Krikorian et al., 1979; Spaulding et al., 1979; Case records, 1980; Rubins et al., 1980; Jacquillat et al., 1984).

It appears that the areas in which there is an overlap between the upper mantle and inverted Y are prone to develop lymphomas (D'Agostino, 1979; Kim et al., 1980; Armitage et al., 1983).

Of the nine reported lymphomas where the cell type was determined, three were B cell lymphomas (Krikorian et al., 1979; Case Records, 1980; Armitage et al., 1983) and the other six were T cell lymphomas (Lowenthal et al., 1981; Armitage et al., 1983; Gowitt et al., 1985).

A possible explanation for the occurrence of a second malignancy in patients treated for HD is an immunological defect associated with this disease which is apparently aggravated by therapy (Lowenthal et al., 1981). A second malignancy is more likely to occur when treatment consists of radiotherapy and chemotherapy (Burns et al., 1971; Cardinali and Eusebio, 1975; Krikorian et al., 1979; Lichtenstein et al., 1979; Valagussa et al., 1980; Case Records, 1980; Rubins et al., 1980; Andrieu et al., 1980; Lowenthal et al., 1981; Boivin and Hutchison, 1981; Coleman et al., 1982; Armitage et al., 1983; Henry-Amar, 1983; Jacquillat et al., 1984; Gowitt et al., 1985). On the other hand, there have been reports concerning patients who received only one treatment modality, radiotherapy (D'Agostino, 1979; Kim et al., 1980; Coleman et al., 1982; Armitage et al., 1983; Henry-Amar, 1983; Miettinen et al., 1983) or chemotherapy and who subsequently developed a secondary tumor (Mims and Constanzi, 1974; Spaulding et al., 1979; Kim et al., 1980; Armitage et al., 1983; Jacquillat et al., 1984; Gowitt et al., 1985). In the group of patients treated with combined therapy, the incidence of a second malignancy is 14-fold greater when patients are compared with matched controls (De Vita, 1981). However, in patients treated with either radiotherapy or chemotherapy alone the incidence of a second malignancy exceeds only slightly the expected number (De Vita, 1981).

Interestingly, in two out of three large published series of patients treated for HD (Nelson et al., 1981; Colman and Dixon, 1982; Glicksman et al., 1982) no case of NHL was observed and, in the remaining study, one case of NHL was identified among 798 patients treated for HD (Glicksman et al., 1982). Probably, the full extent of the real risk in developing secondary malignancies following treatment for HD will not be appreciated for another decade.

### References

- Andrieu J.M., Cassasus P., Degos L., Preud'homme J.L., Berger R. and Flandrin C. (1980). Burkitt's lymphoma occurring six years after Hodgkin's disease. *Acta Haematol.* 63, 330-332.
- Arkin C.F., Kurtz S.R. and Sparks J.T. (1981). Acute B-cell leukemia occurring with Hodgkin's disease. *Am. J. Clin. Pathol.* 75, 406-410.
- Armitage J.O., Dick F.R., Goeken J.A., Foucar K. and Gingrich R.D. (1983). Second lymphoid malignant neoplasms occurring in patients treated for Hodgkin's disease. *Arch. Intern. Med.* 143, 445-450.
- Bartolucci A.A., Lin C.H., Durant J.R. and Gams R.A. (1983). Acute myelogenous leukemia as a second malignant neoplasm following the successful treatment of advanced Hodgkin's disease. *Cancer* 52, 2209-2213.
- Boivin F.J. and Hutchinson G.B. (1981). Leukemia and other cancers after radiotherapy and chemotherapy for Hodgkin's disease. *J. Natl. Cancer Inst.* 67, 751-758.

*Secondary malignancy in Hodgkin's disease*

- Boucheix C., Zittoun R., Reynes M., Diebold J., Bernadou A. and Bilski-Pasquier G. (1979). Atypical T-cell leukemia terminating Hodgkin's disease. *Cancer* **44**, 1403-1407.
- Burns C.P., Stjernholm R.L. and Kellermeyer R.W. (1971). Hodgkin's disease terminating in acute lymphosarcoma cell leukemia: A metabolic study. *Cancer* **27**, 806-811.
- Cadman E.C., Capizzi R.L. and Bertino J.R. (1977). Acute non lymphocytic leukemia. A delayed complication of Hodgkin's disease therapy: Analysis of 109 cases. *Cancer* **40**, 1820-1896.
- Canellos G.P., de Vita V.T., Arsenau J.C., Whang-Peng J. and Johnson R.E.C. (1975). Second malignancies complicating Hodgkin's disease in remission. *Lancet* **i**, 947-949.
- Cardinali G. and Eusebi V. (1975). Hodgkin's disease and nodular lymphoma. *Haematologica* **60**, 236-240.
- Case records of the Massachusetts General Hospital (1980). *N. Eng. J. Med.* **302**, 389-395.
- Coleman C.N., Burke J.S., Varghese A., Rosenberg S.A. and Kaplan S.L. (1982). Secondary leukemia and non-Hodgkin's lymphoma in patients treated for Hodgkin's disease. In: *Advances in Malignant Lymphomas: Etiology, Immunology, Pathology and Treatment*. Kaplan H.S. and Rosenberg S.A. (eds). Academic Press. New York. pp 259-276.
- Colman Ch. A. Jr. and Dixon D.O. (1982). Second malignancies complicating Hodgkin's disease. A Southwest Oncology Group 10 years follow-up. *Cancer Treat. Rep.* **6**, 1023-1033.
- D'Agostino R.S. (1979). Non-Hodgkin's lymphoma after radiotherapy for Hodgkin's disease. *N. Eng. J. Med.* **301**, 1289.
- De Vita V.T. Jr. (1981). The consequences of the chemotherapy of Hodgkin's disease: The 10<sup>th</sup> David. Kafnofsky Memorial Lecture. *Cancer* **47**, 1-13.
- Durant J.R., Gams R.A., Velez Garcia E., Bartolucci A., Witschaffer D. and Dorfman R. (1978). BCNU, velban, cyclophosphamide, procarbazine and prednisone (BVCP) in advanced Hodgkin's disease. *Cancer* **25**, 2101-2110.
- Glicksman A.S., Pajak T.F., Gottlieb A., Niessen N., Stutzman L. and Cooper M.R. (1982). Second malignant neoplasms in patients successfully treated for Hodgkin's disease: A cancer and Leukemia Group B Study. *Cancer Treat. Rep.* **66**, 1035-1044.
- Gottlieb A.J., Bloomfield C.D. and Glicksman A.S. (1981). Nitrosoureas in the therapy of Hodgkin's disease. In: *Nitrosoureas: Current status and New Developments*. Prestayk A.S., Cooke S.T., Baker L.H., Carter S.K. and Scheir P.S. (eds). Academic Press. New York.
- Gowitt G.T., Chan W.C., Brynes R.K. and Heffner L.T. (1985). T-cell lymphoma following Hodgkin's disease. *Cancer* **56**, 1191-1196.
- Grunwald H.W. and Rosner F. (1982). Acute myeloid leukemia following treatment of Hodgkin's disease. A review. *Cancer* **50**, 676-683.
- Henry-Amar M. (1983). Second cancers after radiotherapy and chemotherapy for early stages of Hodgkin's disease. *J. Natl. Cancer Inst.* **71**, 911-916.
- Ibbotson R.M., Revell P.A., Mollan E.A. and Minton M.J. (1977). The simultaneous presentation of Hodgkin's disease and myeloma. *Postgrad. Med. J.* **53**, 52-53.
- Jacquillat C., Khayat D., Desprez-Curely J.P., Weil H., Brocheriou C., Auclerc G., Chamseddine N. and Bernard J. (1984). Non-Hodgkin's lymphoma occurring after Hodgkin's disease. Four new cases and a review of the literature. *Cancer* **53**, 459-462.
- Kaplan H.S. (1977). Hodgkin's disease. Multidisciplinary contributions to the conquest of a neoplasm. *Radiology* **123**, 551-558.
- Kim H.D., Bedetti C.D. and Boggs D.R. (1980). The development of non-Hodgkin's lymphoma following therapy for Hodgkin's disease. *Cancer* **46**, 2596-2602.
- Krikorian J.A., Burke J.S., Rosenberg S.A. and Kaplan H.S. (1979). Occurrence of non-Hodgkin's lymphoma after therapy for Hodgkin's disease. *N. Eng. J. Med.* **300**, 452-458.
- Lichtenstein A., Levine A.M., Lukes R.J., Cramer A.D., Taylor C.R., Lincoln T.L. and Feinstein D.I. (1979). Immunoblastic sarcoma. A clinical description. *Cancer* **43**, 343-352.
- Lowenthal R.M., Harlow R.W.H., Mead A.E. and Tuck Challis D.R. (1981). T-cell non-Hodgkin's lymphoma after radiotherapy and chemotherapy for Hodgkin's disease. *Cancer* **48**, 1586-1589.
- Mauch P.M., Weisntein H., Botnick L., Belli J. and Cassady J.R. (1983). An evaluation of long-term survival and treatment complications in children with Hodgkin's disease. *Cancer* **51**, 925-932.
- Miettinen M., Franssila K.O. and Saxen E. (1983). Hodgkin's disease, lymphocytic predominance nodular. Increase risk for subsequent non-Hodgkin lymphomas. *Cancer* **51**, 2293-2300.
- Misms C.H. and Costanzi J.J. (1974). Conversion of Hodgkin's disease to lymphoblastic lymphosarcoma. *Oncology* **29**, 238-243.
- Nassar V.H., Jacobs J., Mirra S.S., Pandya K.J., Schwartz S. and Ennett J.M. (1982). Burkitt cell leukemia following therapy for Hodgkin's disease. *Am. J. Hematol.* **12**, 73-76.
- Nelson D.F., Cooper S., Weston M.G. and Rubin P. (1981). Second malignant neoplasms in patients treated for Hodgkin's disease with radiotherapy of chemotherapy. *Cancer* **48**, 2386-2393.
- Razis D.V., Diamond H.D. and Craver L.F. (1959). Hodgkin's disease associated with other malignant tumors and certain non-neoplastic disease. *Am. J. Med. Sci.* **238**, 327-335.
- Rubins J., Sischy B. and Lee J.C.K. (1980). Non-Hodgkin's lymphoma following treatment for Hodgkin's disease. *Am. J. Clin Pathol.* **74**, 696-700.
- Schmahl D., Habs M., Lorenz M. and Wagner I. (1982). Occurrence of second tumors in man after anticancer drug treatment. *Cancer Treat. Rev.* **9**, 167-194.
- Spaulding M.B., Mogavero H. and Montes M. (1979). Non-Hodgkin lymphoma after chemotherapy for Hodgkin's disease. *N. Eng. J. Med.* **301**, 384-385.
- Toland D.H., Coltman C.A. and Moon T.E. (1978). Second malignancies complicating Hodgkin's disease: The Southwest Oncology Group Experience. *Cancer Clin. Trials* **1**, 27-33.
- Valagussa P., Santoro A., Kenda R., Bellani F.F., Franchi F., Baufi A., Rilke F. and Bonadonna G. (1980). Second malignancies in Hodgkin's disease: a complication of certain forms of treatment. *Br. Med. J.* **280**, 216-219.