

HBsAg, HBcAg and Delta-Ag in liver tissue: simultaneous visualization in a single tissue section by triple immunostaining

Fabio Facchetti, Regina Tardanico, Maria F. Bonetti, Agostino Guerini and Francesco Callea
Histochemistry Unit, 1st Department of Pathology, Spedali Civili of Brescia, 25100 Brescia, Italy

Summary. The distribution pattern of HBsAg, HBcAg and Delta-Ag was investigated by immunohistochemistry in a series of paraffin embedded liver tissue specimens from 45 subjects with serum HBsAg and anti-Delta antibody positivity.

An indirect immunoperoxidase technique was used. Stains for HBsAg, HBcAg and Delta-Ag were alternatively carried out on serial tissue sections and, for the first time, consecutively in a single section (triple immunostaining). Simultaneous presence of all antigens occurred in 7 out of 45 cases, and of two antigens (HBsAg and Delta-Ag) in the remaining 38. Two antigens (either HBsAg and HBcAg or HBcAg and Delta-Ag) could also be shown in the same cell.

A series of new observations was forwarded by the successful application of triple immunostaining in the present series: 1) high frequency of simultaneous presence of HBcAg and Delta-Ag (7 out of 45 cases = 16%); 2) cytoplasmic localization of Delta-Ag; 3) localization of HBcAg on the cell membrane of HBsAg positive Ground-Glass (G-G) hepatocytes; 4) Ground-Glass appearance of hepatocytic cytoplasm associated with exclusive content of HBcAg (HBcAg-Ground-Glass: a new variant of G-G-hepatocytes).

Key words: Viral hepatitis - HBsAg - HbcAg - Delta-Ag - Liver - Immunohistochemistry

Introduction

The Delta agent (Delta-Ag) is a small RNA virus which requires the helper function of hepatitis B virus (HBV) for its replication (Rizzetto, 1983). It is highly pathogenic, its presence in the liver being almost invariably associated with severe liver disease.

In acute infection, Delta seems to inhibit the synthesis of hepatitis B surface antigen (HBsAg); in chronic Delta carriers there seems to be an exclusion between Delta and hepatitis B core antigen (HBcAg) (Rizzetto and Verme, 1985).

To evaluate the relationship between these three antigens in liver tissue we examined by immunohistochemistry a series of Delta positive liver biopsies. To that purpose serial sections were alternatively stained for HBsAg, HBcAg and Delta-Ag; in addition a triple immunostaining was successively applied on a single section for simultaneous visualization of antigens. The successful application of the latter method yielded the discovery of new distribution patterns of these antigens within hepatocytes.

Materials and methods

Liver biopsies were obtained from 45 patients with serum positivity for HBsAg and anti-Delta antibodies.

Tissue specimens were fixed in 10% formalin and embedded in paraffin. Four micron thick sections were stained for routine histological diagnosis. Further sections were used for immunohistochemical studies. Serial sections were stained for HBsAg, HBcAg and Delta-Ag by indirect immunoperoxidase techniques as follows:

Offprint requests to: Francesco Callea M.D. Ph.D, Histochemistry Unit, 1st Department of Pathology, Spedali Civili, 25100 Brescia, Italy

HBsAg, HBcAg, Delta-Ag in liver tissue

1. Alternative staining for HBsAg, HBcAg, Delta-Ag in serial sections

A. Staining for HBsAg

1. Paraffin sections were mounted in water and dried overnight at 37° C.
 2. Deparaffinization was carried out with xylene (30 min + 15 min).
 3. After Absolute alcohol (5 min + 5 min), sections were incubated in methanol + H2O2 (10%), for 30 min at room temperature (RT), to block endogenous peroxidase.
 4. Sections were kept in alcohol 95" for 5 min, distilled water for 3 min, phosphate buffer saline (PBS) for 5 min.
 5. Sections were incubated in 100 ml PBS containing 50 mg Pronase (Boehringer) for 10 min at RT.
 6. Washing in PBS (3 x 3 min).
 7. A swine serum (1:20 in PBS) was applied for 7 min.
 8. A rabbit anti-HBsAg (Behringwerke), 1:100 in PBS, was used as primary antibody for 30 min at RT.
 9. Washing in PBS (3 x 3 min).
 10. A swine antirabbit IgG antibody (Dako) was used as bridge layer, 1:40 in PBS, for 30 min at RT.
 11. Washing in PBS (3 x 3 min).
 12. A rabbit PAP-complex (Dako) was the third layer, diluted 1:100 in PBS, applied for 30 min at RT.
 13. Washing in PBS (3 x 3 min).
 14. Chromogen reaction was developed in a 3-3 diaminobenzidine tetrahydrochloride 97% (Poliscience) solution (40 mg in 100 ml PBS + H2O2 0.2%) for 5 min at RT.
 15. Washing in PBS (3 x 3 min).
 16. Counterstaining with Mayer Hematoxylin, 40 sec.
 17. Washing in tap water, 5 min.
 18. Sections were dehydrated, cleared and mounted in synthetic medium.
- B. Staining for Delta-Ag.** Steps from 1 to 6 as in A.
7. A rabbit serum (1:20 in PBS) was applied for 7 min.
 8. As a first layer, a human IgG anti-Delta (kindly provided by Dr. Rizzetto, Turin), was used at a dilution of 1:5000 in PBS for 30 min at RT.
 9. Washing in PBS (3 x 3 min).
 10. As a second layer, a rabbit anti-human IgG peroxidase conjugated antiserum (Dako), diluted 1:40 in PBS, was applied for 30 min at RT.
- Thereafter, steps 13 to 18 were followed as in A.
- C. Staining for HBcAg.** All steps were as in A. except for n° 8, where a rabbit anti HBcAg antiserum (Dako), 1:500 in PBS, was used as primary antibody.

2. Successive staining for HBsAg, HBcAg, Delta-Ag in a single section

D. Triple immunostaining. The triple immunostaining was carried out **stepwise** on a single tissue section as follows:

1-15. Staining for HBsAg was as 1 to 15 in A.

16. Sections immunostained for HBsAg were incubated in 0.1 M glycine solution in distilled water, pH 2.2, 3 x 10 min at RT.
17. Washing in PBS, 3 x 3 min.
18. Successive staining for Delta-Ag: incubation of sections previously stained for HBsAg with human IgG anti Delta, 1:5000 in PBS for 30 min at RT.
19. Washing in PBS, 3 x 3 min.
20. Incubation with peroxidase conjugated rabbit anti-human IgG antiserum (Dako), 1:40 in PBS, for 30 min at RT.
21. Washing in PBS, 3 x 3 min.
22. Chromogen reaction was developed in a 0.1% 3-amino-9-ethylcarbazole (Sigma) solution in acetate buffer 0.05 M, pH 5.0 containing H2O2 (0.01%), for 10 min at RT.
23. Washing in acetate buffer, 5 min.
24. Glycine solution as in n° 16 of this section.
25. Washing in PBS, 3 x 3 min.
26. Successive staining for HBcAg: incubation of sections previously stained for HBsAg and Delta-Ag, with a rabbit anti HBcAg antibody (Dako), 1:500, for 30 min at RT.
27. Washing in PBS, 3 x 3 min.
28. Incubation with a Beta-galactosidase conjugated donkey antirabbit IgG antiserum (Clinicals), for 60 min at RT.
29. Washing in PBS, 3 x 3 min.
30. Chromogen reaction development in the following activator-substrate solution: (phosphate buffer 10 mM pH 7.4; NaCl 10 mM; MgCl² 1 mM; iron++cyanide potassium 6 mM; iron+ cyanide potassium 6 mM) + 150 µl bromo-chloro-indolil-galactoside 54 mM, for 120 min at RT.
31. Washing in distilled water, 5 min.
32. Mounting in aqueous medium.

The immunoreaction product appeared as brown-black for HBsAg, red for Delta-Ag, blue for HBcAg.

Control tests included: 1) analogous staining procedures applied on liver tissue sections from HBsAg negative cases; 2) omission of primary antibodies and treatment of sections with only diaminobenzidine; 3) replacement of specific primary antibodies with normal human or rabbit IgG antiserum.

Results

Histopathological details will be given elsewhere.

1. A.B.C. Alternative staining for HBsAg, HBcAg and Delta-Ag

All cases were positive for HBsAg; positivity occurred at the level of cytoplasm and cell membrane of hepatocytes. In most cases, full cytoplasmic positivity corresponded to a ground-glass (G-G) appearance on H&E stained preparations. HBcAg positivity was detected in 7 cases. It was found mainly in the nuclei and less frequently

HBsAg, HBcAg, Delta-Ag in liver tissue

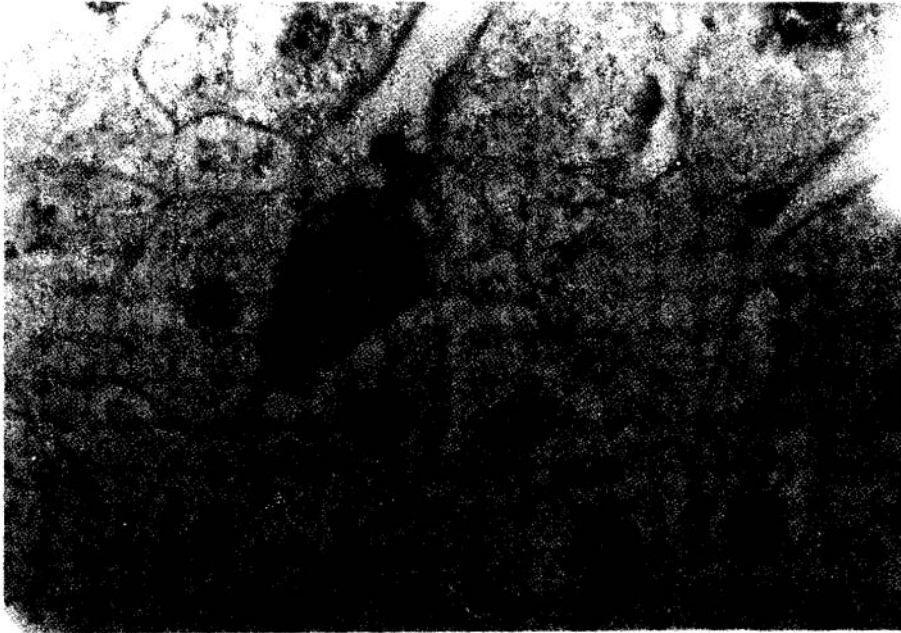


Fig. 1. Section stained for HBcAg. A single cell with a G-G appearance of the cytoplasm is positively stained. Note a few further G-G cells which remain negative. The latter were shown to be positive for HBsAg on serial sections. PAP Hematoxylin. x 660



Fig. 2. Section stained for HBsAg, HBcAg, Delta-Ag, respectively appearing as dark black in the cytoplasm, blue and red in the nuclei. PAP (triple staining). x 660

HBsAg, HBcAg, Delta-Ag in liver tissue

Fig. 3. Section stained for HBsAg, HBcAg, Delta-Ag. The picture shows G-G-hepatocytes positively stained for HBsAg. One of these G-G displays HBcAg (blue) on the cell membrane. PAP x 1,980

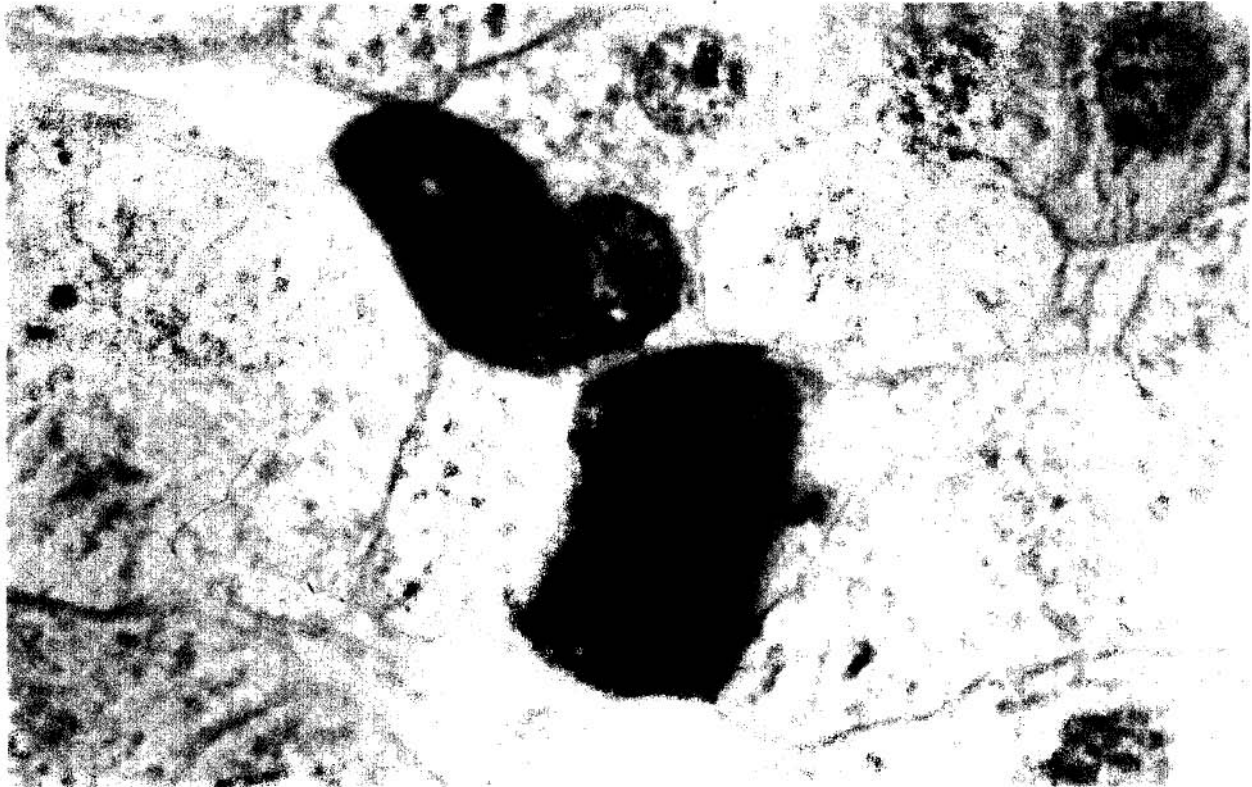


Table 1. Cumulative results of triple immunostaining

N cases	HBsAg +	HBcAg +	Delta-Ag
45	45	7	45
Cell. Local.	HBsAg	HBcAg	Delta-Ag
- nuclei		+	+
- cytoplasm	+	+	+
- membrane	+	+	

on the cell membrane and within the cytoplasm of hepatocytes. In two cases, cytoplasmic HBcAg positivity corresponded to G-G hepatocytes which were negative for HBsAg (Fig. 1). Delta-Ag was detected in hepatocytic nuclei of all cases; a few cells also showed a cytoplasmic staining.

2. D. Successive staining for HBsAg, HBcAg and Delta-Ag (triple immunostaining)

Cumulative results are summarized in Table I. Seven out of 45 cases simultaneously displayed HBsAg, HBcAg

and Delta-Ag (Fig. 2). In the remaining 38 cases, simultaneous positivity was observed for HBsAg and Delta-Ag, whilst staining for HBcAg was negative. In sections positively stained for 2 or 3 antigens, the G-G hepatocyte population turned out to be positive either for HBsAg (the vast majority) and/or for HBcAg (two cases). A strong positive staining for HBcAg was noted on the cell membranes of HBsAg positive G-G-hepatocytes (Fig. 3).

HBsAg was frequently found in the cytoplasm of cells also containing nuclear and cytoplasmic HBcAg. In cells with both HBsAg and HBcAg within the cytoplasm the sum of dark black and blue resulted in brown-green immunoreaction products. More rarely, HBsAg was found in the cytoplasm of cells with nuclear Delta.

HBcAg and Delta-Ag (7 out of 45 cases) were usually distributed in different parenchymal areas. When present in the same territory there was an obvious prevalence of one antigen over the other. A minority of cells showed Delta-Ag in the nuclei and HBcAg in the cytoplasm.

Results of triple immunostaining were always compared with those obtained for individual antigens in alternately stained preparations. Control tests confirmed the specificity of the positive immunoreaction.

Discussion

Original studies on the distribution of HBV and Delta antigens in liver tissue, have been carried out by immunofluorescence techniques (Gudat et al., 1975; Rizzetto et al., 1977). In these studies, individual antigens, i.e. HBsAg or HBcAg or Delta-Ag, were looked for in consecutive histological sections. Since then, immunoperoxidase techniques have become widely available and authors have also succeeded in demonstrating two antigens, i.e. HBsAg and HBcAg in the same tissue section, by applying a double immunostaining (Huang and Neurath, 1979).

We are reporting, for the first time, the successful application of a triple immunostaining for simultaneous visualization of HBsAg, HBcAg and Delta-Ag in the same section from paraffin embedded liver tissue.

Consecutive immunoreactions were developed with different chromogens, so that each antigen was depicted by a different colour. Simultaneous presence of two antigens in the same cell domain, e.g. cytoplasm (always confirmed on consecutive sections alternately stained), resulted in a sum of colours.

Applying this staining technique for the study of a series of biopsies from 45 subjects, a simultaneous positive staining for three antigens was observed in 7 cases, and for two antigens (HBsAg and Delta-Ag) in the remaining 38. In addition, two antigens (either HBsAg and HBcAg or HBsAg and Delta-Ag or HBcAg and Delta-Ag) could be detected in the same cell.

HBcAg appeared not only in the nuclei but also on the cell membrane and within the cytoplasm of hepatocytes. Interestingly, membrane staining for HBcAg also occurred in HBsAg positive-G-G-hepatocytes. In addition, it was unexpectedly found that a minority of G-G-hepatocytes were negative for HBsAg but positive only for HBcAg. **HBcAg-G-G-hepatocytes** represent a new type of G-G cell which now increases the list of conditions in which such cells have been reported (Callea et al., 1986).

The cytoplasmic localization of HBcAg in Delta positive liver biopsies promises to be of interest in view of the recent reports of a variant of chronic B hepatitis in patients serum anti-e antibodies and HBV-DNA associated with cytoplasmic expressions of HBcAg (Bonino et al., 1985).

The demonstration of HBcAg on the cell membrane may also have an important pathogenetic meaning, according to the hypothesis that HBcAg is a target antigen on the liver cell (Bianchi and Gudat, 1979).

A further new finding in the present series forwarded by triple immunostaining is the relatively high frequency of the simultaneous presence of HBcAg and Delta-Ag (7 out of 45 cases = 16%) in the same liver biopsy. These figures would suggest that the exclusion phenomenon between the two antigens is less frequent than had hitherto been thought (Rizzetto et al., 1977). Finally, this study confirms previous observations on cytoplasmic localization of Delta antigen (Kojima et al., 1985).

To summarize, visualization of HBsAg, HBcAg and Delta-Ag in the same histological section was made possible by a triple immunostaining technique. This resulted in the discovery of new distribution patterns of

viral antigens in liver tissue. The technique appears to facilitate, not only the quantitation in one histological section of percentage of population cell positive for HBsAg, HBcAg or Delta-Ag, but also the appraisal of their relationship within the same cell.

Clinical pathological implications resulting from the various associations and combinations of viral antigens in liver tissue will be the subject of a separate report (Callea et al., 1986).

Acknowledgements. The authors wish to thank Dr. M. Rizzetto and Dr. C. Lavarini for providing the anti-Delta-antibody, Mrs. L. Salvi for technical assistance, Mrs. M. Allegro for typing the manuscript.

References

- Bianchi L. and Gudat G.F. (1979). Immunopathology of hepatitis B. In: Progress in liver disease. vol. VI. Popper H. and Shaffner F. (eds). Grune and Stratton. New York. pp 371-392.
- Bonino F., Smedile A., Chiaberge E., Ferrau O., Resta L., Tardanico R., Callea F. and Rizzetto M. (1985). Outcome of chronic hepatitis in HBsAg carriers with serum HBV-DNA and anti-e. *J. Hepat.* 1 (Suppl. 2), S195.
- Callea F. (1986). Prognostic significance of viral antigens in liver tissue. In: Viral Hepatitis. Callea F. et al. (eds). Springer Verlag. Heidelberg, in press.
- Callea F., Facchetti F., Bonera E., Grasso Caprioli G. and Zorzi M. (1986). Prognostic significance of viral antigens in liver tissue. In: Viral Hepatitis Status 1985. Callea F., Zorzi M. and Desmet V. J. (eds). Springer Verlag. Heidelberg. In press.
- Callea F., De Vos R., Togni R., Tardanico R., Vanstapel M.J. and Desmet V.J. (1986). Fibrinogen inclusions in liver cells: a new type of ground-glass hepatocyte. Immune light and electron microscopic characterization. *Histopathology* 10, 65-73.
- Gudat F., Bianchi L., Sonnabend W., Thiel G., Denishaenslin W. and Stadler G. (1975). Patterns of core and surface expression in liver tissue reflects state of specific immune response in hepatitis B. *Lab. Invest.* 32, 1-9.
- Huan S.N. and Neurath A.R. (1979). Immunohistochemical demonstration of hepatitis B viral antigens in liver with reference to its significance in liver injury. *Lab. Invest.* 40, 1-17.
- Kojima T., Callea F., Desmyter J. and Desmet V.J. (1985). Immunoelectron microscopy of Delta antigen (HDAg) in hepatocytes. *Hepatology* 5, 956.
- Rizzetto M. (1983). The Delta agent. *Hepatology* 3, 729-737.
- Rizzetto M., Canese M.G., Arico' S., Crivelli O., Trepo C., Bonino F. and Verne G. (1977). Immunofluorescence detection of new antigen-antibody system (Delta-anti-Delta) associated to hepatitis B virus in liver and serum of HBsAg carriers. *Gut* 18, 997-1003.
- Rizzetto M. and Verne G. (1985). Delta hepatitis-present state. *J Hepat* 1, 187-193.

Accepted March 1, 1986