

Plastinated macroparasites, an alternative resource for use in practical lessons

M. González ^{(1)*}, R. Ruiz de Ybáñez ⁽¹⁾, J. Ortiz ⁽¹⁾, O. López-Albors ⁽²⁾
& R. Latorre ⁽²⁾

(1) Department of Animal Health, Faculty of Veterinary Science, Regional Campus of International Excellence 'Campus Mare Nostrum', University of Murcia, 30100 Murcia, Spain

(2) Department of Anatomy and Comparative Pathological Anatomy, Faculty of Veterinary Science, Regional Campus of International Excellence 'Campus Mare Nostrum', University of Murcia, 30100 Murcia, Spain

*Corresponding author: moises_vet@hotmail.com; moises.gonzalvez@um.es

Summary

The plastination technique is a recently developed option to preserve biological tissues widely used in human and veterinary anatomy. This process allows one to obtain real, safe, clean, dry, resistant and permanently stable material without any additional treatment or maintenance. All these advantages are associated with the rapid expansion of plastination during recent decades in a high number of educational institutions. However, the studies of parasite conservation through plastination are scarce, although the material obtained has a high quality, as prior references have shown. In this study, 141 students of veterinary medicine and pharmacy university degrees used, in a blind study, plastinated specimens (experimental group) or wet specimens (control group) during three consecutive practical sessions. Afterwards all the students completed anonymous questionnaires on both knowledge and satisfaction. The results demonstrated that plastinated parasites are a valid and satisfactory alternative to be used as a teaching/learning tool during practical lessons. Moreover, with regard to the knowledge of morphological structures, the results from the questionnaire of assimilated knowledge showed no differences between the use of plastinated and formaldehyde-preserved parasites.

Keywords

Innovation – Learning tool – Parasite – Plastination – S10 technique.

Introduction

The plastination technique (1) is the most recent and important option for the conservation of biological material, as shown by its rapid expansion in recent years (2). During plastination, body fluids and part of the adipose tissue are slowly replaced by polymers under vacuum conditions (1). In this way, real biological preparations are obtained with advantageous characteristics when compared with traditional conservation. Plastinated samples are clean, dry, resistant, durable and can be handled with no safety precautions such as gloves or masks. In addition, they require no special treatment or storage conditions (3). Moreover, plastinated tissues avoid the daily exposure of students, academics or technical staff to hazardous substances, because they are odourless and free of toxic chemicals such as formaldehyde, phenol or alcohol (4, 5, 6).

Specimens obtained with the well-known S10 silicone plastination technique (7) are of excellent quality, preserving

the original shape and morphology of the specimens along with some flexibility (associated with thinner samples) (8). Plastinated organs have been widely used as a teaching/learning tool in higher education, especially in anatomy. Several previous works have evaluated and even validated the use of plastinated specimens in human and veterinary anatomy practicals (2, 3, 9, 10, 11). Plastination has also been successfully implemented in other disciplines such as zoology (12, 13, 14) and botany (15). A few papers have also referred to the use of plastination to preserve parasites, however they do not provide specific information about their potential use in teaching (12, 16, 17). The validation of plastinated parasites as a teaching tool may help to progressively replace the traditional wet specimens preserved in toxic fixatives, such as formaldehyde, during practical sessions (17, 18).

The objective of this study was to validate the use of plastinated macroparasites in practical lessons in parasitology, by evaluating the satisfaction and knowledge of students studying for degrees in veterinary medicine and pharmacy.

Materials and methods

Specimens

Parasites were obtained from the collection of the Animal Health Department, University of Murcia, Spain: arthropods (*Oestrus ovis*), nematodes (*Parascaris equorum*, *Ascaris suum* and *Macracanthorhynchus hirudinaceus*) and plathelminthes (*Fasciola hepatica*, *Dicrocoelium dendriticum* and *Taenia* spp.) were used (Table I). The specimens were grouped into wet specimens (W, control) fixed in 10% formalin or in ethanol, and plastinated specimens (P) preserved with the standard method of the S10 silicone technique (Biodur® company) (19).

Table I

Plastinated parasites used for practical lessons in veterinary medicine and pharmacy degree programmes

Each parasitic group included specimens of plastinated and non-plastinated specimens, as appropriate

Group	Plastinated specimens
Arthropods	<i>Oestrus ovis</i> larvae (type 2)
	<i>Oestrus ovis</i> larvae (type 3)
Nematodes	<i>Ascaris suum</i>
	<i>Macracanthorhynchus hirudinaceus</i>
	<i>Parascaris equorum</i>
Plathelminthes	<i>Dicrocoelium dendriticum</i>
	<i>Fasciola hepatica</i>
	<i>Taenia</i> spp.

Groups of students

During the 2017/2018 academic year, a total of 141 students of veterinary medicine and pharmacy at the University of Murcia were involved in this project. Information about sex, age and examination failures in previous years was registered to evaluate the influence of these factors on the results obtained. This experiment was performed during three laboratory sessions for each degree subject (Practical 1: plathelminthes, Practical 2: nematodes, and Practical 3: arthropods). The distribution of the study groups and the structure of the assessment of previous knowledge and the knowledge and satisfaction tests were based on previous studies that used plastinated material as a teaching tool (11, 20). The study design of this experiment is represented in Figure 1.

In each practical, the number of students involved was 48–51 in pharmacy (34–37 women and 14 men) and 78–90 in the veterinary medicine degree course (65–73 women and 13–17 men). These students were randomly distributed into two groups: P (using plastinated

specimens) and W (using classical wet specimens). For reasons outside the authors' control, probably influenced by the curiosity of the students about using a new teaching tool (plastinated parasites), the P group had more individuals than the W group.

In order to ensure a blind study, plastinated or wet specimens were distributed in different sessions of the practical, thus avoiding any possibility of contact between the two experimental groups.

Assessment of previous knowledge

Previous knowledge was tested in order to assess the homogeneity of the groups of students at the beginning of the study. It was an anonymous test with 30 multiple-choice questions and four options with only one of them correct. Questions were related to topics including life cycles, geographical distribution, zoonotic conditions and public health relevance, interaction with hosts and economic importance of the parasites.

Laboratory sessions

The three laboratory sessions involved an autonomous evaluation of the structures and morphology of different parasitic groups (plathelminthes, nematodes and arthropods) without time restriction. Upon completion of each session, the students were provided with two individual tests: first, a questionnaire to evaluate knowledge and, second, a satisfaction questionnaire.

Knowledge questionnaire

In the knowledge performance test, each student answered four multiple-choice questions about morphological characteristics of specimens of each of the three parasitic groups (Table II), with an equivalent score for each (2.5 points per question, with a maximum rating of 10 points) (Appendix 1).

Table II

Number of students completing the questionnaires

Laboratory 1 (plathelminthes), Laboratory 2 (nematodes), Laboratory 3 (arthropods), W (wet parasites, control), P (plastinated parasites, experimental group)

Degree	Veterinary		Pharmacy	
	W group	P group	W group	P group
Laboratory 1	37	50	20	31
Laboratory 2	37	53	21	27
Laboratory 3	28	50	20	28
Total for study group	102	153	61	86
Total for degree		255		147
Total questionnaires				402

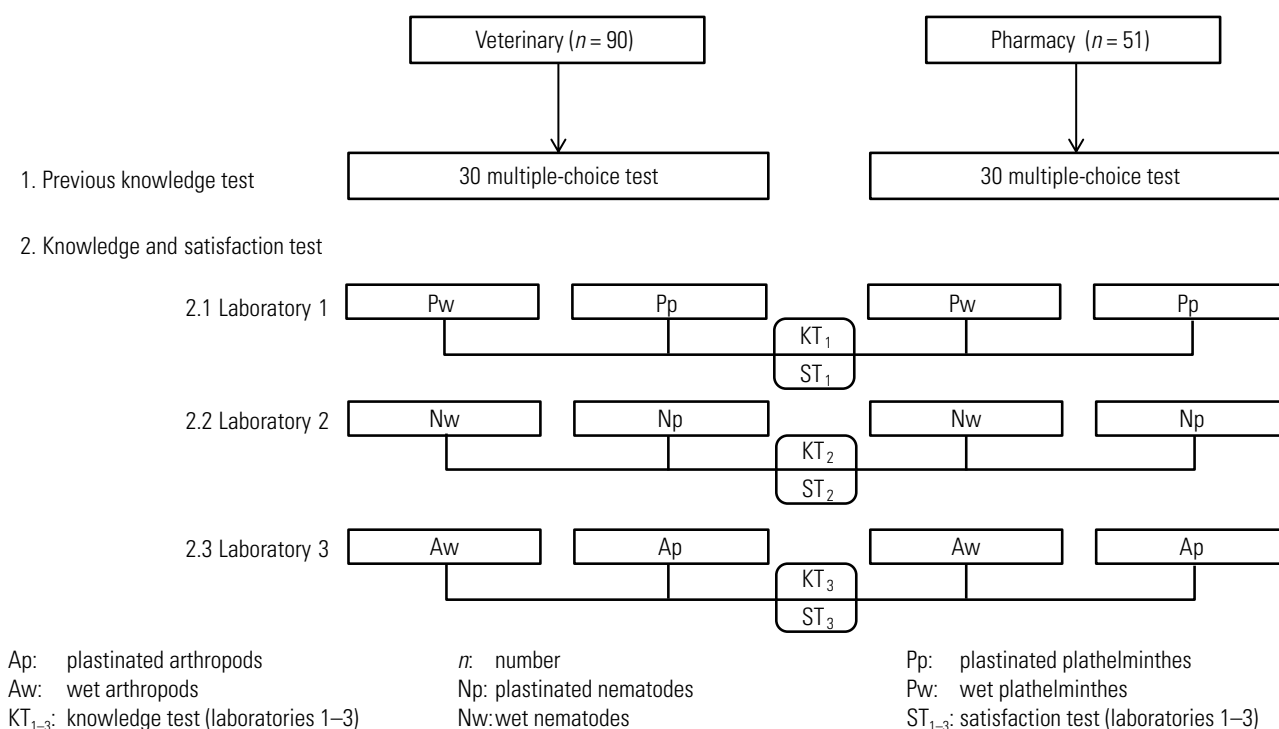


Fig. 1

Study design

The study included a previous knowledge test and the knowledge and satisfaction tests for three laboratories (laboratories 1–3)

Satisfaction questionnaire

This questionnaire comprised five items structured as a Likert-type scale with the following topics, related to plastinated or wet parasites:

1. Did the material help you to learn in the practical lesson? (1 [not at all] to 5 [very much].)
2. What is your opinion about the handling of the parasites? (1 [very uncomfortable] to 5 [very comfortable].)
3. Would you like to have more abundant collections and more groups of parasites for use in the practical lessons? (1 [not at all] to 5 [very much].)
4. How do you evaluate the use of parasites as a teaching tool for practical lessons? (1 [dislike it a lot] to 5 [like it a lot].)
5. Do you recommend the use of the same parasites in the practical lessons for the oncoming years? (1 [totally disagree] to 5 [totally agree].)

Statistical analysis

The statistical software Rstudio v1.0.143 (<http://cran.r-project.org/>) was used to analyse the answers recovered from all questionnaires. Parameters were evaluated for statistical differences using parametric tests (Student's *t*-test and calculation of the Pearson correlation coefficient),

following prior demonstration that the data had a normal distribution. Significance was set to $p < 0.05$.

Results

Assessment of previous knowledge

The results of this pre-test showed that the groups of participants in both degree programmes were homogeneous. This meant that both groups started from a similar level of knowledge, so the results obtained in the study were comparable.

Knowledge questionnaire

Scores were higher in pharmacy (global mean of 6.07 points out of 10) than in veterinary medicine (global mean of 5.75 points out of 10). Among the pharmacy students, the W and P groups obtained an average of 6 and 6.14 points out of 10, respectively. The veterinary students scored 5.7 (W) and 5.8 (P) points out of 10, respectively. All together, the average score of the students was 5.9 and 6 out of 10 for the W and P groups, respectively. However, differences between scores obtained in W and P groups were not statistically significant in any of the above-mentioned comparisons.

The results were also separately evaluated for each practical lesson (plathelminthes, nematodes and arthropods). No differences for any phylum were observed between W and P groups among either pharmacy or veterinary students ($p > 0.05$).

The analysis of the students' characteristics (sex, age and repeater condition) revealed a mild positive correlation ($r = 0.082$) between veterinary students repeating the subject and the knowledge scores, although there were no statistically significant differences when considering the use of plastinated or non-plastinated parasites in practical lessons ($p = 0.109$).

Satisfaction questionnaire

The majority of students using plastinated specimens (96.7%) selected high scores for all the items (average > 4 points out of 5) in the satisfaction questionnaire, while only 73.3% of the students using conventional wet material marked that option ($p > 0.05$) (Fig. 2).

The answers of pharmacy students showed positive statistically significant differences related to the handling advantages (question 1; $p < 0.05$) and the relevance for learning (question 2; $p < 0.05$) of plastinated parasites. Moreover, veterinary students valued positively the use of plastinated parasites as a teaching tool during practical lessons (question 4; $p < 0.05$) (Fig. 2).

A more robust statistical analysis, with an increase in sample size obtained by combining all parasitic groups, showed that plastinated material was rated highest (question 4; $p < 0.05$) by pharmacy students.

In general, the pharmacy and veterinary students expressed a preference for using plastinated arthropods. All experimental groups of parasitic specimens obtained scores above their homologues in the control group. However, neither plastinated nor conventional wet material showed statistically significant differences with regard to the parasitic groups, the degree programme or the student's age, sex or repeater condition.

A low positive correlation ($r = 0.061$) was observed between the knowledge test and the general satisfaction level for plastinated and non-plastinated parasites among students of both pharmacy and veterinary medicine degrees ($p = 0.098$).

Discussion

The results obtained in this study validate the use of plastinated parasites as an alternative teaching/learning tool during practical parasitology lessons in veterinary medicine and pharmacy degrees. Similarly, in other scientific areas of higher education (e.g. anatomy), publications have demonstrated that plastinated specimens are a valid alternative to material fixed with formaldehyde (11, 20). When aiming to evaluate a new teaching tool, it is necessary to ensure the homogeneity of groups (previous knowledge assessment) as well as to compare the experimental data with control information in order to obtain objective results in the analysis and interpretation of the evaluation tests (knowledge and satisfaction questionnaires). Students using plastinated material obtained a better average score in the knowledge test than those using conventional wet specimens, although there were no statistically significant

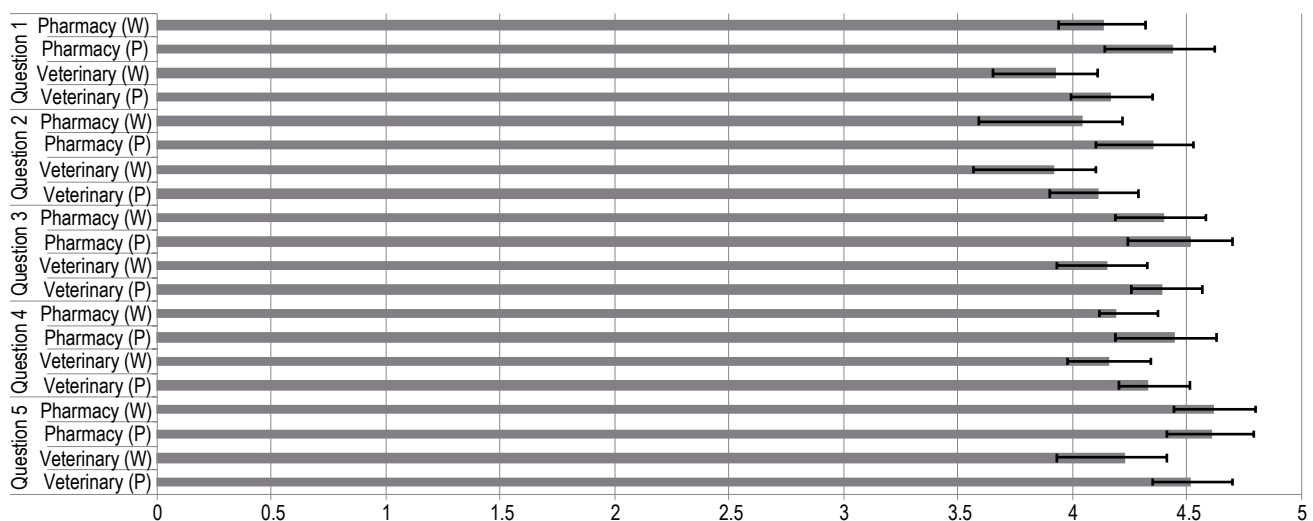


Fig. 2
Mean values (\pm standard deviation) provided by students in relation to W (wet parasites) and P (plastinated parasites) groups for each satisfaction question

differences. This result may be related to the easy handling of plastinated parasites which, according to previous studies, could be a key factor in facilitating the study of the morphological characteristics of parasites (17, 21).

The use of plastinated parasites gained higher acceptance than the traditional wet material in the satisfaction questionnaire, although both pharmacy and veterinary students marked an average score of more than 4 points out of 5 for all the items. Satisfaction with plastinated arthropods obtained the highest score, which could be related to the problems of fragility and management in these species when compared with plathelminthes and nematodes (22).

According to the authors' results, parasite plastination is a promising alternative for the future, and it appears to be an interesting option for preserving teaching tools for routine use in practical sessions in parasitology.

This work is a preliminary study for future experiments in which the number of plastinated parasite species should be greater, in order to work with more specimens whose identification is important for diagnosis, treatment and prophylaxis.

The traditional method of fixing specimens with formaldehyde is considered a significant health hazard. On the other hand, the cost of plastination equipment and chemicals is much greater. Moreover, it is necessary to have good knowledge of the plastination technique to obtain high-quality plastinated specimens. The advantages of

incorporating plastinated parasites in the teaching material of parasitology include provision of a dry, odourless, non-irritating, non-carcinogenic and non-toxic material, ensuring safe procedures in higher education (6, 17, 20, 21, 23, 24). Moreover, the easy storage and conservation of plastinated material is an additional incentive because it ensures a durable teaching tool for use in educational centres (11, 20, 21).

Conclusions

The use of plastinated parasites for teaching purposes allows students to learn morphological structures in parasitology, with no demonstrated differences from wet formaldehyde-preserved specimens. Moreover, this methodology achieved high satisfaction scores with regard to the students' perception of the quality of the specimens when compared with those preserved in formaldehyde.

Acknowledgements

The authors acknowledge the technical support of José Albarracín and Mariano Orenes (Department of Anatomy and Comparative Pathological Anatomy, Veterinary School, University of Murcia, Spain), as well as the Unit of Parasitology and Parasitic Diseases (Department of Animal Health, Veterinary School, University of Murcia, Spain), for the use of the parasite collections. ■

Macroparasites conservés par plastination, une nouvelle ressource pour les leçons pratiques

M. González, R. Ruiz de Ybáñez, J. Ortiz, O. López-Albors & R. Latorre

Résumé

La technique de plastination est une méthode assez récente de préservation des tissus biologiques qui est désormais largement utilisée en anatomie humaine et vétérinaire. Ce procédé permet d'obtenir des préparations anatomiques réalistes, sûres, sèches, résistantes et stables qui ne nécessiteront pas de traitement ni d'entretien ultérieurs pour préserver leur durabilité. Ces avantages expliquent que le recours à la plastination se soit rapidement développé au cours des dernières décennies dans nombre d'institutions d'enseignement. Néanmoins, rares sont les études portant sur la préservation des parasites par plastination, bien que les spécimens obtenus lors de travaux antérieurs aient été jugés de très bonne qualité. Les auteurs présentent les résultats d'une enquête menée auprès de 141 étudiants préparant leur diplôme de médecine vétérinaire ou de pharmacie, à qui ont été distribués en aveugle des spécimens plastinés (groupe

experimental) et des spécimens conservés dans une solution liquide (groupe de contrôle) lors de trois séances consécutives de travaux pratiques. Il a ensuite été demandé aux étudiants de remplir anonymement un questionnaire portant sur les connaissances acquises lors de ces séances et sur leur degré de satisfaction. Les résultats ont montré que les parasites plastinés constituent une alternative valable et satisfaisante en tant que matériel pédagogique et d'entraînement pendant les leçons pratiques. Par ailleurs, s'agissant de l'étude des structures morphologiques, les résultats du questionnaire sur les connaissances acquises lors des travaux pratiques n'ont pas fait apparaître de différences entre les étudiants ayant travaillé sur des parasites plastinés et ceux ayant travaillé avec des parasites conservés dans le formol.

Mots-clés

Innovation – Outil d'apprentissage – Parasite – Plastination – Technique S10 à la silicone.



Los macroparásitos plastinados como recurso alternativo para la enseñanza práctica

M. González, R. Ruiz de Ybáñez, J. Ortiz, O. López-Albors & R. Latorre

Resumen

La técnica de la plastinación es un método de reciente aparición para conservar tejidos biológicos, utilizado con gran frecuencia en anatomía humana y veterinaria. Se trata de un proceso que permite obtener material real, inocuo, limpio, seco, resistente y con una estabilidad permanente sin necesidad de ninguna otra operación de tratamiento o mantenimiento. Todas estas ventajas explican que en los últimos decenios la técnica se haya extendido con rapidez por muy numerosas instituciones de enseñanza. Aun así, hay escasos estudios sobre la conservación de parásitos por plastinación, pese a que el material obtenido, como se desprende de referencias anteriores, es de gran calidad. Los autores describen un estudio ciego en el que 141 estudiantes universitarios en farmacia y medicina veterinaria emplearon muestras plastinadas (grupo experimental) o muestras húmedas (grupo de control) en tres clases prácticas consecutivas, tras lo cual todos los estudiantes respondieron anónimamente a un cuestionario que evaluaba tanto sus conocimientos como su nivel de satisfacción. Los resultados demostraron que los parásitos plastinados constituyen una alternativa válida y satisfactoria como herramienta para impartir y/o recibir clases prácticas. Además, desde el punto de vista del conocimiento de estructuras morfológicas, los resultados del cuestionario sobre conocimientos asimilados no pusieron de manifiesto diferencia alguna entre el uso de parásitos plastinados y el de parásitos conservados en formaldehído.

Palabras clave

Herramienta pedagógica – Innovación – Parásito – Plastinación – Técnica S10.



References

- Von Hagens G., Tiedemann K. & Kriz W. (1987). – The current potential of plastination. *Anat. Embryol. (Berl.)*, **175** (4), 411–421. doi:10.1007/BF00309677.
- Fruhstorfer B.H., Palmer J., Brydges S. & Abrahams P.H. (2011). – The use of plastinated dissections for teaching anatomy: the view of medical students on the value of this learning resource. *Clin. Anat.*, **24** (2), 246–252. doi:10.1002/ca.21107.
- Riederer B.M. (2014). – Plastination and its importance in teaching anatomy. Critical points for long-term preservation of human tissue. *J. Anat.*, **224** (3), 309–315. doi:10.1111/joa.12056.
- McLaughlin J.K. (1994). – Formaldehyde and cancer: a critical review. *Int. Arch. Occup. Environ. Hlth*, **66** (5), 295–301. doi:10.1007/BF00378361.
- Raja D.S. & Sultana B. (2012). – Potential health hazards for students exposed to formaldehyde in the gross anatomy laboratory. *J. Environ. Hlth*, **74** (6), 36–40. Available at: <https://pdfs.semanticscholar.org/a91f/b6510b3cc2e602664f6e502595c680cd9318.pdf> (accessed on 14 February 2019).
- Swenberg J.A., Moeller B.C., Lu K., Rager J.E., Fry R.C. & Starr T.B. (2013). – Formaldehyde carcinogenicity research: 30 years and counting for mode of action, epidemiology, and cancer risk assessment. *Toxicol. Pathol.*, **41** (2), 181–189. doi:10.1177/0192623312466459.
- Şora M.C. (2016). – The general protocol for the S10 technique. *Res. Clin. Med.*, **1** (1), 14–18. Available at: www.resclinmed.eu/public/data_files/articles/12/article_12.pdf (accessed on 14 February 2019).
- Suganthy J. & Francis D.V. (2012). – Plastination using standard S10 technique – our experience in Christian Medical College, Vellore. *J. Anat. Soc. India*, **61** (1), 44–47. doi:10.1016/S0003-2778(12)80012-8.
- Bickley H.C., von Hagens G. & Townsend F.M. (1981). – An improved method for the preservation of teaching specimens [abstract]. *Arch. Pathol. Lab. Med.*, **105** (12), 674–676. Available at: www.ncbi.nlm.nih.gov/pubmed/6895457 (accessed on 14 February 2019).
- Bravo H. (2006). – Plastinación, una herramienta adicional para la enseñanza de la anatomía. *Int. J. Morphol.*, **24** (3), 475–480. doi:10.4067/S0717-95022006000400029.
- Latorre R.M., García-Sanz M.P., Moreno M., Hernández F., Gil F., López O., Ayala M.D., Ramírez G., Vázquez J.M., Arencibia A. & Henry R.W. (2007). – How useful is plastination in learning anatomy? *J. Vet. Med. Educ.*, **34** (2), 172–176. doi:10.3138/jvme.34.2.172.
- Asadi M.H. & Mahmudzadeh A. (2004). – *Ascaris* plastination through S10 techniques. *J. Int. Soc. Plastination*, **19** (1), 20–21. Available at: http://journal.plastination.org/archive/jp_vol.19/jp_vol.19_20-21.pdf (accessed on 14 February 2019).
- Caron M., Grondin G. & Bourassa J.P. (1998). – Elaboration of a three-dimensional identification key for microchiropterans species of Quebec with the S10 plastination technique. In Abstracts presented at the 9th International Conference on Plastination, 5–10 July 1998, Trois-Rivieres, Quebec, Canada. *J. Int. Soc. Plastination*, **13** (2), 34. Available at: http://journal.plastination.org/archive/jp_vol.13.2/jp_vol.13.2_27-42.pdf (accessed on 14 February 2019).
- Schaap C.J. (1998). – Plastination of fish and lobsters. In Abstracts presented at the 9th International Conference on Plastination, 5–10 July 1998, Trois-Rivieres, Quebec, Canada. *J. Int. Soc. Plastination*, **13** (2), 38. Available at: http://journal.plastination.org/archive/jp_vol.13.2/jp_vol.13.2_27-42.pdf (accessed on 14 February 2019).
- Diz A., Martínez-Galisteo A., Sánchez-Rodríguez M. & Conde-Pérez A. (2004). – Plastination of fungi as an aid in teaching botanic classification. In Abstracts presented at the 12th International Conference on Plastination, 11–16 July 2004, Murcia, Spain. *J. Int. Soc. Plastination*, **19** (1), 55. Available at: http://journal.plastination.org/archive/jp_vol.19/jp_vol.19_05-11_43-63.pdf (accessed on 14 February 2019).
- Essa I.M., Al-Emarah G.Y., Al-Azizz S.A., Sawad A.A. & Samar G.H. (2014). – Plastination of arthropods using S10 technique. In Proc. 4th International Scientific Conference, 12–13 November, Basrah, Iraq. *Basrah J. Vet. Res.*, **11** (4), 18–25. Available at: <http://un.uobasrah.edu.iq/papers/1430.pdf> (accessed on 14 February 2019).
- González M., Ortiz J. & Latorre R. (2017). – S10 plastination technique for preservation of parasites: the case of *Oestrus ovis* larvae. *J. Int. Soc. Plastination*, **29** (2), 5–10. Available at: http://journal.plastination.org/archive/jp_vol.29.2/jp_vol29.2_dec17_pages5-10.pdf (accessed on 14 February 2019).
- Kumar N., Das B., Solanki J.B., Jadav M.M. & Menaka R. (2017). – Plastination of macroparasites: an eco-friendly method of long-term preservation. *Vet. World*, **10** (11), 1394–1400. doi:10.14202/vetworld.2017.1394-1400.
- DeJong K. & Henry R.W. (2007). – Silicone plastination of biological tissue: cold-temperature technique Biodur™ S10/S15 technique and products. *J. Int. Soc. Plastination*, **22** (1), 2–14. Available at: http://journal.plastination.org/archive/jp_vol.22/jp_vol.22_02-14.pdf (accessed on 14 February 2019).
- Latorre R., Bainbridge D., Tavernor A. & López Albors O. (2016). – Plastination in anatomy learning: an experience at Cambridge University. *J. Vet. Med. Educ.*, **43** (3), 226–234. doi:10.3138/jvme.0715-113R1.
- Prasad G., Karkera B., Pandit S., Desai D. & Tonse R.G. (2015). – Preservation of tissue by plastination: a review. *Int. J. Adv. Health Sci.*, **1** (11), 27–31.

22. González M., Ortiz J., Navarro M. & Latorre R. (2018). – Preservation of macroparasite species via classic plastination: an evaluation. *Folia Parasitol. (Praha)*, **65**, 019. doi:10.14411/fp.2018.019.
23. Lu Z., Li C.M., Qiao Y., Yan Y. & Yang X. (2008). – Effect of inhaled formaldehyde on learning and memory of mice. *Indoor Air*, **18** (2), 77–83. doi:10.1111/j.1600-0668.2008.00524.x.
24. Dantas de Lucena J., Freitas da Silveira H. [...] & Santos Cerqueira G. (2017). – The irritating effects of exposure to formaldehyde in user students of the human anatomy laboratory. *Int. Arch. Med.*, **10** (220), 1–6. doi:10.3823/2490.

Appendix I

Assessment of knowledge: multiple-choice questions about plathelminthes, nematodes and arthropods provided to the students

Plathelminthes

- Which structure/s could be identified in the anterior region of *Fasciola hepatica* and *Dicrocoelium dendriticum*?
 - Four prominent lips
 - Two keratinised hooks
 - An oral sucker
 - A crown of hooks
- Which structure/s could be found in the ventral region of *Fasciola hepatica* and *Dicrocoelium dendriticum*?
 - A ventral nerve cord
 - A ventral sucker
 - Genital–anal setae
 - Keratinised hooks
- Which of the following definitions fits *Fasciola hepatica*?
 - Segmented trematode with foliaceous shape and length of approximately 3 cm
 - Non-segmented trematode, foliaceous aspect and length of approximately 0.5 cm
 - Non-segmented trematode, foliaceous aspect and length of approximately 3 cm
 - Segmented trematode, oval aspect and length of approximately 3 cm
- The shape of the proglottids of *Taenia* spp. could be defined as:
 - An oval shape
 - The posterior edge is always wider than the anterior one
 - The posterior edge is always narrower than the anterior one
 - A rectangular shape

Nematodes

- Which structure/s could be easily identified in the anterior region of *Parascaris equorum*?
 - Three prominent lips
 - Two large buccal hooks
 - An oral sucker
 - A double crown of hooks
- The cuticle of *Ascaris suum*:
 - Is covered by flakes
 - Has a smooth surface with small transverse striations
 - Has spicules directed backwards along its entire length
 - Has deep segmentations that divide the body into four parts
- Which structure can be identified in the anterior region of *Macracanthorhynchus hirudinaceus*?
 - A proboscis with hooks
 - Two long fimbriae (2 cm approx.)
 - A sucker with four keratinised hooks
 - Three lobed lips
- The cuticle of *Macracanthorhynchus hirudinaceus*:
 - Is entirely smooth
 - Has transverse striations along its entire length
 - Has spines directed backwards along its entire length
 - Is covered with scales

Arthropods

1. What is the main difference between the second (L2) and third (L3) stage larvae of *Oestrus ovis*?
 - a) They are very similar, and a morphological analysis of their spiracles is necessary to distinguish them
 - b) L2 are smaller and whiter than L3, which are larger and have dark transverse striations along their length
 - c) L2 are larger and with dark transverse striations, while L3 are smaller and white
 - d) L2 have two suckers in the anterior region that differentiate them from the L3
 2. The anterior region of *Oestrus ovis* larvae (L2 and L3) has:
 - a) Two keratinised hooks
 - b) A single crown of hooks
 - c) A large sucker
 - d) Three prominent lips
 3. The surface of *Oestrus ovis* larvae (L3):
 - a) Has squamous/verrucous structures over the entire length
 - b) Is smooth, without remarkable structures
 - c) Has macroscopic sensorial fimbriae along its length
 - d) Has rows of spines and dark transverse bands in some segments
 4. The posterior region of *Oestrus ovis* larvae (L2 and L3) has:
 - a) A powerful sucker to increase their adherence to the host
 - b) Two dark and circular structures called spiracles
 - c) Four thick terminal spines
 - d) Two long spicules (2 cm)
-

