

Nerve changes associated with post thoracotomy pain syndrome

Ioan-Adrian Petrache^{1,2*}, Abhinav Sharma^{3,4*}, Abhijit Kumar⁵, Flavia Baderca⁶, Octavian Constantin Neagoe^{7,8}, Emanuela Tudorache⁹, Cristian Oancea⁹, Manuela Emilia Jifcu¹⁰, Mihaela Ionica⁸, Nilima Rajpal Kundnani¹¹, Cozma Gabriel^{1,2} and Ovidiu Burlacu^{1,2}

¹First Discipline of Surgical Semiology, First Department of Surgery, University of Medicine and Pharmacy "Victor Babes", ²Clinic of Thoracic Surgery, Emergency Clinical Municipal Hospital, ³Department of Cardiology, University of Medicine and Pharmacy "Victor Babes", Timisoara, ⁴Department of Occupational Medicine, Municipal Emergency University Hospital, Arad, Romania, ⁵Department of Anesthesiology and Intensive Care in VMMC and Safdarjung Hospital, New Delhi, India, ⁶Department of Microscopic Morphology, University of Medicine and Pharmacy "Victor Babes", ⁷Second Clinic of General Surgery and Surgical Oncology, Emergency Clinical Municipal Hospital Timisoara, ⁸Second Discipline of Surgical Semiology, First Department of Surgery, University of Medicine and Pharmacy "Victor Babes", ⁹Discipline of Pneumology, Department of Infectious Diseases, University of Medicine and Pharmacy "Victor Babes", ¹⁰Service of Pathology, Emergency Clinical Municipal Hospital, and ¹¹Department of Functional Sciences, Physiology, Centre of Immuno-Physiology and Biotechnologies (CIFBIOTEH), University of Medicine and Pharmacy "Victor Babes", Timisoara, Romania

*These authors contributed equally to this paper

Summary. Background. Chronic post-thoracotomy pain (PTPS) is a frequent complication of thoracic operations. Sometimes the pain is excruciating enough to impair activities of daily living (ADL). All thoracic procedures have the potential to cause trauma to the intercostal nerves due to retractor use, chest closure techniques, and or wound healing. In our study, we analyzed the microscopic aspects of the nerves involved in the healing process, to better understand the histopathology of chronic pain.

Methods. 29 patients with PTPS underwent intercostal neurectomy to alleviate the symptoms. Microscopic specimens harvested during the surgeries were sent to our pathology unit for evaluation. The following data regarding the surgical procedures was collected: surgical approach, chest closure type, number of excised nerves, and time interval from previous surgery to neurectomy.

Results. A mean of 2.34 ± 1.11 nerves were excised. Microscopy of the specimens revealed: fibrosis, hyalinization of the epineurium and perineurium, intense

hyperemia of the blood capillaries, and interstitial edema. 7 cases presented with myxoid degeneration of epineurium and perineurium. In all the cases, endoneurium, myelin sheaths, and axons were interrupted. The endoneurium showed the presence of hyperemic dilated capillaries. The segmental cytoplasmic vacuolization of Schwann's cells with the total disappearance of axons was also noted. 60% of the examined specimens had intraneural myxoid degeneration, with highly dense irregular connective tissue around nerve fibers.

Conclusion. The pathologic findings in the structure of the intercostal nerves obtained from the patients are indicative of the involvement of the wound healing mechanisms in PTPS. The negative impact of wound healing could be considered a key component in the development of intense chronic pain.

Key words: Post-thoracotomy pain syndrome, Intercostal nerve, Neuropathy

Corresponding Author: Nilima Rajpal Kundnani, Department of Functional Sciences, Physiology, Centre of Immuno-Physiology and Biotechnologies (CIFBIOTEH), University of Medicine and Pharmacy "Victor Babes", Timisoara, Romania, Str. E. Murgu 2, 300041 Timisoara, Romania. e-mail: knilima@umft.ro
DOI: 10.14670/HH-18-515

Introduction

Chronic post-thoracotomy pain syndrome (PTPS) is the most frequent complication after thoracic surgical procedures, occurring in up to 60% of cases (Gottschalk et al., 2006; Gottschalk and Ochroch, 2008; Kristensen



et al., 2010). Most PTPS patients describe the pain as nagging, but in some cases, it can be excruciating enough to impair activities of daily living (ADL) and affect the patients' quality of life (QOL). Poor coping mechanisms to deal with the associated distress is somewhat similar to that of patients with cancer or tuberculosis (Iovan et al., 2012; Oancea et al., 2018). Though chronic pain has been extensively studied, so far, the consensus on its etiology, population at risk, and pain management has not been reached. The choice of surgical approach for thoracic surgery is vital since the vast majority of cases undergo the incision of the intercostal space, which contains the intercostal nerves. By virtue of their anatomical position, the intercostal nerves are predisposed to trauma in the following three scenarios: 1 – During a thoracotomy, when the intercostal space is transected and the rib retractors are placed to retract the incision, generating constant pressure on the intercostal nerve during the entire operative time; 2 – thoracotomy closure type and 3 – wound healing. However, the advent of new surgical equipment and techniques during the last decade has addressed the aforementioned issues. Nevertheless, the mainstay of treatment to alleviate chronic pain in PTPS patients is surgical excision of the affected nerve. As this is an elective procedure, surgeons ought to correct the perioperative iron deficiency anemia, if any, preferably by intravenous iron (such as ferric carboxymaltose) to minimize the need for allogenic blood transfusion and its associated adverse events (Ionescu et al., 2020).

The group of peripheral neuropathies is heterogeneous; causes include traumatic and non-traumatic injuries. Timar et al. and Popescu et al. have highlighted the importance of age and nerve fiber density in the development and diagnosis of non-traumatic, diabetic peripheral neuropathy (Timar et al., 2016; Popescu et al., 2016). In the 1940s, the pathophysiology of traumatic nerve injury was divided into three classes by Seddon, and later modified by Sunderland in 1951 to provide a five-grade classification based on the degree of injury severity: grade 1 (called neuropraxia by Seddon) in which there is a disruption of myelin sheaths without loss of axonal continuity; grade 2 (called axonotmesis) in which there is a discontinuity in both, myelin sheath and axon, but connective tissue layers (endoneurium, perineurium, and epineurium) are preserved; grade 3 in which axon, myelin sheaths, and endoneurium are affected; grade 4 in which also perineurium is affected; and grade 5 in which the entire nerve fiber and its connective tissue layers are disrupted. Grades 3 to 5 were previously termed neurotmesis by Seddon (Caillaud et al., 2019). The grade 1 lesions are usually reversible since they result from mechanical compression and ischemia. Grade 2 to 4 lesions are more complex, comprising axon disruption with consecutive Wallerian degeneration. However, if the connective tissue layers are preserved, the regeneration of nerve fibers is still possible. The purpose of our study was to analyze the microscopic aspects of the nerves comprised

in the post-traumatic healing process, to better understand the histopathology and basis of chronic pain in PTPS patients.

Materials and methods

As a part of our prospective study, we analyzed the nerves harvested from neurectomy procedures. The patients who were included in the study were admitted to the Thoracic Surgery Department between 2002 – 2020, with the diagnosis of PTPS, and were deemed fit for surgery to alleviate the associated chronic pain. The standard surgical procedure performed on these patients was neurectomy (intercostal nerve resection). Based on the study's inclusion criteria (summarized in Table 1), a total of 29 patients were selected for analysis. Patient charts, operative logs, imaging studies were analyzed. The archived microscopic slides were re-evaluated by two pathologists.

Microscopic specimens harvested during the surgeries were fixed using 4% v/v buffered formaldehyde and sent to the pathology unit. The slides were prepared using the common histological technique.

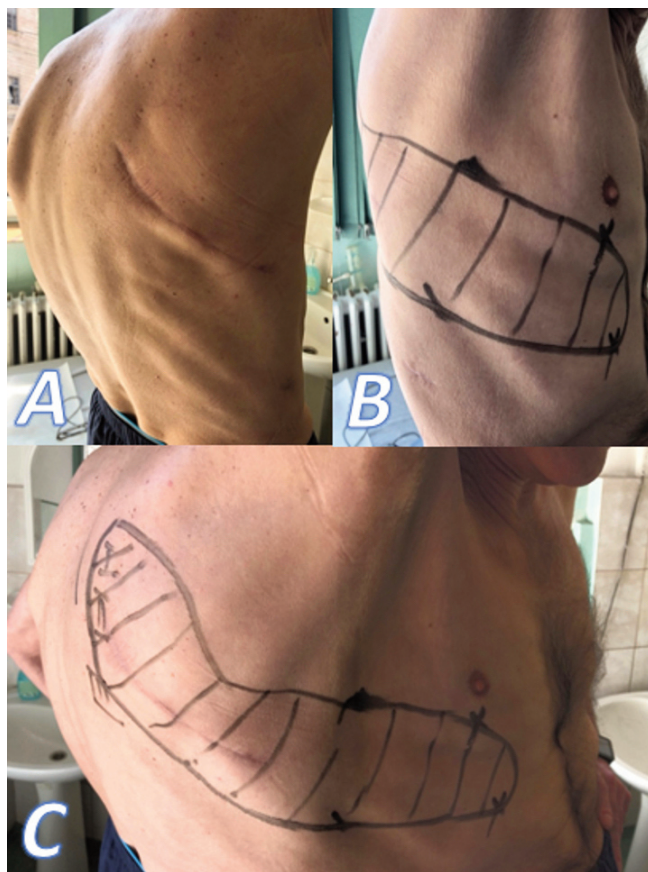


Fig. 1. A. B. Examination of the thoracotomy and identification of painful area. C. Panoramic view of the same patient.

Chronic post thoracotomy pain

To confirm the morphological diagnosis, hematoxylin and eosin (H&E) staining was used.

Each patient's surgical wound was clinically examined at the time of hospitalization. We mapped the painful area to identify the intercostal nerve that was most likely causing the pain. As a part of the process, we applied soft touch, pressure, cold and warm stimuli to the skin posterior to the incision, along the incision, and anterior to the incision (Fig. 1).

Each patient was asked to describe the pain and pain intensity for each stimulus. Each patient's response to pain was recorded using the numeric pain scale (Table 2), and the McGill pain questionnaire (Table 3) (Cerfolio et al., 2003).

For each patient, the following data regarding the surgical procedure were collected: the surgical approach, chest closure type, the number of excised intercostal nerves, and the time interval from previous surgery to neurectomy.

Regarding the initial thoracic procedure, we

recorded 9 patients who had a postero-lateral thoracotomy, 19 patients benefitted from axillar approach and 1 case underwent video-assisted thoracic surgery (VATS). All patients had their chest closed by using standard peri-costal stitches. All PTPS patients benefitted from intercostal neurectomy with curative intent.

Statistical analysis was performed using SPSS software for Windows version 21 (Armonk, NY: IBM Corp.). Descriptive analysis of continuous data was

Table 1. Inclusion criteria for this study.

Inclusion criteria	
Pain duration	at least 6 months
Pain Scale Value at Admission	>8
Local recurrence	None
Response to Analgesic Treatment	Poor
Impairment of Day-to-day Activities	Yes

Table 2. Visual analogic pain scale used in the study.

No pain		Mild pain		Moderate Pain			Severe Pain			Worst Pain Possible	
0	1	2	3	4	5	6	7	8	9	10	

Table 3. McGill pain questionnaire.

Listed below are words that describe pain. Please check the box beside each word that best describes your pain.

	None		Mild		Moderate		Severe	
Throbbing	0	<input type="checkbox"/>	1	<input type="checkbox"/>	2	<input type="checkbox"/>	3	<input type="checkbox"/>
Shooting	0	<input type="checkbox"/>	1	<input type="checkbox"/>	2	<input type="checkbox"/>	3	<input type="checkbox"/>
Stabbing	0	<input type="checkbox"/>	1	<input type="checkbox"/>	2	<input type="checkbox"/>	3	<input type="checkbox"/>
Sharp	0	<input type="checkbox"/>	1	<input type="checkbox"/>	2	<input type="checkbox"/>	3	<input type="checkbox"/>
Cramping	0	<input type="checkbox"/>	1	<input type="checkbox"/>	2	<input type="checkbox"/>	3	<input type="checkbox"/>
Gnawing	0	<input type="checkbox"/>	1	<input type="checkbox"/>	2	<input type="checkbox"/>	3	<input type="checkbox"/>
Hot-burning	0	<input type="checkbox"/>	1	<input type="checkbox"/>	2	<input type="checkbox"/>	3	<input type="checkbox"/>
Aching	0	<input type="checkbox"/>	1	<input type="checkbox"/>	2	<input type="checkbox"/>	3	<input type="checkbox"/>
Heavy	0	<input type="checkbox"/>	1	<input type="checkbox"/>	2	<input type="checkbox"/>	3	<input type="checkbox"/>
Tender	0	<input type="checkbox"/>	1	<input type="checkbox"/>	2	<input type="checkbox"/>	3	<input type="checkbox"/>
Splitting	0	<input type="checkbox"/>	1	<input type="checkbox"/>	2	<input type="checkbox"/>	3	<input type="checkbox"/>
Tiring/Exhausting	0	<input type="checkbox"/>	1	<input type="checkbox"/>	2	<input type="checkbox"/>	3	<input type="checkbox"/>
Sickening	0	<input type="checkbox"/>	1	<input type="checkbox"/>	2	<input type="checkbox"/>	3	<input type="checkbox"/>
Fearful	0	<input type="checkbox"/>	1	<input type="checkbox"/>	2	<input type="checkbox"/>	3	<input type="checkbox"/>
Punishing cruel	0	<input type="checkbox"/>	1	<input type="checkbox"/>	2	<input type="checkbox"/>	3	<input type="checkbox"/>

Check the box that best describes your pain when performing the listed activity

	Resting		Coughing		Lifting arms overhead	
No pain	0	<input type="checkbox"/>	0	<input type="checkbox"/>	0	<input type="checkbox"/>
Mild	1	<input type="checkbox"/>	1	<input type="checkbox"/>	1	<input type="checkbox"/>
Discomforting	2	<input type="checkbox"/>	2	<input type="checkbox"/>	2	<input type="checkbox"/>
Distressing	3	<input type="checkbox"/>	3	<input type="checkbox"/>	3	<input type="checkbox"/>
Horrible	4	<input type="checkbox"/>	4	<input type="checkbox"/>	4	<input type="checkbox"/>
Excruciating	5	<input type="checkbox"/>	5	<input type="checkbox"/>	5	<input type="checkbox"/>

presented as mean and standard deviation. Pearson's chi-square test was used for the assessment of correlation between categorical variables. Student t-test was used to evaluate differences between continuous variables. A p-value of <0.05 was considered statistically significant.

Results

The mean age of the patients was 54.78 ± 14.81 years, with a male/female ratio of 0.37. All the patients in this study complained of pain at the thoracotomy site, stating that they never had a pain-free interval. The McGill pain questionnaire identified higher scores for throbbing, sharp, hot-burning, tiring, punishing cruel pain, having all the characteristics of neuropathy. Pain scores were significantly higher when the patients were subjected to coughing effort ($p < 0.05$), but not significantly higher during the movement of upper limb ipsilateral to the thoracotomy. The results of the pain questionnaire are summarized in Table 4.

In five cases, the preoperative imaging studies showed narrowed intercostal spaces corresponding to the thoracotomy incision, with bony bridges between ribs entrapping the intercostal nerves (Fig. 2).

In these patients, partial rib resections were necessary to reach and excise the intercostal nerve. A mean of 2.34 ± 1.11 nerves was excised, two cases required resection of four nerves, and one patient had five nerves removed. No major complications were recorded: two patients required pleural drainage for iatrogenic pneumothorax, and one patient developed bulging of the muscles of the abdomen because five nerves were resected.

All patients reported significantly lower pain scores post-operatively, stating that the "nagging pain" was substituted with a "more bearable numbing sensation".

The microscopic examination of the harvested

specimens revealed modified nerve histology in all the cases. The following changes were seen: fibrosis, hyalinization of the epineurium and perineurium (Fig. 3) with intense hyperemia of the blood capillaries (Fig. 4), and variable degrees of interstitial edema (Fig. 5). In seven cases, myxoid degeneration of epineurium and perineurium was observed (Fig. 6). In all the cases, endoneurium, myelin sheaths, and axons were interrupted. The endoneurium showed the presence of hyperemic dilated capillaries (Fig. 7). Segmental cytoplasmic vacuolization of Schwann's cells with the total disappearance of axons was also noted (Fig. 8 and 9). In 60% of the examined specimens, intraneural myxoid degeneration was observed (Fig. 10). Furthermore, in the majority of cases, highly dense irregular connective tissue was observed around the nerve fibers (Fig. 11).

Discussion

The physiopathology of chronic post-operative thoracic pain remains unclear. The mechanisms involved in the development of pain are very complex and clinical manifestations of PTPS are heterogeneous, making this syndrome difficult to understand and manage. The literature describes the following treatment strategies with more or less satisfactory results; the use of epidural catheters, cryoanalgesia, intercostal nerve blockade, pulsed radiofrequency of the dorsal root ganglion, chronic use of non-steroidal anti-inflammatories (NSAID), and/or opioid medication (Gilron et al., 2005;

Table 4. Mean values recorded to evaluate pain characteristics.

Pain Characteristic	Mean Score
Throbbing	1.86 ± 0.74
Shooting	0.72 ± 0.84
Stabbing	1.96 ± 0.86
Sharp	1.65 ± 1.11
Cramping	0.24 ± 0.51
Gnawing	0.58 ± 0.56
Hot-burning	2.17 ± 0.88
Aching	1.27 ± 1.16
Heavy	2.1 ± 0.81
Tender	1.55 ± 0.98
Splitting	0.37 ± 0.67
Tiring/Exhausting	2.27 ± 0.79
Sickening	2.13 ± 0.95
Fearful	1.96 ± 0.73
Punishing cruel	2.34 ± 0.66
Rest pain	2.31 ± 0.84
Coughing pain	3.41 ± 0.90
Lifting arms over head	2.55 ± 0.73

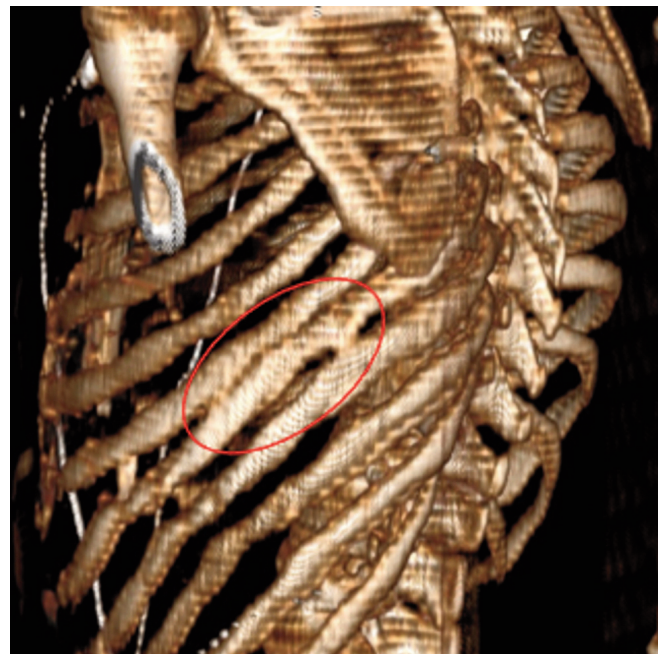


Fig. 2. 3D reconstruction of the rib cage showing intercostal nerve entrapment secondary to rib synostosis.

Detterbeck, 2005; Khelemsky and Noto, 2012; Bottiger et al., 2014; Koethe et al., 2014; Khanbhai et al., 2014). Many authors believe that chronic pain should be taken into account for each thoracic surgical procedure since there is a high prevalence (60-80%) of this complication among the patients who underwent surgery (Perttunen et al., 1999; Bottiger et al., 2014; Alzahrani, 2017). Therefore, thoracic surgeons should be cognizant of all aspects of postoperative pain, such as the psycho-social impact, patient education, other pain-inducing comorbidities, surgical approach and chest closure technique, management of acute pain, wound healing mechanism, and chronic use of pain-relieving medications. The management of chronic pain in patients with PTPS should involve a tailored multi-pronged approach that is based on the patient's individual needs and procedures (Sentürk et al., 2002;

Elmore et al., 2015). Though the consensus on the definition of QOL is yet to be achieved, clinicians and health care systems should begin focusing on the importance of evaluating intervention impact on patients' health, for them to lead a pain-free and fulfilling life (Kundnani et al., 2021).

Post-thoracotomy pain arises in three ways: pain arising from nociceptors and neuropathic afferents, and referred pain (Sentürk et al., 2002). All thoracic surgical procedures have the potential to stimulate the somatic nociceptors; stimulation is initiated by skin incision, muscle division, rib retraction and compression, incision of the parietal pleura, and chest drain insertion. These stimuli are conducted through the intercostal nerve fibers to the dorsal horn of the spinal cord, corresponding to T4-T10 levels and further transmitted to the limbic system and cortex by the contralateral anterolateral

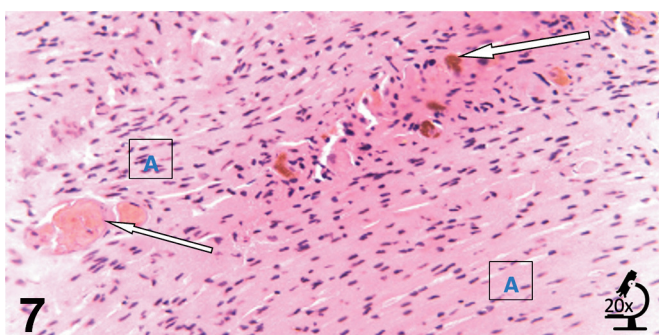
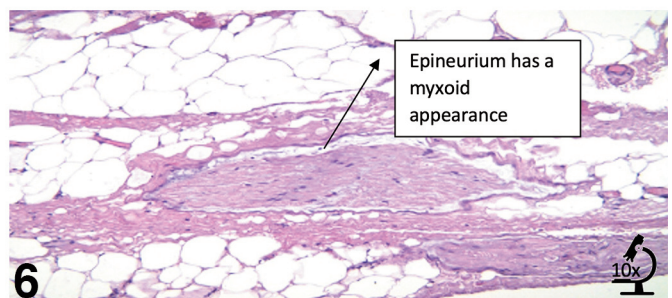
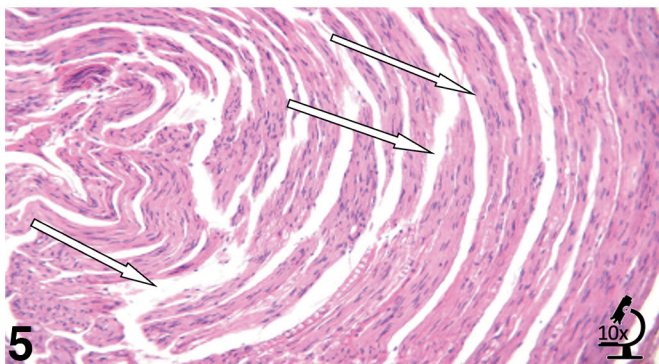
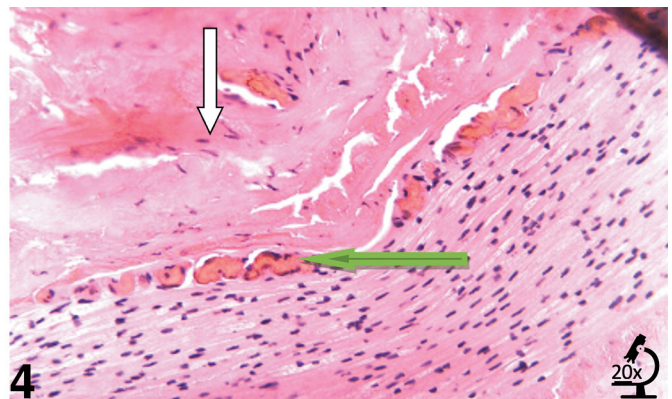
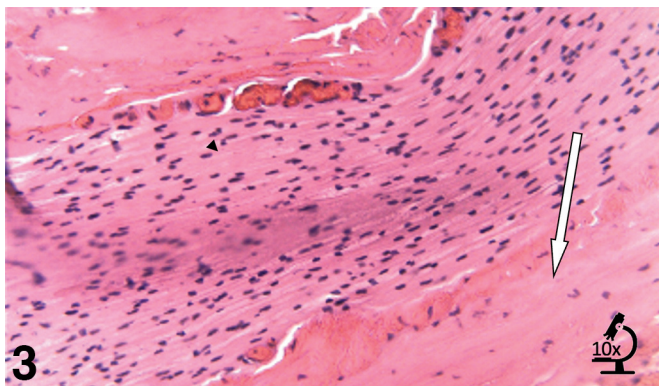


Fig. 3. Epineurium and perineurium with fibrosis (indicated with the white arrow), but normal endoneurium (arrowhead) H&E staining.

Fig. 4. Epineurium with hyperemia of blood capillaries (green arrow) and perineurium with fibrosis and hyperemic capillaries (white arrow) H&E staining.

Fig. 5. Perineurium with variable degrees of interstitial edema which in optical microscopy appears as empty spaces (white arrow), H&E staining.

Fig. 6. Myxoid degeneration of epineurium. The nerve thread is surrounded by adipocytes and collagen fibers, H&E staining.

Fig. 7. Endoneurium with hyperemia of blood capillaries (white arrow), H&E staining. A: endoneurium.

system of the spinal cord (Kuner and Flor, 2016; Yang and Chang, 2019). Also, intra-operative manipulation of the visceral pleura, lung, dissection, division, and suture of the bronchi, or the pericardium determine stimulation of visceral nociceptors, which transmit action potentials by the phrenic and vagus nerves (Mesbah et al., 2015). Continued stimulation of nociceptors in the first postoperative days due to poor pain control can lead to a reduction of the patients' pain threshold and primary sensitization, producing an amplified pain response to coughing effort or chest movements during breathing (Yang and Chang, 2019). Prolonged stimulation of the nociceptors leads to further sensitization and hyperexcitability of the dorsal horn neurons, all the way up to the higher central nervous pain centers through the activation of N-methyl-D-aspartate (NDMA) receptors, glutamate, and calcitonin gene-related peptides, resulting in central sensitization (Voscopoulos and Lema, 2010; Yang and Chang, 2019). However, this may be discontinued if the pain resolves during the process of wound healing (Voscopoulos and Lema, 2010). Therefore, an effective acute pain control strategy should be an essential element in preventing the manifestation of chronic pain (Yarnitsky et al., 2008; Hetmann et al., 2013); however, not all analgesic interventions prove to be effective (Raja and Dougherty, 2000; Brennan and Kehlet, 2005; Dworkin et al., 2010). Nevertheless, there

are published studies that show a reduction in chronic pain if analgesic therapy is aggressively pursued to treat acute pain (Katz et al., 1996).

The neuropathic component of chronic pain entails nerve damage produced by thoracotomy, comprising reduced sensorial input associated with hypersensitivity (Kehlet et al., 2006), whilst referred pain is defined as pain in the ipsilateral shoulder, produced by the irritation of pleura or pericardium due to the presence of chest drains, conducted by the sensory afferents via the phrenic nerve (Kehlet et al., 2006). This mode of transmission of the stimuli explains the presence of shoulder pain despite the use of thoracic epidural analgesia (Mesbah et al., 2015).

Our study demonstrated the risk factors for developing chronic pain post-thoracotomy and how such patients may benefit from surgical ablation of the involved nerves. Though our search of the literature on the assessment of nerve damage in post-operative chronic pain yielded many results, only a few articles addressed the involvement of intercostal nerves in the production of thoracic pain. Also, most studies were electro-physiologic (Maguire et al., 2006). Though the post-surgical chronic pain caused by inflammatory neuropathy (e.g. the pain associated with Guillain-Barre or brachial neuropathy) (Staff et al., 2010) has been amply mentioned in the literature, there is a paucity of

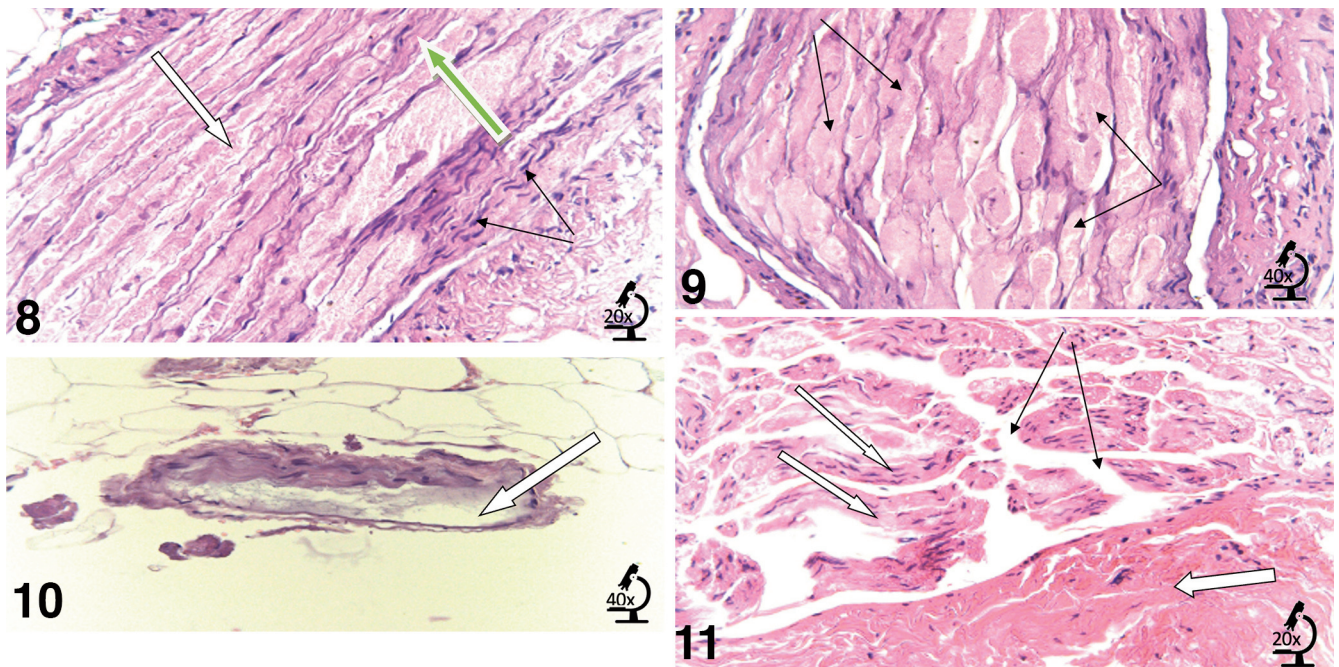


Fig. 8. Swollen Schwann's cells with segmental loss of axons (white arrow), Schwann cell nuclei (black arrow) axons and myelin sheaths (green arrow) H&E staining.

Fig. 9. Possible swollen Schwann's cells with total loss of axons. Large Schwann cell with few nuclei and no axons (black arrow), H&E staining.

Fig. 10. Myxoid degeneration of nerve fiber (white arrow), part of the epineurium and endoneurium has a basophilic, myxoid appearance, H&E staining.

Fig. 11. Irregular dense connective tissue surrounding nerve fibers (thick arrow), perineurium with interstitial edema (black arrow) which separates bundles of Schwann cells (thin arrow), H&E staining.

data on PTPS associated neuropathy.

Our study identified neural structural modifications in all the cases, that can be considered grades 2 and 3 based on Sunderland's classification.

Staff et al. performed nerve biopsies in 23 patients with chronic pain and demonstrated the presence of inflammatory cells in 21 of those biopsies (Staff et al., 2010). On the contrary, no macrophages were noticed in our specimens, probably due to the elapsed time from the onset of nerve injury to the collection of the specimens.

However, focal edema and dilated capillaries, along with fibrosis were present in almost all the samples, suggesting that the nerve fiber modifications can have multiple causes, such as nerve adaptation to the surgical trauma, surgical wound healing related impact on the intercostal nerve, as evident from the presence of thoracotomized intercostal space narrowing with synostosis on imaging studies. These findings may provide an insight as to why pain becomes persistent and why the characteristics of pain change over time. The nerve modifications identified in this study prove that neuropathic pain is not always caused by mechanical injuries, such as caused by surgical interventions, but the wound healing mechanism can also result in focal or diffuse pain responses. Swollen Schwann cells are indicative of the local edema caused by the post-surgical healing process and the consequential pain; however, further research is required to ascertain the correlation. Though the myxoid changes were observed during the study, we cannot attribute these changes solely to the nerve injury caused by surgery, as they might be due to an ongoing degenerative process. The moment when pain becomes chronic remains a mystery (Voscopoulos and Lema, 2010); that is why patients should be encouraged to keep a logbook of pain symptoms to identify even the slightest of modifications in pain characteristics or localization, as these neuropathies may be recognized by their temporospatial separation from the site and time of surgery (Staff et al., 2010; Berini et al., 2014).

Given the paucity of data on intercostal nerve tissue modifications in chronic PTPS, more research is required to categorically link these modifications to the characteristics of pain. Our research provides an insight into the possible causes of surgically induced pain, and therefore, it might help in formulating preventive strategies and measures for pain alleviation. Though there were noticeable improvements in the pain scores of the patients, only a few patients had reported complete pain relief after neurectomy. It is believed that the anatomical disposition of the intercostal nerves that facilitates anastomoses among the nerves in proximity could be a factor for ineffective pain management. Theoretically, the development of new connections could lead to partial re-innervation and pain recurrence.

Our study aimed to explore the microscopic changes in the nerve structures that may be involved in chronic postoperative pain syndrome. In our study, we used only

the standard H&E staining to explore the modifications. In our future study, we intend to assess sections even from the intercostal space that surrounds the nerve. Moreover, we would use immunohistochemical staining to highlight the neuroinflammatory markers and the specific cell types, in order to elucidate the non-neural tissue damage and the wound healing processes.

Conclusions

Pathological changes in the structure of the intercostal nerve in patients with chronic PTPS suggest that surgery is not the sole cause of nerve fiber injuries, and the wound healing mechanisms could also play a role in the development of associated intense chronic pain. Correlation with imaging studies suggests that proper wound healing without intense fibrotic changes could positively affect the postoperative course of these patients. This can be achieved by paying attention to all the technical details when performing a thoracotomy, and also when closing the thorax. Attention to detail may diminish the procedure-related risks for post-operative pain by preventing rib fractures and prolonged nerve compression during and/or after surgery due to improper chest closure technique.

Funding. This research received no external funding.

Institutional Review Board Statement. The study was conducted according to the guidelines of the Declaration of Helsinki, and approved by the Institutional Review Board (or Ethics Committee) of Timisoara Municipal Hospital no E3881.

Informed Consent Statement. Informed consent was obtained from all subjects involved in the study.

Conflicts of Interest. The authors declare no conflict of interest.

Acknowledgements. a). Our team sincerely acknowledges the efforts and the insight provided by Dr. Ovidiu Burlacu (deceased).

References

- Alzahrani T. (2017). Pain relief following thoracic surgical procedures: A literature review of the uncommon techniques. *Saudi J. Anaesth.* 11, 327-331.
- Berini S.E., Spinner R.J., Jentoft M.E., Engelstad J.K., Staff N.P., Suanprasert N., Dyck P.J. and Klein C.J. (2014). Chronic meralgia paresthetica and neurectomy: a clinical pathologic study. *Neurology* 82, 1551-1555.
- Bottiger B.A., Esper S.A. and Stafford-Smith M. (2014). Pain management strategies for thoracotomy and thoracic pain syndromes. *Semin. Cardiothorac. Vasc. Anesth.* 18, 45-56.
- Brennan T.J. and Kehlet H. (2005). Preventive analgesia to reduce wound hyperalgesia and persistent postsurgical pain: not an easy path. *Anesthesiology* 103, 681-683.
- Caillaud M., Richard L., Vallat J.M., Desmoulière A. and Billet F. (2019). Peripheral nerve regeneration and intraneural revascularization. *Neural. Regen. Res.* 14, 24-33.
- Cerfolio R.J., Price T.N., Bryant A.S., Sale Bass C. and Bartolucci A.A. (2003). Intracostal sutures decrease the pain of thoracotomy. *Ann. Thorac. Surg.* 76, 407-411; discussion 411-402.

- Detterbeck F.C. (2005). Efficacy of methods of intercostal nerve blockade for pain relief after thoracotomy. *Ann. Thorac. Surg.* 80, 1550-1559.
- Dworkin R.H., Mcdermott M.P. and Raja S.N. (2010). Preventing chronic postsurgical pain: how much of a difference makes a difference? *Anesthesiology* 112, 516-518.
- Elmore B., Nguyen V., Blank R., Yount K. and Lau C. (2015). Pain management following thoracic surgery. *Thorac. Surg. Clin.* 25, 393-409.
- Gilron I., Bailey J.M., Tu D., Holden R.R., Weaver D.F. and Houlden R.L. (2005). Morphine, gabapentin, or their combination for neuropathic pain. *N. Engl. J. Med.* 352, 1324-1334.
- Gottschalk A. and Ochroch E.A. (2008). Clinical and demographic characteristics of patients with chronic pain after major thoracotomy. *Clin. J. Pain* 24, 708-716.
- Gottschalk A., Cohen S.P., Yang S. and Ochroch E.A. (2006). Preventing and treating pain after thoracic surgery. *Anesthesiology* 104, 594-600.
- Hetmann F., Schou-Bredal I., Sandvik L. and Kongsgaard U.E. (2013). Does chronic pre-operative pain predict severe post-operative pain after thoracotomy? A prospective longitudinal study. *Acta Anaesthesiol. Scand.* 57, 1065-1072.
- Ionescu A., Sharma A., Kundnani N.R., Mihăilescu A., David V.L., Bedreag O., Săndesc D., Dinu A.R., Săndesc M.A., Albuiescu N. and Drăgoi R.G. (2020). Intravenous iron infusion as an alternative to minimize blood transfusion in peri-operative patients. *Sci. Rep.* 10, 18403.
- Iovan I., Vancea D., Fratila Z. and Burlacu O. (2012). Anxiety and depression in tuberculosis hospitalized patients in comparison to healthy individuals. *Euro. Resp. J.* 40, P2591.
- Katz J., Jackson M., Kavanagh B.P. and Sandler A.N. (1996). Acute pain after thoracic surgery predicts long-term post-thoracotomy pain. *Clin. J. Pain* 12, 50-55.
- Kehlet H., Jensen T.S. and Woolf C.J. (2006). Persistent postsurgical pain: risk factors and prevention. *Lancet* 367, 1618-1625.
- Khanbhai M., Yap K.H., Mohamed S. and Dunning J. (2014). Is cryoanalgesia effective for post-thoracotomy pain? *Interact. Cardiovasc. Thorac. Surg.* 18, 202-209.
- Khelemsky Y. and Noto C.J. (2012). Preventing post-thoracotomy pain syndrome. *Mt. Sinai J. Med.* 79, 133-139.
- Koethe Y., Mannes A.J. and Wood B.J. (2014). Image-guided nerve cryoablation for post-thoracotomy pain syndrome. *Cardiovasc. Intervent. Radiol.* 37, 843-846.
- Kristensen A.D., Pedersen T.A., Hjortdal V.E., Jensen T. S. and Nikolajsen L. (2010). Chronic pain in adults after thoracotomy in childhood or youth. *Br. J. Anaesth.* 104, 75-79.
- Kundnani N.R., Rosca C.I., Sharma A., Tudor A., Rosca M.S., Nisulescu D.D., Branea H.S., Mocanu V., Crisan D.C., Buzas D.R., Morariu S. and Lighezan D.F. (2021). Selecting the right anticoagulant for stroke prevention in atrial fibrillation. *Eur. Rev. Med. Pharmacol. Sci.* 25, 4499-4505.
- Kuner R. and Flor H. (2016). Structural plasticity and reorganisation in chronic pain. *Nat. Rev. Neurosci.* 18, 20-30.
- Maguire M.F., Latter J.A., Mahajan R., Beggs F.D. and Duffy J.P. (2006). A study exploring the role of intercostal nerve damage in chronic pain after thoracic surgery. *Eur. J. Cardiothorac. Surg.* 29, 873-879.
- Mesbah A., Yeung J. and Gao F. (2015). Pain after thoracotomy. *BJA Education* 16, 1-7.
- Oancea C., Suciu C., Timar B., Papava I., Raica M. and Burlacu O. (2018). The reciprocal relationship between coping mechanisms and lung cancer diagnosis: findings of a prospective study. *Cancer Manag. Res.* 10, 33-40.
- Perttunen K., Tasmuth T. and Kalso E. (1999). Chronic pain after thoracic surgery: a follow-up study. *Acta Anaesthesiol. Scand.* 43, 563-567.
- Popescu S., Timar B., Baderca F., Simu M., Diaconu L., Velea I. and Timar R. (2016). Age as an independent factor for the development of neuropathy in diabetic patients. *Clin. Interv. Aging.* 11, 313-318.
- Raja S.N. and Dougherty P.M. (2000). Reversing tissue injury-induced plastic changes in the spinal cord: the search for the magic bullet. *Reg. Anesth. Pain. Med.* 25, 441-444.
- Sentürk M., Ozcan P.E., Talu G.K., Kiyan E., Camci E., Ozyalçin S., Dilege S. and Pembeci K. (2002). The effects of three different analgesia techniques on long-term postthoracotomy pain. *Anesth. Analg.* 94, 11-15.
- Staff N.P., Engelstad J., Klein C.J., Amrami K.K., Spinner R.J., Dyck P.J., Warner M.A., Warner M.E. and Dyck P.J. (2010). Post-surgical inflammatory neuropathy. *Brain* 133, 2866-2880.
- Timar B., Popescu S., Timar R., Baderca F., Duica B., Vlad M., Levai C., Balinisteanu B. and Simu M. (2016). The usefulness of quantifying intraepidermal nerve fibers density in the diagnostic of diabetic peripheral neuropathy: a cross-sectional study. *Diabetol. Metab. Syndr.* 8, 31.
- Voscopoulos C. and Lema M. (2010). When does acute pain become chronic? *Br. J. Anaesth.* 105 (Suppl. 1), i69-85.
- Yang S. and Chang M.C. (2019). Chronic pain: Structural and functional changes in brain structures and associated negative affective states. *Int. J. Mol. Sci.* 20, 3130.
- Yarnitsky D., Crispel Y., Eisenberg E., Granovsky Y., Ben-nun A., Sprecher E., Best L.A. and Granot M. (2008). Prediction of chronic post-operative pain: pre-operative DNIC testing identifies patients at risk. *Pain* 138, 22-28.

Accepted August 5, 2022