

Evaluation of the multiple tissue factors in bone of primary osteoplasty and rhinoplasty in patients affected by cleft lip palate

Dace Buile¹, Māra Pilmane¹ and Ilze Akota²

¹Department of Morphology, Institute of Anatomy and Anthropology and

²Department of Maxillofacial Surgery, Institute of Stomatology, Riga Stradiņš University, Riga, Latvia

Summary. Clefts of the lip and/or palate (CLP) are visible disruptions of standard facial structure. The aim of our study was to determine a relative number and appearance of the tissue factors in bone of patients with CLP during first time plastic alveolar osteoplasty or rhinoplasty.

Immunohistochemistry was performed with matrix metalloproteinase-8 (MMP-8), matrix metalloproteinase-9 (MMP-9), osteopontin (OPN), osteocalcin (OC), Runt-related transcription factor 2 (Runx2), beta-defensin-2 (β def-2), beta-defensin-3 (β def-3), interleukin-1 alpha (IL-1 α), and interleukin-10 (IL-10). The bone formation was observed by Masson-trichrome (Masson) staining. For the quantification of structures, the semi-quantitative census method was used. Spearman rank order correlation coefficient and Mann-Whitney U test were used for the statistical analysis.

A significantly higher number of OPN positive osteocytes was observed in the CLP group when compared to the control group ($p=0.002$). The number of OC positive osteocytes ($p=0.000$) and β def-2 positive osteocytes ($p=0.003$) was significantly lower in the CLP group in comparison to the control group. Strong, positive correlations between IL-10 and OC ($rs=0.608$; $p=0.002$), IL-1 α and MMP-9 ($rs=0.666$; $p=0.000$), OPN and MMP-8 ($rs=0.620$; $p=0.002$) were detected in the CLP group. A tendency for the increased appearance of MMP-8, MMP-9 positive osteocytes of the patients with CLP, suggests elevated tissue remodelling properties. Increased appearance of OPN positive osteocytes in bone of the patients with CLP shows increased bone homeostasis based on seriously decreased mineralization, which may be a possible compensatory reaction to decreased quality of postsurgical bone.

Corresponding Author: Dace Buile, Department of Morphology, Institute of Anatomy and Anthropology, Riga Stradiņš University, 9 Kronvalda Str., LV-1010, Negaisa-3, LV-1024, Riga, Latvia. e-mail: dace.danberga@gmail.com
DOI: 10.14670/HH-18-451

Key words: CLP, Remodeling, Human, Bone

Introduction

Clefts of the lip and/or palate (CLP) are visible disruptions of the standard facial structure. They can cause a considerable morbidity to affected children and be a social burden for their families. The incidence of CLP among live births is approximately 1/700 that can be variable between different racial and ethnic groups (Dixon et al., 2011). Primary surgical correction of the cleft palate is typically performed at 12 months of age. However, approximately half of the patients might still need an additional multidisciplinary approach to restore a normal speech production (Ha et al., 2015). The midfacial region consists of mesenchymal cells derived from cranial neural crest (CNC) cells that give rise to the lateral and medial nasal processes, maxilla, and mandible. The identification of genes and remodeling factors that can influence CLP might help to understand their underlying molecular mechanisms (Suzuki et al., 2016). Nevertheless, up to this date, the latest research indicates the identification of tissue remodeling factors, cytokines, and local immunity factors in the pathogenesis of CLP. In this study, the impact of these factors in hard tissue (bone) of patients with CLP after the primary correctional surgery was evaluated.

Matrix metalloproteinases (MMPs) are zinc-dependent proteolytic enzymes that cleave extracellular matrix as well as growth factors. The deregulation of

Abbreviations. β def-2, Beta-defensin-2; β def-3, Beta-defensin-3; CLP, Cleft lip and palate; CNC, Cranial neural crest; ECM, Extracellular matrix; HBD, Human β -defensin; IL-1 α , Interleukin-1 alpha; IL-10, Interleukin-10; MMP, Matrix metalloproteinase; MMP-8, Matrix metalloproteinase-8; MMP-9, Matrix metalloproteinase-9; OC, Osteocalcin; OPN, Osteopontin; Runx2, Runt-related transcription factor 2; TGF- β , Transforming growth factor-beta; TNF- α , Tumor necrosis factor-alpha.



MMPs is involved in many diseases, such as tumor metastasis, rheumatoid arthritis, periodontal disease, and CLP (Yoon et al., 2003). They can be classified into subgroups that include the collagenases (MMP-1, MMP-8, MMP-13) and the gelatinases (MMP-2, MMP-9) (Cowan et al., 2009). Itagaki et al. in 2008 showed that MMP-8 is expressed by endothelial cells, osteoblasts, and osteocytes during bone healing in the parietal bone of rats. In the early phase, it acts as a recruiter for connective tissue to the defect site needed for wound healing and later as a degrading enzyme for extracellular matrix (ECM) proteins (Itagaki et al., 2008). MMP-9 is secreted by osteoclasts in bone during bone resorption and can also be present in tumor cells. When activated, MMP-9 promotes angiogenesis and cell migration (Christensen and Shastri, 2015). The loss of MMP-9 was found to not affect the bending strength of the bone despite causing a decrease in structure, but instead, MMP-9 deletion decreased bone stiffness, and MMP-9 may directly influence the organization extracellular matrix proteins found in bone (Nyman et al., 2011).

Osteopontin (OPN) is an acidic phosphoprotein that can be found in sites of bone nucleation. It binds calcium and may provide an initial scaffold for mineralization (Botham and Murray, 2018). Furthermore, OPN is involved in the inflammation process by inducing cell migration, adhesion, and inhibiting apoptosis of inflammatory cells. OPN activity is mediated by matrix metalloproteinases (MMPs), which inhibit the effects driven by OPN (Clemente et al., 2016). Osteocalcin (OC) is a protein which is produced by osteoblasts. Smaller amounts of OC are also produced by odontoblasts of the teeth and hypertrophic chondrocytes. It is one of the calcium-binding proteins that promote calcification of the ECM in bone (Zoch et al., 2016).

Runt-related transcription factor 2 (Runx2) belongs to the Runx family and is a transcription factor needed for the right layout of osteoblast cells. Runx2 also induces mesenchymal cell differentiation into immature osteoblasts (Dos Santos Pereira et al., 2017). An unbalanced distribution of the Runx2 might be a reason for cranial dysplasia due to the mutation in the Runt domain, which leads to impaired transaction activities of the Runx2 (Zhang et al., 2017).

Human β -defensins (HBD) are a subclass of antimicrobial peptides and act as the first line of the defense with their antimicrobial activity to kill microbes by destroying their cell membranes without the need for the cellular immune system. Varoga et al. demonstrated that osteoblasts were able to produce HBD-2 *in vitro* and in an animal model of staphylococcal osteomyelitis as a support for the immune system (Varoga et al., 2008). Periodontal ligament cells and human bone marrow stromal cells have proven to show higher antimicrobial resistance when transfected with a vector containing HBD-3 in the case of periodontitis (Zhu et al., 2017).

Pro-inflammatory cytokines act to enhance osteoclastogenesis, osteoclast differentiation, and activity in the bone. *In vivo*, Interleukin-1 (IL-1) is a crucial

regulatory cytokine in mouse models of inflammatory arthritis. Overexpression of IL-1 α leads to the development of arthritis with the destruction of cartilage and bone, while mice deficient in IL-1 receptor develop no arthritis (Ji et al., 2002; Yi et al., 2018). Interleukin-10 (IL-10) has immune suppression effects by downregulating secretion and release of inflammatory factors, such as tumor necrosis factor alpha (TNF- α), which play a role in regulating osteoblast and osteoclast functions. In bone marrow samples that were collected from osteoarticular tuberculosis patients undergoing ilium implantation, an overexpression of transforming growth factor-beta (TGF- β) and IL-10 significantly inhibited TNF- α synthesis and release, which resulted in suppression of osteoblast apoptosis and interfered with osteoclast formation and bone absorption (Yi et al., 2018).

The aim of the present study is to determine a relative number and appearance of the tissue factors (MMP-8, MMP-9, OC, OPN, Runx2, β def-2, β def-3, IL-1 α , IL-10) in the bone of patients with CLP during first time plastic alveolar osteoplasty or rhinoplasty.

Materials and methods

Patients

Tissue samples were obtained during first time alveolar osteoplasty and rhinoplasty in the Cleft Lip and Palate Centre of Institute of Stomatology of the Riga Stradiņš University. The patients group consisted of 25 patients with CLP between the ages of 6 years, seven months to 21 years, and one month with bone tissue

Table 1. Information about CLP patients.

Patient	Age	Surgery procedure
No. 1.	6 years 7 months	Rhinoplasty
No. 2.	8 years 5 months	Alveolar osteoplasty
No. 3.	8 years 11 months	Alveolar osteoplasty
No. 4.	9 years 5 months	Alveolar osteoplasty
No. 5.	9 years 11 months	Alveolar osteoplasty
No. 6.	12 years 7 months	Rhinoplasty
No. 7.	12 years 11 months	Rhinoplasty
No. 8.	13 years 5 months	Alveolar osteoplasty
No. 9.	13 years 9 months	Rhinoplasty
No. 10.	13 years 9 months	Rhinoplasty
No. 11.	14 years 5 months	Rhinoplasty
No. 12.	14 years 7 months	Rhinoplasty
No. 13.	15 years	Rhinoplasty
No. 14.	15 years	Rhinoplasty
No. 15.	15 years 10 months	Rhinoplasty
No. 16.	15 years 10 months	Alveolar osteoplasty
No. 17.	16 years 6 months	Rhinoplasty
No. 18.	17 years	Rhinoplasty
No. 19.	17 years	Rhinoplasty
No. 20.	17 years	Rhinoplasty
No. 21.	18 years 8 months	Alveolar osteoplasty
No. 22.	18 years 8 months	Alveolar osteoplasty
No. 23.	18 years 8 months	Alveolar osteoplasty
No. 24.	18 years 8 months	Alveolar osteoplasty
No. 25.	21 years 1 month	Rhinoplasty

Multiple tissue factor in bone of osteoplasty and rhinoplasty

samples (see Table 1) (Fig. 1A). The material for the control group was obtained from eleven patient septal bone between the ages of 12 and 14 years after the tooth extraction procedure (see Table 2) (Fig. 1B,C). Among the patients with CLP, there were 18 males and seven females (see Table 1), whereas among the control patients, there were five males and six females (see Table 2). This study was approved by the local Ethical Committee of the Riga Stradiņš University (Nr. 5/28.06.2018).

Methods

The material from the patients' group was fixated in transport test tubes with Stefanini solution and delivered to Riga Stradiņš University Laboratory of Morphology for further processing. Tyrode's solution was used for a rinse of the material for 24 hours, and alcohol solution was used for the increase of tissue dewatering, and tissue

was put into xylene for 30 minutes for degreasing. Afterward, the tissue was placed into paraffin for one and later two hours for the hardening process. Tissue blocks were cut into sections of 3 micrometers with a semiautomatic rotary microtome (Leica RM2245, Leica Biosystems Richmond Inc., United States). The sections were fixed on slides and dried in a thermostat, re-dewaxed in xylene, dehydrated in alcoholic solutions, and stained with hematoxylin and eosin (H&E). Afterwards, for the expression of proteins, the immunohistochemistry method was used. The tissue selections were stained and processed for the following antibodies: Matrix metalloproteinase-8 (MMP-8) (code: orb18114, rabbit, 1:100, Biorbyt USA), Matrix metalloproteinase-9 (MMP-9) (code: orb11064, rabbit, 1:100, Biorbyt USA), Osteopontin (OPN) (code: orb11191, rabbit, 1:100, Biorbyt USA), Osteocalcin (OC) (code: orb259644, rabbit, 1:100, Biorbyt USA),

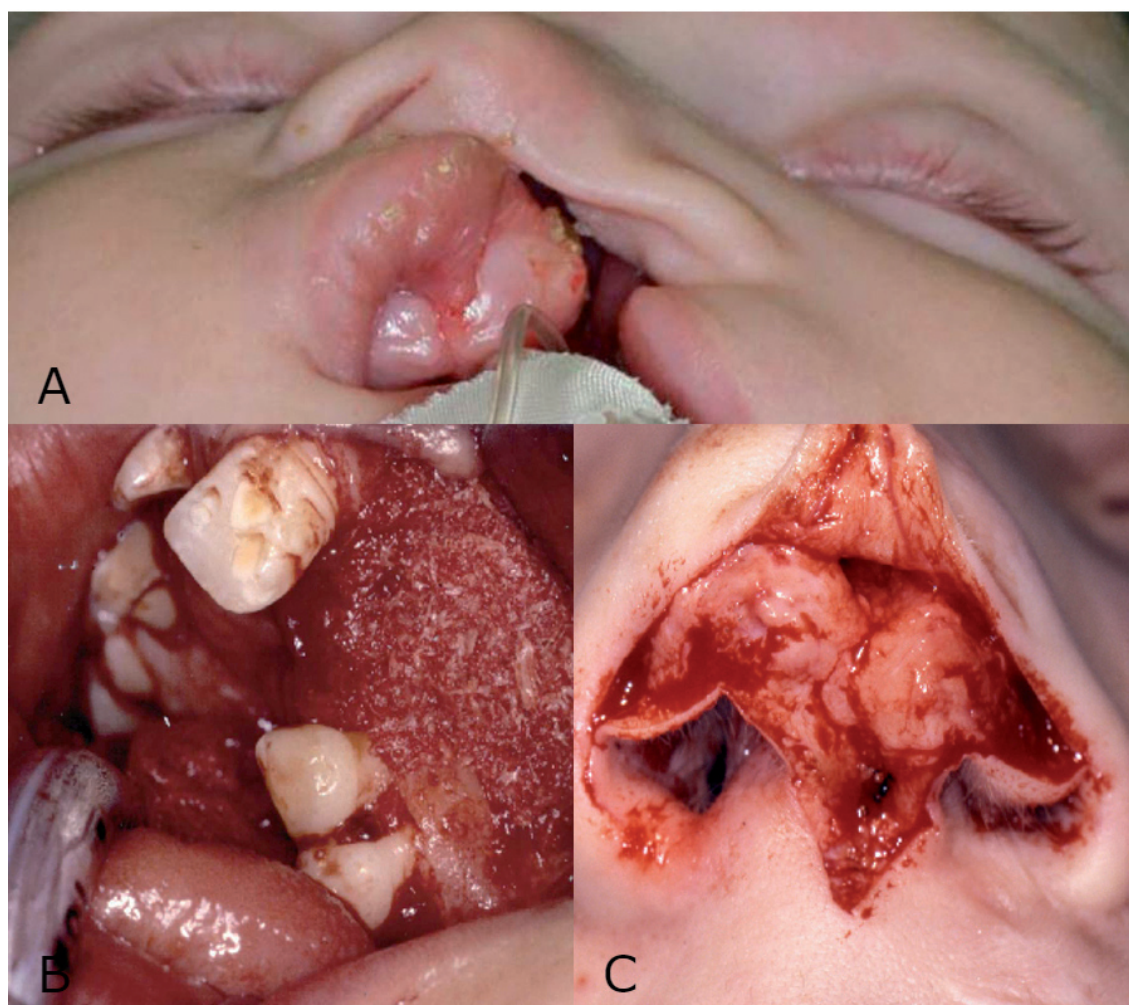


Fig. 1. Photographs of cleft lip and palate patient. **A.** Clinical picture of 4-month-old child with unilateral cleft lip, alveolus and palate (before surgical treatment). **B.** Secondary bone grafting in cleft lip, alveolus and palate patient. Cleft in the alveolar process is packet with spongy bone autotransplant. **C.** Secondary open nose plastic in cleft lip and palate patient. Photo (during operation).

Multiple tissue factor in bone of osteoplasty and rhinoplasty

Runx2 (code: AB192256, rabbit, 1:250, Abcam GB), beta-defensin-2 (β def-2) (code: sc-20789, rabbit, 1:100, Biorbyt USA), beta-defensin-3 (β def-3) (code: orb183268, rabbit, 1:100, Biorbyt USA), interleukin-1 alpha (IL-1 α) (code: orb308787, mouse, 1:100, Biorbyt USA), interleukin-10 (IL-10) (code: orb100193, rabbit, 1:600, Biorbyt USA).

For the quantification of immunological structures, the semi-quantitative census method was used (Pilmane and Šumahers, 2006; Pilmane et al. 2019). The labels were as follows: (0) - no positive structure was detected in the visual field (0/+) - occasional positive structures seen in the visual field, (+) - few positive structures seen in the visual field, (+/++) - few to moderate number of positive structures seen in the visual field, (++) - moderate number of positive structures seen in the visual field, (++) - moderate to numerous positive structures seen in the visual field, (+++) - numerous positive structures seen in the visual field, (+++/++++) - numerous to an abundance of positive structures seen in the visual field, (++++) - an abundance of positive structures seen in the visual field.

Masson-trichrome staining (Masson) was performed as follows: the tissue was fixed in Bouin's solution, embedded in wax, and stained with Weigert iron

hematoxylin for nuclei, picric acid for erythrocytes, a mixture of acid dyes (acid fuchsin - "ponceau de xylidine") for cytoplasm and aniline blue for connective tissue. In the sections of Masson staining, bone and cartilage appeared red, collagen and osteoid - blue, red blood cells - orange, nucleus - blue black (Ou and Huang, 2021).

Statistical analysis of the data

For the statistical analysis, the SPSS 22.0 program version (IBM Corp., Armonk, NY, USA) was used. Spearman's rank correlation coefficient (rs) was used for the determination of correlations between values. The results were interpreted: rs=0.4 - 0.59 - moderate, positive correlation, rs=0.6 - 0.79 - strong, positive correlation. Mann-Whitney U-test was performed for the comparison of the study groups, a normality test was not performed; a P value <0.05 was considered statistically significant.

Results

Routine histology

Routine histology in hematoxylin and eosin did not reveal bone tissue changes that would be out of control, but in some cases, there was a small amount of osteons, which were placed chaotically or were observed in different sizes. The irregular thickness of bone lamellae was also observed. In other cases, osteon channels that were filled with connective tissue were detected. All of the above mentioned might suggest characteristic sclerotic changes in the bone of patients with CLP (Fig. 2D).

Masson-trichrome staining

Representative Masson trichrome staining images of patients with CLP showed that new bone formation

Table 2. Information about the control group.

Patient	Age	Surgery procedure
No. 1.	12 years	Tooth extraction
No. 2.	12 years	Tooth extraction
No. 3.	12 years	Tooth extraction
No. 4.	12 years	Tooth extraction
No. 5.	13 years	Tooth extraction
No. 6.	13 years	Tooth extraction
No. 7.	13 years	Tooth extraction
No. 8.	13 years	Tooth extraction
No. 9.	14 years	Tooth extraction
No. 10.	14 years	Tooth extraction
No. 11.	14 years	Tooth extraction

Table 3. The most common relative number of factor positive cells in the control group and CLP patients.

	IL-1 α	IL-10	β def-2*	β def-3	MMP8	MMP9	OPN*	OC*
Patient group	0/+ - +++	0/+ - +++/++++	0/+ - +++	0/+ - +++	0/+ - +++	0/+ - +++/++++	0/+ - +++	0/+ - +++
Median value	+	+/++	+/++	+/++	+/++	+/++	+/++	++
Modal value	+	+	+	+	+/++	+/++	+	++
Control group	0 - ++/++++	0/+ - +++/++++	+ - +++/++++	+ - +++/++++	0/+ - +++/++++	0/+ - ++/++++	0 - ++/++++	++/+++ - +++++
Median value	+	++	++	++	++	+/++	0/+	+++
Modal value	+	+/++	++	+/++	++	+/++	0/+	+++

IL-1 α , Interleukin-1 alpha; IL-10, Interleukin-10; β def-2, Beta defensin-2; β def-3, Beta defensin-3; MMP-8, Matrix metalloproteinase-8; MMP-9, Matrix metalloproteinase-9; OPN, Osteopontin; OC, Osteocalcin; Median value, middle number in a sorted list of numbers; Modal value, The number which appears most often in a set of numbers. Quantification of Structures: 0, no positive structures in the visual field; 0/+, occasional positive structures in the visual field; +, few positive structures in the visual field; + / ++, few to moderate positive structures in the visual field; ++, moderate positive structures in the visual field; ++ / +++, moderate to numerous positive structures in the visual field; +++, numerous positive structures in the visual field; +++ / +++++, numerous to abundant positive structures in the visual field. *, There was a statistically significant difference between the CLP group and the control group.

Multiple tissue factor in bone of osteoplasty and rhinoplasty

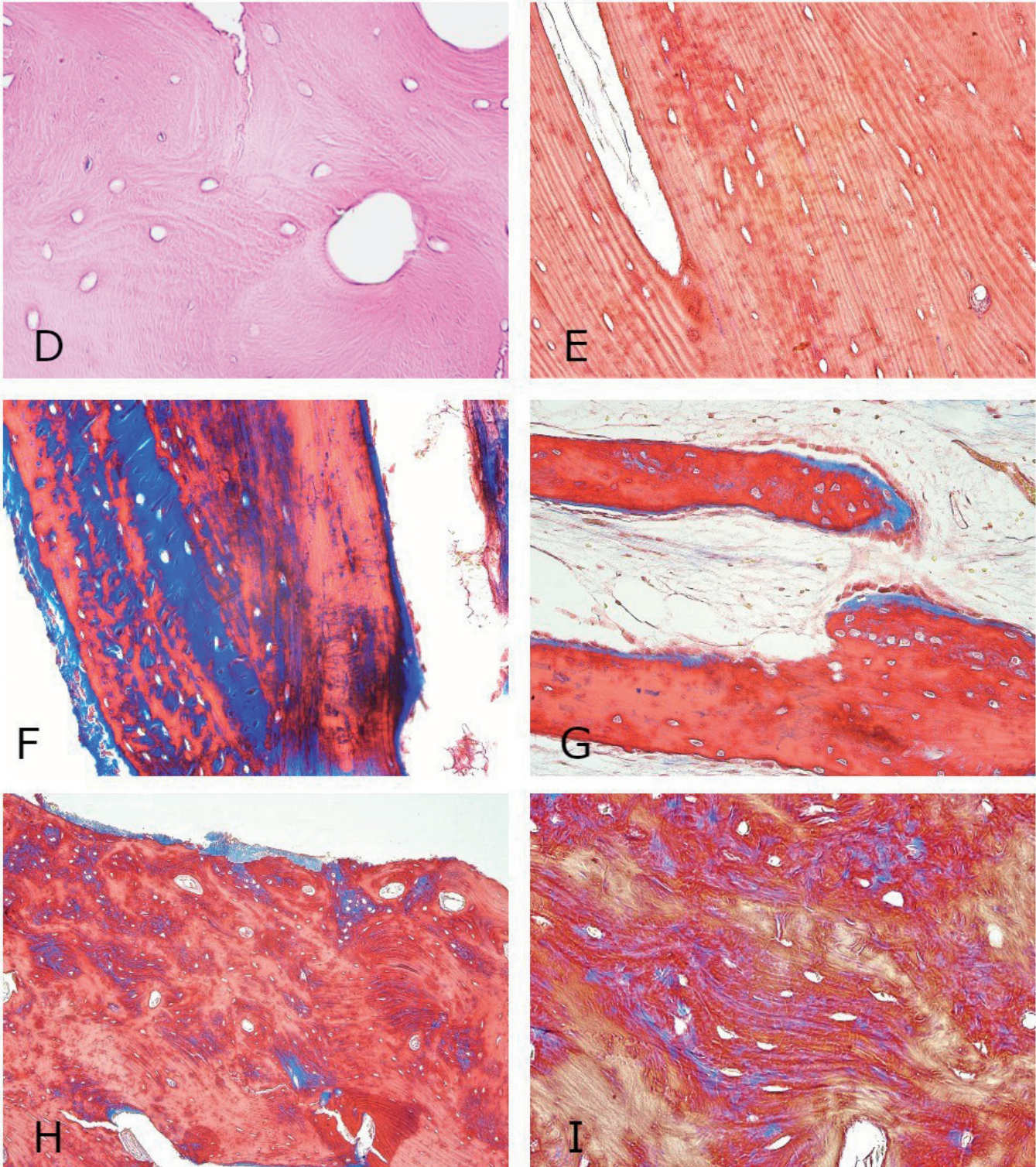


Fig. 2. Microphotographs of H&E and Masson's trichrome of hard tissue in cleft affected patients. **D.** The irregular thickness of bone lamellae observed in the bone of 12 years 5 months old patient with CLP, H&E. **E.** Masson's trichrome staining of 18 years and 8 months old patient with CLP showing absence of formation of new bone. **F.** Masson's trichrome staining of 13 years and 9 months old patient with CLP showing formation of a new bone tissue in the bone lamellae. **G.** Masson's trichrome staining of 17-year-old patient with CLP showing formation of a new bone tissue in the periphery of bone. **H.** Masson's trichrome staining 18 years and 8 months old patient with CLP showing formation of a new bone tissue in the bone lamellae. **I.** Masson's trichrome staining 18 years and 8 months old patient with CLP showing formation of a new bone tissue in the bone lamellae. D, I, x 400; E, F, x 250; G, x 200; H, x 100.

Multiple tissue factor in bone of osteoplasty and rhinoplasty

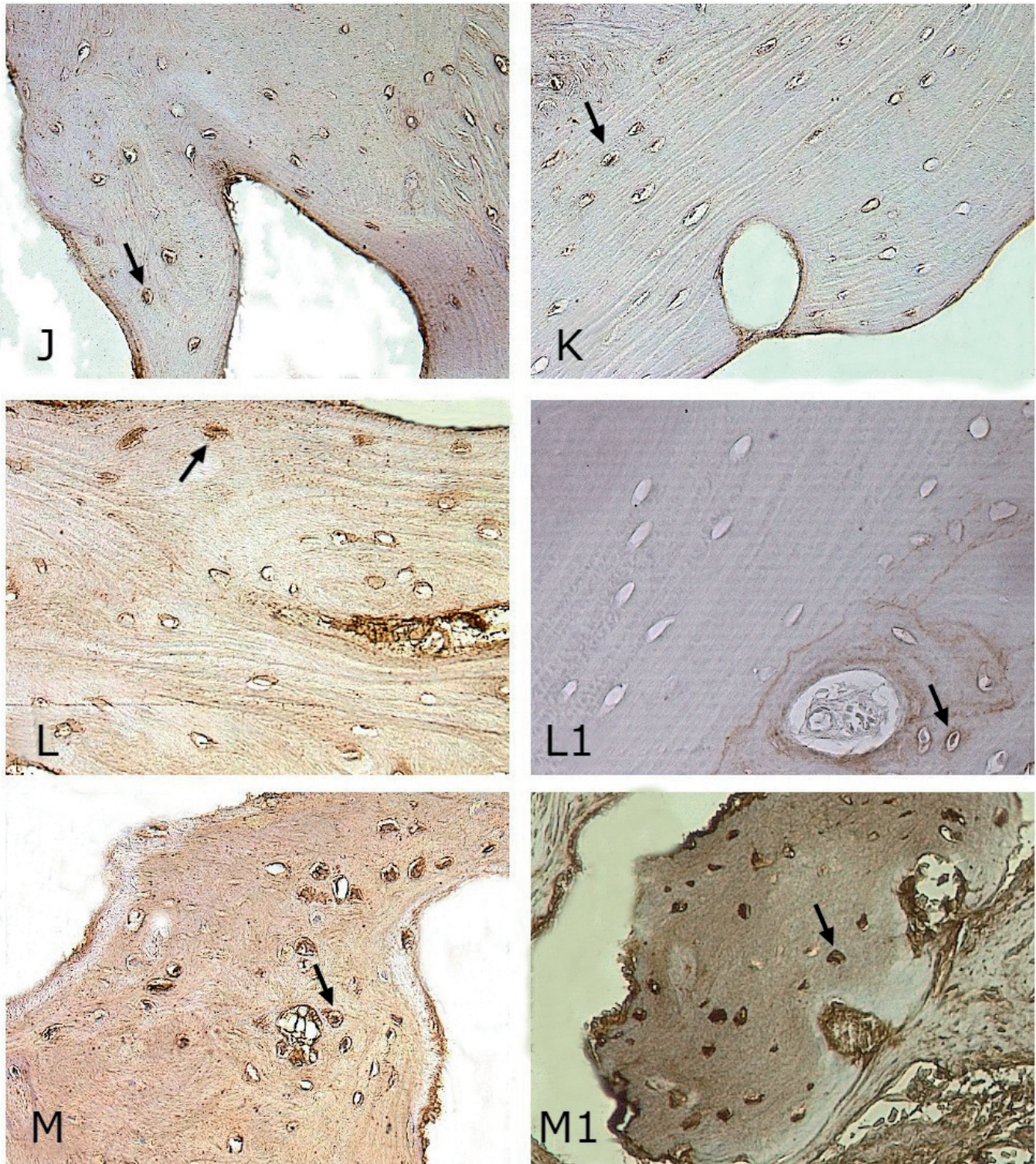


Fig. 3. Microphotographs of relative number in different factors of hard tissue in cleft affected patients. Involvement of markers evaluated in histological micrographs are indicated with arrows. **J.** Few to moderate number of MMP-8 positive osteocytes observed in the bone of 17-year-old patient with CLP. Immunohistochemistry. **K.** Few to moderate number of MMP-9 positive osteocytes observed in the bone of 18 years and 8 months old patient with CLP. Immunohistochemistry. **L.** Few OPN positive osteocytes observed in the bone of 8 years and 5 months old patient with CLP. Immunohistochemistry. **L1.** Occasional number of OPN positive osteocytes observed in the bone of 12-year-old control group patient. Immunohistochemistry. **M.** Moderate number of OC positive osteocytes observed in the bone of 18 years and 8 months old patient with CLP. Immunohistochemistry. **M1.** Numerous of OC positive osteocytes observed in the bone of 13-year-old control group patient. Immunohistochemistry. x 400.

Multiple tissue factor in bone of osteoplasty and rhinoplasty

occurred at the periphery of bone trabeculae and inside the bone lamellae, indicating the remodeling properties of the bone for the majority of the patients (Fig. 2F,I). For a minority of the patients with CLP there was an absence of new bone formation (Fig. 2E).

MMP-8

MMP-8 positive cells were detected in all bone tissue samples from the CLP group and the control group. The number of MMP-8 positive osteocytes in both groups varied from occasional to numerous in the CLP group and moderate to abundant in the control group. The modal value of MMP-8 positive cells in the CLP group was few to moderate, but in the control group it was higher - moderate number of positive structures (Fig. 3J) (see Table 3). No statistically significant difference was found between the CLP group and the control group ($U=87.0$; $p=0.099$).

MMP-9

MMP-9 positive cells were detected in all specimens. The number of MMP-9 positive osteocytes in both- the CLP group and the control group- varied from occasional to moderate to numerous. The modal value of MMP-9 positive osteocytes was the same in both groups - moderate to numerous (Fig. 3K) (see Table 3). There was no statistically significant difference in numbers of MMP-9 positive osteocytes between the CLP group and the control group ($U=136.0$; $p=0.058$).

OPN

OPN positive cells were detected in all bone samples from the CLP group, where the number of OPN positive osteocytes varied from occasional to numerous. OPN positive cells were not detected in all samples from the control group, where OPN positive osteocytes ranged from moderate to numerous. The modal value in the CLP group was few, while in the control group, it was occasional (Fig. 3L) (see Table 3). A significantly higher number of OPN positive osteocytes was observed in the CLP group when compared to the control group (Fig. 3L1) ($U=28.0$; $p=0.002$).

OC

OC positive cells were detected in all bone tissue samples from the CLP group and the control group. The number of OC positive osteocytes in the CLP group varied from occasional to numerous, while in the control group, it varied from moderate to numerous to abundant. The modal value of the CLP group was lower than in the control group - a moderate number of OC positive osteocytes in the CLP group compared to numerous in the control group (Fig. 3M) (see Table 3). The number of OC positive osteocytes was significantly lower in the CLP group when compared to the control group (Fig.

3M1) ($U=15.0$; $p=0.000$).

β def-2

β def-2 positive cells were detected in all bone tissue samples from the CLP group and the control group. The number of β def-2 positive osteocytes in the CLP group varied from occasional to numerous, while in the control group, it varied from few to numerous to abundant. The modal value of β def-2 positive osteocytes in the CLP group was few, while in the control group there was a moderate number of β def-2 positive osteocytes (Fig. 4N) (see Table 3). A significantly lower number of β def-2 positive osteocytes was observed in the CLP group in comparison to the control group (Fig. 4N1) ($U=50.0$; $p=0.003$).

β def-3

β def-3 positive cells were detected in all bone tissue samples from the CLP group and the control group. The number of β def-3 positive osteocytes in the CLP group varied from occasional to numerous, while in the control group, it varied from few to numerous to abundant. The modal value of the β def-3 positive osteocytes in the CLP group was few, while in the control group, it was higher - few to a moderate number of β def-3 positive cells (Fig. 4O) (see Table 3). No statistically significant difference was found between the CLP group and the control group ($U=89.5$; $p=0.164$).

IL-1 α

IL-1 α positive osteocytes were detected in all bone tissue samples from the CLP group, and they varied from occasional to numerous. There was an absence of IL-1 α positive osteocytes in one specimen of the control group, but the results ranged from moderate to numerous. The modal value of the IL-1 α positive cells was few in both groups (Fig. 4P) (see Table 3). No statistically significant difference was found between the CLP group and the control group ($U=121.0$; $p=0.684$).

IL-10

IL-10 positive cells were observed in all bone samples, and the number of IL-10 positive osteocytes in both- the CLP group and the control group- was very variable - from occasional to numerous and abundant. The modal value of IL-10 positive cells was few in the CLP group and few to moderate in the control group (Fig. 4Q) (see Table 3). However, no statistically significant difference between the two groups was found ($U=96.0$; $p=0.173$).

Runx2

Mainly there was an absence of Runx2 positive osteocytes in the control group in comparison to the CLP

Multiple tissue factor in bone of osteoplasty and rhinoplasty

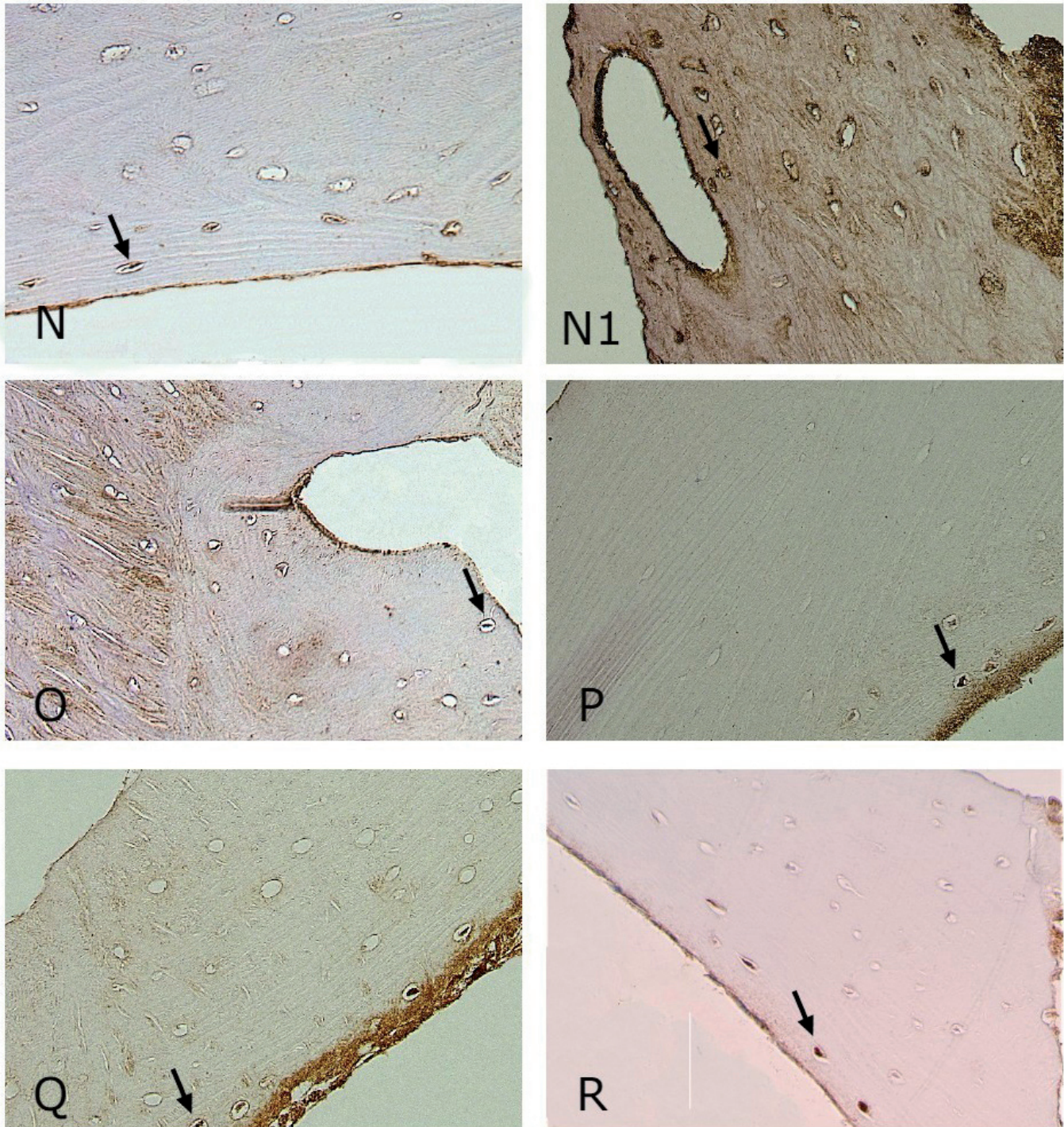


Fig. 4. Microphotographs of relative number in different factors of hard tissue in cleft affected patients. Involvement of markers evaluated in histological micrographs are indicated with arrows. **N.** Few β def-2 positive osteocytes observed in the bone of 18 years and 8 months old patient with CLP. Immunohistochemistry. **N1.** Moderate number of β def-2 positive osteocytes observed in the bone of 12-year-old control group patient. Immunohistochemistry. **O.** Few β def-3 positive osteocytes observed in the bone of 15-year-old patient with CLP. Immunohistochemistry. **P.** Few IL-1 α positive osteocytes observed in the bone of 12 years and 11 months old patient with CLP. Immunohistochemistry. **Q.** Few IL-10 positive osteocytes observed in the bone of 12 years and 11 months old patient with CLP. Immunohistochemistry. **R.** Few Runx2 positive osteocytes observed in the bone of 15-year-old patient with CLP. Immunohistochemistry. N-Q, x 400; R, x 250.

Multiple tissue factor in bone of osteoplasty and rhinoplasty

group, in which an absence of Runx2 expression was observed only in three bone tissue samples, but relative number of Runx2 positive cells ranged up to few. There was no significant difference in the median numbers of Runx2 positive cells between the groups (Fig. 4R) (U=41.0; p=0.073).

Statistical data

Statistically significant ($p < 0.05$) strong ($r_s = 0.6-0.79$) correlations were found between IL10 and OC ($r_s = 0.608$; $p = 0.002$); IL-1 α and MMP-9 ($r_s = 0.666$; $p = 0.000$); OPN and MMP-8 ($r_s = 0.620$; $p = 0.002$); Runx2 and MMP-9 ($r_s = 0.742$; $p = 0.002$); Runx2 and β def-2 ($r_s = 0.671$; $p = 0.009$); Runx2 and IL-10 ($r_s = 0.662$; $p = 0.010$); Runx2 and MMP-8 ($r_s = 0.862$; $p = 0.000$); Runx2 and OC ($r_s = 0.727$; $p = 0.003$) in the CLP group (see Table 4).

Statistically significant ($p < 0.05$) moderate ($r_s = 0.4-0.59$) correlations were found between β def-2 and β def-3 ($r_s = 0.545$; $p = 0.007$); β def-2 and MMP-8 ($r_s = 0.415$; $p = 0.044$); β def-3 and IL-1 ($r_s = 0.439$; $p = 0.036$); β def-3 and OC ($r_s = 0.447$; $p = 0.033$); β def-3 and MMP-8 ($r_s = 0.418$; $p = 0.047$); IL-1 α and IL-10 ($r_s = 0.485$; $p = 0.016$); IL-1 α and OPN ($r_s = 0.581$; $p = 0.003$); IL-1 α and MMP-8 ($r_s = 0.416$; $p = 0.032$); IL-10 and OPN ($r_s = 0.411$; $p = 0.046$); OPN and MMP-9 ($r_s = 0.416$;

$p = 0.043$); OC and MMP-8 ($r_s = 0.458$; $p = 0.028$); Runx2 and β def-3 ($r_s = 0.607$; $p = 0.021$); Runx2 and OPN ($r_s = 0.611$; $p = 0.020$) in the CLP group (see Table 4).

Discussion

Cleft lip palate is one of the most common head and neck congenital malformations. Obtaining a better insight into cellular events in the bone is not only central for a better understanding of the pathology, but also for the means to control it and develop new therapies (Meng et al., 2020). In this study, various tissue factors were investigated, which may contribute to the bone repair and healing after primary plastic osteoplasty, which still has not been entirely investigated.

Interleukin-1 was the first interleukin out of 11 members to be described. IL-1 α is expressed at low levels under normal conditions, but under induction, it increases T cell and B cell responses in the pathway of adaptive immune responses (Ji et al., 2002). It serves as a potent pro-inflammatory cytokine attracting monocytes and neutrophils to the site of tissue damage, inducing MMPs and altering bone homeostasis, being released upon cell necrosis. IL-1 α activates other cytokines such as IL-1 β , IL-6, and TNF- α upon the inflammation process (Schett et al., 2016). In the bone, IL-1 α is produced by osteoblasts, and increased levels can lead to increased bone resorption. This is observed in cases of periapical periodontitis, where higher levels of IL-1 α correlated with the severity of inflammation (Yang et al., 2018). Moreover, these observations of IL-1 α effects on inflammation are supportive for findings in patients with osteoarthritis, where IL-1 α inhibition leads to improved symptoms of the disease (Chevalier et al., 2009). On the other hand, injection of IL-1 receptor antagonist resulted in a reduced number in activated osteoclasts, therefore leading to delayed tooth eruption (Meng et al., 2020). In our study, the numbers of IL-1 α positive osteocytes were low in the CLP group. Moreover, there was no statistically significant ($p < 0.05$) difference between the CLP group and the control group, suggesting that pro-inflammatory cytokines such as IL-1 α , although contributing to disease, is not the prevailing mechanism in the pathogenesis of CLP.

IL-10, in contrast to IL-1 α , is an anti-inflammatory cytokine that can inhibit the release of inflammatory factors and regulate the differentiation and functions of osteoblasts and osteoclasts. Yi et al. showed that increased numbers of IL-10 decreased osteoblast apoptosis, lowered bone absorption, and decreased TNF- α numbers *in vitro* (Yi et al., 2018). Elevated levels of IL-10 promoted the osteogenesis of dental pulp stem cells, enhancing the osteogenic differentiation (Yuan et al., 2021). The present study showed few IL-10 positive osteocytes in the CLP group, and there was no statistically significant difference between the CLP group and the control group. Interestingly, the low levels of IL-10 positive cells made a strong, statistically significant positive correlation with moderate OC

Table 4. Summary of Spearman's rank correlation analysis to determine the strong and moderate relationship between numbers of positive factors in the CLP group.

Factor 1	Factor 2	P value	r_s
Statistically significant ($p < 0.05$) strong correlations ($r_s = 0.6-0.79$)			
IL-10	OC	$p = 0.002$	$r_s = 0.608$
IL-1 α	MMP-9	$p = 0.000$	$r_s = 0.666$
OPN	MMP-8	$p = 0.002$	$r_s = 0.620$
Runx2	MMP-9	$p = 0.002$	$r_s = 0.742$
Runx2	β def-2	$p = 0.009$	$r_s = 0.671$
Runx2	IL-10	$p = 0.010$	$r_s = 0.662$
Runx2	MMP-8	$p = 0.000$	$r_s = 0.862$
Runx2	OC	$p = 0.003$	$r_s = 0.727$
Statistically significant ($p < 0.05$) moderate correlations ($r_s = 0.40-0.59$)			
β def-2	β def-3	$p = 0.007$	$r_s = 0.545$
	MMP-8	$p = 0.044$	$r_s = 0.415$
β def-3	IL-10	$p = 0.036$	$r_s = 0.439$
	OC	$p = 0.033$	$r_s = 0.447$
	MMP-8	$p = 0.047$	$r_s = 0.418$
IL-1 α	IL-10	$p = 0.016$	$r_s = 0.485$
	OPN	$p = 0.003$	$r_s = 0.581$
	MMP-8	$p = 0.032$	$r_s = 0.448$
IL-10	OPN	$p = 0.046$	$r_s = 0.411$
OPN	MMP-9	$p = 0.043$	$r_s = 0.416$
OC	MMP-8	$p = 0.028$	$r_s = 0.458$
Runx2	β def-3	$p = 0.021$	$r_s = 0.607$
Runx2	OPN	$p = 0.020$	$r_s = 0.727$

r_s , Spearman's rank correlation coefficient; IL-1 α , Interleukin-1 alpha; IL-10, Interleukin-10; β def-2, Beta defensin-2; β def-3, Beta defensin-3; MMP8, Matrix metalloproteinase-8; MMP-9, Matrix metalloproteinase-9; OPN, Osteopontin; OC, Osteocalcin.

positive cells ($rs=0.608$; $p=0.002$), probably indicating the compensatory anti-inflammatory protective mechanism in the bone of patients with CLP.

Runx is necessary for the right layout of osteoblast cells. It promotes bone mineralization, osteoblast proliferation and induces mesenchymal cell differentiation into immature osteoblasts until the final stage of process in which maturity of osteoblasts is inhibited (Dos Santos Pereira et al., 2017). Runx2 protein expression can also be used as a measurement in bone therapy with osteoblast proliferation (Liu et al., 2021). Our results indicated that there was no statistically significant difference between the CLP group and the control group, but the numbers of Runx2 positive structures in the bone was low, indicating a problematic osteoblast formation and probably reduced mineralization potential. Similar results were reported by Qin et al. where silencing of Runx2 repressed the osteoblasts, potentially leading to tooth eruption disorder (Qin and Cai, 2018).

Defensins are antimicrobial peptides that can also modulate the immune response and protect the host by attracting immune cells and modulate cellular functions (Fruitwala et al., 2019). Two types of Human beta defensins - β def-2 and β def-3 were investigated, and statistically significant ($p<0.05$) difference between the study groups were observed only on β def-2, where the CLP group presented a lower amount of β def-2 than the control group ($U=50.0$; $p=0.003$). β def-3 positive osteocytes in the CLP group were few, without statistically significant differences between the groups. In bone tissue engineering the occurrence of infections is one of the main causes of bone graft failure; thus, incorporating β def-2 in the graft inhibited bacterial growth, as well as promoted osteogenic differentiation and bone healing (Ren et al., 2021). In another study, the suppressed levels of β def-2 in the human gingival epithelium demonstrated that it could be a possible mechanism for the intensification of periodontal disease (Mahanonda et al., 2009). In another study, after a treatment of osteonecrosis of the jaw, significantly increased mRNA expression of β def-3 was observed, suggesting that it could be a promising target for the treatment of disease (Thiel et al., 2020).

Our results possibly indicate reduced local immunity mechanisms present in the bone of patients with CLP, and it may influence healing properties on bone after the primary osteoplasty.

MMPs are calcium-dependent, zinc-containing endopeptidases, responsible for tissue remodeling and degradation of components of ECM, such as collagens, elastins, gelatin, matrix glycoproteins, and proteoglycans. MMPs are usually minimally expressed in normal physiological conditions, and thus tissue homeostasis is maintained (Kapoor et al., 2016). MMP8 is a collagenase with functions to destroy collagen types I, II, III, V, and IX. It also has significance in tissue regeneration and organ development by performing ECM remodeling (Van Doren, 2015). The dysregulation

of MMP-8 levels can participate in multiple pathological conditions, such as periodontitis (Kraft-Neumarker et al., 2012), periradicular lesions (Matsui et al., 2011), and osteonecrosis of the femoral head (Jiang et al., 2018). In a study with rats with alveolar bone damage, better bone healing was exhibited with a significantly decreased MMP-8 expression (Prahasanti et al., 2020).

Disruption in the activity of MMPs is also involved in the process of abnormal palatogenesis resulting in CLP (Brown et al., 2002). Nyman et al. found that MMP-9-null mice had improved the density of the bone trabeculae and lowered bone volume fraction in the vertebra, showing the complexity of bone integrity (Nyman et al., 2011). Bone repair in apical periodontitis resulted in reduced amount of osteoclasts and lower synthesis of MMP-9, thus showing a faster recovery (Paula-Silva et al., 2021). The results of our study showed the modal value for both MMP-8 and MMP-9 positive osteocytes was moderate to numerous in the CLP group. Although, no statistically significant ($p<0.05$) differences were found between the CLP group and the control group. The statistically significant strong positive correlations between the IL-1 α and MMP-9 ($rs=0.666$; $p=0.000$) and between OPN and MMP-8 ($rs=0.620$; $p=0.002$) could possibly indicate the increased bone remodeling properties in patients with CLP.

Osteopontin is a glycoprotein secreted by activated immune system cells like macrophages and leukocytes and can be found at sites of inflammation and the ECM of mineralized tissues. It takes place in leading macrophages to the site of inflammation (Gravallese, 2003). OPN has the ability to bind Ca²⁺ and hydroxyapatite to participate in the regulation of the mineralization process, but in the initial process of bone remodeling it can recruit osteoclasts into an active area of bone resorption (Gerstenfeld, 1999). Foster et al. detected that loss of OPN in mice increased volume and mineral density of alveolar bone and promoted dentin and cellular cementum formation that indicates the OPN role in controlling bone matrix mineralization (Foster et al., 2018). Moreover, OPN absence displayed greater matrix disorganization and altered collagen fibrillogenesis at the wound site, affecting matrix-matrix adhesion, changing bone mechanical integrity (Depalle et al., 2021). These observations of the OPN effects are supportive of findings in patients with multiple myeloma, where higher levels of OPN correlated with more bone loss, therefore probably protecting the bone from destruction (Robbani et al., 2007). In our study, a statistically significant ($p<0.05$) increase in the amount of OPN in the bone of the patients with CLP in comparison to the control group was observed. Moreover, there was a statistically significant strong positive correlation between OPN and MMP-8 positive osteocytes ($rs=0.620$; $p=0.002$) in the bone of the patients with CLP. These findings may suggest intensified bone homeostasis, which could be a possible protective reaction to inflammation.

Osteocalcin is a protein mostly expressed by

Multiple tissue factor in bone of osteoplasty and rhinoplasty

osteoblasts, a specific non-collagenous protein of ECM under the control of the Runx2/Cbfa1 transcription factor. It regulates bone remodeling by modulating osteoblasts and osteoclast activity, and acts as a regulator of bone mineralization (Oury and Oury, 2018). In 1996 Ducy et al. developed osteocalcin-deficient mice, which developed higher cortical bone mass and improved functional quality without affecting the bone mineralization process, but with smaller mineral crystals in ECM (Ducy et al., 1996). In 2018 Poundarik et al. showed that OC is more dominant in the regulation of mineral thickness of bone mineral, while OPN is more responsible for the elemental composition of bone mineral in developing the osteocalcin-null/osteopontin-null mice. This suggests that these smaller crystals in the OC-null mice might be explained by incomplete mineral apposition, and OC may function to maintain the normal bone anisotropy (Poundarik et al., 2018). High levels of osteocalcin in bone were observed, which formed a suitable, mature bone for receiving dental implants (Pereira et al., 2020). In our study, a statistically significant decrease in OC positive osteocytes in the CLP group in comparison to the control group was found. A strong, statistically significant positive correlation was observed with IL-10 ($r_s=0.608$; $p=0.002$). These findings probably suggest that OC plays a role in increased bone mineralization in patients with CLP, probably as a response to bone healing after primary osteoplasty.

Conclusions

The low appearance of IL-10, β def-2 and β def-3, and positive osteocytes in the bone of the patients with CLP indicate a tendency for reduced anti-inflammatory mechanism in the bone after primary osteoplasty.

A tendency for the increased appearance of MMP-8, MMP-9 positive osteocytes in the bone of the patients with CLP, suggests increased bone degradation, therefore elevated tissue remodeling properties.

A low number of Runx2 positive cells in bone indicates a problematic cell transformation into the osteoblasts and problematic mineralization in case of CLP.

Increased appearance of OPN positive osteocytes in the bone of the patients with CLP shows increased bone homeostasis on the basis of seriously decreased mineralization, which may be a possible compensatory reaction to a decreased quality of postsurgical bone.

Acknowledgements. Riga Stradiņš University kind support for the research is highly acknowledged.

Conflict of Interests. Authors declare no Conflict of Interests for this article.

References

Botham K.M. and Murray R.K. (2018). The extracellular matrix. In Harper's illustrated biochemistry. 31e. Rodwell V.W., Bender D.A.,

- Botham K.M., Kennelly P.J. and Weil P.A. (eds). McGraw-Hill Education. New York.
- Brown N.L., Yarram S.J., Mansell J.P. and Sandy J.R. (2002). Matrix metalloproteinases have a role in palatogenesis. *J. Dent. Res.* 81, 826-830.
- Chevalier X., Goupille P., Beaulieu A.D., Burch F.X., Bensen W.G., Conrozier T., Loeuille D., Kivitz A.J., Silver D. and Appleton B.E. (2009). Intraarticular injection of anakinra in osteoarthritis of the knee: a multicenter, randomized, double-blind, placebocontrolled study. *Arthritis Rheum.* 61, 344-352.
- Christensen J. and Shastri V.P. (2015). Matrix-metalloproteinase-9 is cleaved and activated by cathepsin K. *BMC Res. Notes* 8, 322-322.
- Clemente N., Raineri D., Cappellano G., Boggio E., Favero F., Soluri M.F., Dianzani C., Comi C., Dianzani U. and Chiochetti A. (2016). Osteopontin bridging innate and adaptive immunity in autoimmune diseases. *J. Immunol. Res.* 7675437.
- Cowan R.W., Mak I.W.Y., Colterjohn N., Singh G. and Ghert M. (2009). Collagenase expression and activity in the stromal cells from giant cell tumour of bone. *Bone* 44, 865-871.
- Depalle B., McGilvery C.M., Nobakhti S., Aldegaitner N., Shefelbine S.J. and Porter A.E. (2021). Osteopontin regulates type I collagen fibril formation in bone tissue. *Acta Biomater.* 120, 194-202.
- Dixon M.J., Marazita M.L., Beaty T.H. and Murray J.C. (2011). Cleft lip and palate: understanding genetic and environmental influences. *Nat. Rev. Genet.* 12, 167-178.
- Dos Santos Pereira R.S., Boos F.B., Gorla L.F., Garcia I.R., Okamoto R., Hochuli-Vieira E. (2017). Maxillary sinus elevation surgery with chronos and autogenous bone graft: Immunohistochemical assessment of RUNX2, VEGF, TRAP and osteocalcin. *Int. J. Periodontics Restorative Dent.* 37, 321-327.
- Ducy P., Desbois C., Boyce B., Pinero G., Story B., Dunstan C., Smith E., Bonadio J., Goldstein S., Gundberg C., Bradley A. and Karsenty G. (1996). Increased bone formation in osteocalcin-deficient mice. *Nature* 382, 448-452.
- Foster B.L., Ao M., Salmon C.R., Chavez M.B., Kolli T.N., Tran A.B., Chu E.Y., Kantovitz K.R., Yadav M., Narisawa S., Millan J.L., Nociti F.H., Jr. and Somerman M.J. (2018). Osteopontin regulates dentin and alveolar bone development and mineralization. *Bone* 107, 196-207.
- Fruitwala S., El-Naccache D.W. and Chang T.L. (2019). Multifaceted immune functions of human defensins and underlying mechanisms. *Semin. Cell Dev. Biol.* 88, 163-172.
- Gerstenfeld L.C. (1999). Osteopontin in skeletal tissue homeostasis: An emerging picture of the autocrine/paracrine functions of the extracellular matrix. *J. Bone Miner. Res.* 14, 850-855.
- Gravallese E.M. (2003). Osteopontin: a bridge between bone and the immune system. *J. Clin. Invest.* 112, 147-149.
- Ha S., Koh K.S., Moon H., Jung S. and Oh T.S. (2015). Clinical outcomes of primary palatal surgery in children with nonsyndromic cleft palate with and without lip. *Biomed. Res. Int.* 185459-185459.
- Itagaki T., Honma T., Takahashi I., Echigo S. and Sasano Y. (2008). Quantitative analysis and localization of mRNA transcripts of type I collagen, osteocalcin, MMP 2, MMP 8, and MMP 13 during bone healing in a rat calvarial experimental defect model. *Anat. Rec. (Hoboken)*. 291, 1038-1046.
- Ji H., Pettit A., Ohmura K., Ortiz-Lopez A., Duchatelle V., Degott C., Gravallese E., Mathis D. and Benoist C. (2002). Critical roles for interleukin 1 and tumor necrosis factor alpha in antibody-induced arthritis. *J. Exp. Med.* 196, 77-85.
- Jiang L., Zhang C. and Wei B. (2018). Association of MMP-8 rs2012390

- and rs11225394 polymorphisms with osteonecrosis of the femoral head risks: Evidence from a metaanalysis. *Medicine (Baltimore)*. 97, e12753-e12753.
- Kapoor C., Vaidya S., Wadhwan V., Kaur G. and Pathak A. (2016). Seesaw of matrix metalloproteinases (MMPs). *J. Cancer Res. Ther.* 12, 28-35.
- Kraft-Neumarker M., Lorenz K., Koch R., Hoffmann R., Mantyla P., Sorsa T. and Netuschil L. (2012). Full-mouth profile of active MMP-8 in periodontitis patients. *J. Periodontol Res.* 47, 121-128.
- Liu X.W., Ma B., Zi Y., Xiang L.B. and Han T.Y. (2021). Effects of rutin on osteoblast MC3T3-E1 differentiation, ALP activity and Runx2 protein expression. *Eur. J. Histochem.* 20 65, 3195.
- Mahanonda R., Sa-Ard-lam N., Eksomtramate M., Rerkyen P, Phairat B., Schaecher K.E., Fukuda M.M. and Pichyangkul S. (2009). Cigarette smoke extract modulates human beta-defensin-2 and interleukin-8 expression in human gingival epithelial cells. *J. Periodontol Res.* 44, 557-564.
- Matsui H., Yamasaki M., Nakata K., Amano K. and Nakamura H. (2011). Expression of MMP-8 and MMP-13 in the development of periradicular lesions. *Int. Endod. J.* 44, 739-745.
- Meng M., Chen Y., Chen X., Zhang Q., Guo W., Zhou X. and Zou J. (2020). IL-1 α regulates osteogenesis and osteoclastic activity of dental follicle cells through JNK and p38 MAPK pathways. *Stem Cells Dev.* 24, 1552-1566.
- Nyman J.S., Lynch C.C., Perrien D.S., Thiollou S., O'Quinn E.C., Patil C.A., Bi X., Pharr G.M., Mahadevan-Jansen A. and Mundy G.R. (2011). Differential effects between the loss of MMP-2 and MMP-9 on structural and tissue-level properties of bone. *J. Bone Miner. Res.* 26, 1252-1260.
- Ou M. and Huang X. (2021). Influence of bone formation by composite scaffolds with different proportions of hydroxyapatite and collagen. *Dent. Mater.* 37, 231-244.
- Oury J. and Oury F. (2018). Osteocalcin, a key molecule for bone endocrine functions. *Med. Sci. (Paris)* 34, 54-62.
- Paula-Silva F.W.G., Arnez M.F.M., de Campos Chaves Lamarque G., Petille R., Ribeiro-Santos F.R., de Sena M.F., Nelson-Filho P. and da Silva L.A.B. (2021). Osteoclast formation, inflammation, and matrix metalloproteinase-9 are downregulated in bone repair following root canal treatment in dogs teeth. *Clin. Oral Invest.* 25, 4699-4707.
- Pereira R.D.S., Bonardi J.P., Ouverney F.R.F., Campos A.B., Griza G.L., Okamoto R. and Hochuli-Vieira E. (2020). The new bone formation in human maxillary sinuses using two bone substitutes with different resorption types associated or not with autogenous bone graft: a comparative histomorphometric, immunohistochemical and randomized clinical study. *J. Appl. Oral Sci.* 29.
- Pilmane M., Sidhoma E., Akota I. and Kazoka D. (2019). Characterization of cytokines and proliferation marker Ki67 in cleft affected lip tissue. *Medicina (Kaunas)*. 55, 518.
- Pilmane M., Šūmahers G.H. (2006). *Medicīniskā embrioloģija*. Rīgas Stradiņa universitāte, Rīga. 164-172. lpp. (in Latvian).
- Poundarik A.A., Boskey A., Gundberg C. and Vashishth D. (2018). Biomolecular regulation, composition and nanoarchitecture of bone mineral. *Sci. Rep.* 8, 1191.
- Prahasanti C., Nugraha A.P., Saskianti T., Suardita K., Riawan W. and ernawati d.s. (2020). exfoliated human deciduous tooth stem cells incorporating carbonate apatite scaffold enhance BMP-2, BMP-7 and attenuate MMP-8 expression during initial alveolar bone remodeling in wistar rats (*Rattus norvegicus*). *Clin. Cosmet. Investig. Dent.* 12, 79-85.
- Qin H. and Cai J. (2018). Effect of Runx2 silencing on autophagy and RANKL expression in osteoblasts. *Arch. Oral Biol.* 95, 74-78.
- Ren L., Zhang Z., Deng C., Zhang N. and Li D. (2021) Antibacterial and pro-osteogenic effects of β -Defensin-2-loaded mesoporous bioglass. *Dent. Mater J.* 40, 464-471.
- Robbiani D.F., Colon K., Ely S., Chesi M. and Bergsagel P.L. (2007). Osteopontin dysregulation and lytic bone lesions in multiple myeloma. *Hematol. Oncol.* 25, 16-20.
- Schett G., Dayer J.M. and Manger B. (2016). Interleukin-1 function and role in rheumatic disease. *Nat. Rev. Rheumatol.* 12, 14-24.
- Suzuki A., Sangani D.R., Ansari A. and Iwata J. (2016). Molecular mechanisms of midfacial developmental defects. *Dev. Dyn.* 245, 276-293.
- Thiel Y., Ghayor C., Lindhorst D., Essig H., Weber F., Rücker M. and Schumann P. (2020). Antimicrobial peptide gene expression in medication-related osteonecrosis of the jaw. *Pathol. Res. Pract.* 6, 153245.
- Van Doren S.R. (2015). Matrix metalloproteinase interactions with collagen and elastin. *Matrix Biol.* 44-46, 224-231.
- Varoga, D., Tohidnezhad M., Paulsen F., Wruck C.J., Brandenburg L., Mentlein R., Lippross S., Hassenpflug J., Besch L., Müller M., Jürgens C., Seekamp A., Schmitt L. and Pufe T. (2008). The role of human beta-defensin-2 in bone. *J. Anat.* 213, 749-757.
- Yang N.Y., Zhou Y., Zhao H.Y., Liu X.Y., Sun Z. and Shang J.J. (2018). Increased interleukin 1 α and interleukin 1 β expression is involved in the progression of periapical lesions in primary teeth. *BMC Oral Health* 18, 124.
- Yi L., Li. Z., Jiang H., Cao Z., Liu J. and Zhang X. (2018). Gene modification of transforming growth factor β (TGF- β) and interleukin 10 (IL-10) in suppressing Mt sonicate induced osteoclast formation and bone absorption. *Med. Sci. Monit.* 24, 5200-5207.
- Yoon S.O., Park S.J., Yun C.H. and Chung A.S. (2003). Roles of matrix metalloproteinases in tumor metastasis and angiogenesis. *J. Biochem. Mol. Biol.* 36, 128-137.
- Yuan L., You H., Qin N. and Zuo W. (2021). Interleukin-10 modulates the metabolism and osteogenesis of human dental pulp stem cells. *Cell Reprogram.* 23, 270-276.
- Zhang X., Liu Y., Wang X., Sun X., Zhang C. and Zheng S. (2017). Analysis of novel RUNX2 mutations in Chinese patients with cleidocranial dysplasia. *PLoS One* 12, 1-6.
- Zhu M., Miao B., Zhu J., Wang H. and Zhou Z. (2017). Expression and antimicrobial character of cells transfected with human β defensin 3 against periodontitis associated microbiota *in vitro*. *Mol. Med. Rep.* 16, 2455-2460.
- Zoch M.L., Clemens T.L. and Riddle R.C. (2016). New insights into the biology of osteocalcin. *Bone* 82, 42-49.