

Optimisation and validation of immunohistochemistry protocols for cancer research

Peter Ella-tongwiis^{1,2,3}, Alexander Makanga^{2,4}, Iqbal Shergill^{1,2,3,5} and Stephen Fôn Hughes^{1,2,3}

¹North Wales and North West Urological Research Centre, ²North Wales Clinical Research Centre, Betsi Cadwaladr University Health Board (BCUHB) Wrexham Maelor Hospital, ³Faculty of Social and Life Sciences, Wrexham Glyndwr University, Wrexham, ⁴Department of Histopathology, BCUHB Glan Clwyd Hospital, Denbighshire and ⁵The Alan de Bolla Department of Urology, BCUHB Wrexham Maelor Hospital, Wrexham, Wales, UK

Summary. Background. Immunohistochemistry (IHC) has become a valuable laboratory technique for diagnosing, evaluating metastasis and informing treatment selection in several cancers. Standardization however remains a limiting factor in IHC. The main aim of this research study was to optimise, validate and standardize antibodies and IHC protocols for cancer research.

Methods. Seven monoclonal mouse and rabbit antibodies were optimised using formalin-fixed paraffin embedded (FFPE) human tissue blocks. 4µm sections of FFPE block were stained using the Roche Ventana XT or Ventana ULTRA IHC automated analysers. This study modified manufacturer recommended protocols by using a unique antigen retrieval method, adding an amplification step, varying primary antibody incubation times, as well as using the Roche Ventana Ultraview detection system.

Results. Optimum antibody localisation was observed in modified IHC protocols in comparison with manufacturer recommended protocols for anti-CEACAM-1, anti-CD31, anti-COX-2, anti-HER-2/neu, anti-S100P, anti-thrombomodulin and anti-VEGFR-3. Majority of antibodies required more than one modification of the initial protocol. For anti-VEGFR-3 optimum staining was observed following 4 protocol modifications.

Conclusions. This study has optimised and standardized several tissue-based biomarkers that may be, in the future, used to screen, diagnose and monitor patients with certain cancer, such as bladder cancer. Accurate data on optimised protocols reduce time and

resources wasted on experimental protocols, and ultimately help identify biomarkers or biomarker panels, which may be used to select treatment regimens for various cancers.

Key words: Immunohistochemistry (IHC), Pathology, Angiogenesis, Cancer, Antibodies

Introduction

Immunohistochemistry (IHC) has become an important tool for differential diagnosis in cancer and also aids subsequent treatment selection. In breast cancer for example, IHC evaluation of oestrogen receptor, progesterone receptor and human epidermal growth factor receptor-2 (HER-2), provides valuable information in deciding treatment options (Dede et al., 2013; Xu et al., 2018). In bladder cancer, IHC is a potential tool for sub-classifying T1 tumours (Mhawech et al., 2002) and can also be used to highlight histological characteristics in various disorders of the bladder (Rajcani et al., 2013).

Research into biomarkers such as CEACAM-1, CD31, COX-2, HER-2, S100P, thrombomodulin and VEGFR-3 has produced varying results. Although CEACAM-1 is physiologically expressed in endothelial cells, epithelial cells and myeloid cells of several human organ systems (Kilic et al., 2005), it has also been associated with increased vascularisation of the chorioallantoic membrane. Furthermore, increased VEGF, a known pro-angiogenic factor, induces CEACAM-1, highlighting its link with tumour angiogenesis (Ergün et al., 2000). CD31, another marker of angiogenesis, is mainly localised on the surfaces of neutrophils, monocytes, platelets and endothelial cells (Stockinger et al., 1990; Righi et al., 2003). It may be secreted, membrane bound or localised intracellularly

Corresponding Author: Stephen Fôn Hughes, North Wales and North West Urological Research Centre, Betsi Cadwaladr University Health Board (BCUHB) Wrexham Maelor Hospital, Wrexham, Wales, UK. e-mail: Stephen.hughes6@wales.nhs.uk
DOI: 10.14670/HH-18-317



but it is most importantly utilised as a marker of angiogenesis by evaluating its immunoreactivity on blood vessel endothelium (Deliu et al., 2016; Qian et al., 2018).

Cyclooxygenase-2 (COX-2) is highly expressed in high stage and high grade colonic adenocarcinoma (Hedaya et al., 2015) and can therefore be used as a marker for diagnosis or exploited in the development of treatment therapies. Thrombomodulin, a membrane receptor expressed on endothelial cells, has important roles in physiological coagulation (Esmon et al., 1982), inflammation and cancer promotion and proliferation (Wu et al., 2014; Greineder et al., 2017). The S100 proteins are associated with roles in cellular processes like regulation of cell cycle, growth, transcription and differentiation (Jiang et al., 2016). These proteins may be localised in different cellular compartments and are activated through calcium activation. The association between S100P and cellular processes such as cell survival, proliferation, tumour invasion and angiogenesis have been studied by various researchers (Guo et al., 2014; Liu et al., 2017; Tabrizi et al., 2018).

In order to precisely determine cancer diagnosis, progression or prognosis, clinicians rely on suitably researched biomarkers (O'Hurley et al., 2014). However, inter-laboratory variations due to sample collection and processing, antibody selection, detection systems and stain interpretation has led to difficulties in standardising IHC results across various pathology laboratories (Kirkegaard et al., 2006).

The main aim of this research study was to optimise, validate and standardize antibodies (anti-CEACAM-1, anti-CD31, anti_COX-2, anti-HER-2/neu, anti-S100P, anti-thrombomodulin and anti-VEGFR-3) and IHC protocols for evaluating cancers in the Histopathology Department. The data presented in this research study will provide valuable information for both researchers and practicing professionals, which may ultimately lead to the development of specific IHC platforms being created and utilised for clinical screening, diagnosis, and aiding treatment for several cancers.

Materials and methods

Ethical consideration and sample preparation

Permission for this research study was sought from

the Research Ethics Service (Reference: 14/WA/0033). Anonymised control FFPE tissue were kindly provided by the Histopathology Department of Betsi Cadwaladr University Health Board (BCUHB), Ysbyty Glan Clwyd Hospital, North Wales (UK). All tissue samples were stained using either the Roche Ventana BenchMark ULTRA (Automated IHC/ISH slide staining system) or the Roche Ventana BenchMark XT (Automated IHC/ISH slide staining system). The NHS pathology department where this research was conducted is working towards ISO15189 accreditation and participates in UKNeqas testing schemes.

Antibodies

Monoclonal mouse anti-human CEACAM-1/CD66a, CD-31, S100P, thrombomodulin, VEGFR-3 and monoclonal rabbit anti-human COX-2, and HER-2/neu were investigated in this study. Antibodies were stored and treated according to manufacturer's instructions. Table 1 summarises important information for each antibody optimised in this study. Other reagents used in this research include Ultraview universal DAB detection kit (Ventana medical systems; product number 760-500), amplification kit (Ventana medical systems; product no. 760-080), hematoxylin II (Ventana medical systems; product no 790-2208), Cell conditioning I (Ventana medical systems; product no 950-124), Cell conditioning II (Ventana medical systems; product no 950-123), EZ prep solution (Ventana medical systems; Product no. 950-102) and liquid coverslip (Ventana medical systems; product no 250-009).

Control tissues

FFPE Human Colon adenocarcinoma, Placenta, Breast Carcinoma, Fallopian Tube, Umbilical Cord, and Transitional Cell Carcinoma (TCC) Bladder were used for validating the various antibodies. These tissues were specifically selected because previous research has shown that CEACAM-1 is expressed in colon (Han et al., 2018), CD31 is expressed in human placenta (Shchegolev et al., 2016), COX-2 is expressed human colon (Wu and Sun, 2015), HER-2/neu is expressed in breast cancer (Gulzar et al., 2018), S100P is expressed in human placenta (Zhu et al., 2015), Thrombomodulin is expressed in human bladder (Chuang et al., 2007) and

Table 1. Details of antibody clones, suppliers and Immunohistochemical staining localisations.

Antibody (clone)	Supplier	Control tissue	Localisation
CEACAM-1/CD66a (283324)	R&D medical systems Europe Ltd	Colon	Cytoplasmic, membranous
CD31 (JC70)	Cell Marque (Sigma Aldrich, UK)	Placenta	Cytoplasmic, membranous
COX-2 (SP21)	Cell Marque (Sigma Aldrich, UK)	Colon	Cytoplasmic, membranous
HER-2/neu (4B5)	Roch diagnostics	Breast	membranous
S100P (16/f5)	Cell Marque (Sigma Aldrich, UK)	Placenta	Cytoplasmic, nuclear
Thrombomodulin (1009)	Cell Marque (Sigma Aldrich, UK)	Bladder	Cytoplasmic, membranous
VEGFR-3/Flt-4) (54703)	R&D medical systems Europe Ltd	Umbilical cord	Nuclear

VEGFR-3 is expressed in human umbilical cord (Olaya et al., 2019).

Immunohistochemistry protocols

A modified indirect IHC used in a UKAS Accredited NHS Pathology Department was used to stain all tissue sections (Fig. 1). Tissue slides were dewaxed by using 1X EZ prep solution (supplied by Ventana Medical Systems, UK), heat and vortex mixing. Heated paraffin wax floated out from tissue sections through the aqueous solution and was efficiently removed by vortex mixing. In the presence of heat, Cell Conditioning 1 (CC1-supplied by Ventana Medical Systems, UK) was used for antigen retrieval (heat induced epitope retrieval). The basic pH and tris-based buffer in CC1 enhances antibody binding in tissues, by hydrolysing covalent bonds at high temperature. Evaporation was minimized by using liquid cover slip (LCS) (Ventana Medical Systems, UK). This prevents tissue sections from drying up during the IHC. Liquid coverslip was applied between segments of IHC procedure.

Endogenous proteins and peroxides were blocked using Ventana diluent/option 1 for 4 minutes. Primary antibodies, which were mouse or rabbit monoclonal IgG antibodies, were applied to tissues sections and incubated at various durations (see optimised protocols). HRP-labelled secondary antibodies (goat anti-mouse IgG, goat anti-mouse IgM, and goat anti-rabbit IgG) were then added to the slides.

The detection kit used in this research; the Ventana

Ultraview DAB universal detection kit (Ventana Medical Systems, UK) is an indirect biotin-free kit capable of identifying mouse and rabbit IgG and IgM antibodies in PPFE tissue sections. Following exposure to primary antibody and HRP-labelled secondary antibody, 3, 3'-diaminobenzidine (DAB) was used for colour development. DAB is catalysed to form a brown precipitate (oxidised form of DAB) in the presence of hydrogen peroxide. This is then visualised using light microscopy (Fig. 2).

Ventana haematoxylin 1 was used as counterstain and stains nuclei blue by reacting with a dye complex in the presence of nucleic acids and histone proteins. Tissue sections were dehydrated and mounted in DPX. For each IHC stain, both positive and negative control tissues were present on the slides. Additionally, negative control slides were added to each staining cycle by omitting the primary antibody.

Results

Optimisation of anti-CEACAM-1 primary monoclonal antibody reactivity in tissues using IHC

CEACAM-1 exhibits membranous or cytoplasmic localisation in colonic epithelial cells. Three experimental protocols were analysed for optimum anti-CEACAM-1 staining in human colon adenocarcinoma tissue. Protocol 2 [summarised in Table 2] produced clear moderate staining intensity and had a shorter duration, less background staining and required an

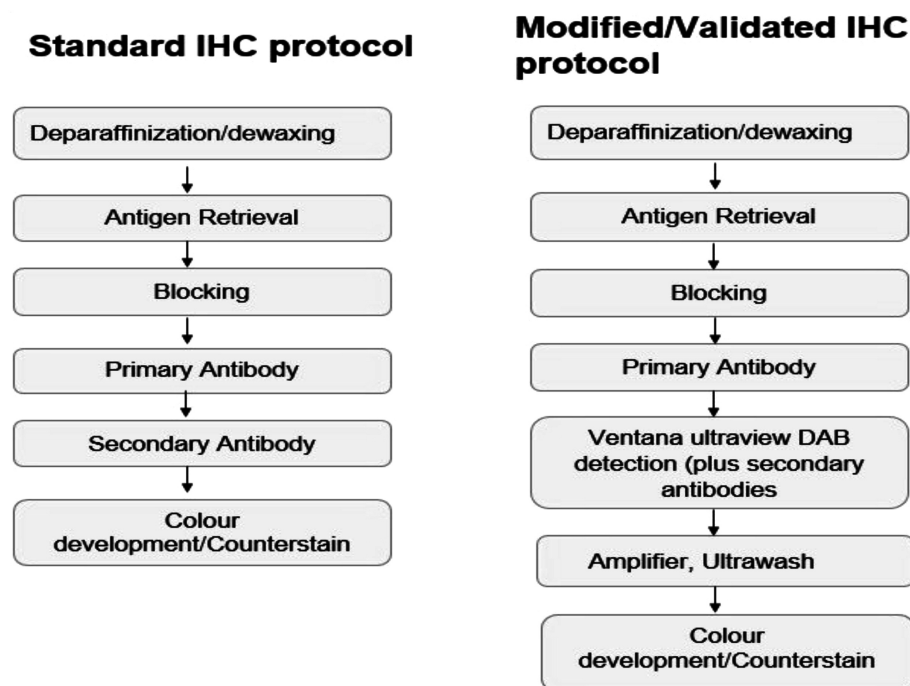


Fig. 1. Standard IHC protocol versus the modified protocol used in this research (standard IHC protocol adapted from Taylor et al., 2013).

amplification step (Fig. 3A-C).

Optimisation of anti-CD31 primary monoclonal antibody reactivity in tissues using IHC

CD31 exhibits membranous and cytoplasmic localisation in vascular endothelial cells in human placenta. Two modification of the recommended protocol were analysed for optimum anti-CD31 staining (Fig. 4A,B).

Optimisation of COX-2 antibody immunoreactivity in tissues using IHC

Three variations of the protocol were used in

optimising anti-COX-2 antibody. Optimum staining was achieved with protocol 2, which showed strong intensity staining with little background noise. Protocol 2 had 32 minutes primary antibody incubation and did not require amplification (Fig. 5A-C).

Optimisation of Anti HER-2/neu (4B5) monoclonal antibody

Figure 6A-C illustrate optimisation of Anti-HER-2/neu. The optimum protocol produced strong intensity membranous staining with a primary antibody incubation of 32 minutes, and an amplification step. IHC optimisation protocols for anti-S100P monoclonal antibody.

Table 2. Summary of optimised protocols for IHC. These protocols are modifications of manufacturer recommendation and produced optimum antibody staining in FFPE human control tissues. The modified IHC protocol used in this research has a unique and novel antigen retrieval method on the Roche Ventana XT and Ventana ultra IHC system(s). For all protocols, haematoxylin counter stain was applied for 12 minutes, blueing reagent was applied for 4 minutes and the ventana Ultraview DAB detection system was used.

	Optimised S100P protocol	Optimised COX-2 protocol	Optimised HER-2 protocol	Optimised VEGFR-3 protocol	Optimised CEACAM-1 protocol	Optimised CD31 protocol	Optimised Thrombomodulin protocol
Control tissue	Placenta	Colon adenocarcinoma	Breast carcinoma	Umbilical cord	Colon	Placenta	Bladder
Deparaffinization	72°C for 4 minutes	72°C for 4 minutes	72°C for 4 minutes	72°C for 4 minutes	72°C for 4 minutes	72°C for 4 minutes	72°C for 4 minutes
Antigen retrieval	Protease 1 for 8 minutes	CC1 95-100°C for 64 minutes	CC1 95-100°C for 64 minutes	CC1 at 100°C for 52 minutes	CC1 at 100°C for 36 minutes	CC1 at 100°C for 64 minutes	CC1 for 8 minutes
Blocking	Not required	Required	Ultra block with Ventana diluent	Ventana diluent	Ventana diluent	Not required	Ventana diluent
Primary antibody incubation at 37°C	24 minutes	32 minutes	20 minutes	16 Minutes (1:200 dilution)	8 Minutes (1:100 dilution)	32 Minutes	32 minutes
Amplification step	Amplifier required	Amplifier not required	Amplifier required	Ultrawash	Amplifier required	Amplifier required	Amplifier and Ultrawash required

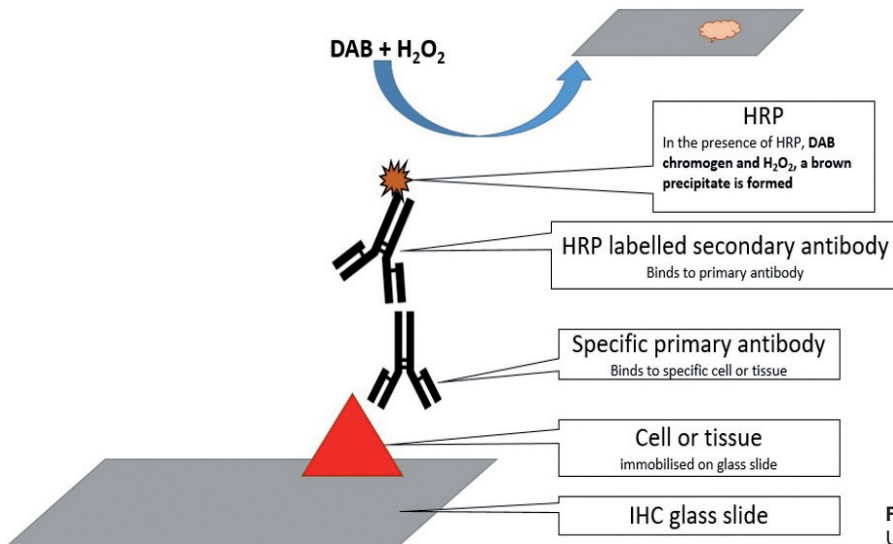


Fig. 2. Graphical representation of the Ventana Ultraview detection kit.

Strong intensity anti-S100P staining was observed in human placenta tissues increasing primary antibody incubation time and adding an amplification step to the protocol using ventana amplifier (Fig. 7A,B).

Optimisation of anti-thrombomodulin primary monoclonal antibody

Anti-thrombomodulin staining in human bladder required two modification of the initial protocol. The optimised protocol had a blocking step, primary antibody incubation time of 32 minutes, an amplification step and an ultrawash step. These resulted in strong intense membranous staining in epithelial cells within human bladder (Fig. 8A-C).

Optimisation of anti-VEGFR-3 primary monoclonal antibody

Moderate IHC staining was achieved in protocol 4. Three other experimental protocols produced non-specific staining with high background noise in human umbilical cord sample (Fig. 9A-D).

Discussion

The main aim of this study was to optimise IHC protocols and antibodies (CEACAM-1, CD31, COX-2, HER-2, S100P, thrombomodulin and VEGFR-3) that may provide standardized information used for assessing IHC staining of various antibodies in cancer research.

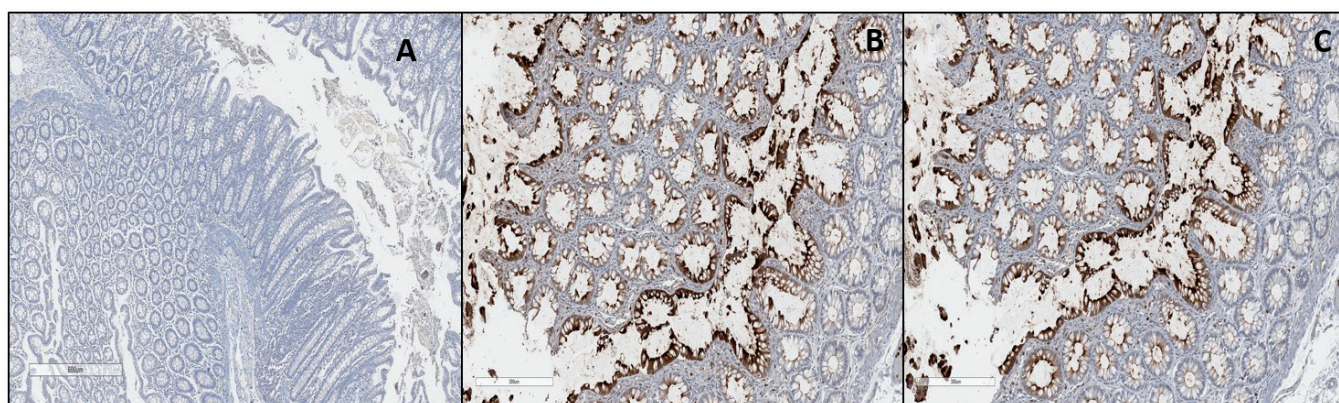


Fig. 3. Optimisation of anti-CEACAM-1 antibody. **A.** Negative control shows no membranous or cytoplasmic staining in human colon. **B.** Optimum membranous and cytoplasmic staining (moderate stain intensity) in colon epithelial cells (brown). Deparaffinization- 72°C, CC1 at 100°C for 36 minutes, blocking- Option 1, Ab at 37°C for 8 minutes (1:100 dilution), amplification step included. **C.** Manufacturer recommended protocol (moderate stain intensity) in colon epithelial cells (brown). Deparaffinization- 72°C, CC1 at 100°C for 36 minutes, blocking- Option 1, Ab at 37°C for 8 minutes (1:200 dilution), amplification step included. Note: All protocols used detection kit- Optiview, counterstain (12 minutes), blueing reagent (4 minutes). x 100.

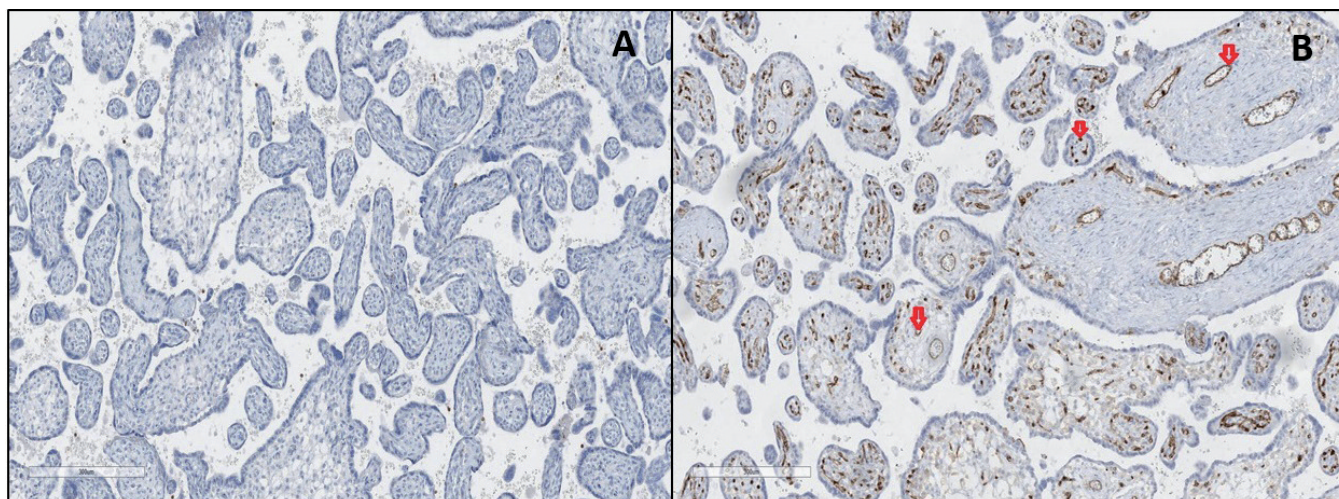


Fig. 4. Optimisation of anti-CD31 antibody. **A.** Negative control shows no staining in human placenta samples. **B.** Moderate intensity membranous and cytoplasmic staining in vascular endothelial cells (red arrows) in human placenta tissue. Deparaffinization- 72°C for 4 minutes, CC1 at 100°C for 64 minutes, blocking- Not required, Anti CEACAM-1 Ab at 37°C for 32 minutes, amplification- not required, counterstain (12 minutes), blueing reagent (4 minutes). x 100.

Internal quality control was enhanced by including both control and sample tissues on the same IHC microscope slide.

Optimisation of the S100P antibody required an increased primary antibody incubation time, a post-stain amplification step was included and duration of counterstaining was increased to 12 minutes. The positive nuclear and cytoplasmic staining and reduced background staining, in trophoblastic epithelial cells of the human placenta control tissue complements other studies (Maciejczyk et al., 2013). Our study, however, requires a shorter primary antibody incubation time (24 minutes), shorter antigen retrieval (8 minutes) and a shorter overall IHC process compared to the process reported by others (Surowiak et al., 2007; Maciejczyk et

al., 2013) and could be used as an alternative methodology for assessing anti-S100P immunoreactivity in BC tissues.

Anti-VEGFR-3 optimisation produced generally unspecific nuclei and cytoplasmic staining within normal endothelial cells, muscle tissue and other underlying stromal cells. Other researchers have observed non-specific staining in 4 clones of VEGFR-3 (Smith et al., 2010). With respect to the present study, the protocol was performed on umbilical cord samples in contrast with breast and colorectal cancers used by others (Smith et al., 2010), providing further application for staining of this biomarker in other tissue sample types.

Although previous studies have assessed COX-2 IHC staining in human endometrial carcinoma and

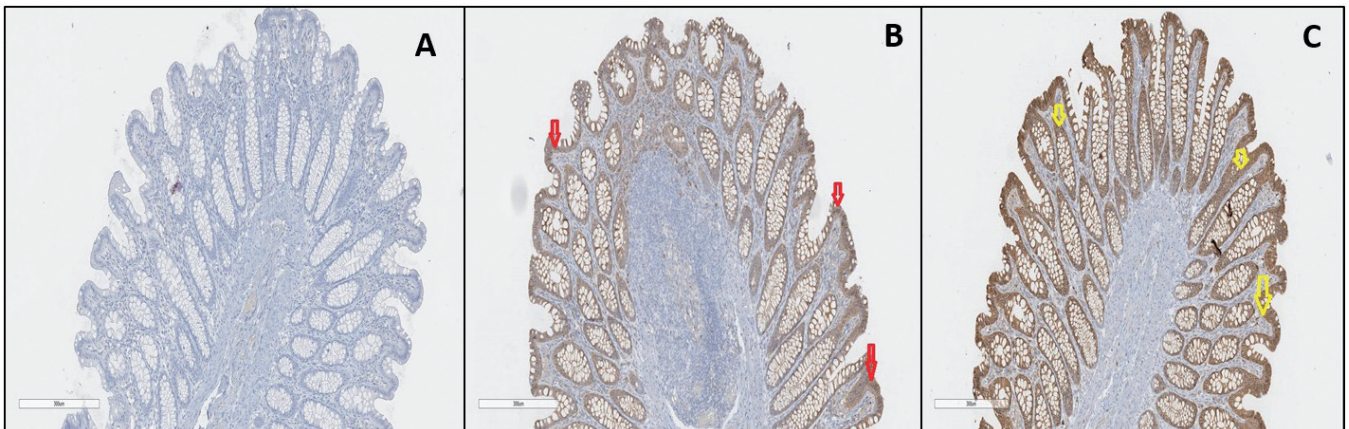


Fig. 5. Optimisation of Anti-COX-2 monoclonal antibody. **A.** Negative control using human Colon adenocarcinoma. **B.** (optimised protocol) Strong intensity cytoplasmic and membranous staining (red arrows) in colonic crypts. Deparaffinization - 72°C for 4 minutes, Antigen retrieval - CC1 95 -100°C for 64 minutes, Ab incubation at 37°C for 32 minutes, Amplification- not required. **C.** (manufacturer recommended) Strong intensity cytoplasmic and membranous staining in colonic crypts. Amplification step applied. Also note the deeper intensity and background staining. Note: All protocols used Detection kit- Ultraview. Counterstain for 12 minutes, blueing reagent (4 minutes). x 100.

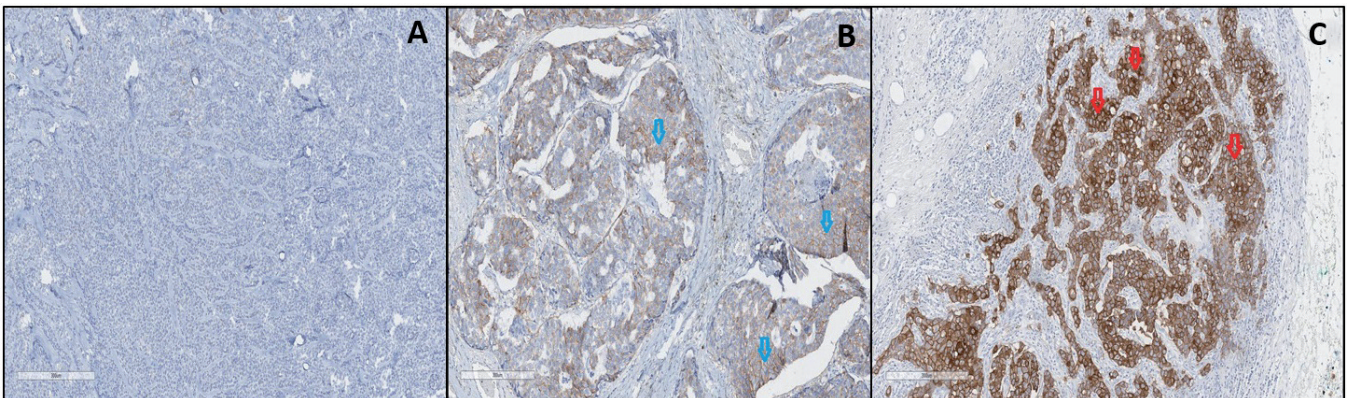


Fig. 6. Optimisation of Anti-HER-2/neu monoclonal antibody. **A.** Negative control shows no staining in human breast carcinoma tissue. **B.** (Manufacturer recommended) weak intensity membranous staining (blue arrows) in human breast carcinoma tissue using manufacturer settings. **C.** (Optimised protocol). Strong intensity membranous staining seen in human breast carcinoma tissue (red arrows). Deparaffinization - 72°C for 4 minutes, antigen retrieval - CC1 95-100°C for 36 minutes, ultra-block with ventana diluent, antibody incubation at 37°C for 20 minutes, amplification- Ventana amplifier, detection kit- Ultraview, Counterstain for 12 minutes, blueing reagent (4 minutes).

colorectal cancer tissues (Hedaya et al., 2015; Cai et al., 2017), optimisation results from this present study provides a new and novel method for performing IHC in human BC tissues. In contrast to others who used an EDTA buffer antigen retrieval method (Hedaya et al., 2015), the COX-2 antibody and IHC process used in this research study used a tris-based Heat Induced Epitope Retrieval (HIER) method for optimum staining. We provide further details of the staining process, sample micrographs of staining intensity, control and staining duration for optimum staining. This new approach and method for staining tissue COX-2, will help standardize future research protocols for those operators using the Roche Ventana XT IHC autostainer or the Roche

Ventana ultra IHC autostainer platforms.

With regards to CEACAM-1, although the experimental protocols produced few overall variations, the optimum staining in human colon tissues was observed in experimental protocol 2. Previous research by Thöm et al. (2009), reported a longer IHC protocol (2 days) and used only negative controls in contrast with our present study, which has a shorter protocol (3 hours). The CEACAM-1 IHC method developed in the present study, significantly reduces the protocol assay duration (2 days vs 3 hours) compared to the original method as described by Thöm et al. (2009), and furthermore provides more detailed information about the staining patterns in control tissues.

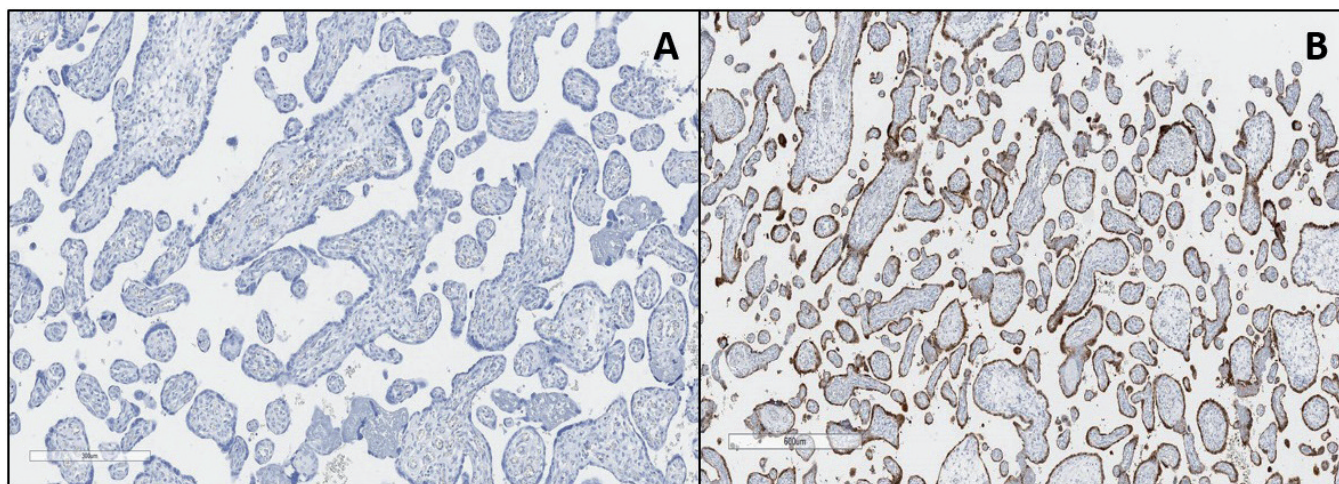


Fig. 7. Optimisation of anti-S100P monoclonal antibody. **A.** Negative control shows no staining in human placenta. **B.** (Optimised protocol). Strong intensity staining reported in human placenta. Deparaffinization – 72°C for 4 minutes, Antigen retrieval - Protease 1 for 8 minutes, antibody incubation at 37°C for 24 minutes, Amplification step included, Detection kit- Ultraview, Counterstain for 12 minutes, blueing reagent (4 minutes).

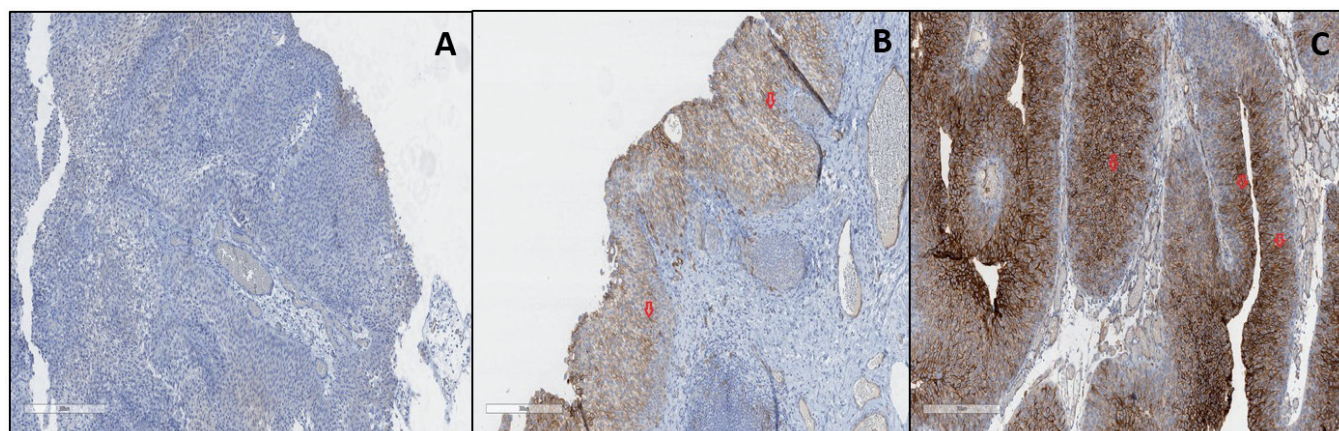


Fig. 8. Optimisation of Anti-Thrombomodulin antibody. **A.** Negative control shows no cytoplasmic or membranous staining in human bladder tissues. **B.** (Manufacturer recommended) Moderate intensity membranous and cytoplasmic staining in bladder tissue (red arrows). Antibody incubation= 16 Minutes, no amplification, Ultrawash added, Ventana ultraview DAB detection. **C.** (Optimised protocol) Strong intensity membranous and cytoplasmic staining seen in epithelial cells in human bladder tissue (red arrows). Deparaffinization- 72°C for 4 minutes, antigen retrieval - CC1 for 8 minutes, blocking- Ventana option 1, antibody incubation at 37°C for 32 minutes, amplification- Ventana amplifier, Ultrawash step included. Note: All protocols used detection kit- Ultraview, counterstain for 12 minutes, blueing reagent (4 minutes). x 100.

Using breast adenocarcinoma tissue samples, the optimised protocol for HER-2/neu had an antigen retrieval time of 36 minutes, primary antibody incubation time was 20 minutes, and an amplification step was also included. HER-2 IHC is currently used for clinical management of invasive breast cancer, and has therefore been studied by other research groups (Shirsat et al., 2012; Ji et al., 2014). However, the present study provides new information with regards to staining Bladder Cancer (BC) tissues using the Roche Ventana XT IHC autostainer and the Roche Ventana ultra IHC autostainer platforms.

With the inclusion of an amplification step and an increased incubation time, optimum CD31 staining was observed within vascular endothelial cells in placenta tissues. The modified protocol for assessing CD31 used in this research, therefore, may provide an alternative method for future researchers and will aid standardization of IHC protocols within pathology (clinical and research) laboratories.

Non-specific binding of anti-thrombomodulin was prevented by adding a blocking step, increasing primary

antibody incubation time and adding an amplification step. These modifications produced enhanced membranous and cytoplasmic staining within Bladder epithelial cells as also reported by others (Song et al., 2018). In contrast to this present study however, the study by Song et al. (2018) does not provide any information on control tissues, stain protocol and protocol duration.

The optimised anti-VEGFR-3 antibody protocol produced nuclear staining patterns in fallopian tube tissues and complements results from a study by Capatina et al. (2019) who also reported similar staining patterns. In comparison with Capatina et al., (2019) however, the protocol developed in this current study had a shorter overall duration and is more suitable for BC research. Furthermore, this current research provides new information with regards staining BC tissues using the Roche Ventana XT IHC autostainer and the Roche Ventana ultra IHC autostainer platforms.

Variation in IHC may be caused by several factors and is one main source of controversy limiting standardisation across laboratories, research groups and

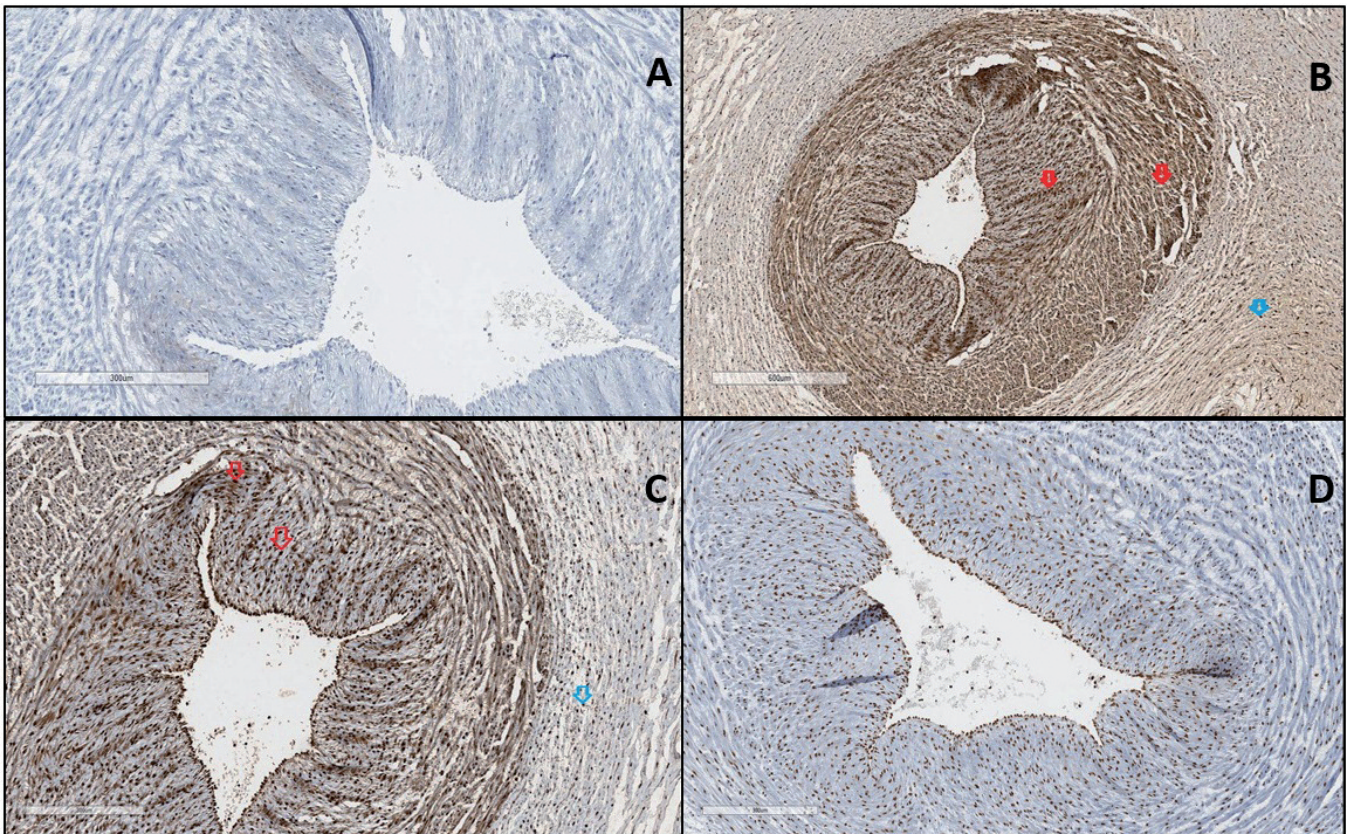


Fig. 9. Optimisation of anti-VEGFR-3 antibody. **A.** Negative control shows no staining. **B.** (Manufacturer recommended) Strong intensity nuclear staining. Positive nuclear staining in endothelial cells (red arrows). Note the strong nonspecific staining (blue arrows) within underlying stroma and muscle cell. **C.** Strong intensity nuclear staining. Positive nuclear staining in endothelial cells (red arrows). Note the reduced background staining compared to 3E. **D.** (Optimised protocol). Moderate intensity nuclear staining in endothelial cells (brown). Note the significantly reduced nonspecific staining within underlying stroma and muscle cell. Deparaffinization- 72°C, CC1 at 100°C for 52 minutes, Blocking- Ventana diluent, antibody incubation at 37°C for 16 minutes (1:200 dilution), Ultrawash, detection kit- Ultraview, counterstain (12 minutes), blueing reagent (4 minutes). x 100.

regulatory bodies. Although storage duration of FFPE tissues has been highlighted as a potential source of variation, (Shi et al., 2007) have recommended the need to optimise antigen retrieval techniques prior to staining sample tissues.

In this study, validation of IHC protocols was performed by using manufacturer recommended protocols as a foundation for cancer research. Several FFPE tissue sections from control tissues (Table 1) were stained using manufacturer recommended protocols. Following initial assessment by experienced pathologists/histopathologists, modification of the initial protocols were performed until optimised staining was achieved.

We acknowledge a limiting factor of this study was that only one clone per antibody was optimised and validated. There is therefore scope to perform further studies using other antibody clones and the present study provides a sound foundation to undertake such investigations.

A possible future direction for the present study is that the data obtained from this study, if standardized across laboratories, may be used as template in bladder cancer research. In future, this data may also be used for large studies in other cancers using FFPE tissue blocks. In summary, this study provides a sound platform for continued work in this area which will no doubt help contribute new knowledge and IHC protocol development involving cancer research.

In conclusion, the present study has optimised biomarker tissue staining methods that may be, in the future, used to validate and standardize IHC protocols for routine use or cancer research. Accurate data on optimised protocols reduce time and resources wasted on experimental protocols and ultimately help identify biomarkers or biomarker panels which may be used to select treatment regimens for various cancers.

Acknowledgements. The authors wish to thank all the staff at the Department of Histology at Betsi Cadwaladr University Health Board (BCUHB), Ysbyty Glan Clwyd, North Wales, UK, for their support regards our continued research activities.

Disclosure statement. No potential conflict of interest was reported by the authors.

Funding. The authors thankfully acknowledge BCUHB Department of Research & Innovation for their financial support.

References

- Cai S., Zhang Y., Han K. and Ding Y. (2017). Expressions and clinical significance of COX-2, VEGF-C, and EGFR in endometrial carcinoma. *Arch. Gynecol. Obstet.* 296, 93-98.
- Capatina C., Cimpean A.M., Raica M., Coculescu M. and Poiana C. (2019). SOX 2 expression in human pituitary adenomas-correlations with pituitary function. *In Vivo* 33, 79-83.
- Chuang A.Y., DeMarzo A.M., Veltri R.W., Sharma R.B., Bieberich C.J. and Epstein J.I. (2007). Immunohistochemical differentiation of high-grade prostate carcinoma from urothelial carcinoma. *Am. J. Sur. Pathol.* 31, 1246-1255.
- Dede D.S., Gumuskaya B., Guler G., Onat D., Altundag K. and Ozisik Y. (2013). Evaluation of changes in biologic markers ER, PR, HER 2 and Ki-67 index in breast cancer with administration of neoadjuvant dose dense doxorubicin, cyclophosphamide followed by paclitaxel chemotherapy. *JBUON* 18, 366-371.
- Deliu I.C., Neagoe C.D., Bezna M., Genunche-Dumitrescu A.V., Toma S.C., Ungureanu B.S., Uscatu C.D., Bezna M.C., Lungulescu C.V., Padureanu V. and Gheonea D.I. (2016). Correlations between endothelial cell markers CD31, CD34 and CD105 in colorectal carcinoma. *Rom. J. Morphol. Embryol.* 57, 1025-1030.
- Ergün S., Kilic N., Ziegeler G., Hansen A., Nollau P., Götze J., Wurmbach J.H., Horst A., Weil J., Fernando M. and Wagener C. (2000). CEA-related cell adhesion molecule 1: a potent angiogenic factor and a major effector of vascular endothelial growth factor. *Mol. Cell* 5, 311-320.
- Esmon N.L., Owen W. and Esmon C. (1982). Isolation of a membrane-bound cofactor for thrombin-catalyzed activation of protein C. *J. Biol.* 257, 859-864.
- Greineder C.F., Johnston I.H., Villa C.H., Gollomp K., Esmon C.T., Cines D.B., Poncz M. and Muzykantov V.R. (2017). ICAM-1-targeted thrombomodulin mitigates tissue factor-driven inflammatory thrombosis in a human endothelialized microfluidic model. *Blood Adv.* 1, 1452-1465.
- Gulzar R., Shahid R. and Saleem O. (2018). Molecular subtypes of breast cancer by immunohistochemical profiling. *Int. J. Pathol.* 16, 129-134.
- Guo L., Chen S., Jiang H., Huang J., Jin W. and Yao S. (2014). The expression of S100P increases and promotes cellular proliferation by increasing nuclear translocation of beta-catenin in endometrial cancer. *Int. J. Clin. Exp. Pathol.* 7, 2102-2112.
- Han Z.M., Huang H.M. and Sun Y.W. (2018). Effect of CEACAM-1 knockdown in human colorectal cancer cells. *Oncol. Lett.* 16, 1622-1626.
- Hedaya M., Helmy A., Ezzat H. and Hammam O. (2015). Cyclooxygenase-2 and vascular endothelial growth factor expression in colorectal cancer patients. *Egypt J. Sur.* 34 35-40.
- Ji Y., Sheng L., Du X., Qiu G., Chen B. and Wang X. (2014). Clinicopathological variables predicting HER-2 gene status in immunohistochemistry-equivocal (2+) invasive breast cancer. *J. Thorac. Dis.* 6, 896-904.
- Jiang H., Hu H., Lin F., Lim Y.P., Hua Y., Tong X. and Zhang S. (2016). S100P is overexpressed in squamous cell and adenocarcinoma subtypes of endometrial cancer and promotes cancer cell proliferation and invasion. *Can. Invest.* 34, 477-488.
- Kilic N., Oliveira-Ferrer L., Wurmbach J.H., Loges S., Chalajour F., Vahid S.N., Weil J., Fernando M. and Ergun S. (2005). Pro-angiogenic signaling by the endothelial presence of CEACAM1. *J. Biol.* 280, 2361-2369.
- Kirkegaard T., Edwards J., Tovey S., McGlynn L.M., Krishna S.N., Mukherjee R., Tam L., Munro A.F., Dunne B. and Bartlett J.M. (2006). Observer variation in immunohistochemical analysis of protein expression, time for a change?. *Histopathology* 48, 787-794.
- Liu Y., Wang C., Shan X., Wu J., Liu H., Liu H., Zhang J., Xu W., Sha Z., He J. and Fan J. (2017). S100P is associated with proliferation and migration in nasopharyngeal carcinoma. *Oncol. Lett.* 14, 525-532.
- Maciejczyk A., Lacko A., Ekiert M., Jagoda E., Wysocka T., Matkowski R., Halon A., Györfy B., Lage H. and Surowiak P. (2013). Elevated

- nuclear S100P expression is associated with poor survival in early breast cancer patients. *Histol. Histopathol.* 28, 513-524.
- Mhawech P, Iselin C and Pelte MF. (2002). Value of immunohistochemistry in staging T1 urothelial bladder carcinoma. *Eur. Urol.* 42, 459-463.
- O'Hurley G., Sjöstedt E., Rahman A., Li B., Kampf C., Pontén F., Gallagher W.M. and Lindskog C. (2014). Garbage in, garbage out: a critical evaluation of strategies used for validation of immunohistochemical biomarkers. *Mol. Oncol.* 8, 783-798.
- Olaya C.M., Michael F., Fabian G., Silva J.L., Bernal J. and Garzon A. (2019). Role of VEGF in the differential growth between the fetal and placental ends of the umbilical cord. *J. Neonatal. Perinatal Med.* 12, 47-56.
- Qian H., Yang L., Zhao W., Chen H. and He S. (2018). A comparison of CD105 and CD31 expression in tumor vessels of hepatocellular carcinoma by tissue microarray and flow cytometry. *Exp. Ther. Med.* 16, 2881-2888.
- Rajcani J., Kajo K., Adamkov M., Moravekova E., Lauko L., Felcanova D. and Bencat M. (2013). Immunohistochemical characterization of urothelial carcinoma. *Bratisl. Lek Listy* 114, 431-438.
- Righi L., Deaglio S., Pecchioni C., Gregorini A., Horenstein A.L., Bussolati G., Sapino A. and Malavasi F. (2003). Role of CD31/platelet endothelial cell adhesion molecule-1 expression in in vitro and in vivo growth and differentiation of human breast cancer cells. *Am. J. Pathol.* 162, 1163-1174.
- Shchegolev A., Lyapin V., Tumanova U., Vodneva D. and Shmakov R. (2016). Histological changes in the placenta and vascularization of its villi in early- and late-onset preeclampsia. *Arkh. Pat.* 78, 13-18. (in Russian).
- Shi S.R., Cote R.J. and Taylor C.R. (2007). Standardization of immunohistochemistry for formalin-fixed, paraffin-embedded tissue sections based on the antigen-retrieval technique: from experiments to hypothesis. *J. Histochem. Cytochem.* 55, 105-109.
- Shirsat H.S., Epari S., Shet T., Bagal R., Hawaldar R. and Desai S.B. (2012). HER 2 status in invasive breast cancer: immunohistochemistry, fluorescence in-situ hybridization and chromogenic in-situ hybridization. *Indian J. Pathol. Microbiol.* 55, 175-179.
- Smith N.R., Baker D, James N.H., Ratcliffe K., Jenkins M., Ashton S.E., Sproat G., Swann R., Gray N., Ryan A. and Jürgensmeier J.M. (2010). Vascular endothelial growth factor receptors VEGFR-2 and VEGFR-3 are localized primarily to the vasculature in human primary solid cancers. *Clin. Can. Res.* 16, 3548-3561.
- Song J., Ma D., Liu X., Chen Y., Fang J., Lui V.W., Zhao S., Xia J., Cheng B. and Wang Z. (2018). Thrombomodulin (TM) in tumor cell differentiation and periphery blood immune microenvironment in oral squamous cell carcinoma. *Clin. Immunol.* 191, 27-33.
- Stockinger H.A., Gadd S.J., Eher R.E., Majdic O.T., Schreiber W., Kasinrerker W., Strass B., Schnabl E. and Knapp W. (1990). Molecular characterization and functional analysis of the leukocyte surface protein CD31. *J. Immunol.* 145, 3889-3897.
- Surowiak P., Maciejczyk A., Materna V., Drag-Zalesińska M., Wojnar A., Pudielko M., Kędzia W., Spaczyński M., Dietel M., Zabel M. and Lage H. (2007). Unfavourable prognostic significance of S100P expression in ovarian cancers. *Histopathology* 51, 125-127.
- Tabrizi M.E., Lancaster T.L., Ismail T.M., Georgiadou A., Ganguly A., Mistry J.J., Wang K., Rudland P.S., Ahmad S and Gross SR. (2018). S100P enhances the motility and invasion of human trophoblast cell lines. *Sci. Rep.* 8, 11488.
- Thöm I., Schult-Kronefeld O., Burkholder I., Schuch G., Andritzky B., Kastendieck H., Edler L., Wagener C., Bokemeyer C., Schumacher U. and Laack E. (2009). Expression of CEACAM-1 in pulmonary adenocarcinomas and their metastases. *Anticancer Res.* 29, 249-254.
- Wu C.T., Chang Y.H., Lin P.Y., Chen W.C. and Chen M.F. (2014). Thrombomodulin expression regulates tumorigenesis in bladder cancer. *BMC Cancer* 14, 375.
- Wu Q.B. and Sun G.P. (2015). Expression of COX-2 and HER-2 in colorectal cancer and their correlation. *World J. Gastroenterol.* 21, 6206.
- Xu J., Guo X., Jing M. and Sun T. (2018). Prediction of tumor mutation burden in breast cancer based on the expression of ER, PR, HER-2, and Ki-67. *Oncotargets Ther.* 11, 2269-2275.
- Zhu H.Y., Tong X.M., Lin X.N., Jiang L.Y., Wang J.X. and Zhang S.Y. (2015). Expression and distribution of calcium-binding protein S100P in human placenta during pregnancy. *Int. J. Fertil. Steril.* 8, 445.