

The flavonoid 6-hydroxyflavone prevention of cisplatin-induced nephrotoxicity

Zia Ud Din¹, Syed Umer Farooq², Muhammad Shahid^{3,4}, Osama Alghamdi⁵, Nawwaf Al-Hamoudi⁶, Fahim Vohra⁷ and Tariq Abduljabbar⁷

¹Department of Anatomy, Khyber Medical College, ²Department of Oral Pathology, Khyber College of Dentistry, ³Department of Pharmacy, Sarhad University of Science and Information Technology, ⁴Department of Pharmacy, University of Peshawar, Peshawar, Khyber Pakhtunkhwa, Pakistan, ⁵Department of Oral and Maxillofacial Surgery, College of Dentistry, ⁶Department of Periodontics and Community Dentistry and ⁷Department of Prosthetic Dental Science, College of Dentistry, King Saud University, Riyadh, Saudi Arabia

Summary. In this study, the flavonoid, 6-hydroxyflavone was investigated for its renal protective activity in the cisplatin rat model of nephrotoxicity. Male Sprague-Dawley rats weighing 200-250 g were included in the study. 6-Hydroxyflavone was daily administered at 25 and 50 mg/kg (i.p.), while ascorbic acid was used as a positive control and injected (i.p.) at 50 mg/kg for 15 days. The nephrotoxicity was evoked with a single cisplatin injection at 7.5 mg/kg on the tenth day of treatment. The renal function and levels of oxidative stress markers were assessed. Each tissue slide of different groups was observed under a compound microscope attached with a digital camera. Cisplatin significantly decreased the overall body weight with an increase in serum creatinine and urea and production of severe histopathological and oxidative stress in the kidneys. The daily treatment with 6-hydroxyflavone significantly attenuated the cisplatin associated detrimental changes in the body weight, and serum levels of creatinine and urea at both 25 mg/kg ($P<0.05$) and 50 mg/kg ($P<0.01$). The 6-hydroxyflavone treatment also preserved the renal histoarchitecture from the toxicological influence of cisplatin as evident from a significant reduction in the severity of histopathological changes in the renal tissues. Moreover, 6-hydroxyflavone also reduced the cisplatin-induced lipid peroxidation and corrected the renal antioxidant status. A similar protective effect was observed with the

positive control, ascorbic acid (50 mg/kg). These findings show that the flavonoid 6-hydroxyflavone has potential nephroprotective properties and can be used for the management of chemotherapy associated renal disturbances.

Key words: Chemotherapy induced renal toxicity, Nephrotoxicity, Natural product, Nephroprotection

Introduction

Significant advances have been made in recent years for the efficient treatment of cancer of different tissues, which dramatically increases the benefit of therapy, decreases the progression of tumors and increases the survival rate among cancer patients. Despite all these advances, drug induced nephrotoxicity still remains a major complication that profoundly limits the overall efficacy of protective chemotherapy in cancer patients (Sahni et al., 2009; Perazella, 2012). The occurrence of nephrotoxicity in cancer patients is reported as 60%. The nature of nephrotoxicity varies with the type of chemotherapeutic agent, the cancer type, patient age, nutritional status, and underlying secondary disease (Glezerman and Jaimes, 2016).

Cisplatin is a platinum-based drug and is one of the most effective chemotherapeutic agents having the highest cure rate of >90%. It is effectively used for the treatment of diverse neoplasms and cancer of different organs (Florea and Büsselberg, 2011). Its effectiveness is limited by acquired resistance to occurrence of severe side-effects (Barabas et al., 2008) that include nausea

and vomiting (Ullah et al., 2014, 2018; Alam et al., 2017), central nervous system (CNS) toxicity (Shahid et al., 2019a), ototoxicity (Gentilin et al., 2019), and renal injury (Pabla and Dong, 2008) as the most prominent. Various strategies have been devised to limit these untoward effects and include cisplatin analogues with reduced toxicologic propensity (carboplatin) (Adams et al., 1989; Martinez et al., 1993) in addition to other platinum analogues (Uehara et al., 2011; Lin et al., 2019) and adequate hydration of patients during treatment with cisplatin (Crona et al., 2017). Regardless of all these approaches, the cisplatin-induced toxicities, nephrotoxicity particularly is a major barrier that limits the overall effectiveness of cisplatin (Yao et al., 2007). Studies have shown that cisplatin-induced kidney injury involves four major mechanisms. These include injury to the proximal convoluted tubules (apoptosis, autophagy, dysregulation of cell-cycle proteins, activation of mitogen-activated protein kinase (MAPK) pathways, renal tubular epithelial cell damage, DNA damage, and dysfunction of mitochondria), generation of oxidative stress (increased reactive oxygen species (ROS), lipid peroxidation products and decreased antioxidant system), activation of inflammation [cytokines, tumor necrosis factor alpha (TNF- α), interleukin (IL)-33, nuclear factor kappa B (NF- κ B), infiltration of T-cells, neutrophils, mast cells, and macrophages] and injury to the vascular system in the kidneys (decreased renal blood flow). Collectively they lead to tubular cell necrosis and reduction in glomerular filtration rate, culminating in renal failure (Ozkok and Edelstein, 2014). In addition, apoptosis is also a major mechanism underlying cisplatin-induced renal cell injury, as cisplatin activates both the intrinsic mitochondrial pathway and the extrinsic death receptor pathway of apoptosis (Pabla and Dong, 2008).

Natural products including medicinal plants are efficient in reducing the complications of systemic diseases including that of kidney (Ghayur and Janssen, 2010; Peesa, 2013; Zhong et al., 2013; Aman et al., 2016; Raziq et al., 2016; Shahid et al., 2017a,c, 2019b; Nawaz et al., 2020). Antioxidants derived from natural products can improve the oxidative stress in kidney damage and protective mechanisms reduce lipid peroxidation, increasing the scavenging ability of antioxidant defense system in nephrons (Pervez et al., 2018). Flavonoids (natural products) form an integral part of both conventional and contemporary therapeutic systems (Nijveldt et al., 2001; Erlund, 2004; Akbar et al., 2017). This is due to their favorable aqueous solubility, lipophilicity and thermodynamic stability. They are easily absorbed and distributed, thus providing efficient bioavailability and nephroprotective potential (Dahal and Mulukuri, 2015). Furthermore, Flavanoids prevent renal oxidative stress by increasing the rate of glutathione (GSH) synthesis (Rodrigo and Bosco, 2006), in addition to prevention and attenuation of renal scarring in animal models of kidney diseases (Athira et al., 2016; Diwan et al., 2017; Vargas et al., 2018).

A previous *in vitro* study has shown that 6-hydroxyflavone potently inhibited the inflammatory responses induced by lipopolysaccharide in kidney mesangial cells and may play an important role in the attenuation of glomerulonephritis (Wang et al., 2015). Moreover, 6-hydroxyflavone strongly attenuates the cisplatin associated testicular toxicity (Din et al., 2019b) and hepatotoxicity (Din et al., 2019a). Considering the potential *in vitro* protective activity of 6-hydroxyflavone in kidney cells (Wang et al., 2015), the present study was designed to establish the *in vivo* renal protective activity of 6-hydroxyflavone and particularly its effectiveness in chemotherapy induced nephrotoxicity.

Materials and methods

Chemicals

6-Hydroxyflavone (98%) was procured from Sigma-Aldrich, St. Louis, MO, USA. It was dissolved in a vehicle comprising 5% dimethyl sulfoxide (DMSO) and 2% Tween80 (Akbar et al., 2016, Shahid et al., 2017b). The dose of 6-hydroxyflavone was prepared daily by dissolving 4 mg (4 mg/mL) of drug powder in 1 mL of vehicle. The positive control, ascorbic acid was acquired from Sigma-Aldrich, St. Louis, MO, USA. It was dissolved in normal saline and was freshly prepared daily (10 mg in 1 mL normal saline) prior to administration (Shahid et al., 2016).

In vitro antioxidant activity of 6-hydroxyflavone

The *in vitro* antioxidant activity of 6-hydroxyflavone was measured by the 2,2-diphenyl-1-picrylhydrazyl (DPPH) free radical scavenging assay as previously reported (Shahid and Subhan, 2014b; Shahid et al., 2016). Briefly, 1 mL of methanolic 0.1 mM DPPH free radical solution was mixed with 1 mL of different concentrations (1, 10, 30, 50, 100, 400, and 400 μ g/mL) of 6-hydroxyflavone or standard in methanol. The solutions were thoroughly mixed and incubated in the dark at an ambient temperature for 40 min. The absorbance was measured at 517 nm using a UV/visible spectrophotometer. Ascorbic acid was used as a standard. The control was prepared by mixing 2 mL of 0.1 mM DPPH free radical solution with 1 mL of methanol, while blank consisted of methanol alone. The percentage scavenging of the DPPH free radicals was calculated as follows.

Percentage of DPPH free radicals scavenging activity = [(AI-AII/AI) \times 100]

The absorbance of the control reaction was AI while the absorbance in the presence of sample was AII. The EC₅₀ value, which is the concentration of antioxidant at which there is 50% loss of DPPH free radicals scavenging activity, was calculated from the graph of absorbance versus respective concentrations using

Cisplatin-nephrotoxicity and 6-hydroxyflavone

nonlinear regression analysis. The antiradical power and stoichiometry were determined, and the assay was performed in triplicate.

Animals

Male Sprague-Dawley rats weighing 200–250 g were purchased from the Department of Pharmacy. They were acclimatized at a light dark cycle of 12/12 h at 20–24°C. The experiments were approved by the Ethical Committee of the Khyber Medical College, Peshawar, Pakistan and approval for the study was granted vide registration number 42/PG/KMC. The experimental procedures were performed in accordance with the UK Animals (Scientific Procedures) Act 1986.

Grouping of animals and treatment protocol

Nephrotoxicity was induced by a single intraperitoneal injection of cisplatin (7.5 mg/kg) (Sueishi et al., 2002; Saad et al., 2009). The different doses of 6-hydroxyflavone (25 and 50 mg/kg, i.p.) were selected based on our laboratory studies on flavonoids (Akbar et al., 2016, 2020; Shahid et al., 2017b). The ascorbic acid was used as a positive control and was administered at a dose of 50 mg/kg (i.p.) (Zhang et al., 2004). The animals were randomly divided into the following groups, with each group consisting of six animals:

Group A served as a negative control and was injected with the vehicle (1 mL/kg, i.p.). Group B received the vehicle for 15 consecutive days along with cisplatin as a single injection (7.5 mg/kg) on day 10 of the experiment. Group C received daily 6-hydroxyflavone injection at 25 mg/kg for 15 consecutive days along with cisplatin (7.5 mg/kg), which was administered two hours after 6-hydroxyflavone administration on day 10 of the experiment. Group D received daily 6-hydroxyflavone injection at 50 mg/kg for 15 consecutive days along with cisplatin (7.5 mg/kg), which was administered two hours after 6-hydroxyflavone administration on day 10 of the experiment. Group E received daily ascorbic acid injection at 50 mg/kg for 15 consecutive days along with cisplatin (7.5 mg/kg), which was administered two hours after ascorbic acid administration on day 10 of the experiment. Group F received daily 6-hydroxyflavone injection at 50 mg/kg for 15 consecutive days (Saad et al., 2009).

Collection of blood and tissue

At the termination of the dosing schedule, blood from each animal was withdrawn through cardiac puncture under xylazine plus ketamine anesthesia. The collected blood was centrifuged at 3000 rpm at 25°C. The serum was then separated in properly labeled Eppendorf tubes. The serum was stored at 4°C. After blood collection, each animal was euthanized by cervical dislocation. The major organs including the kidneys, liver, adrenals, brain, spleen, testis, thymus gland, lungs

and heart were collected. Their individual weight was measured using an analytical balance. After weighing, a sample of kidney from each group was reserved for measurement of oxidative stress markers, while the other portion of kidney was instantaneously transferred to a jar containing 10% neutrally buffered formalin. The tissues were kept for 48 h for fixation. The kidneys were then sliced and then subjected to histopathological processing according to standard protocols (Prophet et al., 1992; Shahid and Subhan, 2014a; Shahid et al., 2016). The tissues were dehydrated in graded ethanol solutions (50, 70, 80, 90, two changes each of 100%), cleared in two changes each of 100% xylene and were infiltrated and embedded in paraffin wax. The tissue blocks were sectioned at 4 µm through a rotary microtome and were stained with Harris hematoxylin and eosin (H&E).

Renal function and levels of oxidative stress markers

The serum creatinine and urea were measured according to the kits protocols specified by the manufacturer [(Chema Diagnostica CR 0500 CH, Italy for creatinine), and (Chema Diagnostica AZ F245 CH, Italy for urea)]. The serum electrolytes were determined in a private laboratory (OK Laboratory and Diagnostic Center, Peshawar, Pakistan). The kidney tissues were minced into small pieces and homogenized in ice-cold phosphate buffer saline to obtain 1:9 (w/v) whole homogenate. The level of lipid peroxidation was assayed in the form of thiobarbituric acid reacting substances (TBARS) and expressed as nmol of malondialdehyde (MDA)/g wet tissue (Ohkawa et al., 1979). Briefly, the tissue homogenate (0.2 mL) was mixed with 8.1% sodium dodecyl sulfate, 30% acetic acid and 0.8% thiobarbituric acid and the mix was heated at 95°C for 60 min and then cooled, after which 1 mL of distilled water and 5 mL of n-butanol:pyridine (15:1 v/v) solution were added and centrifuged at 5000 rpm for 20 min. The absorbance of the generated pink color in the organic layer was measured at 532 nm and 1,1,3,3-tetraethoxypropane was used as standard. The tissue reduced-GSH concentration was measured by the method as described by Ellman (1959) and was expressed as µmol/g tissue. Briefly, 100 µL of tissue homogenate was added to 0.2 M Tris-EDTA buffer before the addition of 20 µL of Ellman's reagent (10 mmol/L DTNB in methanol) and the absorbance was recorded at 412 nm. The glutathione peroxidase (GSH-Px) activity was assayed using the method of Chiu et al. (Chiu et al., 1976). The catalase activity was determined according to the method described by Aebi (Aebi, 1984). The superoxide dismutase (SOD) activity was determined according to the method of Misra and Fridovich (Misra and Fridovich, 1972).

Histopathological evaluation of kidneys

Each tissue slide of different groups was observed under a compound microscope attached with a digital

camera. The photomicrographs were observed at two resolutions (100x and 400x magnification). The tissues slides were evaluated by an experienced pathologist who was blinded to the various treatment groups. The histopathological changes were scored according to the scoring system as previously reported (El-Sheikh et al., 2012; Hamed et al., 2012). Moreover, the slides were also interpreted according to the EGTI scoring system for kidney tissues i.e. endothelial, glomerular, tubular, and interstitial (Khalid et al., 2016).

Statistical analysis

The data were expressed as mean \pm S.E.M. The EC50 value in the *in vitro* antioxidant activity was calculated from the graph of absorbance versus respective concentrations using nonlinear regression analysis. The *in vivo* data were analyzed using one-way ANOVA followed by Tukey's post hoc test using GraphPad Prism 5 (GraphPad Software Inc. San Diego CA, USA). A P value of ≤ 0.05 was accepted as significant.

Results

In vitro antioxidant activity of 6-hydroxyflavone

In the DPPH free radical scavenging assay, a concentration dependent percentage inhibition of DPPH free radicals was observed for both 6-hydroxyflavone (13.38-94.89% at 1-400 $\mu\text{g/mL}$), and ascorbic acid (26.23-97.08% at 1-400 $\mu\text{g/mL}$). The maximum inhibition of DPPH free radicals by 6-hydroxyflavone was observed as 94.89% at 400 $\mu\text{g/mL}$, while that of ascorbic acid was 97.08% at 400 $\mu\text{g/mL}$, respectively. The EC50, antiradical power and stoichiometry of 6-hydroxyflavone and ascorbic acid are shown in Table 1.

Table 1. *In vitro* antioxidant activity of 6-hydroxyflavone and ascorbic acid.

Concentration ($\mu\text{g/mL}$)	Percentage inhibition (%)	
	6-Hydroxyflavone	Ascorbic acid
1	13.38 \pm 1.177	26.23 \pm 0.107
10	59.81 \pm 4.775	86.65 \pm 0.278
30	89.55 \pm 1.177	96.08 \pm 0.599
50	90.41 \pm 2.044	96.09 \pm 0.781
100	93.77 \pm 1.595	96.47 \pm 0.481
200	92.78 \pm 0.835	96.79 \pm 0.096
400	94.89 \pm 0.802	97.08 \pm 0.321
Antioxidant strength		
EC50 ($\mu\text{g/mL}$)	8.632 \pm 0.733	4.672 \pm 1.485
Antiradical power	0.116 \pm 0.011	0.238 \pm 0.075
Stoichiometry	17.26 \pm 1.466	9.344 \pm 2.970

Values are expressed as mean \pm S.E.M from three separate experiments.

Effect of 6-hydroxyflavone and cisplatin on general behavior and physical appearance of animals

Administration of cisplatin produced severe changes in the physical appearance of animals. The vehicle treated cisplatin animals appeared thin and lethargic and exhibited repetitive wet dog shakes. Their fur was raised, and skin appeared bluish in color. On examination, the locomotion of the animals was considerably reduced with a decrease in exploratory behavior. The fur on the posterior side of the body appeared contaminated which may be due to a reduction in the overall mobility. Bleeding from the nose was observed and clotted patches of blood were examined along the periphery of nostrils. The general gait of the animals was deranged. A decrease in grooming behavior was noted. The animals were moderately active to pinching of their tails. A reduction in the escape behavior was observed after lifting the animals by their tails.

Similar behavioral changes were noted in groups of animals treated with 6-hydroxyflavone at 25 and 50 mg/kg plus cisplatin; however, the presentation of these behaviors was less severe in comparison to the vehicle treated cisplatin animals. Particularly, the animals treated with 6-hydroxyflavone at 50 mg/kg were resistant to the cisplatin associated aberrant changes in the behavior and physical appearance. The gross changes observed in this group of animals were mild to moderate in severity compared to the 6-hydroxyflavone lower dose group (25 mg/kg), in which moderate to severe behavioral changes were observed. The positive control, ascorbic acid treated animals also showed mild to moderate changes in the general behavioral and moderate to less severe changes in the general appearance of animals.

Effect of 6-hydroxyflavone and cisplatin on body weight

The vehicle treated cisplatin animals displayed a significant decrease ($P < 0.001$) in their body weight as compared to the vehicle alone treated animals. A significant increase ($P < 0.05$) in body weight was observed with 6-hydroxyflavone at a dose of 50 mg/kg, as compared to the vehicle treated cisplatin animals. A significant decrease ($P < 0.001$) in body weight gain was observed for the vehicle plus cisplatin animals as compared to the negative control. However, the animals administered with 6-hydroxyflavone at a dose of 50 mg/kg showed a significant ($P < 0.05$) increase in body weight gain as compared to vehicle-cisplatin group (Fig. 1).

Effect of 6-hydroxyflavone and cisplatin on organ weights

No significant changes in the organ weights were noted in the groups of animals administered with vehicle plus cisplatin, 6-hydroxyflavone at 25 and 50 mg/kg plus cisplatin, and ascorbic acid at 50 mg/kg plus cisplatin.

Cisplatin-nephrotoxicity and 6-hydroxyflavone

Effect of 6-hydroxyflavone and cisplatin on serum creatinine, urea and electrolytes

Administration of cisplatin (7.5 mg/kg) was associated with a significant increase ($P<0.001$) in the serum level of creatinine, when compared to the serum level of vehicle treated animals. A significant reversal of cisplatin-induced elevated serum creatinine level was noted with 6-hydroxyflavone at 25 mg/kg ($P<0.05$) and 50 mg/kg ($P<0.01$), as well as with the ascorbic acid at 50 mg/kg ($P<0.001$), when compared to vehicle treated cisplatin animals. Cisplatin at 7.5 mg/kg produced a significant increase ($P<0.001$) in the level of urea as compared to vehicle treated negative controls. 6-Hydroxyflavone produced a significant reversal of cisplatin-induced increased serum urea level at 25 mg/kg ($P<0.05$) and 50 mg/kg ($P<0.01$), when compared to vehicle-cisplatin group. The positive control, ascorbic acid also provided a beneficial proclivity against

nephrotoxicity as it significantly decreased ($P<0.01$) the elevated serum levels of urea. Treatment with the vehicle, vehicle plus cisplatin, 6-hydroxyflavone at 25 and 50 mg/kg plus cisplatin, and ascorbic acid at 50 mg/kg plus cisplatin produced no significant effect on the serum levels of sodium, potassium, and chloride (Table 2).

Effect of 6-hydroxyflavone on cisplatin induced renal oxidative stress

Administration of cisplatin was associated with a marked induction of lipid peroxidation and oxidative stress in the kidneys. This has been observed from the significant increase in the contents of TBARS ($P<0.001$) as well as a significant reduction in the levels of GSH ($P<0.001$), and the activities of GSH-Px ($P<0.001$), catalase ($P<0.001$) and SOD ($P<0.001$), as compared to vehicle-cisplatin animals. A significant reduction in the cisplatin-induced elevated TBARS levels was produced by 6-hydroxyflavone at 25 mg/kg ($P<0.05$) and 50 mg/kg ($P<0.01$). Moreover, the restoration of the antioxidant status parameters underlying glutathione ($P<0.05$, $P<0.01$), glutathione peroxidase ($P<0.05$, $P<0.001$), catalase ($P<0.05$, $P<0.01$) and SOD ($P<0.05$, $P<0.01$) levels in the cisplatin exposed kidneys was significant for 6-hydroxyflavone treatment at doses of 25 and 50 mg/kg. The group of animals treated with ascorbic acid at 50 mg/kg showed a similar significant antioxidant effect in the kidneys during cisplatin asserted nephrogenic oxidative stress i.e. $P<0.01$ for GSH, GSH-Px, catalase and SOD, as compared to the vehicle treated cisplatin injected animals (Fig. 2).

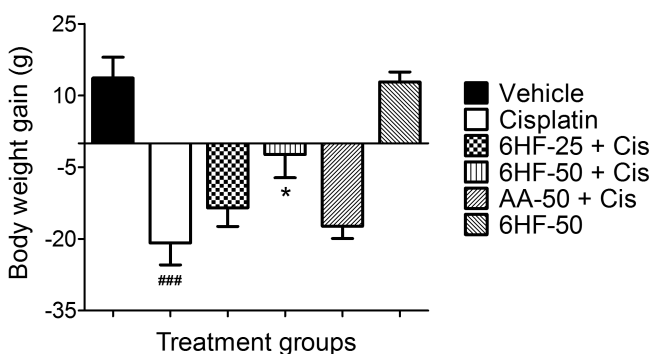


Fig. 1. Body weight gain in the cisplatin (Cis) administered animals pre-treated with 6-hydroxyflavone at 25 mg/kg (6HF-25) and 50 mg/kg (6HF-50), and standard ascorbic acid at 50 mg/kg (AA-50). Each bar represents mean body weight gain in grams \pm SEM. ### $P<0.001$ shows a comparison with the vehicle administered experimental group, * $P<0.05$ shows a comparison with the cisplatin non-treated animals group. One-way ANOVA with Tukey's test, each group contained 6 animals.

Effect of 6-hydroxyflavone on cisplatin induced renal histopathology

Administration of cisplatin (7.5 mg/kg) produced typical histological changes of chemotherapy-induced nephrotoxicity. These histopathological changes were observed as necrosis of the renal tubules particularly affecting the proximal convoluted tubules in which

Table 2. Effect of 6-hydroxyflavone at 25 mg/kg (6HF-25) and 50 mg/kg (6HF-50), and standard ascorbic acid at 50 mg/kg (AA-50) and cisplatin (Cis) on serum creatinine, urea and electrolytes.

Treatment	Creatinine (mg/dL)	Urea (mg/dL)	Electrolytes (mmol/L)		
			Sodium	Potassium	Chloride
Vehicle	0.633 \pm 0.055	34.00 \pm 5.508	140.2 \pm 2.121	4.417 \pm 0.1641	103.1 \pm 1.317
Cisplatin	4.883 \pm 0.486###	329.2 \pm 32.29###	131.1 \pm 3.724	5.883 \pm 0.6539	96.51 \pm 3.658
6HF-25+Cis	2.851 \pm 0.672*	213.2 \pm 36.37*	131.1 \pm 1.844	5.333 \pm 0.3393	97.67 \pm 2.861
6HF-50+Cis	1.951 \pm 0.567**	159.7 \pm 34.43**	135.2 \pm 3.582	5.383 \pm 0.4037	99.01 \pm 3.183
AA-50+Cis	1.851 \pm 0.545***	158.2 \pm 27.03**	132.8 \pm 3.497	4.351 \pm 0.2247	101.7 \pm 1.431
6HF-50	0.766 \pm 0.081	35.17 \pm 5.173	140.1 \pm 1.317	4.251 \pm 0.1688	102.3 \pm 1.085

The mean values are denoted as mean serum levels \pm SEM. ### $P<0.001$ shows a comparison with the vehicle only administered animals group, * $P<0.05$, ** $P<0.01$, *** $P<0.001$ shows a comparison with the vehicle treated cisplatin animals group. One-way ANOVA with Tukey's post hoc test, each group contained 6 animals.

Cisplatin-nephrotoxicity and 6-hydroxyflavone

extensive loss of the brush border was noted. The epithelial cells lost their integrity and showed severe desquamation. Debris of cuboidal cells was visible in the empty renal tubules. The remaining cuboidal epithelial cells showed severe signs of cell injury. The cytoplasm contained vacuoles and the apical cell membrane was disrupted. Cellular cast was observed in most distal convoluted tubules. The tuft of glomerulus was retracted and glomerular capillaries were heavily congested with red blood cells. Deposition of connective tissue was also observed with thickening of the glomerular capsule. The interstitial spaces were heavily dilated and contained numerous lymphocytes, red blood cells and cellular debris (Fig. 3B).

Treatment with 6-hydroxyflavone has a protective effect against the toxicological influence of cisplatin on the renal tissue. The 25 mg/kg dose preserved the normal histological architecture of the renal tubules and glomerulus but was associated with mild to moderate histopathological changes as congestion of interstitial spaces and glomerulus with red blood cells, disruption of brush border lining the cuboidal epithelial cells of the proximal convoluted tubules, dilatation of the interstitial spaces containing small numbers of lymphocytes and large numbers of red blood cells, formation of cast in a small number of renal tubules, vacuolar changes in the epithelial cells lining both the proximal and distal convoluted tubules (Fig. 3C). Treatment for 15

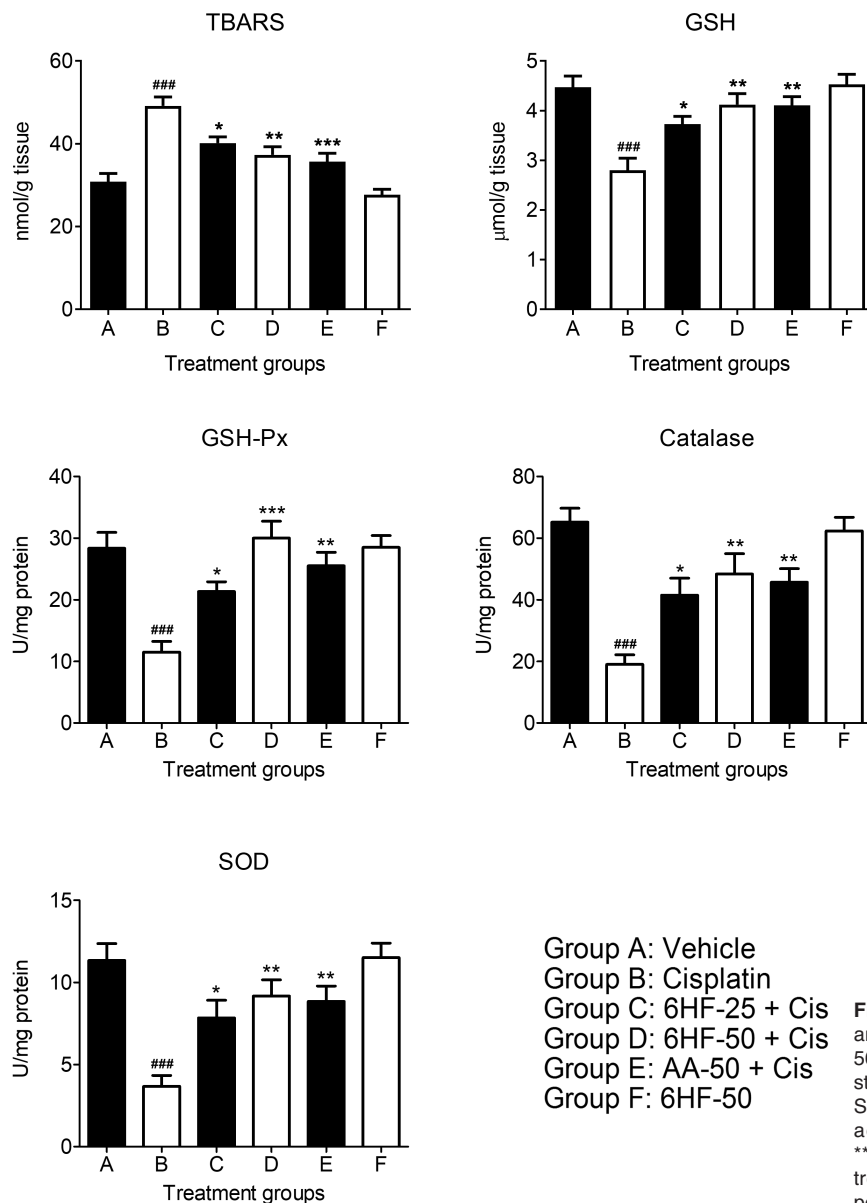


Fig. 2. Effect of 6-hydroxyflavone at 25 mg/kg (6HF-25) and 50 mg/kg (6HF-50), and standard ascorbic acid at 50 mg/kg (AA-50) on cisplatin (Cis) induced oxidative stress in kidneys. Ear column represents mean value \pm SEM. ^{###} $P < 0.001$ shows a comparison with the vehicle administered animals group, ^{*} $P < 0.05$, ^{**} $P < 0.01$, ^{***} $P < 0.001$ shows a comparison with the cisplatin non-treated animals group. One-way ANOVA with Tukey's post hoc test, each group contained 6 animals.

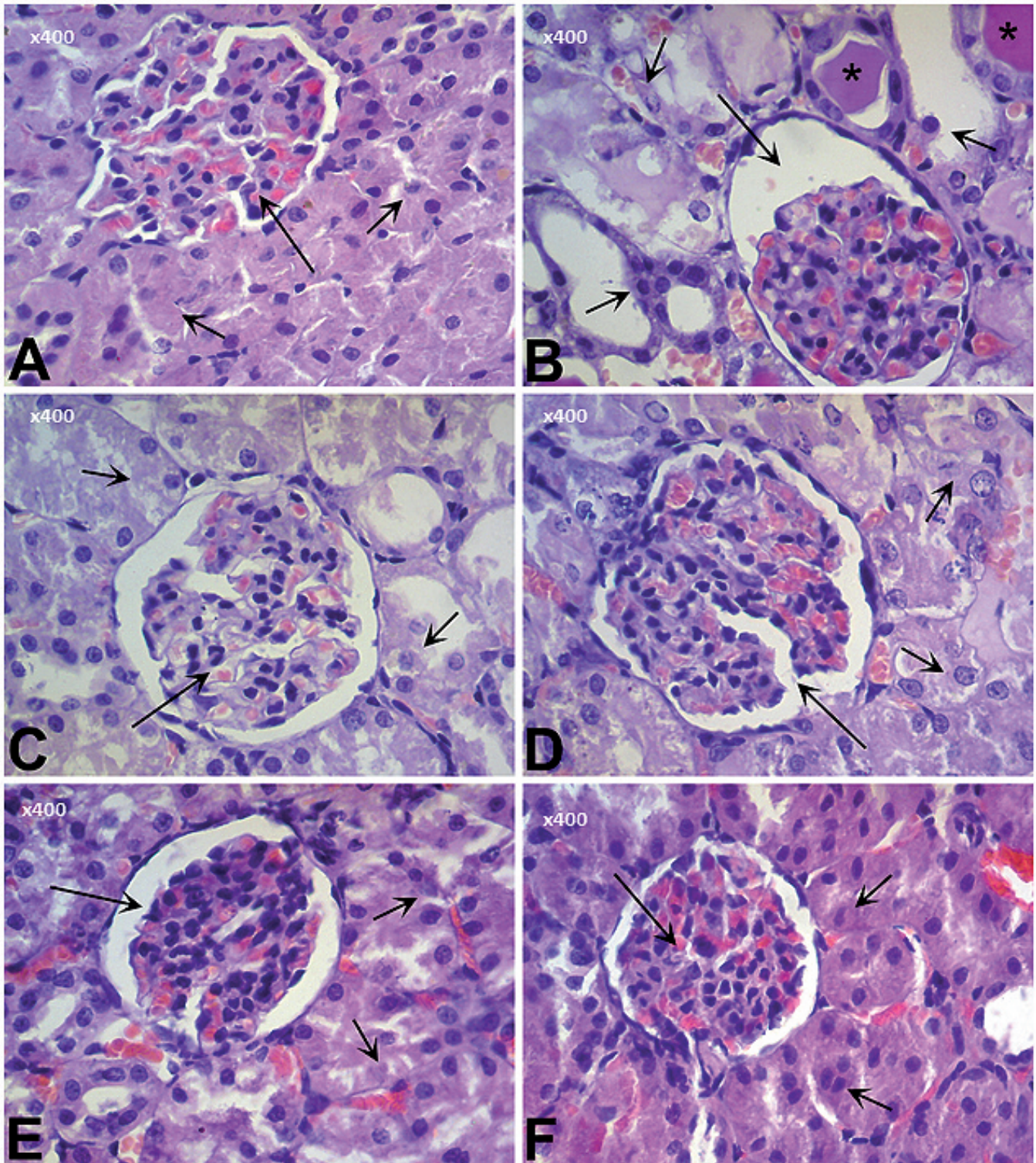


Fig. 3. Histopathological evaluation of cisplatin-induced nephrotoxicity after treatment with 6-hydroxyflavone and ascorbic acid (H & E). **A.** Photomicrograph of a section of kidney from a rat treated with vehicle showing normal appearing glomerulus (large arrow) and renal tubules (small arrows). **B.** Photomicrograph of a section of kidney from a rat treated with vehicle and administered with cisplatin showing retraction of glomerulus with an increase in the capsular space (large arrow), extensive necrosis of cuboidal epithelial cells lining the renal tubules with a loss of brush border (small arrows) and accumulation of eosinophilic cellular casts in the lumen of renal tubules (asterisk). **C.** Photomicrograph of a section of kidney from a rat treated with 6-hydroxyflavone at 25 mg/kg and administered with cisplatin showing normal glomerulus (large arrow) and mild necrosis of the renal tubules (small arrows). Normal histological features of glomerulus (large arrow) and proximal convoluted tubules (small arrows) are visible in the group of animals treated with 6-hydroxyflavone at 50 mg/kg plus cisplatin (**D**), ascorbic acid at 50 mg/kg plus cisplatin (**E**), and 6-hydroxyflavone alone at 50 mg/kg (**F**). x 400.

continuous days with the 50 mg/kg dose potently inhibited the formation of histopathological changes typical of cisplatin in the kidneys. This dose preserved the characteristic appearance of the proximal convoluted tubules. There was a mild dilatation of the interstitial spaces and a visible congestion of these spaces with red blood cells in a small number of cross-sectional areas. A mild retraction of the glomerulus, dilatation of the renal tubules with mild disruption of brush border were also evident (Fig. 3D).

A similar histopathological profile was observed in the group of animals treated with the positive control, ascorbic acid, which was administered continuously for 15 days at a dose of 50 mg/kg (Fig. 3E). Moreover, the animals treated with the vehicle or 6-hydroxyflavone alone at a dose of 50 mg/kg for 15 consecutive days showed no significant histological aberrations in the renal tissues that were characteristic of cisplatin nephrotoxicity (Fig. 3F).

Effect of 6-hydroxyflavone and cisplatin on the severity of histopathological changes in kidneys

Administration of cisplatin at 7.5 mg/kg was associated with extensive tubular necrosis ($P<0.001$), cellular casts in the renal tubules ($P<0.001$), retraction of

the tuft of glomerular capillaries with an increase in the space between the inner visceral and outer parietal layers of the renal capsule ($P<0.001$), hemorrhage and congestion of blood vessels with red blood cells ($P<0.001$), extensive degradation of brush border lining the cuboidal cells of the proximal convoluted tubules ($P<0.001$), inflammation of the interstitial spaces with lymphocytes infiltration ($P<0.001$) and disruption of endothelial cells with glomerular congestion ($P<0.001$). Moderate thickening of the glomerular capsule was observed ($P<0.001$). Treatment with 6-hydroxyflavone for 15 consecutive days exerted a protective effect against the cisplatin-induced histopathological changes in the renal tissues. At doses of 25 and 50 mg/kg, 6-hydroxyflavone potently inhibited the formation of cisplatin-induced tubular necrosis ($P<0.05$ and $P<0.01$), tubular cast ($P<0.001$ and $P<0.001$), retraction of glomerulus ($P<0.05$ and $P<0.001$), thickening of capsular layer ($P<0.05$ and $P<0.001$), hemorrhage and congestion of vessels ($P<0.001$ only with 50 mg/kg), loss of brush border ($P<0.05$ and $P<0.001$), inflammation of the interstitium ($P<0.05$ and $P<0.001$), endothelial disruption ($P<0.05$ and $P<0.001$) and congestion of glomerulus ($P<0.01$ only with 50 mg/kg), respectively. The positive control, ascorbic acid also potently attenuated ($P<0.001$) the cisplatin-induced nephrotoxicity (Table 3).

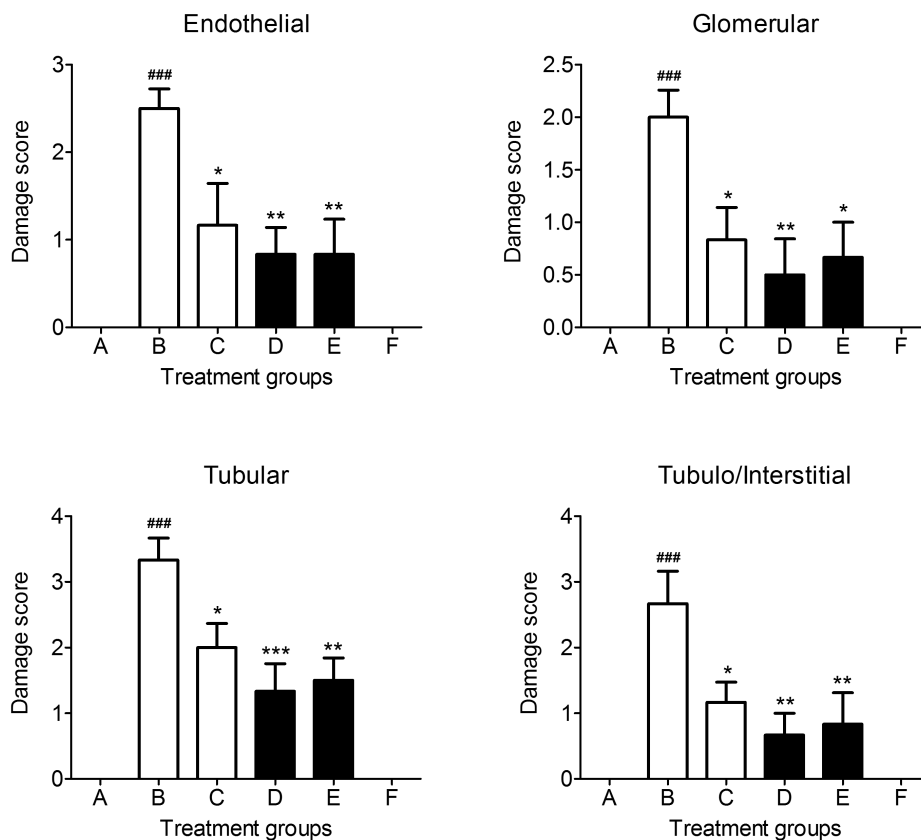


Fig. 4. Effect of 6-hydroxyflavone and cisplatin on the endothelial, glomerular, tubular, and tubule/interstitial damage score in the EGTI scoring system. The mean values were denoted as mean damage score \pm SEM. ### $P<0.001$ showing a comparison with the vehicle administered animals, * $P<0.05$, ** $P<0.01$, *** $P<0.001$ shows a comparison with the cisplatin alone animals group. One-way ANOVA with Tukey's post hoc test, each group contained 6 animals. Group A: vehicle treated control, Group B: vehicle plus cisplatin, Group C: 6-hydroxyflavone at 25 mg/kg plus cisplatin (7.5 mg/kg), Group D: 6-hydroxyflavone at 50 mg/kg plus cisplatin (7.5 mg/kg), Group E: ascorbic acid at 50 mg/kg plus cisplatin (7.5 mg/kg), Group F: 6-hydroxyflavone at 50 mg/kg for 15 days.

Cisplatin-nephrotoxicity and 6-hydroxyflavone

Effect of 6-hydroxyflavone and cisplatin on the severity of histopathological changes in kidneys according to the EGTI scoring system

In the tubules, cisplatin was associated with severe damage ($P<0.001$) and occurred as extensive loss of brush border, thickening of basal membrane, tubular necrosis, inflammation and cast formation. Cisplatin also markedly damaged ($P<0.001$) the endothelial layers as severe endothelial swelling, endothelial disruption and its eventual loss were observed. The glomerulus was also severely affected by cisplatin ($P<0.001$) and the pathological changes observed were thickening of the Bowman's capsule, and retraction of the glomerular tuft with underlying fibrosis. The interstitium was severely damaged ($P<0.001$) by cisplatin as extensive inflammatory changes were observed with severe infiltration of lymphocytes and red blood cells along with debris of necrotic renal tubules. The protective effect conferred by 6-hydroxyflavone at 25 and 50 mg/kg was noted as potent reversal of histopathological changes in the tubules ($P<0.01$ and $P<0.001$), endothelial ($P<0.05$ and $P<0.01$), glomerulus ($P<0.05$ and $P<0.01$), and interstitium ($P<0.05$ and $P<0.01$), respectively. Similarly, the positive control, ascorbic acid at 50 mg/kg also significantly alleviated the cisplatin-induced degenerative changes in the tubules ($P<0.01$), endothelial ($P<0.01$), glomerulus ($P<0.05$), and interstitium ($P<0.01$) (Fig. 4).

Discussion

In this study, the protective activity of the flavonoid, 6-hydroxyflavone was investigated in an animal model of kidney disease. The cisplatin was administered at 7.5 mg/kg and the animals have been monitored grossly, biochemically and histopathologically for the induction of kidney injury. Similar dose of cisplatin has shown to induce reliable nephrotoxicity in laboratory animals without significant incidence of mortality (Kodama et al., 2009; Prabhu et al., 2013). In this study, cisplatin

produced significant changes in the overall behavior and body weights of animals and these findings corroborated with the previous reported studies on cisplatin (Antunes et al., 2000; de Oliveira Mora et al., 2003; Atessahin et al., 2005). cisplatin-induced body weight loss has been reported in both humans and acute or chronic animal models (Garcia et al., 2013; Hojman et al., 2014). Various mechanisms have been reported to exist underlying cisplatin-induced anorexia and these include gastrointestinal disorders (nausea, vomiting, distention of stomach, gastric stasis which results in decreased intake of food), a decrease in plasma level of ghrelin (hunger hormone) and decreased secretion of serotonin from the enterochromaffin cells. The reduction in ingestion of food and reduced body capacity to utilize the food lead to a loss of body weight during cisplatin treatment (Endo and Kanbayashi, 2003; Garcia et al., 2013).

In this study, cisplatin injection produced a significant increase in the serum creatinine and urea. The serum level of creatinine is considered as a useful biomarker for screening and diagnosing kidney diseases (Levey et al., 1988). Increased blood urea level is used in the differential diagnosis of acute kidney diseases and a higher level has been observed in pathological conditions like congestive cardiac failure, fever, kidney stone blockage disease, shock and gastrointestinal bleeding among others diseases (Lopez-Giacoman and Madero, 2015). Cisplatin treatment has been shown to decrease the serum aspartate and alanine aminotransferase, lactic dehydrogenase and alkaline phosphatase, while it increases isocitric dehydrogenase and glutathione reductase activities. An increase in blood urea, total lipids, creatinine, and magnesium while a decrease in albumin and glucose have been observed after treatment with cisplatin (Bogin et al., 1994; Arunkumar et al., 2012).

Studies have shown that cisplatin produces dilatation of renal tubules, degeneration of epithelial cells, cellular and proteinaceous casts in the lumen of tubules, necrosis and apoptosis with epithelial desquamation of the

Table 3. Effect of 6-hydroxyflavone at 25 mg/kg (6HF-25) and 50 mg/kg (6HF-50), and standard ascorbic acid at 50 mg/kg (AA-50) on the severity of cisplatin (Cis)-induced histopathological changes during nephrotoxicity.

Lesion description	Vehicle	Cisplatin	6HF-25 + Cis	6HF-50 + Cis	AA-50 + Cis	6HF-50
Necrosis of tubules	0.0±0.0	2.667±0.211###	1.500±0.223*	1.000±0.365**	1.000±0.365***	0.0±0.0
Formation of cellular cast	0.0±0.0	2.667±0.211###	1.333±0.333***	0.500±0.223***	0.333±0.211***	0.0±0.0
Glomerular retraction	0.0±0.0	2.167±0.166###	1.167±0.307*	0.500±0.223***	0.500±0.223***	0.0±0.0
Thickening of capsule	0.0±0.0	1.333±0.211###	0.333±0.218**	0.166±0.166***	0.166±0.167***	0.0±0.0
Hemorrhage and vessels congestion	0.0±0.0	2.500±0.223###	1.833±0.307	0.833±0.307***	1.000±0.258***	0.0±0.0
Loss of brush border	0.0±0.0	2.500±0.341###	1.333±0.333*	0.500±0.224***	0.500±0.223***	0.0±0.0
Interstitial inflammation	0.0±0.0	2.167±0.307###	1.000±0.365*	0.500±0.223***	0.333±0.212***	0.0±0.0
Endothelial disruption	0.0±0.0	2.000±0.365###	1.000±0.258*	0.500±0.224***	0.334±0.211***	0.0±0.0
Glomerular congestion	0.0±0.0	2.500±0.223###	1.667±0.333	1.167±0.307**	0.833±0.307***	0.0±0.0

Severity of damage is graded as no change (0); mild (1); moderate (2); severe (3). The mean values denote mean severity score ± SEM. ### $P<0.001$ shows a comparison with the vehicle only administered animals group, * $P<0.05$, ** $P<0.01$, *** $P<0.001$ shows a comparison with the vehicle treated cisplatin animals group. One-way ANOVA with Tukey's post hoc test, each group contained 6 animals.

proximal tubules, dilatation with condensed glomerular capillary tuft, and interstitial infiltration of mononuclear cells containing focal hemorrhagic foci (Nasr, 2013; Mashhadi et al., 2014). Similar patterns of histological aberrations were observed in this study. The various ultrastructural changes produced by cisplatin are cell size reduction, decreased number of basal infoldings, a reduction in apical lysosomes and pinocytotic vesicles with fragmentation and shredding of the brush border, irregular nuclear membrane, nuclear heterochromatin margination and loss of nucleolus, reduction and condensation of mitochondria, and apoptotic changes (Nasr, 2013; Craciun and Pasca, 2014).

In the present study, the flavonoid, 6-hydroxyflavone was evaluated for its renal protective effect against renal injury induced by cisplatin. Flavonoids have been shown to possess potent nephroprotective properties and are regarded as the most efficient agents for kidney protection (Dahal and Mulukuri, 2015). The flavonoids, hesperidin and lipoic acid possess a protective activity against sodium arsenite and trichloroethylene induced nephrotoxicity (Pires Das Neves et al., 2004; Siddiqi et al., 2015). Naringenin afforded protection against cadmium, carbon tetrachloride and gentamicin induced oxidative renal dysfunction (Renugadevi and Prabu, 2009; Hermenean et al., 2013; Fouad et al., 2014). Rutin has been shown to provide a nephroprotective effect against renal damage induced by ferric nitrilotriacetate (Shimoi et al., 1997). The flavonoid quercetin has been shown to be effective against gentamicin and cadmium induced oxidative stress and nephrotoxicity (Morales et al., 2006; Abdel-Raheem et al., 2009). The polyphenols isolated from red wine have antiapoptotic properties and strongly prevented the cyclosporine-induced nephrotoxicity (Rezzani et al., 2009). Silymarin, which is a strong free radical scavenger provides a protective effect on kidney cells against oxidative damage induced by cisplatin (Abdelmeguid et al., 2010), acetaminophen (Bektur et al., 2016), fumonisin B1 (He et al., 2002) and ischemia/ reperfusion injury (Senturk et al., 2008). Flavonoids possess strong anti-urolithiasis activity and are appropriate for patients with small size of stones and those undergoing drug therapy (Zeng et al., 2018).

In the present study, daily administration of 6-hydroxyflavone provided a protective effect against the toxicological influence of cisplatin in kidneys. It has been observed that 6-hydroxyflavone has a potent relaxant effect on the trachea (Ko et al., 2003) and possesses strong anti-allergic properties by inhibiting the release of hexosaminidase (Cheong et al., 1998). In addition, it has DNA binding activity (Vitorino and Sottomayor, 2010) and is a potent inhibitor of 17 β -hydroxysteroid dehydrogenase with potential to treat estrogen associated diseases (Brožič et al., 2009). A study has reported potent anti-inflammatory activity of 6-hydroxyflavone in the kidney mesangial cells and thus provides a platform to develop naturally derived products for the management of nephritis and other kidney diseases (Wang et al., 2015).

Conclusion

A single injection of cisplatin produced a marked reduction in body weight, increased the serum creatinine and urea levels and produced marked histopathological changes in the glomerulus and renal tubules. However, these changes were counterbalanced by the protective effect of the flavonoid, 6-hydroxyflavone and succinctly reversed the body weight loss, normalizing the serum biochemical changes and afforded protection against oxidative stress and the underlying structural damage in the renal parenchyma. Further studies are warranted to check the effect of 6-hydroxyflavone on anti-inflammatory markers as cisplatin-induced oxidative stress triggers inflammatory pathways. Additionally, the effect of 6-hydroxyflavone on the expression of kidney injury molecule should be investigated as its selective expression in the renal proximal tubular epithelial cells is an important indicator of structural injury to kidney tissue.

Acknowledgements. The authors are grateful to the Researchers Supporting Project at King Saud University for funding through Researchers Supporting Project No. RSP-2019-44. The authors gratefully acknowledge the Khyber Medical College, Peshawar, Pakistan and University of Peshawar, Peshawar, Pakistan for providing all the necessary facilities to carry out this research work.

Conflicts of Interest. None.

References

- Abdel-Raheem I.T., Abdel-Ghany A.A. and Mohamed G.A. (2009). Protective effect of quercetin against gentamicin-induced nephrotoxicity in rats. *Biol. Pharm. Bull.* 32, 61-67.
- Abdelmeguid N.E., Chmaisse H.N. and Zeinab N.S.A. (2010). Protective effect of silymarin on cisplatin-induced nephrotoxicity in rats. *Pak. J. Nutr.* 9, 624-636.
- Adams M., Kerby I., Rucker I., Evans A., Johansen K. and Franks C. (1989). A comparison of the toxicity and efficacy of cisplatin and carboplatin in advanced ovarian cancer. *Acta Oncol.* 28, 57-60.
- Aebi H. (1984). Catalase *in vitro*. *Methods Enzymol.* 105, 121-126.
- Akbar S., Subhan F., Karim N., Shahid M., Ahmad N., Ali G., Mahmood W. and Fawad K. (2016). 6-methoxyflavanone attenuates mechanical allodynia and vulvodinia in the streptozotocin-induced diabetic neuropathic pain. *Biomed. Pharmacother.* 84, 962-971.
- Akbar S., Subhan F., Shahid M., Wadood A., Shahbaz N., Farooq U., Ayaz M. and Raziq N. (2020). 6-methoxyflavanone abates cisplatin-induced neuropathic pain apropos anti-inflammatory mechanisms: A behavioral and molecular simulation study. *Eur. J. Pharmacol.* 172972.
- Akbar S., Subhan F., Karim N., Aman U., Ullah S., Shahid M., Ahmad N., Fawad K. and Sewell R.D. (2017). Characterization of 6-methoxyflavanone as a novel anxiolytic agent: A behavioral and pharmacokinetic approach. *Eur. J. Pharmacol.* 801, 19-27.
- Alam J., Subhan F., Ullah I., Shahid M., Ali G. and Sewell R.D. (2017). Synthetic and natural antioxidants attenuate cisplatin-induced vomiting. *BMC Pharmacol. Toxicol.* 18, 4.
- Aman U., Subhan F., Shahid M., Akbar S., Ahmad N., Ali G., Fawad K.

Cisplatin-nephrotoxicity and 6-hydroxyflavone

- and Sewell R.D. (2016). Passiflora incarnata attenuation of neuropathic allodynia and vulvodinia apropos gaba-ergic and opioidergic antinociceptive and behavioural mechanisms. *BMC Complement. Altern. Med.* 16, 77.
- Antunes L.M.G., Darin J.D.A.C. and Bianchi M.D.L.P. (2000). Protective effects of vitamin C against cisplatin-induced nephrotoxicity and lipid peroxidation in adult rats: A dose-dependent study. *Pharmacol. Res.* 41, 405-411.
- Arunkumar P., Viswanatha G., Radheshyam N., Mukund H. and Belliyappa M. (2012). Science behind cisplatin-induced nephrotoxicity in humans: A clinical study. *Asian Pac. J. Trop. Biomed.* 2, 640-644.
- Atessahin A., Yilmaz S., Karahan I., Ceribasi A.O. and Karaoglu A. (2005). Effects of lycopene against cisplatin-induced nephrotoxicity and oxidative stress in rats. *Toxicology* 212, 116-123.
- Athira K., Madhana R.M. and Lahkar M. (2016). Flavonoids, the emerging dietary supplement against cisplatin-induced nephrotoxicity. *Chem. Biol. Interact.* 248, 18-20.
- Barabas K., Milner R., Lurie D. and Adin C. (2008). Cisplatin: A review of toxicities and therapeutic applications. *Vet. Comp. Oncol.* 6, 1-18.
- Bektur N.E., Sahin E., Baycu C. and Unver G. (2016). Protective effects of silymarin against acetaminophen-induced hepatotoxicity and nephrotoxicity in mice. *Toxicol. Ind. Health* 32, 589-600.
- Bogin E., Marom M. and Levi Y. (1994). Changes in serum, liver and kidneys of cisplatin-treated rats; effects of antioxidants. *Clin. Chem. Lab. Med.* 32, 843-852.
- Brožič P., Kocbek P., Sova M., Kristl J., Martens S., Adamski J., Gobec S. and Rižner T.L. (2009). Flavonoids and cinnamic acid derivatives as inhibitors of 17 β -hydroxysteroid dehydrogenase type 1. *Mol. Cell. Endocrinol.* 301, 229-234.
- Cheong H., Ryu S.-Y., Oak M.-H., Cheon S.-H., Yoo G.-S. and Kim K.-M. (1998). Studies of structure activity relationship of flavonoids for the anti-allergic actions. *Arch. Pharm. Res.* 21, 478-480.
- Chiu D.T., Stults F.H. and Tappel A.L. (1976). Purification and properties of rat lung soluble glutathione peroxidase. *Biochim. Biophys. Acta* 445, 558-566.
- Craciun C. and Pasca C. (2014). Structural and ultrastructural data on side effects of cisplatin in spleen, kidney and liver of rats. *Acta Metallomica* 11, 9-22.
- Crona D.J., Faso A., Nishijima T.F., McGraw K.A., Galsky M.D. and Milowsky M.I. (2017). A systematic review of strategies to prevent cisplatin-induced nephrotoxicity. *Oncologist* 22, 609-619.
- Dahal A. and Mulukuri S. (2015). Flavonoids in kidney protection. *World J. Pharm. Pharmaceut. Sci.* 4, 362-382.
- de Oliveira Mora L., Antunes L.M.G., Francescato H.s.D.C. and Bianchi M.d.L.P. (2003). The effects of oral glutamine on cisplatin-induced nephrotoxicity in rats. *Pharmacol. Res.* 47, 517-522.
- Din Z.U., Iftikhar S., Rehman Z., Harris M., Ambreen S., Khattak M.S., Shahid M. and Rahimullah S.H. (2019a). Effect of 6-hydroxyflavone on cisplatin induced histopathological and biochemical changes in liver of sprague-dawley rats. *J. Khyber College of Dentistry* 9, 92-98.
- Din Z.U., Amir S., Haris M., Ismail N., Wazir N.U., Shahid M., Ullah R., Ahmad N., Farooq U. and Ullah I. (2019b). Attenuation of cisplatin associated testicular toxicity by 6-hydroxyflavone. *J. Khyber College of Dentistry* 9, 38-44.
- Diwan V., Brown L. and Gobe G.C. (2017). The flavonoid rutin improves kidney and heart structure and function in an adenine-induced rat model of chronic kidney disease. *J. Funct. Foods* 33, 85-93.
- El-Sheikh A.A., Morsy M.A., Mahmoud M.M., Rifaai R.A. and Abdelrahman A.M. (2012). Effect of coenzyme-q10 on doxorubicin-induced nephrotoxicity in rats. *Adv. Pharmacol. Sci.* 2012, 981461.
- Ellman G.L. (1959). Tissue sulfhydryl groups. *Arch. Biochem. Biophys.* 82, 70-77.
- Endo Y. and Kanbayashi H. (2003). Modified rice bran beneficial for weight loss of mice as a major and acute adverse effect of cisplatin. *Pharmacol. Toxicol.* 92, 300-303.
- Erlund I. (2004). Review of the flavonoids quercetin, hesperetin, and naringenin. Dietary sources, bioactivities, bioavailability, and epidemiology. *Nutr. Res.* 24, 851-874.
- Florea A.-M. and Büsselberg D. (2011). Cisplatin as an anti-tumor drug: Cellular mechanisms of activity, drug resistance and induced side effects. *Cancers (Basel)* 3, 1351-1371.
- Fouad A.A., Albuali W.H., Zahran A. and Gomaa W. (2014). Protective effect of naringenin against gentamicin-induced nephrotoxicity in rats. *Environ. Toxicol. Pharmacol.* 38, 420-429.
- Garcia J.M., Scherer T., Chen J.-a., Guillory B., Nassif A., Papusha V., Smiechowska J., Asnicar M., Buettner C. and Smith R.G. (2013). Inhibition of cisplatin-induced lipid catabolism and weight loss by ghrelin in male mice. *Endocrinology* 154, 3118-3129.
- Gentilin E., Simoni E., Candito M., Cazzador D. and Astolfi L. (2019). Cisplatin-induced ototoxicity: Updates on molecular targets. *Trends Mol. Med.* 25, 1123-1132.
- Ghayur M.N. and Janssen L.J. (2010). Nephroprotective drugs from traditionally used aboriginal medicinal plants. *Kidney Int.* 77, 471-472.
- Glezerman I.G. and Jaimes E.A. (2016). Chemotherapy and kidney injury. *American Society of Nephrology, Onco-Nephrology Curriculum* 1-10.
- Hamed M.A., Ali S.A. and Saba El-Rigal N. (2012). Therapeutic potential of ginger against renal injury induced by carbon tetrachloride in rats. *Sci. World J.* 2012, 1-12.
- He Q., Riley R.T. and Sharma R.P. (2002). Pharmacological antagonism of fumonisin b1 cytotoxicity in porcine renal epithelial cells (Ilc-pk1): A model for reducing fumonisin-induced nephrotoxicity *in vivo*. *Pharmacol. Toxicol.* 90, 268-277.
- Hermenean A., Ardelean A., Stan M., Herman H., Mihali C.-V., Costache M. and Dinischiotu A. (2013). Protective effects of naringenin on carbon tetrachloride-induced acute nephrotoxicity in mouse kidney. *Chem. Biol. Interact.* 205, 138-147.
- Hojman P., Fjelbye J., Zerahn B., Christensen J.F., Dethlefsen C., Lonkvist C.K., Brandt C., Gissel H., Pedersen B.K. and Gehl J. (2014). Voluntary exercise prevents cisplatin-induced muscle wasting during chemotherapy in mice. *PLoS One* 9, e109030.
- Khalid U., Pino-Chavez G., Nesargikar P., Jenkins R.H., Bowen T., Fraser D.J. and Chavez R. (2016). Kidney ischaemia reperfusion injury in the rat: The egti scoring system as a valid and reliable tool for histological assessment. *J. Histol. Histopathol.* 3, 1.
- Ko W.-C., Liu P.-Y., Chen J.-L., Leu I.-J. and Shih C.-M. (2003). Relaxant effects of flavonoids in isolated guinea pig trachea and their structure-activity relationships. *Planta Med.* 69, 1086-1090.
- Kodama A., To H., Kinoshita T., Ieiri I. and Higuchi S. (2009). Influence of dosing schedules on toxicity and antitumor effects of combined cisplatin and docetaxel treatment in mice. *J. Pharm. Pharmacol.* 61, 615-621.
- Levey A.S., Perrone R.D. and Madias N.E. (1988). Serum creatinine and renal function. *Annu. Rev. Med.* 39, 465-490.
- Lin X., Jia Y., Dong X., Shen J., Jin Y., Li Y., Wang F., Anenberg E., Zhou J. and Zhu J. (2019). Diplatin, a novel low toxicity and less

- resistance anti-lung cancer platinum complex activates cell death in tumors via a ros/Jnk/p53 dependent pathway. *Front. Pharmacol.* 10, 982.
- Lopez-Giacoman S. and Madero M. (2015). Biomarkers in chronic kidney disease, from kidney function to kidney damage. *World J. Nephrol.* 4, 573.
- Martinez F., Deray G., Dubois M., Beaufile H., Jacquiaud C., Bourbouze R., Benhmida M., Jaudon M.-C. and Jacobs C. (1993). Comparative nephrotoxicity of carboplatin and cisplatin in euvoletic and dehydrated rats. *Anticancer Drugs* 4, 85-90.
- Mashhadi M.A., Arab M.R., Azizi F. and Shahraki M.R. (2014). Histological study of toxic effects of cisplatin single dose injection on rat kidney. *Gene Cell and Tissue* 1, e21536.
- Misra H.P. and Fridovich I. (1972). The role of superoxide anion in the autoxidation of epinephrine and a simple assay for superoxide dismutase. *J. Biol. Chem.* 247, 3170-3175.
- Morales A., Vicente-Sanchez C., Sandoval J.S., Egado J., Mayoral P., Arevalo M., Fernandez-Tagarro M., Lopez-Novoa J. and Perez-Barriocanal F. (2006). Protective effect of quercetin on experimental chronic cadmium nephrotoxicity in rats is based on its antioxidant properties. *Food Chem. Toxicol.* 44, 2092-2100.
- Nasr A. (2013). Effect of misoprostol on ultrastructural changes of renal tissues in cisplatin-treated adult rats. *J. Cytol. Histol.* 4, 1-7.
- Nawaz N.U.A., Saeed M., Khan K.M., Ali I., Bhatti H.A., Sabi Ur R., Shahid M. and Faizi S. (2020). Isolation of tyrosine derived phenolics and their possible beneficial role in anti-inflammatory and antioxidant potential of *tithonia tubaeformis*. *Nat. Prod. Res.* (in press).
- Nijveldt R.J., Van Nood E., Van Hoorn D.E., Boelens P.G., Van Norren K. and Van Leeuwen P.A. (2001). Flavonoids: A review of probable mechanisms of action and potential applications. *Am. J. Clin. Nutr.* 74, 418-425.
- Ohkawa H., Ohishi N. and Yagi K. (1979). Assay for lipid peroxides in animal tissues by thiobarbituric acid reaction. *Anal. Biochem.* 95, 351-358.
- Ozkok A. and Edelstein C.L. (2014). Pathophysiology of cisplatin-induced acute kidney injury. *BioMed Res. Int.* 2014.
- Pabla N. and Dong Z. (2008). Cisplatin nephrotoxicity: Mechanisms and renoprotective strategies. *Kidney Int.* 73, 994-1007.
- Peesa J.P. (2013). Nephroprotective potential of herbal medicines: A review. *Asian J. Pharm. Technol.* 3, 115-118.
- Perazella M.A. (2012). Onco-nephrology: Renal toxicities of chemotherapeutic agents. *Clin. J. Am. Soc. Nephrol.* 7, 1713-1721.
- Pervez S., Saeed M., Khan H., Shahid M. and Ullah I. (2018). Nephroprotective effect of berberis baluchistanica against gentamicin induced nephrotoxicity in rabbits. *Bangladesh J. Pharmacol.* 13, 222-230.
- Pires Das Neves R.N., Carvalho F., Carvalho M., Fernandes E., Soares E., Bastos M.D.L. and Pereira M.D.L. (2004). Protective activity of hesperidin and lipoic acid against sodium arsenite acute toxicity in mice. *Toxicol. Pathol.* 32, 527-535.
- Prabhu V.V., Kannan N. and Guruvayoorappan C. (2013). 1,2-diazole prevents cisplatin-induced nephrotoxicity in experimental rats. *Pharmacol. Rep.* 65, 980-990.
- Prophet E., Mills B., Arrington J. and Sobin L. (1992). *Afip*, laboratory methods in histotechnology by armed forces institute of pathology. American Registry of Pathology, Washington, DC.
- Raziq N., Saeed M., Ali M.S., Zafar S., Shahid M. and Lateef M. (2016). A new glycosidic antioxidant from *ranunculus muricatus* l.(ranunculaceae) exhibited lipoxygenase and xanthine oxidase inhibition properties. *Nat. Prod. Res.* 11, 1251-1257.
- Renugadevi J. and Prabu S.M. (2009). Naringenin protects against cadmium-induced oxidative renal dysfunction in rats. *Toxicology* 256, 128-134.
- Rezzani R., Tengattini S., Bonomini F., Filippini F., Pechánová O., Bianchi R. and Andriantsitohaina R. (2009). Red wine polyphenols prevent cyclosporine-induced nephrotoxicity at the level of the intrinsic apoptotic pathway. *Physiol. Res.* 58, 511-519.
- Rodrigo R. and Bosco C. (2006). Oxidative stress and protective effects of polyphenols: Comparative studies in human and rodent kidney. *Comp. Biochem. Physiol. C Toxicol. Pharmacol.* 142, 317-327.
- Saad A.A., Youssef M.I. and El-Shennawy L.K. (2009). Cisplatin induced damage in kidney genomic DNA and nephrotoxicity in male rats: The protective effect of grape seed proanthocyanidin extract. *Food Chem. Toxicol.* 47, 1499-1506.
- Sahni V., Choudhury D. and Ahmed Z. (2009). Chemotherapy-associated renal dysfunction. *Nat. Rev. Nephrol.* 5, 450-462.
- Senturk H., Kabay S., Bayramoglu G., Ozden H., Yaylak F., Yucel M., Olgun E.G. and Kutlu A. (2008). Silymarin attenuates the renal ischemia/reperfusion injury-induced morphological changes in the rat kidney. *World J. Urol.* 26, 401-407.
- Shahid M. and Subhan F. (2014a). Comparative histopathology of acetaminophen induced hepatotoxicity in animal models of mice and rats. *Pharmacologyonline* 3, 32-43.
- Shahid M. and Subhan F. (2014b). Protective effect of bacopa monniera methanol extract against carbon tetrachloride induced hepatotoxicity and nephrotoxicity. *Pharmacologyonline* 2, 18-28.
- Shahid M., Subhan F., Ahmad N. and Ullah I. (2017a). A bacosides containing bacopa monnieri extract alleviates allodynia and hyperalgesia in the chronic constriction injury model of neuropathic pain in rats. *BMC Complement. Altern. Med.* 17, 293.
- Shahid M., Subhan F., Ahmad N. and Sewell R.D.E. (2017b). The flavonoid 6-methoxyflavone allays cisplatin-induced neuropathic allodynia and hypoalgesia. *Biomed. Pharmacother.* 95, 1725-1733.
- Shahid M., Subhan F., Ahmad N. and Sewell R.D.E. (2019a). Efficacy of a topical gabapentin gel in a cisplatin paradigm of chemotherapy-induced peripheral neuropathy. *BMC Pharmacol. Toxicol.* 20, 51.
- Shahid M., Subhan F., Ullah I., Ali G., Alam J. and Shah R. (2016). Beneficial effects of bacopa monnieri extract on opioid induced toxicity. *Heliyon* 2, e00068.
- Shahid M., Subhan F., Ali G., Ullah I., Alam J., Ullah S. and Rauf K. (2017c). Neuroprotective effect of bacopa monnieri against morphine-induced histopathological changes in the cerebellum of rats. *Pak. J. Pharm. Sci.* 30, 2067-2074.
- Shahid M., Subhan F., Islam N.U., Ullah I., Alam J., Ahmad N. and Ali G. (2019b). Phytochemical, pharmacological and therapeutic profile of bacopa monnieri: A prospective complementary medicine. In: *Natural medicines: Clinical efficacy, safety and quality*. CRC Press, Taylor & Francis Group, Florida, USA. pp 447-476.
- Shimoi K., Shen B., Toyokuni S., Mochizuki R., Furugori M. and Kinai N. (1997). Protection by ag-rutin, a water-soluble antioxidant flavonoid, against renal damage in mice treated with ferric nitrilotriacetate. *Cancer Sci.* 88, 453-460.
- Siddiqi A., Nafees S., Rashid S., Sultana S. and Saidullah B. (2015). Hesperidin ameliorates trichloroethylene-induced nephrotoxicity by abrogation of oxidative stress and apoptosis in wistar rats. *Mol. Cell. Biochem.* 406, 9-20.
- Sueishi K., Mishima K., Makino K., Itoh Y., Tsuruya K., Hirakata H. and

Cisplatin-nephrotoxicity and 6-hydroxyflavone

- Oishi R. (2002). Protection by a radical scavenger edaravone against cisplatin-induced nephrotoxicity in rats. *Eur. J. Pharmacol.* 451, 203-208.
- Uehara T., Yamate J., Torii M. and Maruyama T. (2011). Comparative nephrotoxicity of cisplatin and nedaplatin: Mechanisms and histopathological characteristics. *J. Toxicol. Pathol.* 24, 87-94.
- Ullah I., Subhan F., Alam J., Shahid M. and Ayaz M. (2018). Suppression of cisplatin-induced vomiting by cannabis sativa in pigeons: Neurochemical evidences. *Front. Pharmacol.* 9, 231.
- Ullah I., Subhan F., Rudd J.A., Rauf K., Alam J., Shahid M. and Sewell R. (2014). Attenuation of cisplatin-induced emetogenesis by standardized bacopa monnieri extracts in the pigeon: Behavioral and neurochemical correlations. *Planta Med.* 80, 1569-1579.
- Vargas F., Duran R., Alejandra P., García-Guillén A.I., Wangenstein R., Tendero P., Atucha N.M. and García-Estañ J. (2018). Flavonoids in kidney health and disease. *Front. Physiol.* 9, 394.
- Vitorino J. and Sottomayor M. (2010). DNA interaction with flavone and hydroxyflavones. *J. Mol. Struct.* 975, 292-297.
- Wang X., Wang Z., Sidhu P.S., Desai U.R. and Zhou Q. (2015). 6-hydroxyflavone and derivatives exhibit potent anti-inflammatory activity among mono-, di- and polyhydroxylated flavones in kidney mesangial cells. *PLoS One* 10, e0116409.
- Yao X., Panichpisal K., Kurtzman N. and Nugent K. (2007). Cisplatin nephrotoxicity: A review. *Am. J. Med. Sci.* 334, 115-124.
- Zeng X., Xi Y. and Jiang W. (2018). Protective roles of flavonoids and flavonoid-rich plant extracts against urolithiasis: A review. *Crit. Rev. Food Sci. Nutr.* 1-44.
- Zhang Y.T., Zheng Q.S., Pan J. and Zheng R.L. (2004). Oxidative damage of biomolecules in mouse liver induced by morphine and protected by antioxidants. *Basic Clin. Pharmacol. Toxicol.* 95, 53-58.
- Zhong Y., Deng Y., Chen Y., Chuang P.Y. and He J.C. (2013). Therapeutic use of traditional chinese herbal medications for chronic kidney diseases. *Kidney Int.* 84, 1108-1118.

Accepted September 10, 2020