

Aliskiren improves renal morphophysiology and inflammation in Wistar rats with 2K1C renovascular hypertension

Priscila G. Pereira¹, Kíssila Rabelo¹, Jemima F. R. da Silva¹, Bianca T. Ciambarella¹, Juliana G.C. Argento¹, Ana L.R. Nascimento¹, Aline B. Vieira² and Jorge J. de Carvalho¹

¹Laboratory of Ultrastructure and Tecdial Biology, Institute of Biology, State University of Rio de Janeiro, RJ, Brazil and ²Ross University School of Veterinary Medicine, Biomedical Department, Basseterre, Saint Kitts

Summary. Hypertension is characterized by persistent elevated blood pressure levels, one of the leading causes of death in the world. Renovascular hypertension represents the most common cause of secondary hypertension, and its progress is associated with overactivation of the renin angiotensin aldosterone system (RAAS), causing systemic and local changes. Aliskiren is a renin-inhibiting drug that optimizes RAAS suppression. In this sense, the objective of the present study was to analyze the morphophysiology of the left kidney in Wistar rats with renovascular hypertension after treatment with Aliskiren. Parameters such as systolic blood pressure, urinary creatinine and protein excretion, renal cortex structure and ultrastructure, fibrosis and tissue inflammation were analyzed. Our results showed that the hypertensive animals treated with Aliskiren presented a reestablishment of blood pressure, expression of renin, and renal function, as well as a remodeling of morphological alterations through the reduction of fibrosis. The treatment regulated the laminin expression and decreased pro-inflammatory cytokines, restoring the integrity of the glomerular filtration barrier. Therefore, our findings suggest that Aliskiren has a renoprotective effect acting on the

improvement of the morphology, physiology and pathology of the renal cortex of animals with renovascular hypertension.

Keywords: Renovascular hypertension, Aliskiren, Wistar, Inflammation, Renal histopathology

Introduction

Systemic arterial hypertension is a multifactorial clinical condition characterized by persistent elevated blood pressure levels. The death rate caused by hypertension increased 13.2% within a period of ten years in over 190 countries (Sociedade Brasileira de Cardiologia, 2010). Secondary hypertension is characterized by the existence of an unknown triggering factor, in which renovascular disease is one of the most common causes of secondary hypertension (Pullalarevu et al., 2014). Renovascular hypertension (RH) is described as a partial reduction of renal perfusion pressure, caused by a stenotic or obstructive lesion of one or both renal arteries, leading to an increase in the activity of the renin angiotensin aldosterone system (RAAS) (Ledingham, 1971).

The most used experimental model for the study of the pathogenesis of RH is the prototype of Goldblatt, with the reduction of the renal blood supply. In this model, called 2 Kidney - 1 Clip (2K1C), HR is induced by unilateral partial occlusion, by implantation of a silver clip in the renal artery, causing a reduction in renal blood by approximately 50% and promoting a necessary

Offprint requests to: Jorge José de Carvalho, PhD., Laboratório de Ultraestrutura e Biologia Tecidual, Departamento de Histologia e Embriologia. Universidade do Estado do Rio de Janeiro, Instituto de Biologia Roberto Alcântara Gomes. Boulevard Vinte e Oito de Setembro - 87 fundos - 3º andar Vila Isabel. CEP: 20551-030 - Rio de Janeiro, RJ - Brasil. e-mail: jjcarv@gmail.com

DOI: 10.14670/HH-18-173

condition to develop hypertension. Due to the anatomy of the renal arteries, the kidney of choice is usually the left one (Goldblatt et al., 1934; Lupu et al., 1972).

The reduction of renal perfusion caused by artery stenosis results in an increased release of renin by juxtaglomerular cells in the afferent arteriole. This intensification in renin levels leads to the activation of RAAS and a gradual increase in systemic blood pressure, circulating angiotensin II (Ang II) and aldosterone levels, causing renal damage (Minuz et al., 2002). High levels of Ang II cause systemic changes such as increased blood volume, systemic vasoconstriction, activation of the sympathetic nervous system, retention of sodium and water, and local alterations such as oxidative stress, macrophage infiltration, release of pro-inflammatory cytokines, inflammation, dysfunction, and fibrosis in the kidney (Stouffer et al., 2010; Matavelli et al., 2011; Oliveira-Sales et al., 2014). Some studies have associated increased levels of Ang II to increased transcription and synthesis of proinflammatory cytokines such as tumor necrosis factor alpha (TNF- α) and interleukin 6 (IL-6) (Han et al., 1999; Kranzhöfer et al., 1999; Skurk et al., 2004). In patients with hypertension, a higher level of TNF- α and IL-6 has already been demonstrated than in normotensive individuals, suggesting that these cytokines may play a role in the development of hypertension through cellular immune dysfunction and inflammatory reaction (Chae et al., 2001; Bautista et al., 2005; Sardo et al., 2009). In another study, rats with renovascular hypertension two-kidney one-clip (2K1C), showed greater expression of TNF- α and IL-6 in the plasma through activation of vasoconstrictors, decreased endothelium-dependent vasodilation function (Van Hinsbergh et al., 1988; Marsden and Brenner, 1992; Conrad and Benyo, 1997), and proliferation of fibroblasts (Ikeda et al., 1991).

In addition, elevated systemic levels of inflammatory markers are associated with augmented risk of developing chronic kidney disease (CKD) in humans (Shankar et al., 2011). CKD is usually associated with advanced age, diabetes, hypertension, obesity and cardiovascular diseases (Levey et al., 2003). It is characterized by structural damage, which can progressively induce uremia, and renal failure (Polzin et al., 2000). Renal damage refers to histopathological abnormalities observed by biopsy or imaging, changes in urine sedimentation, proteinuria, or plasma and / or urinary creatinine concentrations (Lamb et al., 2013). In patients with CKD, the goal of treatment of hypertension includes not only cardiovascular protection, reduction of blood pressure, but also retardation of the progression of renal disease (Ravera et al., 2006; Sarafidis and Bakris, 2008).

Aliskiren is an oral drug, which inhibits renin by binding to its active site. This drug directly inhibits plasma renin activity, the initial and limiting step in RAAS, which results in a complete inhibition of RAAS leading to the decline of Ang II levels (Friedrich and

Schmieder, 2013; Lizakowski et al., 2013). Several clinical studies have shown that Aliskiren is effective in lowering blood pressure in patients with mild to moderate hypertension (Chen et al., 2013; Robles et al., 2014), and prevents and / or improves insulin resistance, aortic endothelial dysfunction and vascular remodeling in hypertensive rats fed with fructose (Chou et al., 2013). The optimization of RAAS suppression is difficult to obtain with ACE inhibitors and Ang II receptor blockers. It occurs because these two classes of antihypertensives activate compensatory mechanisms that result in the release of renin and increased plasma renin activity. In contrast, Aliskiren neutralizes any compensatory increase in plasma renin and prevents the formation of both Ang I and Ang II (Imanishi et al., 2008).

Aliskiren administration has been reported to have beneficial effects on target organ damage, preventing or treating not only diseases of the cardiovascular system but also the renal system (Fogari and Zoppi, 2010; Van Esch et al., 2010). Aliskiren has been shown to be a renoprotective agent for CKD, pointing to efficacy in reducing albuminuria, proteinuria, plasma renin activity and Ang II (Fisher et al., 2008; Persson et al., 2008; Lizakowski et al., 2013), as well as suppression of the production of collagens type III and IV and transforming growth factor beta (TGF- β) (Feldman et al., 2008).

Based on the above considerations, here we investigated the morphophysiological effects of treatment with Aliskiren in the left kidney of rats with renovascular hypertension 2K1C. Therefore, we evaluated the kidney histopathology, biochemical parameters and renin expression, since it is essential for the understanding of renal function. Fibrosis, laminin expression and ultrastructural analysis were also investigated. Finally, the productions of pro-inflammatory cytokines were assessed to elucidate the Aliskiren effects to restore the integrity of the glomerular filtration barrier.

Materials and methods

Animals

All experimental procedures involving animals were approved by the Committee for Ethics in Animal Experimentation of the State University of Rio de Janeiro (n° 019/2017). Forty male Wistar rats were housed in cages with free access to standard commercial feed (Nuvilab, Curitiba, Paraná, Brasil) and water, maintained in temperature controlled environment (21 \pm 2°C) and controlled undergoing reversed light cycle (12-light/dark), in accordance with the Committee's guidelines.

Induction of renovascular hypertension and experimental groups

For the experiments, 45-day-old Wistar rats were anesthetized with intraperitoneal injection of

Aliskiren induces renoprotection in 2K1C rats

pentobarbital sodium (40 mg/kg) and the left renal artery was partially obstructed with a 0.2 mm silver clip according to experimental model 2 Kidneys-1 Clip (2K-1C) developed by Goldblatt et al. (1934). Control animals were submitted to the same surgical procedure, with manipulation of the left renal artery, but the clip was not implanted. Four weeks following the surgical procedure were considered as induction of hypertension. Animals were divided in four groups (n=10): Sham, Sham treated with Aliskiren (Sham+A), 2K1C and 2K1C treated with Aliskiren (2K1C+A). The Aliskiren was administered daily via orogastric gavage in the Sham+A and 2K1C+A groups at a dose of 10 mg/ Kg for four weeks. Sham and 2K1C groups received water by oral gavage to be also handled. The systolic blood pressure (SBP) was measured weekly using the noninvasive method of plethysmography of the caudal artery (Letica LE 5100, Panlab, Barcelona, Spain) in all experimental groups with conscious animals. The mean of three measurements of each animal was used. Before the experimental period, the SBP was measured in rats with the objective of acclimatizing them and attenuating possible future changes in pressure due to stress.

On the day of euthanasia, eight weeks after the surgical procedure, the rats were anesthetized with intraperitoneal injection of pentobarbital sodium (40 mg/kg) and the blood was removed by cardiac puncture. Then, the left kidneys were collected and fixed in 4% paraformaldehyde for optical analysis or 2,5% glutaldehyde for electron microscopy analysis.

Assessment of renal function

One day before euthanasia, the animals were placed in metabolic cages for 24 h urine collection. Urinary creatinine and protein concentrations were determined accordingly with the manufacturer. All commercial kits used were purchased from Bioclin (Bioclin, Belo Horizonte, Minas Gerais, Brazil).

Morphological analysis

Kidneys fixed with 4% paraformaldehyde were embedded in paraffin and sectioned (5 μ m thickness). The slices were stained with Hematoxylin-Eosin (HE) for histopathological analysis or with Picro Sirius Red (PS) for fibrosis detection and then observed under a light microscope equipped with a CCD camera (Olympus BX53 with camera Olympus DP72, Nagano, Chubu, Japan). Twenty random fields were obtained from each slide. The Image-Pro Plus 7.0 program (Media Cybernetics, Silver Springs, Maryland, EUA) was used to quantify the fibrotic areas with a magnification of 20x.

Immunohistochemistry

Antigen retrieval was performed by citrate buffer at pH 6.0 incubation for 30 min at 60°C. Endogenous

peroxidase activity was blocked using 0.3% hydrogen peroxide (H₂O₂) and non-specific binding of the polyclonal antibodies was blocked by incubation 5% (w/v) BSA. Subsequently, sections were incubated with antibodies, and these reactions were amplified using a biotin-streptavidin system (Dako, Santa Clara, California, USA). Immunoreactive products were visualized using diaminobenzidine (DAB) reagent (Dako) and counter stained with hematoxylin. Control sections were obtained by primary antibody omission. We used anti-TNF- α , anti-TGF- β , anti-renin, anti-laminin, anti-IL-6, and anti-interleucin 10 (IL-10) (dilution 1:100, Santa Cruz Biotechnology, Dallas, Texas, EUA) antibodies. Then, twenty random fields were obtained from each slide and observed under a light microscope. The expression of all markings was quantified using the Image-Pro Plus 7.0 program at a magnification of $\times 20$.

Electron microscopic study

Kidneys were collected, cut into small tissue blocks (1 mm³), and fixed in 2.5% glutaldehyde at 4°C. After postfixation with 2% osmium tetroxide, tissues were dehydrated in increasing series of acetone, and embedded in epoxy resin. Ultrathin sections were double-stained with uranyl acetate and lead. Sections were examined with a JEM1200EX electron microscopy (JEOL, São Paulo, São Paulo, Brasil) at 80 kV.

Statistical analysis

Data were analyzed with GraphPad prism software v 6.0 (San Diego, California, USA) using analysis of one-way ANOVA with Holm-Sidak post-test, except the SBP data, which were analyzed by two-way with Holm-Sidak post-test. The differences between groups were considered statistically significant when values of $p < 0.05$.

Results

Assessment of systolic blood pressure and renin expression

The rats SBP was measured weekly throughout the experiment (week 0 to week 8). One day prior to performing the surgical procedure, the SBP was measured (week 0). The weeks 1 to 4 refer to the induction period of hypertension and weeks 5 to 8 to the period of Aliskiren treatment. The SBP of the Sham and Sham + A groups remained constant throughout the experiment (Sham: 117.3 \pm 5 mmHg, Sham + A: 120.6 \pm 5 mmHg) and did not show significant differences between them. On the other hand, SBP of the animals of the 2K1C group increased gradually from week 1 to week 8 (from 136.8 \pm 5 mmHg to 205.5 \pm 4 mmHg). In the first four weeks, animals in the 2K1C + A group presented a gradual increase in SBP levels (from

Aliskiren induces renoprotection in 2K1C rats

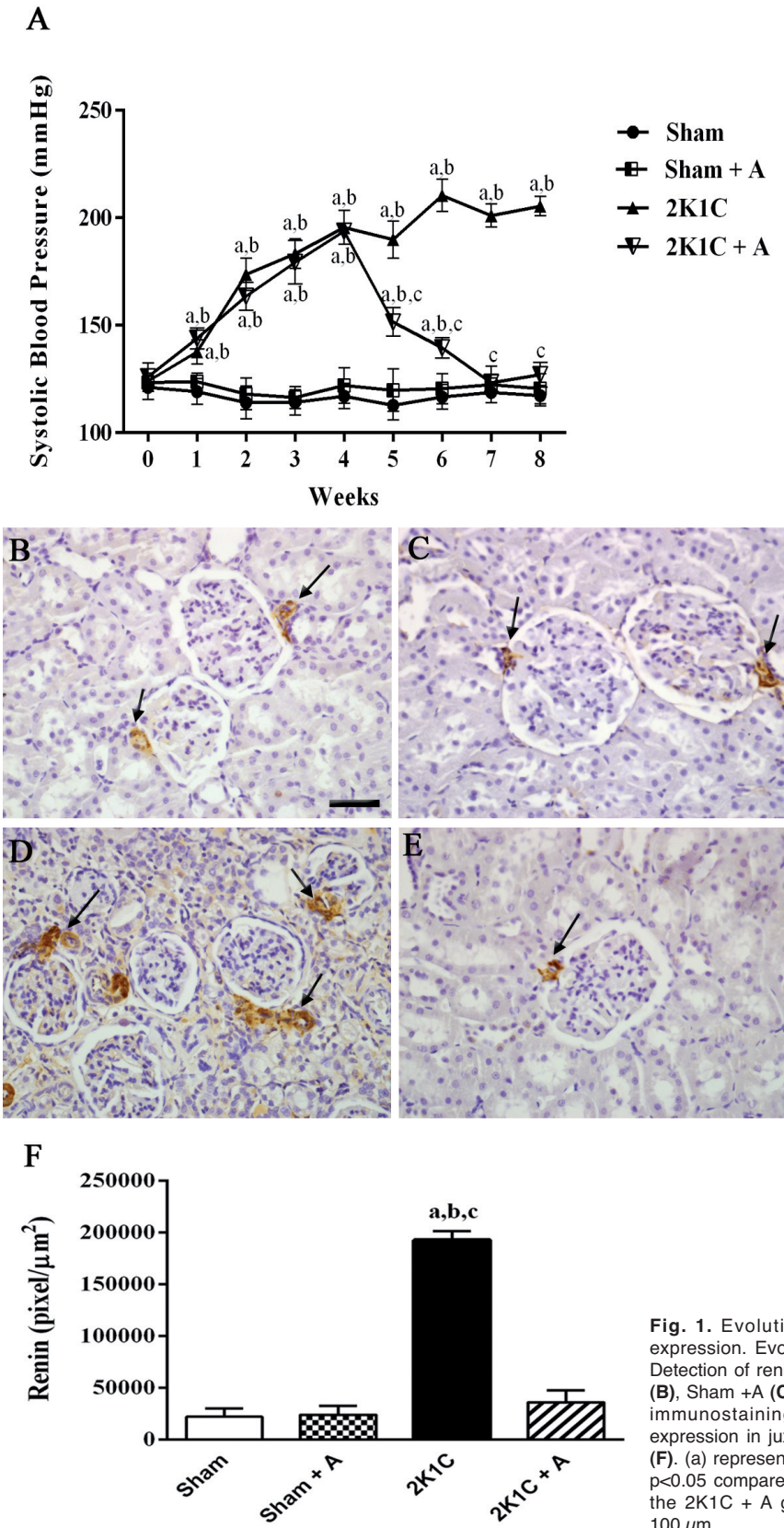


Fig. 1. Evolution of blood pressure and quantification of renin expression. Evolution of SBP in millimeters of mercury (mmHg) (**A**). Detection of renin expression by immunohistochemistry in Sham group (**B**), Sham +A (**C**), 2K1C (**D**) and 2K1C +A (**E**). Arrows indicate positive immunostaining in juxtaglomerular cells. Quantification of renin expression in juxtaglomerular cells of hypertensive and control groups (**F**). (a) represents $p < 0.05$ compared to the Sham group, (b) represents $p < 0.05$ compared to the Sham + A group and (c) $p < 0.05$ compared to the 2K1C + A group. $n = 10$ for all experimental groups. Scale bar: 100 μm .

Aliskiren induces renoprotection in 2K1C rats

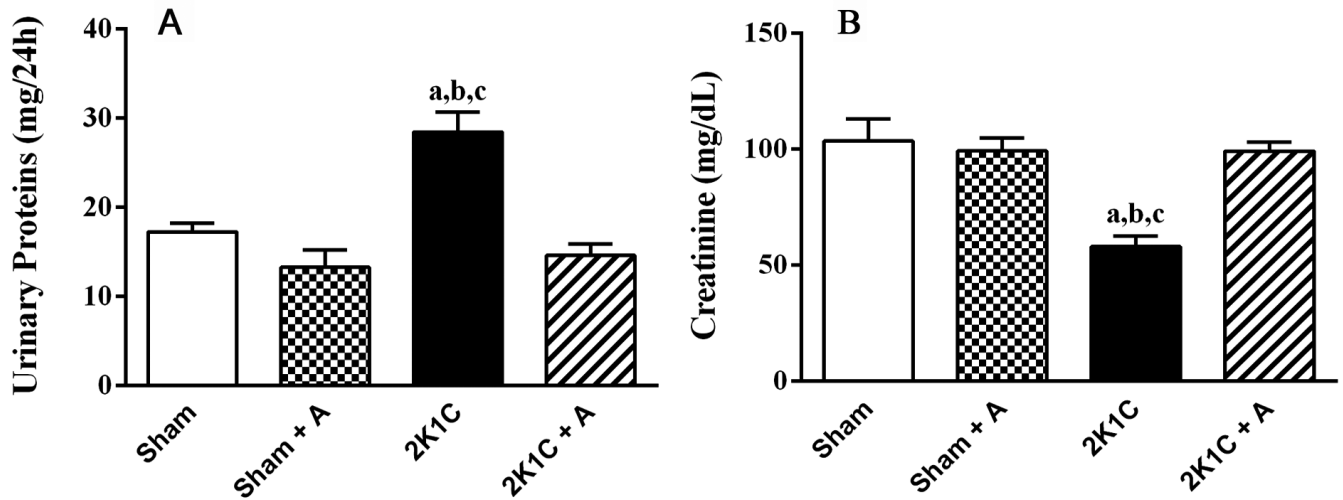


Fig. 2. Biochemical parameters in urine. Urinary protein levels (**A**) (mg/24h) and creatinine levels (**B**) (mg/dL). (a) $p < 0.05$ compared to the Sham group, (b) $p < 0.05$ compared to the Sham + A group and (c) $p < 0.05$ compared to the 2K1C + A group. $n = 7$ for all experimental groups.

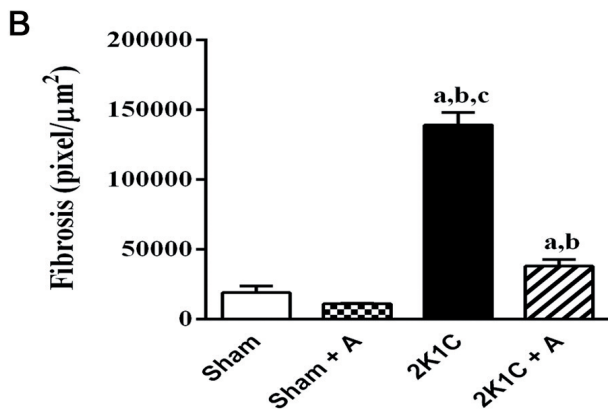
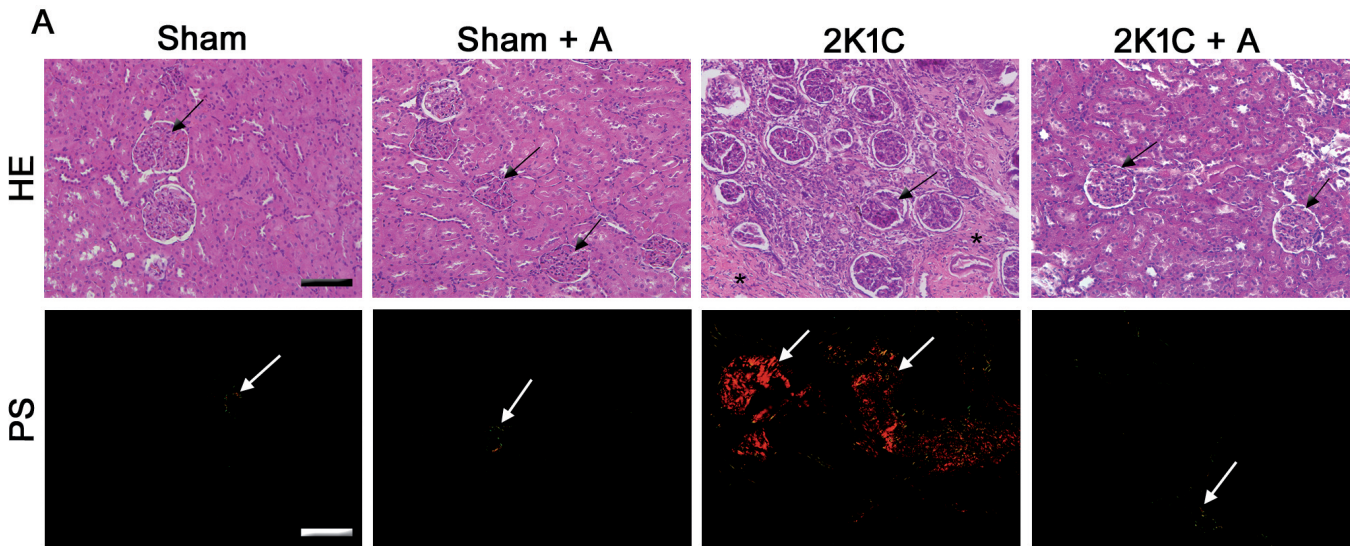


Fig. 3. Renal histopathology and quantification of the areas of fibrosis. **A.** Coloration in Hematoxylin-Eosin (HE) and Picro Sirius Red (PS) in all groups. **B.** Quantification of the fibrotic area. In HE, the arrows indicate the glomeruli and the asterisks indicate areas of interstitial fibrosis. In PS, the arrows indicate areas of deposition of collagen fibers. (a) represents $p < 0.05$ compared to the Sham group, (b) represents $p < 0.05$ compared to the Sham + A group and (c) $p < 0.05$ compared to the 2K1C + A group. $n = 10$ for all experimental groups. Scale bar: 100 μm (HE) and 50 μm (PS).

142.6±3 mmHg to 193.2±2 mmHg). At week 5, when the Aliskiren administration was started, the animals in the 2K1C + A group presented a reduction in SBP (from 193.2±2 mmHg to 150.4±5 mmHg) and in week 7, the SBP levels of these animals were similar to the SBP levels of the Sham and Sham + A (123.2±3 mmHg) animals (Fig. 1A).

In an immunohistochemical study, positive anti-renin antibody immunostaining was observed in the juxtaglomerular cells of the renal cortex in all experimental groups (Fig. 1B-E). The 2K1C group (Fig. 1D) showed more positive areas, both in the juxtaglomerular cells and in the tubular region, compared to the Sham (Fig. 1B) and Sham + A (Fig. 1C) groups. On the other hand, a decrease in the positive areas was observed in the 2K1C group treated with Aliskiren (Fig. 1E) compared to the 2K1C group. By quantifying the anti-renin antibody, a significant increase in the number of cells marked in the 2K1C group was observed in relation to the other groups, as shown in Fig. 1F.

Assessment of renal function

Urinary levels of creatinine and total proteins were evaluated in the animals of the four experimental groups (Fig. 2). Urinary protein levels showed a significant increase in the 2K1C group compared to the Sham, Sham + A and 2K1C + A groups (Fig. 2A). The results regarding urinary creatinine levels showed a significant decrease in their excretion in the 2K1C group when compared to the other groups (Fig. 2B).

Histopathological evaluation and quantification of areas of fibrosis

Histopathological changes were analyzed by HE staining. The groups Sham and Sham + A presented Bowman's capsule, glomeruli and proximal and distal convoluted tubules preserved. However, the 2K1C group presented a large area of interstitial fibrosis in the renal cortex and loss of structure of the corpuscles and renal tubules. In addition, the animals of the 2K1C group presented glomeruli lesion. The 2K1C + A group showed a decrease in interstitial fibrosis and a restructuring of the renal cortex when compared to the 2K1C group, mainly of the corpuscles and proximal and distal convoluted tubules (Fig. 3A).

The deposition of collagen fibers was analyzed by Picro Sirius Red staining (Fig. 3A) and after, quantified (Fig. 3B). The 2K1C group showed an increase in perivascular, peritubular and pericapsular collagen expression compared to the Sham and Sham + A groups, indicating fibrosis in the 2K1C group. In the 2K1C + A group a lower collagen deposition was observed, compared to the 2K1C group. The amount of collagen in the treated 2K1C group was very close to the results found in the animals of the Sham group.

Evaluation of laminin expression and renal ultrastructure

In the evaluation of the anti-laminin antibody immunostaining, the 2K1C group (Fig. 4C) presented more areas with intense labeling in both the glomerular and tubular region compared to Sham (Fig. 4A) and

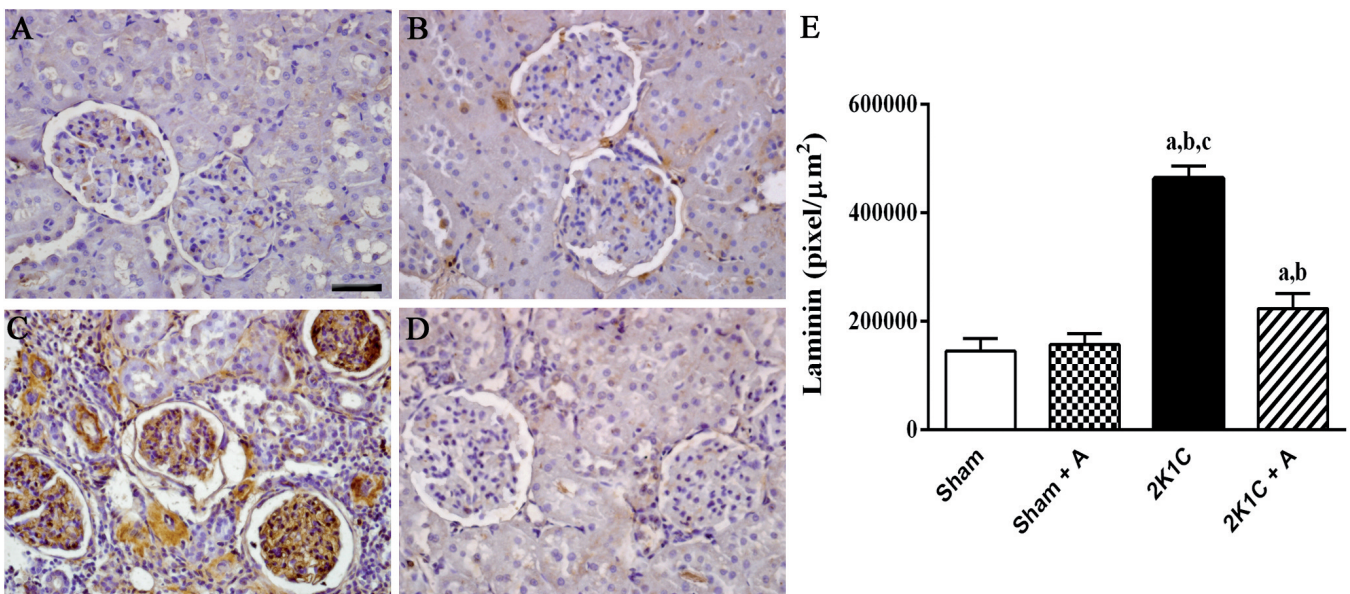


Fig. 4. Detection of laminin by immunostaining and quantification in the renal cortex. Photomicrographs of groups Sham (A); Sham + A (B); 2K1C (C); 2K1C + A (D). (a) represents $p < 0.05$ compared to the Sham group, (b) represents $p < 0.05$ compared to the Sham + A group and (c) $p < 0.05$ compared to the 2K1C + A group. $n = 10$ for all experimental groups. Scale bar: 100 μm .

Aliskiren induces renoprotection in 2K1C rats

Sham + A (Fig. 4 B), which had few labeled cells. In the 2K1C group treated with Aliskiren (Fig. 4 D), a decrease of this marking was observed compared to the 2K1C, and similar to the Sham group. By quantifying the laminin expression, a significant increase in the number of labeled cells in the 2K1C group was observed in relation to the other groups, as shown in

Fig. 4E.

In the analysis of the renal ultrastructure (Fig. 5), the animals of the 2K1C group presented a retraction of the pedicels (arrowhead), morphological alteration of the filtration slit (arrows) and thickening of the glomerular basement membrane (GBM) (asterisks) (Fig. 5C) when compared to the Sham (Fig. 5A) and Sham + A groups

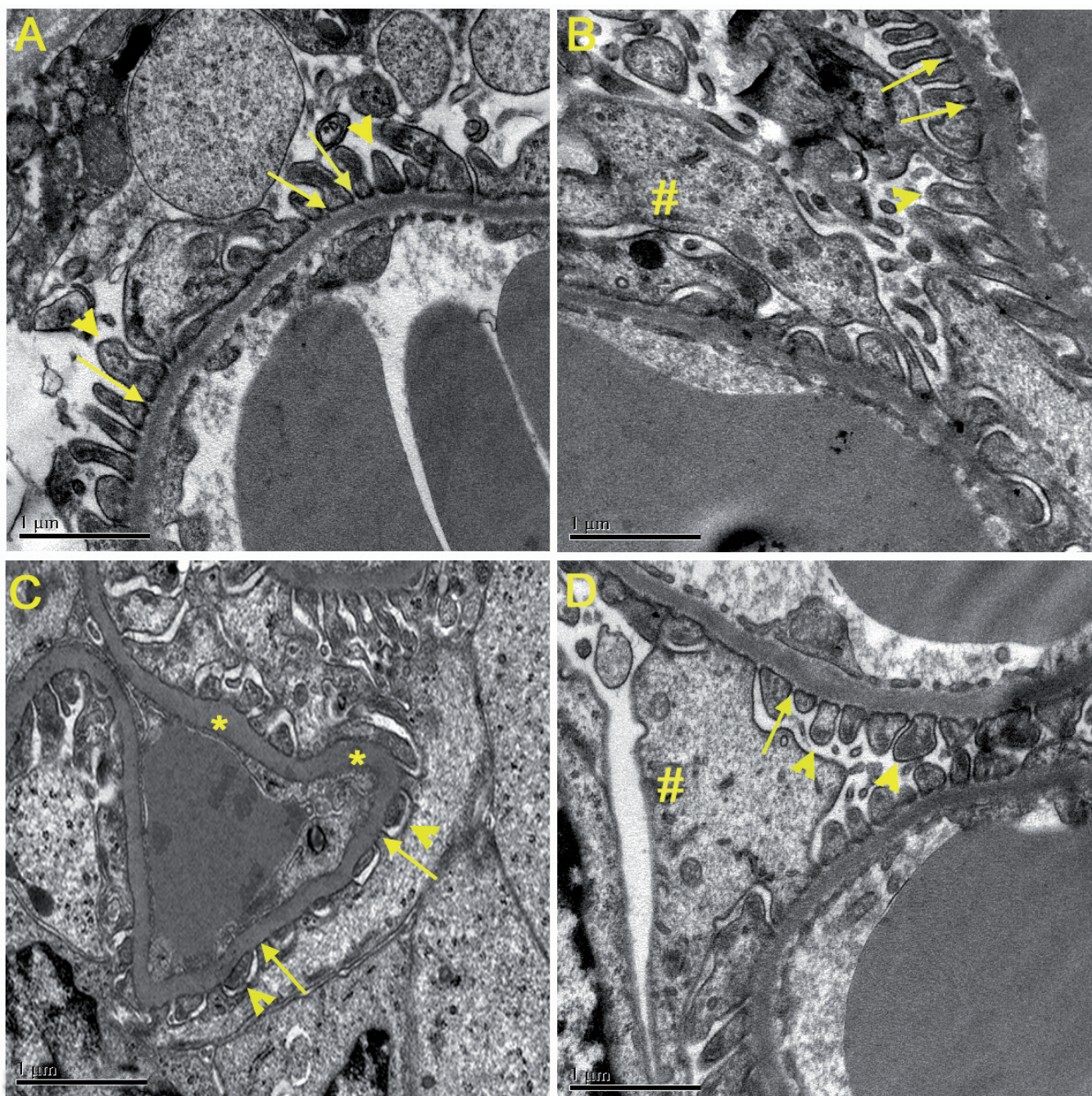


Fig. 5. Analysis of renal ultrastructure. **A.** Sham group. **B.** Sham + A group. **C.** 2K1C group. **D.** 2K1C + A group. The filtration slit (arrows), the pedicels (arrowheads), the glomerular basement membrane (*) and the podocyte cell body (#) are indicated. Scale bars: 1 µm.

(Fig. 5B). In these, the integrity of the pedicels and the diaphragm of the filtration cleft, as well as of the BMG and the fenestrated capillary were evidenced. In the Aliskiren-treated 2K1C group, a recovery of the basement membrane structure and pedicle morphology was observed (Fig. 5D).

Renal inflammatory response evaluation by immunohistochemistry

In the specific immunostaining for TNF- α and IL-6 (Fig. 6A), the Sham and Sham + A groups showed a minor expression of these cytokines. In contrast, the 2K1C group showed diffuse areas of intense labeling of both TNF- α and IL-6 in the proximal and distal tubules. However, these markers were less frequent in the Aliskiren-treated 2K1C group. The quantification of TNF- α and IL-6 is shown in Fig. 6A,B, respectively,

and corroborates the findings described above, with a significant increase in levels of TNF- α and IL-6 in the hypertensive group compared to the other groups.

The detection of IL-10 and TGF- β were also performed by immunohistochemistry (Fig. 7A). Both Sham and Sham + A groups showed little intensity in the specific labeling for IL-10 and TGF- β . In IL-10 specific immunostaining, it was observed that the 2K1C + A group showed an increase in the expression of this cytokine compared to the 2K1C group. In the 2K1C group, TGF- β intense labeling was observed both in the proximal and distal tubules, as well as in the glomeruli. However, this marking was less frequent in the Aliskiren-treated 2K1C group. By quantifying immunostaining with anti-IL-10 (Fig. 7B) and anti-TGF- β antibodies (Fig. 7C), a significant decrease in IL-10 and increase in TGF- β expression was observed in the 2K1C group in relation to the other groups.

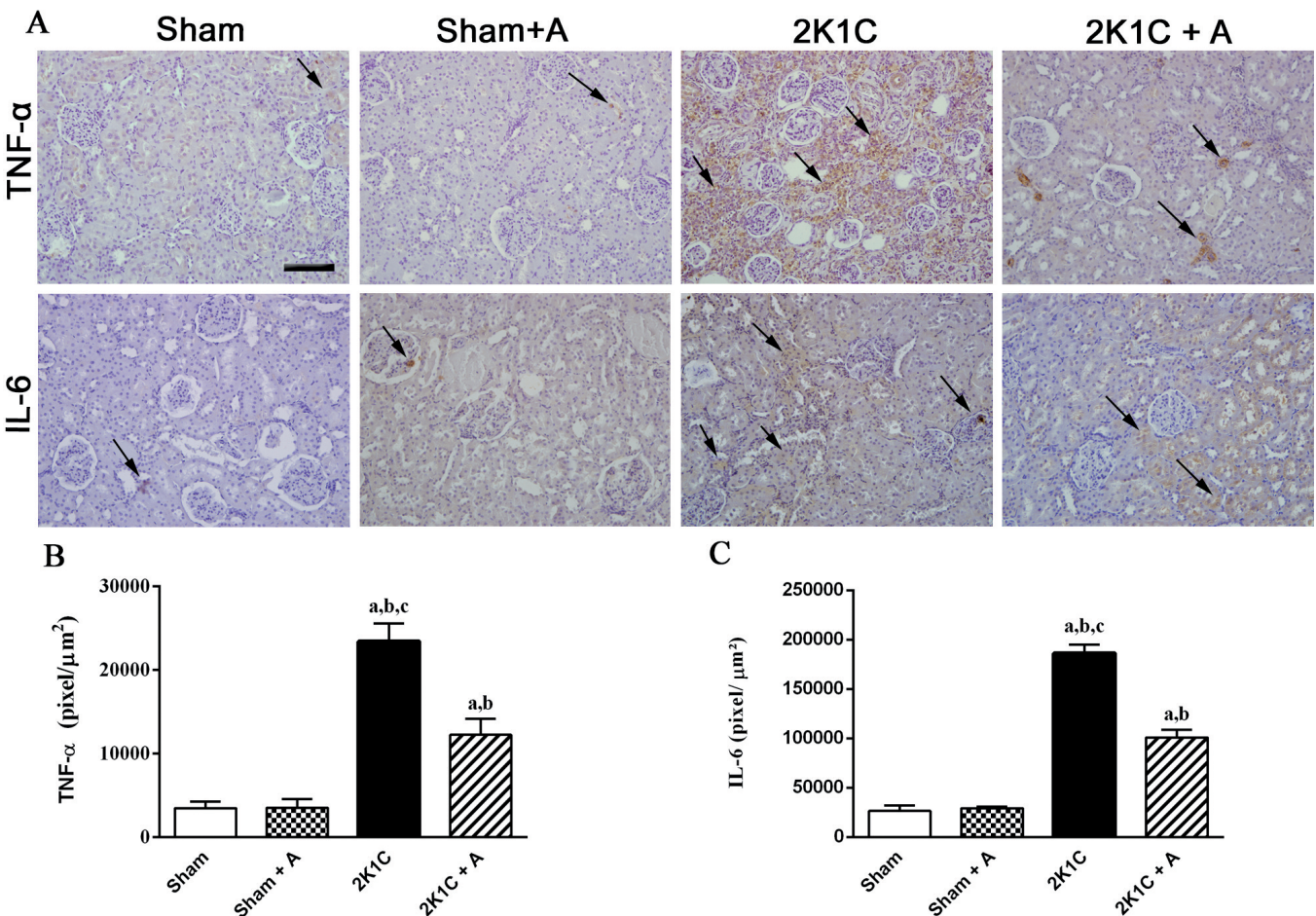


Fig. 6. Immunostaining and quantification of anti-TNF- α and anti-IL-6 antibodies in the renal cortex of the experimental groups. **A.** Photomicrographs of all experimental groups are presented. **B, C.** Quantification of TNF- α and IL-6 are shown, respectively. (a) $p < 0.05$ compared to the Sham group, (b) $p < 0.05$ compared to the Sham + A group and (c) $p < 0.05$ compared to the 2K1C + A group. $n = 10$ for all experimental groups. The arrows indicate positive immunostaining. Scale bar: 100 μm .

Discussion

The 2K1C renovascular hypertension model, developed by Goldblatt in 1934, is widely used for the experimental study of hypertension pathophysiology and antihypertensive drugs (Amat et al., 2014). This model is associated with a reduction of blood flow that, consequently, stimulates a renin secretion leading to an overactivation of RAAS and increased blood pressure. In addition, chronic renal hypoperfusion causes clipped renal atrophy, inflammation, interstitial fibrosis, and tubular damage (Oliveira-Sales and Boim, 2016). In the present study, we observed that left renal artery stenosis caused elevated systolic blood pressure, loss of renal function, severe fibrosis with tubular and glomerular basement membrane alterations, in addition to increased renin, laminin and proinflammatory cytokines expression.

Excessive activation of RAAS has been implicated in the progression of the entire evolution of

cardiovascular and renal diseases from the early stages, such as hypertension, to the later stages, such as microalbuminuria and renal failure. Therefore, the overactivation of RAAS culminating in excess production of Ang II is largely responsible for the establishment and development of hypertension and renal injury (Escobar et al., 2012). For this reason, the RAAS becomes a good target for antihypertensive therapies and, consequently, for the treatment of renal disease. Therefore, the use of ACE inhibitors, angiotensin receptor blockers and, in recent years, Aliskiren, a renin inhibitor, are drugs of choice in the clinical treatment of renovascular hypertension (Riccioni et al., 2009; Riccioni, 2011).

The development of systemic hypertension in 2K1C animals is associated with increased renin secretion by renal juxtaglomerular cells. It is known that 2K1C renovascular hypertension is dependent on Ang II with hypersecretion of renin, leading to the development of systemic arterial hypertension (Kashyap et al., 2016).

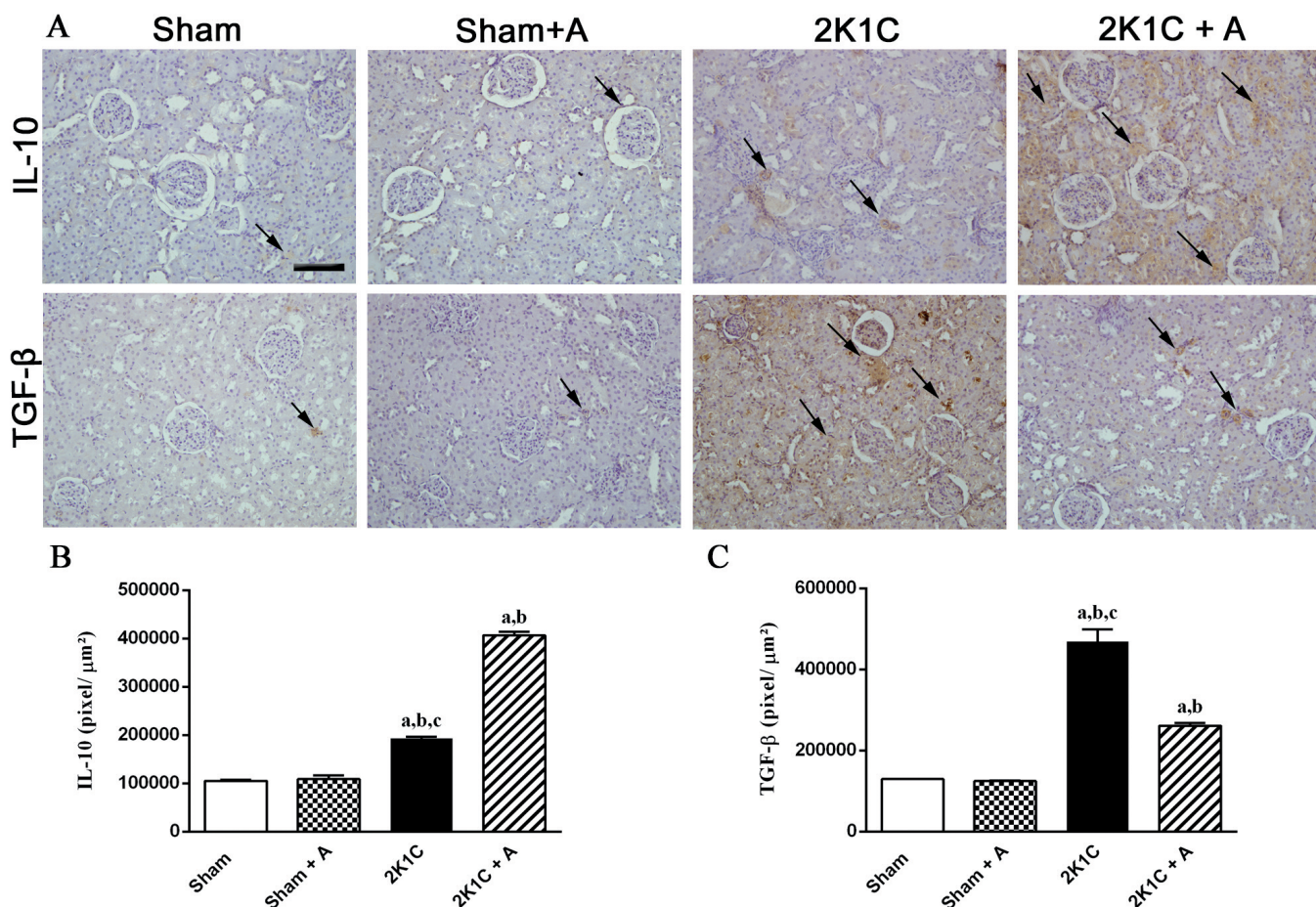


Fig. 7. Detection of TGF-β and IL-10 by immunohistochemistry and quantification. Photomicrographs of all experimental groups are presented in (A). Quantification of IL-10 and TGF-β are shown in (B and C) respectively. (a) $p < 0.05$ compared to the Sham group, (b) $p < 0.05$ compared to the Sham + A group and (c) $p < 0.05$ compared to the 2K1C + A group. $n = 10$ for all experimental groups. The arrows indicate positive immunostaining. Scale bar: 100 μm.

After the treatment with Aliskiren, renin expression is normalized, which allowed the control of the RAAS activity and, consequently, a reduction of the SBP of the 2K1C animals.

Our data showed that the Sham groups treated and not treated with Aliskiren did not present a significant difference, although it was expected that the treated group presented a reduction in BP. Muller and Luft (2006) have shown that the direct renin inhibitor increases renal blood flow at more significant levels than angiotensin converting enzyme inhibitors. Aliskiren-induced increased renal blood flow may occur in response to preferential vasodilation of the efferent arteriole due to inhibition of the effect of angiotensin II on AT 1 receptors located in these arterioles (Kedrah et al., 2012). As a consequence, the glomerular filtration pressure is reduced and according to the phenomenon of self-regulation, the urine output will also be reduced, with consequent increase in plasma volume (Guyton and Hall, 2006). These data corroborate our results in urine biochemistry where the Sham + A group showed a significant reduction of urinary volume and slight non-significant reduction of creatinine and urinary protein parameters.

Our findings showed that treatment with Aliskiren reduced SBP and interstitial fibrosis, improving renal morphology, and decreased TGF- β expression. Aliskiren improved these physiological parameters, playing a renal protective role through the suppression of type III and IV collagen production and reduction of TGF- β expression. This cytokine acts as a mediator key in the progression of the pathologic renal fibrosis through of the extracellular matrix production (Bottinger, 2007; Nussberger et al., 2007; Kelly et al., 2007; Feldman et al., 2008). The fibrotic effects of TGF- β can be summarized in two cellular events: apoptosis induction and transition from epithelial to mesenchymal cells. Induction of apoptosis by TGF- β is associated with podocyte depletion, glomerulosclerosis, loss of glomerular or peritubular capillaries, and tubular atrophy (Meier et al., 2007; Cho, 2010).

Laminin is the main component of the basement membrane and connects the cells to the other components of the membrane, as well as modulating cell proliferation, differentiation and motility (Kumar et al., 2013). In our study, a significant increase in laminin synthesis was observed in the 2K1C group. According to other studies, this increase is associated with pathophysiological processes that affect the nephron, such as the progression of mesangial cells and the consequent development of its matrix, causing thickening of the basement membrane (Pinto, 1998). Increased pressure and glomerular filtration in the nephrons causes sclerotic lesions, that is, the replacement of normal tissue by connective tissue, beginning with the accumulation of extracellular matrix (Guyton and Hall, 2006). The mesangial expansion is a consequence of this accumulation, and causes increased deposition of components such as collagen, laminin and

fibronectin, due to increased production of these elements and / or decreased degradation (Fioretto and Mauer, 2007).

The renal ultrastructure analysis showed that the animals of the 2K1C group had pedicle retraction, secondary podocyte extensions, loss of glomerular filtration cleft integrity and GBM thickening. This alteration corroborates the increased expression of laminin. Evidence shows that lesions to the podocytes are closely correlated with proteinuria and, consequently, loss of kidney function, since the pedicels are interconnected by a slit diaphragm, which is the main filtration barrier (Pavenstadt et al., 2003; Wartiovaara et al., 2004). In our study, the hypertensive animals treated with Aliskiren showed integrity of the pedicels and the filtration slit, as well as normalization of GBM.

In addition, we demonstrated a reduction in kidney inflammation, by increasing the expression of IL-10, an anti-inflammatory cytokine and decreased expression of TNF- α and IL-6, proinflammatory cytokines, in Aliskiren-treated 2K1C hypertensive rats. IL-10 is a cytokine with important anti-inflammatory properties, such as an inhibition of the production of proinflammatory cytokines and stimulation of anti-inflammatory cells, such as regulatory T cells and macrophages (Moore et al., 2001). A deficiency in IL-10 expression may aggravate the development of CKD through the progression of atherosclerosis (George et al., 2004). In our model of 2K1C hypertension, the hypertensive group showed a decrease in immunostaining by the anti-IL-10 antibody, whereas the hypertensive animals treated with Aliskiren showed an increase in this staining.

In relation to proinflammatory cytokines, our study demonstrated that animals with 2K1C hypertension had increased expression of TNF- α and IL-6, mainly in the tubular region, suggesting that these cytokines may play a role without the development of inflammatory hypertension (Dzielak, 1992; Cottone et al., 1998).

The TNF- α plays an important role in the maintenance of inflammation through the induction of adhesion molecules, chemotactic factors and cytokines, besides acting on the infiltration and activation of macrophages. In rats with renal injury, increased levels of TNF- α were observed mainly in renal tubules and interstitial cells, suggesting that increased cytokine expression is associated with interstitial fibrosis (Taal et al., 2000).

The levels of TNF- α and IL-6 are correlated with the increase and variability of SBP, suggesting that an inflammation may be a mediator between our SBP levels and target organ damage (Kim et al., 2008). Previous studies have shown an increase in the production of inflammatory factors, such as IL-6 and TNF- α in 2K1C hypertensive rats (Matavelli et al., 2011) and in patients with renovascular hypertension (Alhadad et al., 2007). However, 2K1C animals treated with Aliskiren showed a significant reduction in TNF- α and IL-6 marking, suggesting that Aliskiren is able to reduce the

Aliskiren induces renoprotection in 2K1C rats

inflammatory condition established by renal artery stenosis.

For the evaluation of renal function, creatinine and protein urinary levels were analyzed. Creatinine is an important marker of renal function and is derived primarily from the metabolism of muscle creatine and excreted entirely by the urine, it is not reabsorbed by the body. Therefore, its urinary level decreases when there is a deficiency in renal filtration capacity, suggesting that there is damage to the nephrons (Abensur, 2011). However, treatment with Aliskiren was able to increase creatinine urinary levels close to the animals in the Sham group.

The proteinuria was observed in the animals of the 2K1C group. In the 2K1C group treated with Aliskiren, proteinuria was significantly reduced, matching values found in the Sham group. The presence of protein in the urine, called proteinuria, is toxic to the tubules and can cause tubulointerstitial inflammation and is associated with damage to the kidney through the stimulation of pro-inflammatory effects. Therefore, this biochemical marker is considered a strong parameter to identify the progression of CKD (Gorriz and Martinez-Castelao, 2012). Therefore, these data indicate that treatment with Aliskiren was able to reverse the renal damage caused by artery stenosis in the 2K1C group.

Further studies are necessary to elucidate the mechanism of action of aliskiren, which was a limitation of our work. However, based on our findings, we can hypothesize, mainly because some studies corroborate our findings (Costanzo et al., 2003; Bivol et al., 2008; Baracho et al., 2017; Chalmers et al., 2019). In the 2K1C hypertension model, the elevation of arterial hypertension is observed due to the renin increasing, demonstrating that this is the main route of BP elevation. With the overactivation of the RAAS, there is an increase of Ang II systemic and intra-renal. Renal cells, such as tubular and mesangial cells, have Ang II receptors whose increased effect generates activation of the intracellular cascade of NF- κ -B transcription factor. This factor is involved in the inflammatory process, increasing the transcription of pro-inflammatory cytokines, such as IL-6 and TNF- α . The chronicity of the inflammatory process leads to renal damage, evaluated by the increase of urinary proteins, that stimulates the tissue repair indicated by the increase of TGF- β expression, deposition of laminin and tubular fibrosis. Thus, there is an increase in the thickness of the basement membrane of the nephrons and consequent reduction of protein filtration capacity, as seen in the reduction of creatinine in our model. The administration of Aliskiren, because it acts on renin blockade, decreases systemic Ang II, leading to the inhibition of the cascade of proinflammatory intracellular signaling, reversing the hypertensive effects generated by the 2K1C model.

In conclusion, this study showed that daily treatment with Aliskiren orally promoted the reduction of systemic arterial pressure, reestablished the renal parenchyma and the glomerular filtration barrier, attenuating interstitial

fibrosis and decreasing the expression of pro-inflammatory cytokines in the kidney cortex of rats with renovascular hypertension. In addition, it was able to improve renal function by restoring urinary creatinine protein levels. Therefore, our findings suggest that treatment with Aliskiren is not only a medicine capable of reducing blood pressure, but it also has beneficial effects on the structure and function of the kidney, improving the systemic and local effects caused by renovascular hypertension.

Acknowledgements. This study was supported by Fundação Carlos Chagas Filho de Amparo à Pesquisa do Estado do Rio de Janeiro (FAPERJ), Conselho Nacional de Desenvolvimento Científico e Tecnológico (CNPq), Coordenação de Aperfeiçoamento de Pessoal de nível Superior (Capes) and Universidade do Estado do Rio de Janeiro (UERJ).

Disclosure statements. We declare no competing interests in this work.

Authors contribution. PP, JF and JC designed the study. PP, KR and JA performed the research experiments for renal evaluation and analyzed the results. AN, JF, BC, AV optimized or supported some experiments. PP wrote the first version of the manuscript. KR, AV and JJC edited the manuscript. All authors gave final approval.

References

- Abensur H. (2011). E-book-Biomarcadores na nefrologia. Associação Brasileira de Nefrologia.
- Alhadad A., Guron G., Fortuna-Nowakowska E., Saeed A., Mattiasson I., Jensen G., Lindblad B., Gottsater A. and Herlitz H. (2007). Renal angioplasty causes a rapid transient increase in inflammatory biomarkers, but reduced levels of interleukin-6 and endothelin-1 1 month after intervention. *J. Hypertens.* 25, 1907-1914.
- Amat N., Amat R., Abdureyim S., Hoxur P., Osman Z., Mamut D. and Kijjoa A. (2014). Aqueous extract of *dioscorea opposita* thunb normalizes the hypertension in 2K1C hypertensive rats. *BMC Complement Altern. Med.* 14-36.
- Baracho N.C.D.V., Silveira K.D.D., Rocha N.P., Cordeiro T.M., Feracin V., Pereira R.M., Reis M.A.A.D., Teixeira M.M. and Silva A.C.S.E. (2017). Urinary cytokine profiles according to the site of blockade of the renin-angiotensin system in nephrectomized rats. *J. Bras. Nefrol.* 39, 108-118.
- Bautista L.E., Vera L.M., Arenas I.A. and Gamarra G. (2005). Independent association between inflammatory markers (C-reactive protein, interleukin-6, and TNF-alpha) and essential hypertension. *J. Hum. Hypertens.* 19, 149-154.
- Bivol L.M., Berge R.K. and Iversen B.M. (2008). Tetradecylthioacetic acid prevents the inflammatory response in two-kidney, one-cliphypertension. *Am. J. Physiol. Regul. Integr. Comp. Physiol.* 294, 38-47.
- Bottinger E.P. (2007). TGF-beta in renal injury and disease. *Semin Nephrol.* 27, 309-320.
- Chae C.U., Lee R.T., Rifai N. and Ridker P.M. (2001). Blood pressure and inflammation in apparently healthy men. *Hypertension* 38, 399-403.
- Chalmers S.A., Garcia S.J., Reynolds J.A., Herlitz L. and Putterman C. (2019). NF- κ B signaling in myeloid cells mediates the pathogenesis of immune-mediated nephritis. *J. Autoimmun.* 98, 33-43.

Aliskiren induces renoprotection in 2K1C rats

- Chen Y., Meng L., Shao H. and Yu F. (2013). Aliskiren vs. other antihypertensive drugs in the treatment of hypertension: a meta-analysis. *Hypertens Res.* 36, 252-261.
- Cho M.H. (2010). Renal fibrosis. *Korean J. Pediatrics* 53, 735-740.
- Chou C.L., Pang C.Y., Lee T.J. and Fang T.C. (2013). Direct renin inhibitor prevents and ameliorates insulin resistance, aortic endothelial dysfunction and vascular remodeling in fructose-fed hypertensive rats. *Hypertens Res.* 36, 123-128.
- Conrad K.P. and Benyo D.F. (1997). Placental cytokines and the pathogenesis of preeclampsia. *Am. J. Reprod. Immunol.* 37, 240-249.
- Costanzo A., Moretti F., Burgio V.L., Bravi C., Guido F., Levrero M. and Puri P.L. (2003). Endothelial activation by angiotensin II through NfκappaB and p38 pathways: Involvement of NFKappaB-inducible kinase (NIK), free oxygen radicals, and selective inhibition by aspirin. *J. Cell Physiol.* 195, 402-410.
- Cottone S., Vadalà A., Vella M.C., Mulè G., Contorno A. and Cerasola G. (1998). Comparison of tumor necrosis factor and endothelin-1 between essential and renal hypertension patients. *J. Hum. Hypertens.* 12, 351-354.
- Dzielak D.J. (1992). The immune system and hypertension. *Hypertension* 19, 136-144.
- Escobar C., Echarri R. and Barrios V. (2012). Emerging drug combinations to optimize renovascular protection and blood pressure goals *International J. Nephrol. Renovasc. Dis.* 5, 69-80.
- Feldman D.L., Jin L., Xuan H., Contrepas A., Zhou Y., Webb R.L., Mueller D.N., Feldt S., Cumin F., Maniara W., Persohn E., Schuetz H., Jan Danser A.H. and Nguyen G. (2008). Effects of aliskiren on blood pressure, albuminuria, and (pro)renin receptor expression in diabetic TG(mRen-2)27 rats. *Hypertension* 2008. 52, 130-136.
- Fioretto P. and Mauer M. (2007). Histopathology of diabetic nephropathy. *Semin. Nephrol.* 27, 195-207.
- Fisher N.D., Jan Danser A.H., Nussberger J., Dole W.P. and Hollenberg N.K. (2008). Renal and hormonal responses to direct renin inhibition with aliskiren in healthy humans. *Circulation* 117, 3199-3205.
- Fogari R. and Zoppi A. (2010). New class of agents for treatment of hypertension: focus on direct renin inhibition. *Vasc. Health Risk Manag.* 6, 869-882.
- Friedrich S. and Schmieder R.E. (2013). Review of direct renin inhibition by aliskiren. *J. Renin Angiotensin Aldosterone Sys.* 2013. 14, 193-196.
- George S., Ruan X.Z., Navarrete C., Turner D., Reynard M., Sweny P., Hamilton G., Wheeler D.C., Powis S.H., Moorhead J.F. and Varghese Z. (2004). Renovascular disease is associated with low producer genotypes of the anti-inflammatory cytokine interleukin-10. *Tissue Antigens* 63, 470-475.
- Goldblatt H., Lynch J., Hanzal R.F. and Summerville W.W. (1934). Studies on experimental hypertension: I. The production of persistente elevation of systolic blood pressure by means of renal ischemia. *J. Exp. Med.* 59, 347-379.
- Gorritz J.L. and Martinez-Castelao A. (2012). Proteinuria: detection and role in native renal disease progression. *Transplant Rev.* 26, 3-13.
- Guyton A.C. and Hall J.E. (2006). Text book of medical physiology. 11th ed. In: Elsevier Saunders. São Paulo. Brazil. pp 248-256.
- Han Y., Runge M.S. and Brasier A.R. (1999). Angiotensin II induces interleukin-6 transcription in vascular smooth muscle cells through pleiotropic activation of nuclear factor kappa B transcription factors. *Circ. Res.* 84, 695-703.
- Ikeda U., Ikeda M., Oohara T., Oguchi A., Kamitani T., Tsuruya Y. and Kano S. (1991). Interleukin 6 stimulates growth of vascular smooth muscle cells in a PDGF-dependent manner. *Am. J. Physiol.* 260, H1713-H1717.
- Imanishi T., Tsujioka H., Ikejima H., Kuroi A., Takarada S., Kitabata H., Tanimoto T., Muragaki Y., Mochizuki S., Goto M., Yoshida K. and Akasaka T. (2008). Renin inhibitor aliskiren improves impaired nitric oxide bioavailability and protects against atherosclerotic changes. *Hypertension* 52, 563-572.
- Kashyap S., Boyilla R., Zaia P.J., Ghossan R., Nath K.A., Textor S.C., Lerman L.O. and Grande J.P. (2016). Development of renal atrophy in murine 2 kidney 1 clip hypertension is strain independent. *Res. Vet. Sci.* 107, 171-177.
- Kedrah A.E., Ari E., Alahdab Y., Gul C.B., Macunluoglu B., Atakan A., Asicioglu E., Cakalagaoglu F. and Koc M. (2012). Effect of the direct renin inhibitor aliskiren in the prevention of experimental contrast-induced nephropathy in the rat. *Kidney Blood Press Res.* 35, 425-430.
- Kelly D.J., Zhang Y., Moe G., Naik G. and Gilbert R.E. (2007). Aliskiren, a novel renin inhibitor, is renoprotective in a model of advanced diabetic nephropathy in rats. *Diabetologia* 50, 2398-2404.
- Kim K.I., Lee J.H., Chang H.J., Cho Y.S., Youn T.J., Chung W.Y., Chae I.H., Choi D.J., Park K.U. and Kim C.H. (2008). Association between blood pressure variability and inflammatory marker in hypertensive patients. *Circ. J.* 72, 293-298.
- Kranzhöfer R., Schmidt J., Pfeiffer C.A., Hagl S., Libby P. and Kübler W. (1999). Angiotensin induces inflammatory activation of human vascular smooth muscle cells. *Arterioscler Thromb. Vasc. Biol.* 19, 1623-1629.
- Kumar V., Abbas A.K. and Aster J.C. (2013). Text book of Robbins Pathologic Basis of Disease. 9th ed. In: Elsevier. Rio de Janeiro. Brazil. pp 100-103.
- Lamb E.J., Levey A.S. and Stevens P.E. (2013). The Kidney Disease Improving Global Outcomes (KDIGO) guideline update for chronic kidney disease: evolution not revolution. *Clin. Chem.* 59, 462-465.
- Ledingham J.M. (1971). The etiology of hypertension. *Practitioner.* 207, 5-19.
- Levey A.S., Coresh J., Balk E., Kausz A.T., Levin A., Steffes M.W., Hogg R.J., Perrone R.D., Lau J., Eknoyan G. and National Kidney Foundation. (2003). National Kidney Foundation practice guidelines for chronic kidney disease: evaluation, classification, and stratification. *Ann. Intern. Med.* 139, 137-147.
- Lizakowski S., Tylicki L. and Rutkowski B. (2013). Direct renin inhibition - a promising strategy for renal protection? *Med. Sci. Monit.* 19, 451-457.
- Lupu A.N., Maxwell M.H., Kaufman J.J. and White F.N. (1972). Experimental unilateral renal artery constriction in the dog. *Cir. Res.* 30, 567-574.
- Marsden P.A. and Brenner B.M. (1992). Transcriptional regulation of the endothelin-1 gene by TNF-α. *Am. J. Physiol.* 262, C854-C861.
- Matavelli L.C., Huang J. and Siragy H.M. (2011). Angiotensin at receptor stimulation inhibits early renal inflammation in renovascular hypertension. *Hypertension* 57, 308-313.
- Meier M., Menne J., Park J.K., Holtz M., Gueler F., Kirsch T., Schiffer M., Mengel M., Lindschau C., Leitges M. and Haller H. (2007). Deletion of protein kinase C-epsilon signaling pathway induces glomerulosclerosis and tubulointerstitial fibrosis in vivo. *J. Am. Soc. Nephrol.* 18, 1190-1198.
- Minuz P., Patrignani P., Gaino S., Degan M., Menapace L., Tommasoli

Aliskiren induces renoprotection in 2K1C rats

- R., Seta F., Capone M.L., Tacconelli S., Palatresi S., Bencini C., Del Vecchio C., Mansueto G., Arosio E., Santonastaso C.L., Lechi A., Morganti A. and Patrono C. (2002). Increased oxidative stress and platelet activation in patients with hypertension and renovascular disease. *Circulation* 106, 2800-2805.
- Moore K.W., de Waal Malefyt R., Coffman R.L. and O'Garra A. (2001). Interleukin-10 and the interleukin-10 receptor. *Annu. Rev. Immunol.* 19, 683-765.
- Müller D.N. and Luft F.C. (2006). Direct renin inhibition with aliskiren in hypertension and target organ damage. *Clin. J. Am. Soc. Nephrol.* 1, 221-228.
- Nussberger J., Gradman A.H., Schmieder R.E., Lins R.L., Chiang Y. and Prescott M.F. (2007). Plasma renin and the antihypertensive effect of the orally active renin inhibitor aliskiren in clinical hypertension. *Int. J. Clin. Pract.* 61, 1461-1468.
- Oliveira-Sales E.B. and Boim M.A. (2016). Mesenchymal stem cells and chronic renal artery stenosis. *Am. J. Physiol. Renal. Physiol.* 310, 6-9.
- Oliveira-Sales E.B., Toward M.A., Campos R.R. and Paton J.F. (2014). Revealing the role of the autonomic nervous system in the development and maintenance of Goldblatt hypertension in rats. *Auton. Neurosci.* 183, 23-29.
- Pavenstadt H., Kriz W. and Kretzler M. (2003). Cell biology of the glomerular podocyte. *Physiol. Rev.* 83, 253-307.
- Persson F., Rossing P., Schjoedt K.J., Juhl T., Tarnow L., Stehouwer C.D., Schalkwijk C., Boomsma F., Frandsen E. and Parving H.H. (2008). Time course of the antiproteinuric and antihypertensive effects of direct renin inhibition in type 2 diabetes. *Kidney Int.* 73, 1419-1425.
- Pinto L.M. (1998). Células mesangiais e matriz mesangial: sua interação mediando o processo de cronificação da lesão glomerular. *Jornal Brasileiro de Nefrologia* 20, 178-185.
- Polzin D.J., Osborne C.A. and Bartges J.W. (2000). Chronic renal failure. In: *Textbook of veterinary internal medicine*. 5^a ed. Ettinger S.J., Feldman E.C. and Saunders W.B. (eds). (Philadelphia). 239, 1634-1662.
- Pullalarevu R., Akbar G. and Teehan G. (2014). Secondary hypertension, issues in diagnosis and treatment. *Prim. Care.* 41, 749-764.
- Ravera M., Re M., Deferrari L., Vettoretti S. and Deferrari G. (2006). Importance of blood pressure control in chronic kidney disease. *J. Am. Soc. Nephrol.* 4, S98-S103.
- Riccioni G. (2011). Aliskiren in the treatment of hypertension and organ damage. *Cardiovasc. Ther.* 29, 77-87.
- Riccioni G., Vitulano N., D'orazio N. and Bellocci F. (2009). Aliskiren, the first approved renin inhibitor: Clinical application and safety in the treatment of hypertension. *Adv. Ther.* 26, 700-710.
- Robles N.R., Cerezo I. and Hernandez-Gallego R. (2014). Renin-angiotensin system blocking drugs. *J. Cardiovasc. Pharmacol. Ther.* 19, 14-33.
- Sarafidis P.A. and Bakris G.L. (2008). Renin-angiotensin blockade and kidney disease. *Lancet* 372, 511-512.
- Sardo M.A., Mandraffino G., Campo S., Saitta C., Bitto A., Alibrandi A., Riggio S., Imbalzano E. and Saitta A. (2009). Biglycan expression in hypertensive subjects with normal or increased carotid intima-media wall thickness. *Clin. Chim. Acta* 406, 89-93.
- Shankar A., Sun L., Klein B.E., Lee K.E., Muntner P., Nieto F.J., Tsai M.Y., Cruickshanks K.J., Schubert C.R., Brazy P.C., Coresh J. and Klein R. (2011). Markers of inflammation predict the long-term risk of developing chronic kidney disease: a population-based cohort study. *Kidney Int.* 80, 1231-1238.
- Skurk T., van Harmelen V. and Hauner H. (2004). Angiotensin II stimulates the release of interleukin-6 and interleukin-8 from cultured human adipocytes by activation of nuclear factor kappa B. *Arterioscler. Thromb. Vasc. Biol.* 24, 1199-1203.
- Sociedade Brasileira de Cardiologia (2010). VI Diretrizes Brasileiras de Hipertensão. *Arq. Bras. Cardiol.* 95, 1-51.
- Stouffer G.A., Pathak A. and Rojas M. (2010). Unilateral renal artery stenosis causes a chronic vascular inflammatory response in apoe2/2 mice. *Trans. Am. Clin. Climatol. Assoc.* 121, 252-264; 264-256.
- Taal M.W., Zandi-Nejad K., Weening B., Shahsafaei A., Kato S., Lee K.W., Ziai F., Jiang T., Brenner B.M. and MacKenzie H.S. (2000). Proinflammatory gene expression and macrophage recruitment in the rat remnant kidney. *Kidney Int.* 58, 1664-1676.
- Van Esch J.H., Moltzer E., Van Veghel R., Garrelds I.M., Leijten F., Bouhuizen A.M. and Danser A.H. (2010). Beneficial cardiac effects of the renin inhibitor aliskiren in spontaneously hypertensive rats. *J. Hypertens.* 28, 2145-2155.
- Van Hinsbergh V.W., Kooistra T., van den Berg E.A., Princen H.M., Fiers W. and Emeis J.J. (1988). Tumor necrosis factor increases the production of plasminogen activator inhibitor in human endothelial cells in vitro and rats in vivo. *Blood* 72, 1467-1473.
- Wartiovaara J., Ofverstedt L.G., Khoshnoodi J., Zhang J., Makela E., Sandin S., Ruotsalainen V., Cheng R.H., Jalanko H., Skoglund U. and Tryggvason K. (2004). Nephron strands contribute to a porous slit diaphragm scaffold as revealed by electron tomography. *J. Clin. Invest.* 114, 1475-1483.

Accepted October 18, 2019