

# Storage of blood clots for histological analysis: how long is too long in saline and paraformaldehyde?

Andrew Douglas<sup>1,2</sup>, Seán Fitzgerald<sup>1,2</sup>, Abhay Pandit<sup>1</sup> and Karen M. Doyle<sup>1,2</sup>

<sup>1</sup>Centre for Research in Medical Devices and <sup>2</sup>Department of Physiology, National University of Ireland, Galway, Ireland

**Summary.** To investigate the composition of blood clots following mechanical thrombectomy, it is essential to ensure optimum storage for highest quality histological and immunofluorescence analysis. We investigated for how long clots can be stored in paraformaldehyde (PFA), saline and heparinised saline before the tissue integrity is compromised.

Whole blood and fibrin-rich clot analogues were made under dynamic flow conditions. Clots were stored in 4% PFA, saline or heparinised saline for timepoints ranging from 1 hour to two months. Five  $\mu\text{m}$  sections were stained with Martius Scarlet Blue to visualise red blood cells (RBCs), white blood cells (WBCs) and fibrin. Semi-quantitative analysis of the integrity of clot components used a scoring system (0: Poor; 1: Sub-par; 2: High). Quantitative analysis used Orbit Image Analysis software. Autofluorescence was assessed using a relative scale.

Clots stored in PFA for up to two months were qualitatively similar to those stored for all shorter periods (median score: 2 per component). Clots stored in saline/heparinised saline for one week showed degradation of RBCs and WBCs, but fibrin remained intact (median score: 1, 1, 2 respectively). Degradation of the samples stored in saline/heparinised saline made accurate quantification using Image Analysis software difficult from 24h.

Samples stored in PFA for up to two weeks showed an edging autofluorescence effect, which became more

evident with prolonged storage.

For optimum histology, ideally clots should not be stored in saline before fixation and should ideally be stored in formalin for less than one month to minimise the impact of autofluorescence on immunofluorescence.

**Key words:** Paraformaldehyde (PFA), Clot analogues, Histological and Tissue integrity

## Introduction

In global terms stroke is one of the most common causes of death and sustained disability. In 2013 the prevalence of stroke was 25.7 million (Feigin et al., 2016), with up to 85% of strokes being ischaemic. Currently the only approved pharmacological treatment for acute ischaemic stroke is intravenous thrombolysis with tissue-type plasminogen activator (IVtPA), which was shown to have favourable outcomes in the 1996 National Institute of Neurological Disorders and Stroke (NINDS) study (NINDS rt-PA Stroke Study Group, 1995). More recently the use of mechanical thrombectomy (MT) has become the standard for thrombus removal in Large Vessels occlusions. In 2015 five randomised trials, ESCAPE (Goyal et al., 2015), EXTEND-IA (Campbell et al., 2015), MR CLEAN (Berkhemer et al., 2015), REVASCAT (Jovin et al., 2015) and SWIFT-PRIME (Saver et al., 2015) were published. The results from these studies show much better outcomes for MT, mainly in conjunction with IV-tPA and also in cases if IV-tPA was contraindicated against other non-invasive procedures (Fiehler and Gerloff, 2015).

Removal of these clots by MT provides an

*Offprint requests to:* Dr Karen Doyle, Department of Physiology, School of Medicine, CÚRAM-Centre for Research in Medical Devices, National University of Ireland Galway, University Road, Galway, Ireland. e-mail: [karen.doyle@nuigalway.ie](mailto:karen.doyle@nuigalway.ie)

DOI: 10.14670/HH-18-154

opportunity to study their histological composition which was not previously the case in patients treated with IV-tPA as the thrombus was broken down internally. The composition of thrombi has been shown to significantly affect the success of the mechanical thrombectomy procedure (Chueh et al., 2011; Maekawa et al., 2018) and therefore studying the histopathological composition of thrombi is essential for the advancement of acute ischaemic stroke treatment and the improvement of clinical outcomes (De Meyer et al., 2017). This study investigated the optimal storage conditions for human blood clots prior to histological analysis.

## Materials and methods

### Clot analogue creation

The study was approved by the National University of Ireland Galway Ethics committee. Human blood from two O+ donors that was technically unusable for transfusion was obtained from the Irish Blood Transfusion Service (IBTS) and used to make clot analogues. Briefly, venous blood was drawn into a standard blood bag containing sodium citrate (3.2% w/v) in a citrate phosphate dextrose (CPD) solution containing citric acid, sodium citrate, monobasic sodium phosphate, and dextrose. This CPD solution is the primary anticoagulant used for preservation of whole blood (1 in 10 dilution) for up to 21 days. Blood was stored at 4°C prior to clot creation. Two different clot analogues were used; whole blood and fibrin-rich (Fig. 1). Whole blood clots were made using un-centrifuged whole blood. In order to make a fibrin-rich clot, whole blood was centrifuged at 1,500 RPM for 15 minutes at room temperature to separate the blood into its primary components. Plasma and red blood cells were then mixed in a 19:1 ratio (Plasma: RBC). Clot analogues were made using a modified Chandler loop system. Briefly, 9ml of blood was added to the silicone loop. In order to stimulate coagulation, 1 ml of 5% calcium chloride in distilled water (1:9 CaCl<sub>2</sub> into blood) was added at the terminal face of the blood. The Chandler loop containing the blood was spun at 24 RPM for one hour at room temperature to achieve clot formation.

### Storage solutions and storage times

Storage solutions used in this study were 4% Paraformaldehyde (PFA), 0.9% Saline and heparinised saline (100 IU/ml). All storage solutions had 6 common time points for storage before processing, these being 1 hour, 24 hours, 48 hours, 1 week, 2 weeks and 1 month. Additionally, PFA stored analogues had a further time point of two months.

### Tissue processing and histology

The clot analogue tissue was processed using a


routine overnight protocol on a Leica ASP300 tissue processor, formaldehyde (1 hour), 70% ethanol (45 mins), 90% ethanol (45 mins), three changes in 100% ethanol (45 mins, 1 hour, 1 hour), three changes in xylene (45 mins, 1 hour, 1 hour 15 mins), three changes in paraffin wax (1 hour (temp 62°C)). Sections were then blocked in paraffin wax. Sections were cut at five  $\mu$ m on a Leica RM2125 manual microtome. Sections were then stained with Haematoxylin and Eosin (H&E), Masson's trichrome stain and Martius Scarlet Blue (MSB) stains for tissue visualisation.

### Haematoxylin and eosin

Slides were deparaffinised in xylene (2x10 mins) and rehydrated in two changes of absolute alcohol, one change of 95%, 70% and 50% alcohols (2 mins each). Slides were then washed in running tap water (2 mins) then stained with Mayer's Haematoxylin for six minutes. Slides were rinsed in running tap water (4 mins) to allow bluing then placed in Eosin (2 mins). Slides were then dehydrated in one change of 50% and 70% (10 secs each), 95% (2 mins) and two changes of absolute alcohols (2x2 mins), cleared with xylene (2x10 mins) and mounted with DPX.

### Masson's Trichrome

Slides were deparaffinised in xylene (2x10 mins) and rehydrated in two changes of absolute alcohol, one change of 95%, 70% and 50% alcohols (2 mins each). Slides were then washed in running tap water (2 mins) and oxidised in 0.5% KMnO<sub>4</sub>/0.5% H<sub>2</sub>SO<sub>4</sub> (2 mins).



**Fig. 1.** Clot Analogues. **A.** An example of a gross photograph of a whole blood clot analogue. **B.** An example of a gross photograph of a fibrin-rich clot analogue.

## Storage of blood clots for histological analysis

Slides were rinsed in running tap water and bleached in 2% Sodium Metabisulphite ( $\text{Na}_2\text{S}_2\text{O}_5$ ) (2 mins), rinsed in tap water (30 secs) followed by 70% alcohol (1 min). Slides were then stained in Gomori's Aldehyde Fuchsin (1 min), rinsed quickly in tap water followed by 95% alcohol (10 secs) and tap water (10 secs) and then stained in celestine blue (4 mins). Slides were rinsed in running tap water (30 secs), stained in Mayer's Haematoxylin (4 mins), rinsed in tap water (20 secs), differentiated in acid/alcohol (20 secs) and rinsed in running tap water (4 mins) to allow bluing. Slides were stained in Masson's cytoplasmic stain (1 min), rinsed quickly in tap water and differentiated in 1% dodecamolybdophosphoric acid ( $\text{H}_3\text{PO}_4 \cdot 12\text{MoO}_3 \cdot 4\text{H}_2\text{O}$ ) (2 mins), rinsed quickly in tap water, counterstained in fast green (1 min) and differentiated in 1% acetic acid solution (1 min). Slides were then dehydrated in one change of 50%, 70% and 95% (1 min) and absolute alcohols (2x1 min), cleared with xylene (2x10 mins) and mounted with DPX.

### Martius scarlet blue

Slides were deparaffinised in xylene (2x10 mins) and rehydrated in absolute alcohol (2x2 mins), 95% alcohol (2x2 mins), 80% alcohol (2 mins) and rinsed in running tap water (2 mins). Slides were then placed into Bouin's fluid at 56°C in a water bath (1 hour) and then rinsed in running tap water (5 mins). Slides were then placed into filtered Iron ammonium-celestine blue solution (10 mins), rinsed in running tap water (5 mins), stained with filtered Mayer's Haematoxylin (10 mins) and rinsed in warm running water to blue. Slides were rinsed with 95% alcohol (1 min) followed by fresh Martius yellow (5 mins), rinsed in distilled water (1 min) and then stained in filtered Crystal scarlet (10 mins). Slides were then differentiated in fresh phosphotungstic acid (7 mins), stained with Methyl blue (10 mins) and rinsed in 1% aqueous acetic acid (1 min). Sections were dehydrated in absolute alcohol (2 fast dips), cleared in xylene (2x5 mins) and mounted in DPX.

### Scanning and quantification

Slides were scanned on an Olympus VS120 slide scanner and whole-slide scan images were generated in a

.vsi format. Images could then be visualised using the Olympus OlyVIA software. For semi quantitative analysis .jpeg images were generated from the Olympus OlyVIA software. For quantitative analysis the scan file was opened up directly using ORBIT analysis freeware.

Clot analogues were visually analysed for the integrity of three clot components using a scoring system (0: low; 1: sub-par; 2: high). Images in a .jpeg format were generated using the Olympus OlyVIA software at X200 magnification to assess the clot composition. RBC's, WBC's and fibrin in four regions from each clot were assessed giving a maximum score of 8 for each component and a total maximum score of 24 for each clot.

Quantitative analysis was performed on whole sections of MSB stained tissue using Orbit Image Analysis machine learning software (Fitzgerald et al., 2018). This software contains image algorithms for segmentation, classification and quantification, these are described in detail (Stritt et al., 2011; Seger et al., 2018). Using representative MSB stained images the machine learning model is trained to recognise different cell and tissue types. The results were expressed as an area fraction for each cell/tissue type. Analysis was only performed on PFA sections due to the deterioration found in the saline and heparinised saline series.

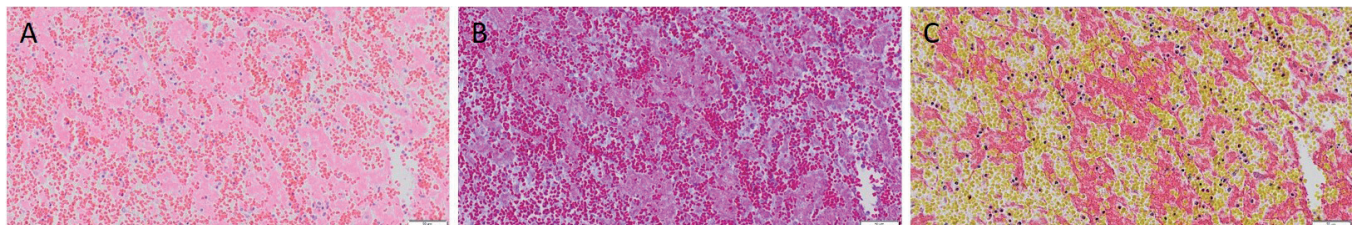
### Immunofluorescence

Sections were dewaxed, rehydrated and cleared using standard histological protocols and then washed (3x5 mins) in phosphate buffered saline (PBS). No antibodies were used as the aim was to detect the level of autofluorescence. Sections were then mounted in Fluoroshield mounting medium with DAPI (Abcam - ab104139) and cover-slipped. Sections from each time point were then scanned on an Olympus VS120 slide scanner using the DAPI, FITC and TRITC channels and assessed for autofluorescence.

## Results

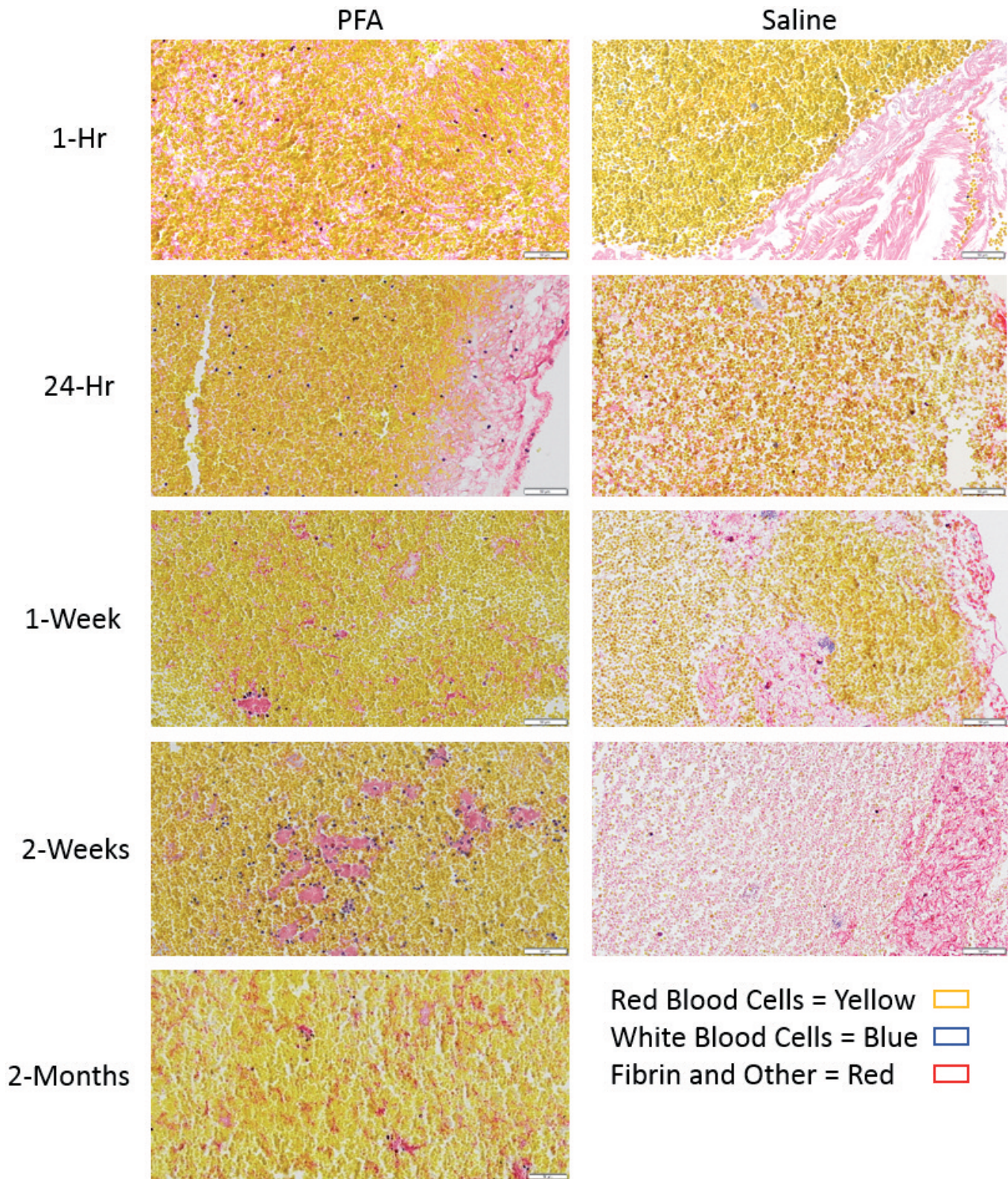
### Histological assessment

The first objective of this study was to assess the histological staining qualities of three stains H&E,



**Fig. 2.** Comparison between stains H&E (A), Masson's (B) and MSB (C). Images are from sample stored in PFA for one week prior to fixation. The three components are easily identifiable in the MSB stained section having distinctly different colours. x 200.

Storage of blood clots for histological analysis



**Fig. 3.** PFA versus Saline Storage Conditions. Tissue stored in PFA showed no signs of cellular degradation and staining was consistent across all time points. Tissue stored in Saline showed deterioration in both RBC and WBC becoming more pronounced after 1 week of storage. x 200.

## Storage of blood clots for histological analysis

Masson's trichrome and MSB. The main criteria for determining the suitability of these stains when compared was the visualisation of three main components found within the clot analogues, red blood cells, white blood cells and fibrin. Another consideration that had to be taken into account was the degree of colour differentiation between the components in order to be able to quantify them accurately using the Orbit Image analysis software for quantification wherein each component within the clot is identified based upon its colour. Consequently, we found that of the three stains, the MSB stain produced the best results (Fig. 2) for both criteria, in that the three components studied were of distinctly different colour.

Histological integrity was assessed in each clot cohort by visual scoring. Clot analogues stored in PFA showed no deterioration in histological quality at all-time points up to two months in PFA solution before processing (Fig. 3). Clot analogues stored in both saline and heparinised saline had a marked reduction in white blood cell content after one week in solution. Degradation of RBC's was also observed in the form of reduced colouration of RBC's (Fig. 3), most notably

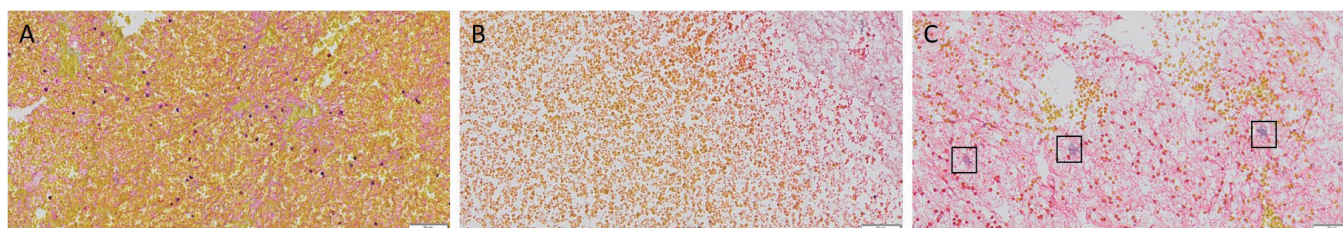
after two weeks of storage in saline and heparinised saline. This finding was observed in both the whole blood and the 5% RBC clots.

After two weeks in both the saline and heparinised saline many red blood cells had become crenated (Fig. 4B). Also, there were very few white blood cells visible and also evidence of nuclear material on the section (Fig. 4C).

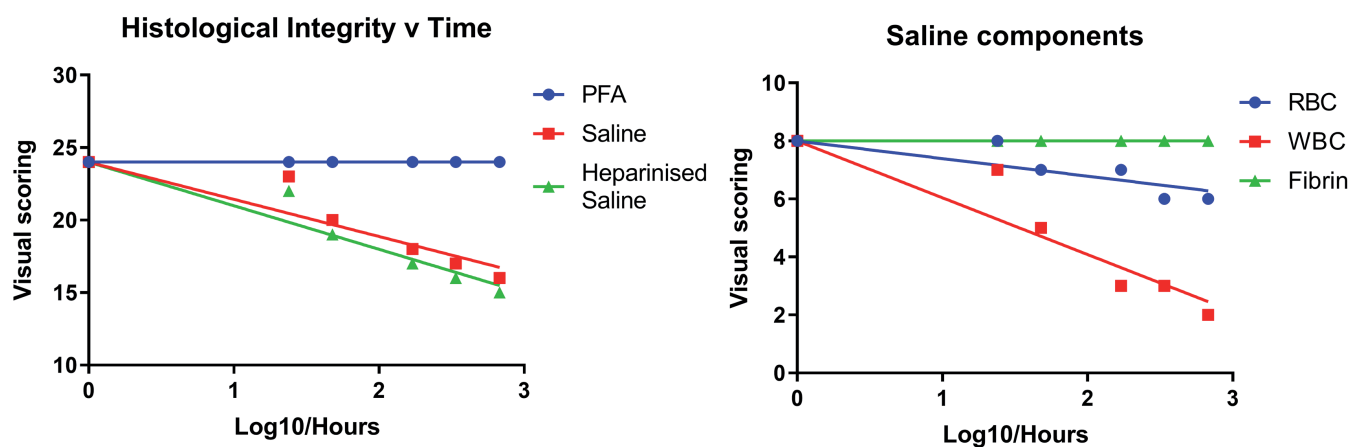
Clot analogues stored in saline and heparinised saline showed decreasing quality in a time-dependent manner (Fig. 5).

### Quantification

Quantification was performed on the whole blood series stored in PFA (Fig. 6) and demonstrated that quantification was accurate even after storage in PFA up to 1 month. Statistical analysis was performed on the quantification results in the form of a 2-way ANOVA to show there was no significant difference in clot composition in the clot analogues  $F(5, 10)=7.0 \times 10^{-8}$ ,  $p>0.9999$ , confirming no deterioration in PFA stored clot components over time.



**Fig. 4.** Degradation of Components in Saline. **A.** A clot analogue made from Whole blood stored in PFA for two weeks showing normal tissue with RBC, WBC and fibrin all intact. **B.** A clot analogue made from whole blood stored in saline for two weeks showing RBC crenation. **C.** A clot analogue made from whole blood stored in saline for two weeks showing WBC disruption. x 200.



**Fig. 5.** Semi-quantitative assessment of Clot Analogues. **A.** Visual scoring of tissue quality of whole (0: Poor; 1: Sub-par; 2: High) blood analogues using RBC, WBC and fibrin as indicators, storage times in each solution was 1hr, 24hrs, 48hrs, 1 week and 1 month. **B.** Visual scoring of quality for individual components stored in saline.

*Immunofluorescence*

Clot analogues stored in PFA showed a distinct autofluorescence edging effect in the 1 hour, 24 hour, 48 hour, 1 week and 2 week samples. From one month onwards this autofluorescence became more pronounced and was evident throughout the whole tissue (Fig. 7).

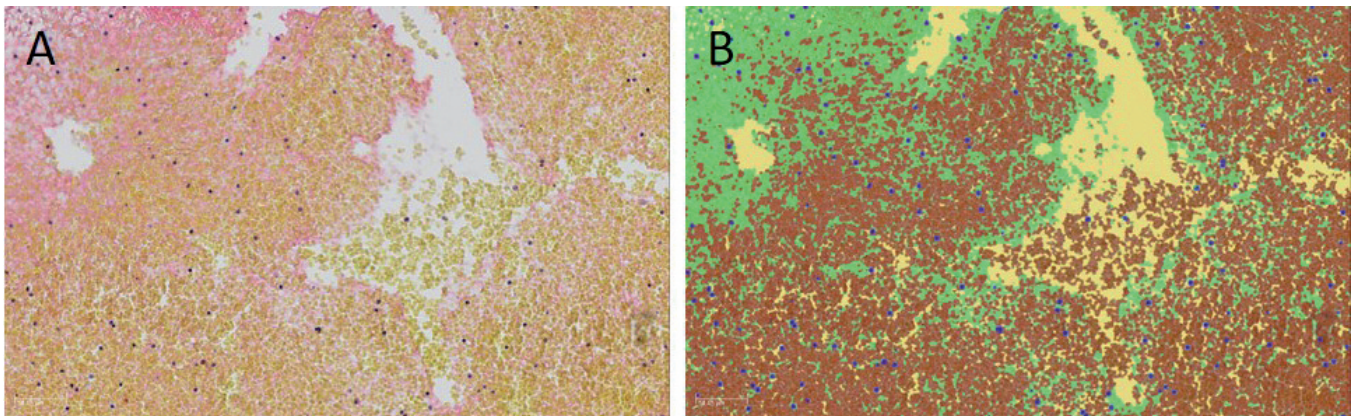
**Discussion**

This study demonstrates that PFA is the optimal storage solution for whole blood and fibrin clots and potentially for acute ischemic stroke blood clots. Degradation of the major clot components occurs quickly in a time-dependent manner when stored in both saline and heparinized saline solutions. Therefore, clots removed during an endovascular procedure may be stored in saline/heparinised saline temporarily in the

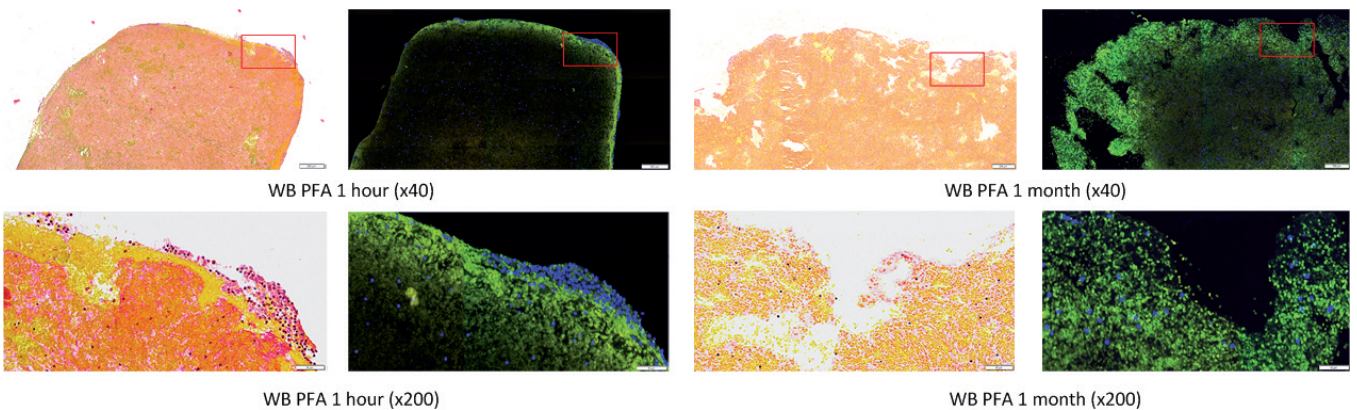
acute setting, but should be transferred to PFA as soon as possible after the completion of the procedure.

PFA is the most commonly used fixative in histopathology and typically results in the preservation of tissue and cells in a state that most closely resembles the natural condition. PFA-fixation terminates biochemical reactions such as autolysis and bacterial decomposition. We found that clot analogues stored in PFA for up to two months demonstrated no signs of deterioration of any of the major components of AIS clots. PFA-stored clot analogues were quantifiable using the Orbit Image analysis software and no significant difference was observed in the clot components at different time points.

The histological integrity of clots stored in both saline and heparinised saline deteriorates over time when compared with their PFA stored counterparts. This effect has been noted in other tissues similarly stored in saline



**Fig. 6.** ORBIT analysis for quantification. **A.** A MSB stained slide demonstrating the presence of fibrin strands (Red), red blood cells (Yellow) and white blood cells (Purple) in a clot. **B.** Pixel-wise representation of quantified clot components; RBC - red, fibrin - green, WBC - Purple, Background - yellow. x 100.



**Fig. 7.** Autofluorescence in Clot Analogues. Whole blood samples stored in PFA show a marked increase in auto-fluorescence over time. Samples stored up to two weeks exhibited an edging effect whereas samples after this point exhibited auto-fluorescence throughout the entire clot. The 1-hour sample has a group of nucleated cells (stained blue with DAPI) that are not fluorescing, fluorescence appearing to be confined to the red blood cells.

## Storage of blood clots for histological analysis

over different time points prior to fixation. For example in one study skin biopsy samples deteriorated over time, showing compression of nuclei by vacuoles when stored in saline for 1 day (Inoshita and Youngberg, 1983). After day 2 coalescence of vacuoles in basal cells along with slits between the dermis and basal layer, by day 3 these slits had formed into complete separation between the layers. After days 4 to 7 the layers had separated further and nuclei had also lost staining properties (Inoshita and Youngberg, 1983). In another study normal oral mucosa was placed into normal saline at time points of 0 (immediately fixed), 1, 3, 12, 24 and 36 hours respectively before fixation (Sengupta et al., 2014). A steady degeneration was observed from the beginning with cell vacuolisation in the basal layer at the one hour time point followed by widespread vacuolisation at three hours, loss of cellular integrity at 12 hours and total lysis of cellular architecture at 36 hours. These trends were also observed in our findings, significantly in the loss of nucleated cells at 24 hours, followed by the loss of RBC's more gradually over time suggesting that saline for histological purposes should not be used as a holding solution.

As a consequence of the potential carcinogenicity of formalin, other commercial fixatives were developed. In a blinded study five fixatives, Glyo-Fixx, STF, Omnifix II, Histochoice and Histofix were compared to formalin (Titford and Horenstein, 2005). Formalin attained the highest overall morphology and staining scores and interestingly, in regard to the assessment of clot morphology, it also scored best for cellular outline and erythrocyte integrity (Titford and Horenstein, 2005). One consideration to take when using PFA is distortion as a result of shrinkage during the fixation process (Fox et al., 1985). Human lenses stored in PFA were shown to have a large decrease in wet weight at 30 days, this process was rapid initially before becoming more gradual. Conversely lenses stored in phosphate buffered saline (PBS) increased in weight by an average of 38% by day 13, whilst others had ruptured by day 4 (Augusteyn et al., 2008).

A further consideration when using PFA for fixation is reduced antigenicity in Immunohistochemistry. PFA fixation results in the formation of cross-links between peptides (Ramos-Vara, 2005), having the effect of masking epitopes. Fixation alters the tertiary and quaternary structures of the protein but has minimal effect on the primary and secondary structures (Mason and O'leary, 1991; Hayat, 2002). Studies investigating the effects of PFA on antigenicity have shown that extended PFA storage results in reduced immunoreactivity (Battifora and Kopinski, 1986; Shi et al., 1998), however the use of enzymatic and heat induced antigen retrieval improve the immunoreactivity (Battifora and Kopinski, 1986; Shi et al., 1998). One study evaluated the effect of prolonged PFA fixation on immunohistochemical detection for 61 different antigens (Webster et al., 2009). In this study 32 antigens were cytoplasmic, 17 were localised to the plasma membrane,

8 were nuclear and 2 extracellular. Additionally, antigen retrieval was performed, 32 treated by heat induced epitope retrieval (HIER) citrate buffer (pH 6.0), 6 with HIER EDTA (pH 9.0), 13 with proteinase K and 10 with no antigen retrieval. Most antibodies tested exhibited moderate to strong immunostaining at all time points up to seven weeks with a few exceptions, also those treated with HIER tended to have better immunoreactivity compared to those treated with proteinase K or no antigen retrieval (Webster et al., 2009). This suggests that prolonged PFA fixation up to seven weeks is not a major limiting factor for immunohistochemistry but also the effects of prolonged fixation are antibody and antigen dependent (Webster et al., 2009).

Delays in fixation have been shown to have an effect on antigen immunoreactivity. Immunohistochemistry performed on oestrogen receptor and progesterone receptor showed a drop in staining intensity in oestrogen after 2 hours and progesterone after one hour in saline prior to fixation (Khoury et al., 2009). The recommendations from this study were to not delay fixation beyond one hour and to avoid storing samples overnight.

### Autofluorescence

Tissue stored in PFA up to 2 weeks showed autofluorescence as an edging effect on the section, this being associated with red blood cells. At 1 month in PFA this effect was more pronounced throughout the tissue, suggesting that PFA itself enhances autofluorescence. Immunofluorescent analysis requires processing and embedding tissue at the earliest possible time.

### Limitations

This study has limitations in that clot analogues are not real clots that form over time (LAA) and thus may be slightly different in structural architecture from clots formed in physiological conditions. Also, as these clot analogues are generated from incomplete blood draws and refrigerated, many of the components involved in the clotting process under physiological conditions may be inactivated.

### Conclusions

Short term storage of clots in saline/heparinised saline in the acute setting is acceptable, but clots should be transferred into PFA immediately after the endovascular procedure in order to preserve the histological integrity of the clot. Clots stored in PFA should be processed within one month.

---

*Financial support.* This work was supported by the European Regional Development Fund and Science Foundation Ireland under Ireland's European Structural and Investment Fund (Grant Number 13/RC/2073) and Cerenovus.

---

## References

- Augusteyn R.C., Vrensen G. and Willekens B. (2008). The effect of paraformaldehyde fixation and pbs storage on the water content of the human lens. *Mol. Vis.* 14, 90.
- Battifora H. and Kopinski M. (1986). The influence of protease digestion and duration of fixation on the immunostaining of keratins. A comparison of formalin and ethanol fixation. *J. Histochem. Cytochem.* 34, 1095-1100.
- Berkhemer O.A., Fransen P.S., Beumer D., Van Den Berg L.A., Lingsma H.F., Yoo A.J., Schonewille W.J., Vos J.A., Nederkoorn P.J. and Wermer M.J. (2015). A randomized trial of intraarterial treatment for acute ischemic stroke. *N. Engl. J. Med.* 372, 11-20.
- Campbell B.C., Mitchell P.J., Kleinig T.J., Dewey H.M., Churilov L., Yassi N., Yan B., Dowling R.J., Parsons M.W. and Oxley T.J. (2015). Endovascular therapy for ischemic stroke with perfusion-imaging selection. *N. Engl. J. Med.* 372, 1009-1018.
- Chueh J.Y., Wakhloo A.K., Hendricks G.H., Silva C.F., Weaver J.P. and Gounis M.J. (2011). Mechanical characterization of thromboemboli in acute ischemic stroke and laboratory embolus analogs. *Am. J. Neuroradiol.* 32, 1237.
- De Meyer S., Andersson T., Baxter B., Bendszus M., Brouwer P., Brinjikji W., Campbell B., Costalat V., Dávalos A. and Demchuk A. (2017). Analyses of thrombi in acute ischemic stroke: A consensus statement on current knowledge and future directions. *Int. J. Stroke* 12, 606.
- Feigin V.L., Roth G.A., Naghavi M., Parmar P., Krishnamurthi R., Chugh S., Mensah G.A., Norrving B., Shiuie I. and Ng M. (2016). Global burden of stroke and risk factors in 188 countries, during 1990-2013: A systematic analysis for the global burden of disease study 2013. *Lancet Neurol.* 15, 913-924.
- Fiehler J. and Gerloff C. (2015). Mechanical thrombectomy in stroke. *Dtsch. Aerztebl. Int.* 112, 830.
- Fitzgerald S., Wang S., Dai D., Murphree D., Pandit A., Douglas A., Kadirvel R., Brinjikji W., Kallmes D.F. and Doyle K.M. (2018). Machine-learned characterization of acute ischemic stroke clots reveals a correlation between clot composition and hu density on CT. *International Stroke Conference. Los Angeles, CA, USA. January 23-26, 2018.*
- Fox C.H., Johnson F.B., Whiting J. and Roller P.P. (1985). Formaldehyde fixation. *J. Histochem. Cytochem.* 33, 845-853.
- Goyal M., Demchuk A.M., Menon B.K., Eesa M., Rempel J.L., Thornton J., Roy D., Jovin T.G., Willinsky R.A. and Sapkota B.L. (2015). Randomized assessment of rapid endovascular treatment of ischemic stroke. *N. Eng. J. Med.* 372, 1019-1030.
- Hayat M.A. (2002). *Microscopy, immunohistochemistry, and antigen retrieval methods: For light and electron microscopy.* Springer Science & Business Media.
- Inoshita T. and Youngberg G.A. (1983). Artfactual hydropic degeneration in skin biopsy specimens immersed in saline: A light and electron microscopic study. *Am. J. Clin. Pathol.* 80, 206-209.
- Jovin T.G., Chamorro A., Cobo E., de Miquel M.A., Molina C.A., Rovira A., San Román L., Serena J., Abilleira S. and Ribó M. (2015). Thrombectomy within 8 hours after symptom onset in ischemic stroke. *N. Engl. J. Med.* 372, 2296-2306.
- Khoury T., Sait S., Hwang H., Chandrasekhar R., Wilding G., Tan D. and Kulkarni S. (2009). Delay to formalin fixation effect on breast biomarkers. *Modern Pathol.* 22, 1457.
- Maekawa K., Shibata M., Nakajima H., Mizutani A., Kitano Y., Seguchi M., Yamasaki M., Kobayashi K., Sano T. and Mori G. (2018). Erythrocyte-rich thrombus is associated with reduced number of maneuvers and procedure time in patients with acute ischemic stroke undergoing mechanical thrombectomy. *Cerebrovasc. Dis. Extra* 8, 39-49.
- Mason J.T. and O'leary T.J. (1991). Effects of formaldehyde fixation on protein secondary structure: A calorimetric and infrared spectroscopic investigation. *J. Histochem. Cytochem.* 39, 225-229.
- NINDS rt-PA Stroke Study Group (1995). Tissue plasminogen activator for acute ischemic stroke. *N. Engl. J. Med.* 333, 1581-1588.
- Ramos-Vara J. (2005). Technical aspects of immunohistochemistry. *Vet. Pathol.* 42, 405-426.
- Saver J.L., Goyal M., Bonafe A., Diener H.-C., Levy E.I., Pereira V.M., Albers G.W., Cognard C., Cohen D.J., Hacke W., Jansen O., Jovin T.G., Mattle H.P., Nogueira R.G., Siddiqui A.H., Yavagal D.R., Baxter B.W., Devlin T.G., Lopes D.K., Reddy V.K., du Mesnil de Rochemont R., Singer O.C., Jahan R.; SWIFT PRIME Investigators. (2015). Stent-retriever thrombectomy after intravenous t-PA vs. T-PA alone in stroke. *N. Engl. J. Med.* 372, 2285-2295.
- Seger S., Stritt M., Vezzali E., Nayler O., Hess P., Groenen P.M. and Stalder A.K. (2018). A fully automated image analysis method to quantify lung fibrosis in the bleomycin-induced rat model. *PLoS One* 13, e0193057.
- Sengupta S., Prabhat K., Gupta V., Vij H., Vij R. and Sharma V. (2014). Artefacts produced by normal saline when used as a holding solution for biopsy tissues in transit. *J. Maxillofac. Oral Surg.* 13, 148-151.
- Shi S.R., Cote R.J., Chaiwun B., Young L.L., Shi Y., Hawes D., Chen T. and Taylor C.R. (1998). Standardization of immunohistochemistry based on antigen retrieval technique for routine formalin-fixed tissue sections. *Applied Immunohistochem.* 6, 89-96.
- Stritt M., Bär R., Freyss J., Marrie J., Vezzali E., Weber E. and Stalder A. (2011). Supervised machine learning methods for quantification of pulmonary fibrosis. In: *MDA*. pp 24-37.
- Titford M.E. and Horenstein M.G. (2005). Histomorphologic assessment of formalin substitute fixatives for diagnostic surgical pathology. *Arch. Pathol. Lab. Med.* 129, 502-506.
- Webster J.D., Miller M.A., DuSold D. and Ramos-Vara J. (2009). Effects of prolonged formalin fixation on diagnostic immunohistochemistry in domestic animals. *J. Histochem. Cytochem.* 57, 753-761.